

Management of Massive Arterial Hemorrhage After Pancreatobiliary Surgery: Does Embolotherapy Contribute to Successful Outcome?

Yoshiro Fujii · Hiroshi Shimada · Itaru Endo ·
Ken-ichi Yoshida · Ken-ichi Matsuo ·
Kazuhisa Takeda · Michio Ueda · Daisuke Morioka ·
Kuniya Tanaka · Shinji Togo

Published online: 8 March 2007
© 2007 The Society for Surgery of the Alimentary Tract

Abstract Massive arterial hemorrhage is, although unusual, a life-threatening complication of major pancreatobiliary surgery. Records of 351 patients who underwent major surgery for malignant pancreatobiliary disease were reviewed in this series. Thirteen patients (3.7%) experienced massive hemorrhage after surgery. Complete hemostasis by transcatheter arterial embolization (TAE) or re-laparotomy was achieved in five patients and one patient, respectively. However, 7 of 13 cases ended in fatality, which is a 54% mortality rate. Among six survivors, one underwent selective TAE for a pseudoaneurysm of the right hepatic artery (RHA). Three patients underwent TAE proximal to the proper hepatic artery (PHA): hepatic inflow was maintained by successful TAE of the gastroduodenal artery in two and via a well-developed subphrenic artery in one. One patient had TAE of the celiac axis for a pseudoaneurysm of the splenic artery (SPA), and hepatic inflow was maintained by the arcades around the pancreatic head. One patient who experienced a pseudoaneurysm of the RHA after left hemihepatectomy successfully underwent re-laparotomy, ligation of RHA, and creation of an ileocolic arteriportal shunt. In contrast, four of seven patients with fatal outcomes experienced hepatic infarction following TAE proximal to the PHA or injury of the common hepatic artery during angiography. One patient who underwent a major hepatectomy for hilar bile duct cancer had a recurrent hemorrhage after TAE of the gastroduodenal artery and experienced hepatic failure. In the two patients with a pseudoaneurysm of the SPA or the superior mesenteric artery, an emergency re-laparotomy was required to obtain hemostasis because of worsening clinical status. Selective TAE distal to PHA or in the SPA is usually successful. TAE proximal to PHA must be restricted to cases where collateral hepatic blood flow exists. Otherwise or for a pseudoaneurysm of the superior mesenteric artery, endovascular stenting, temporary creation of an ileocolic arteriportal shunt, or vascular reconstruction by re-laparotomy is an alternative.

Keywords Hemorrhage · Pseudoaneurysm ·
Pancreato-biliary surgery · Transcatheter arterial
embolization

Recent advances in surgical technique and postoperative management of major pancreatobiliary surgery have re-

duced the morbidity and mortality. However, the problem of life-threatening postoperative arterial hemorrhage caused by pseudoaneurysm rupture, although uncommon, has received little attention.^{1–6} Immediate arteriography to identify the site of bleeding and subsequent treatment by radiological intervention have been the first approach for the last decade.^{7–9} The efficacy of transcatheter arterial embolization (TAE) is well established.^{8–18} Nevertheless, occlusion by TAE sometimes causes distal end-organ damage, even though bleeding has been controlled.^{9–11} Indeed, complete interruption of hepatic inflow may lead to fatal hepatic necrosis, but risk factors for whole liver infarction have yet to be identified. Knowledge of which sites are associated with a high risk of hepatic necrosis

Y. Fujii (✉) · H. Shimada · I. Endo · K. Yoshida · K. Matsuo ·
K. Takeda · M. Ueda · D. Morioka · K. Tanaka · S. Togo
Department of Gastroenterological Surgery,
Yokohama City University School of Medicine,
3-9 Fukuura, Kanazawa-ku,
Yokohama 236-0004, Japan
e-mail: Yfvj@aol.com

would enable surgeons to choose an alternative to TAE, such as vascular reconstruction. Recent reports have documented an advantage of endovascular stenting over TAE.^{19–22} We reviewed the records of patients who experienced massive arterial hemorrhage after pancreatobiliary surgery to help generate guidelines for the management of postoperative pseudoaneurysm rupture.

Patients and Methods

From January 1993 to December 2005, 351 patients underwent major surgery for malignant pancreatobiliary disease in the Department of Gastroenterological Surgery, Yokohama City University. The cases were pancreatic cancer ($n=139$), distal bile duct cancer ($n=58$), ampullary cancer ($n=46$), hilar bile duct cancer ($n=47$), advanced gallbladder cancer ($n=42$), and intrahepatic cholangiocarcinoma ($n=19$). Procedures included pylorus-preserving pancreatoduodenectomy (PPPD) in 113, conventional pancreatoduodenectomy (PD) in 84, distal pancreatectomy (DP) in 35, segmental resection of the pancreas in 4, total pancreatectomy in 6, bile duct resection with partial hepatectomy in 98, and PD combined with partial hepatectomy (HPD) in 11. Patients undergoing isolated bile duct resection or partial hepatectomy without bile duct resection were excluded. Except for the patients who underwent DP, all patients received biliary tract reconstruction and skeletonization of the hepatic arteries to complete lymphadenectomy within the hepatoduodenal ligament. Pancreatojejunostomy was created as an end-to-side, duct-to-mucosa anastomosis with a stenting tube, or via the pancreatic duct insertion technique with total tube drainage when the pancreatic duct was smaller than 3 mm. Hepaticojejunostomy was created end-to-side in a single layer.

Massive postoperative arterial hemorrhage was defined as bleeding requiring a transfusion of 2 or more units of packed red blood cells, an invasive intervention such as laparotomy or TAE and monitoring in the surgical intensive care unit within 24 h of the onset of hemorrhage. The medical records of these patients were analyzed retrospectively.

Results

Of the 351 patients who underwent a major procedure, 13 (3.7%) presented with massive postoperative arterial hemorrhage (10 men and 3 women; average age, 66 ± 10 years). The demographic and clinical characteristics are summarized in Table 1.

After restoration of hemodynamic stability by volume loading, 10 of 13 patients underwent emergency pan-abdominal angiography visualizing the celiac axis (CA)

and superior mesenteric artery (SMA) by standard Seldinger technique. The other three patients required emergency laparotomy without angiography because their clinical status was deteriorating.

Of the 10 patients who underwent angiography, an arterial pseudoaneurysm was detected in 7: right hepatic artery (RHA) in two, gastroduodenal artery (GDA) in three, common hepatic artery (CHA) in one, and splenic artery (SPA) in one. Three patients had extravasation in the area of the middle hepatic artery (MHA), proper hepatic artery (PHA), or GDA without a clear source of bleeding (see Table 1).

TAE was attempted in nine patients using various coil occlusion devices. Table 1 details the origin of bleeding and the sites of TAE. Complete hemostasis was achieved by TAE in five patients, but hemostasis was only temporary in four: two required a second TAE and two required laparotomy to control rebleeding.

Of the three patients with a pseudoaneurysm distal to the PHA, one received selective TAE of the RHA with a successful outcome (patient 1). A second patient had recurrent hemorrhage after TAE of the RHA and second TAE of the PHA was required. Unfortunately, the cluster of coils compressed the portal vein and portal flow was disrupted after the second TAE. This patient died of hepatic failure secondary to hepatic hypoperfusion (patient 2). The third patient had undergone extended left hepatectomy with resection of the RHA and had bleeding from the site of the RHA reconstruction (patient 3). If TAE had been performed at the RHA, inflow to the small remnant liver would be completely interrupted, and fatal hepatic failure would have been the most likely outcome. Instead, we re-operated, ligated the RHA, and created an ileocolic arteriportal shunt to supply the hepatic remnant. The patient survived without hepatic failure. However, portal hypertension developed because this shunt remained patent 6 months after reoperation, and the patient died of spinal metastasis 11 months after the initial operation.

In seven patients, the pseudoaneurysm was proximal to the PHA and involved the GDA or CHA. Two patients successfully underwent selective TAE of the GDA for a pseudoaneurysm that originated from the ligated GDA. One patient had a replaced RHA from the CA, which contributed to a favorable outcome (patient 4, Fig. 1). One patient underwent TAE of the CHA uneventfully because the hepatic inflow was narrowly maintained by the left subphrenic artery (patient 6, Fig. 2). In contrast, the patient who had extravasation of the PHA without a discrete source had intimal injury and occlusion of the CHA during angiography. The patient experienced a liver abscess that was difficult to treat and died of sepsis and cancer recurrence during a long hospital stay (patient 7). Of the three patients who underwent right hepatectomy, two had complete disruption of the inflow to the hepatic remnant by TAE of

Table 1 Baseline Characteristics of Patients

Case	Disease	Origin of bleed	Surgery	Interval (days) ^a	Site of TAE	Re-laparotomy	Cause of bleed	Outcome
1	Ampullary cancer	RHA	PPPD	10	RHA	No	Pancreatic leak	Alive
2	Gallbladder cancer	RHA and RHA	HPD	8 and 12	RHA and PHA	No	Minor injury	Hepatic failure died
3	Hilar bile duct cancer	RHA	Extended left hepatectomy	9	None	No	Unsuccessful reconstruction	Cancer recurrence, died
4	Gallbladder cancer	GDA	HPD	10	GDA	No	Pancreatic leak	Alive
5	Distal bile duct cancer	GDA	PD	11	GDA	Yes	Minor injury	Alive
6	Distal bile duct cancer	CHA	PPPD	24	CHA	No	Pancreatic leak	Alive
7	Distal bile duct cancer	PHA	PD	7	None	No	Pancreatic leak	Sepsis, died
8	Hilar bile duct cancer	GDA	Right hepatectomy	7	CHA	Yes	Minor injury	Hepatic failure died
9	Gallbladder cancer	MHA and GDA	Right hepatectomy	13 and 27	MHA and CHA	No	Pancreatic leak	Hepatic failure died
10	Gallbladder cancer	GDA	Right hepatectomy	7	GDA	Yes	Pancreatic leak	Hepatic failure died
11	Pancreatic cancer	SPA	DP	17	CA	Yes	Pancreatic leak	Alive
12	Intrahepatic cholangiocarcinoma	SPA	HPD	9	None	Yes	Minor injury	Hepatic failure died
13	Pancreatic cancer	SMA	PPPD	34	None	Yes	Pancreatic leak	MOF, died

TAE Transcatheter arterial embolization, *RHA* right hepatic artery, *PHA* proper hepatic artery, *GDA* gastroduodenal artery, *CHA* common hepatic artery, *MHA* middle hepatic artery, *SPA* splenic artery, *CA* celiac axis, *SMA* superior mesenteric artery, *PPPD* pylorus preserving pancreatoduodenectomy, *HPD* pancreatoduodenectomy combined with partial hepatectomy, *DP* distal pancreatectomy, *PD* pancreatoduodenectomy, *MOF* multiple organ failure

^aDays from surgery to hemorrhage

the CHA, leading to fatal hepatic failure (patients 8 and 9), and one underwent unsuccessful TAE of the GDA and required a laparotomy. Vascular ligation at the pancreatic head was successful in achieving hemostasis, but hepatic failure secondary to hemorrhagic shock proved fatal 59 days after the initial surgery (patient 10).

Of the two patients with a pseudoaneurysm originating from the SPA, one underwent TAE of the CA with a favorable outcome because the pancreatoduodenal arcades around the pancreatic head maintained hepatic inflow after DP (patient 11, Fig. 3). The other patient underwent an emergency laparotomy. Complete hemostasis was achieved

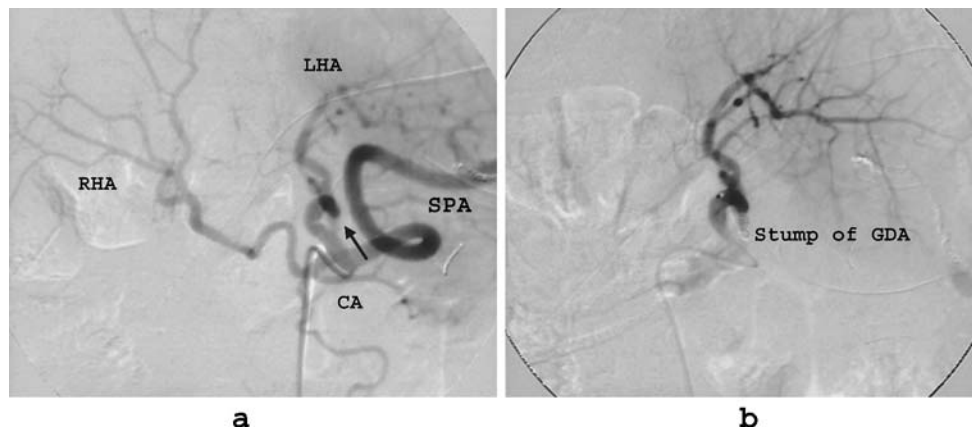


Figure 1 Case 3. A 74-year-old woman with advanced gallbladder cancer presented with massive hemorrhage 10 days after pancreatoduodenectomy combined with partial hepatectomy of the segments (Couinaud segments) IVb and V. Angiogram of the common hepatic artery [the right hepatic artery (RHA) replaced from the celiac axis (CA)] showed a pseudoaneurysm (*arrow*) originating from the stump of the gastroduodenal artery (GDA). (a) Complete hemostasis was obtained using transcatheter arterial embolization of this stump. The patient survived without hepatic failure because the hepatic inflow was maintained by the replaced RHA (b). *LHA* Left hepatic artery, *SPA* splenic artery.

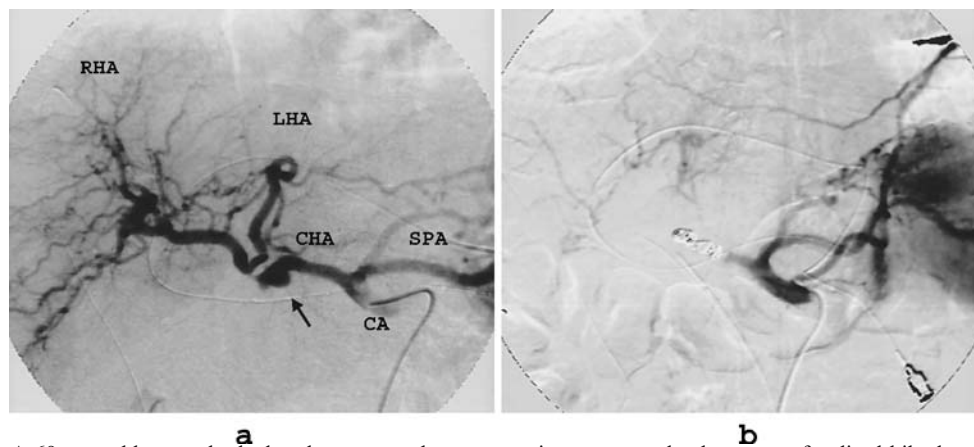


Figure 2 Case 4. A 69-year-old man who had undergone a pylorus preserving pancreatoduodenectomy for distal bile duct cancer had massive hemorrhage 24 days after surgery. Angiogram of the celiac axis (CA) showed a pseudoaneurysm (*arrow*) originating from the common hepatic artery (CHA) (a) Complete hemostasis was obtained using transcatheter arterial embolization proximally and distally to the origin of the pseudoaneurysm, but the proper hepatic artery was occluded. The hepatic arterial inflow was narrowly maintained via the left subphrenic artery (b). The patient had an uneventful course. RHA Right hepatic artery, LHA left hepatic artery, SPA splenic artery.

by ligation, but hemorrhagic shock resulted in subsequent hepatic failure (patient 12).

One patient with a pseudoaneurysm of the SMA underwent surgical resection with vascular reconstruction. However, the patient died of recurrent pancreatic cancer and multiple organ failure during the hospital stay (patient 13).

Seven of 13 patients died in the hospital; thus, the mortality rate for massive arterial hemorrhage was 54%, and the overall mortality rate was 2.0%.

Case reports of some patients are illustrated in Figs. 1, 2, and 3.

Discussion

Rupture of a pseudoaneurysm, although uncommon, can cause life-threatening hemorrhage even comparatively late after pancreatobiliary surgery.^{1–6} This morbidity rate for pancreatectomy was reported to range from 2.0% to 4.6%.^{4–6,11,12} A pseudoaneurysm is a pulsatile hematoma surrounded by fibrous tissue that communicates with the artery via a disruption of the arterial wall. It can rupture into the peritoneal cavity, the gastrointestinal tract, or bilio-pancreatic ducts through a point of weakness, most

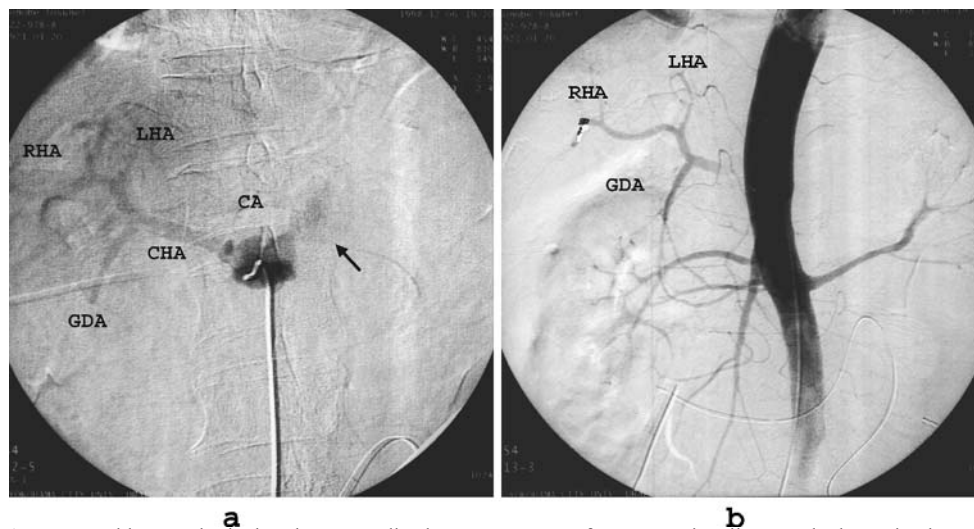
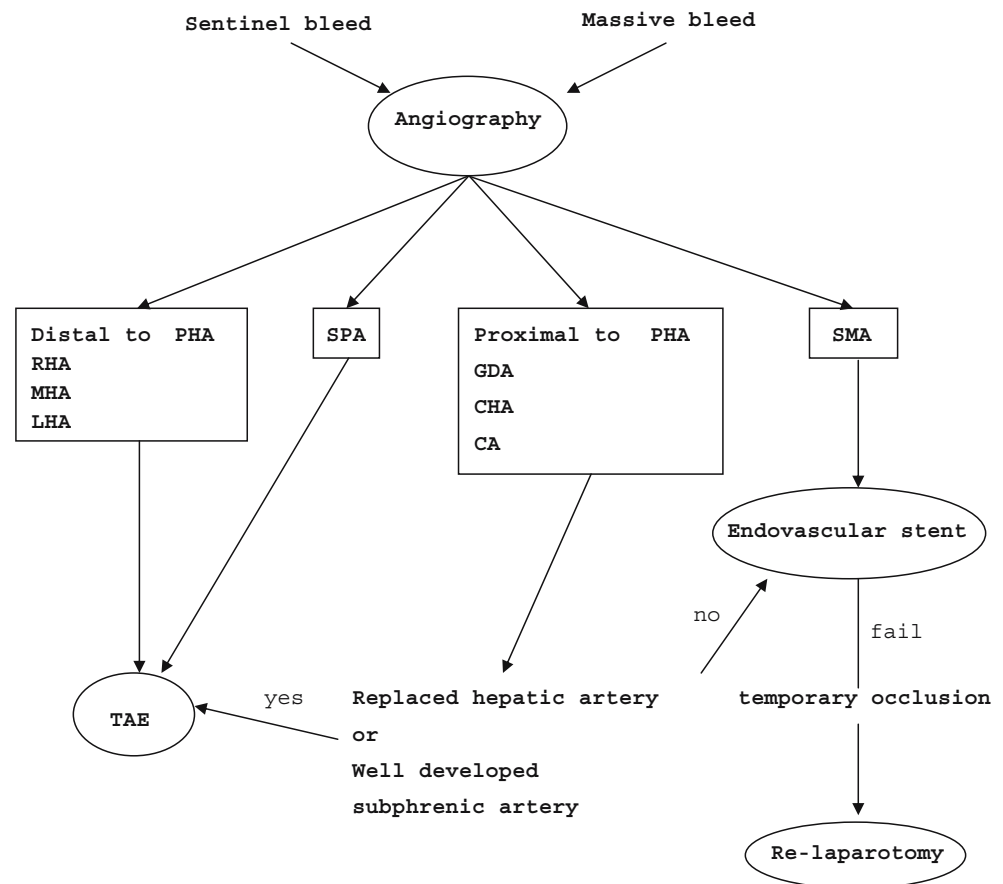


Figure 3 Case 8. A 77-year-old man who had undergone a distal pancreatectomy for pancreatic tail cancer had massive hemorrhage 17 days after surgery. Angiogram of the celiac axis (CA) showed a pseudoaneurysm (*arrow*) originating from the splenic artery (a). Hemostasis was obtained using transcatheter arterial embolization (TAE) of the CA. The common hepatic artery (CHA) was occluded by TAE but the hepatic inflow was maintained via the arcades of the pancreatic head from the superior mesenteric artery (b). The patient had a favorable course. RHA Right hepatic artery, LHA left hepatic artery, GDA gastrooduodenal artery.

Figure 4 Scheme for an approach to the management of a pseudoaneurysm according to the site of bleeding. PHA Proper hepatic artery, RHA right hepatic artery, MHA middle hepatic artery, LHA left hepatic artery, SPA splenic artery, GDA gastroduodenal artery, CHA common hepatic artery, CA celiac axis, SMA superior mesenteric artery, TAE transcatheter arterial embolization.



commonly the anastomotic site. The Japanese Multi-institutional Study of 1,066 patients who underwent PPPD reported that the incidence of intra-abdominal hemorrhage was 3.5% and that of upper gastrointestinal hemorrhage was 3.2%.²³

The etiology of pseudoaneurysm formation has yet to be clearly delineated. It is believed to be most commonly due to pancreatic fistula or anastomotic dehiscence.^{1–4,10–12} However, pseudoaneurysm can develop far from the pancreatic cut surface, and there is no evidence of a pancreatic leak in some cases. It has been suggested that skeletonization of the visceral arteries may result in iatrogenic vascular injury (e.g., secondary to diathermy).^{10,14} In three patients in our series, the etiology was thought to be a minor vascular injury that occurred during dissection (see Table 1). Previous reports found that the patients with massive arterial bleeding frequently had septic complications.^{3,4,17} Therefore, both arterial injury and infection can contribute to massive arterial hemorrhage. Whether or not preoperative obstructive jaundice is an etiologic fact remains controversial.^{3,24}

Some clinical studies found that a preliminary warning bleeding (sentinel bleeding) precedes major hemorrhage.^{1,2,9–13} This sentinel bleeding probably indicates local

infection and an anastomotic leak.² So, recognition of a sentinel bleeding and prompt intervention can be life-saving.

Angiography is necessary to identify the site of bleeding, and TAE is the treatment of choice to control massive bleeding and achieve hemodynamic stabilization. When performing TAE for a pseudoaneurysm, microcoils must be placed both proximally and distally to the origin, not within the pseudoaneurysm itself.^{11,25}

When the origin of the pseudoaneurysm is distal to the PHA, left hepatic artery, RHA, or MHA, TAE should be highly selective to preserve the other branch to the liver. Selective TAE without devascularization of the other lobe provides optimal protection of the liver parenchyma (patient 1).¹⁵ Nevertheless, superselective TAE frequently is not possible. Inadvertent occlusion of PHA, even when bleeding is controlled, may cause fatal hepatic infarction (patient 2).¹⁰ Therefore, the success of superselective TAE distal to the PHA depends on the expertise of the radiologist.

Superselective TAE is difficult or even impossible for a pseudoaneurysm proximal to the PHA.²⁴ When the GDA is ligated close to its divergence from the CHA, you must embolize the CHA to obtain hemostasis. The proximal and

distal control of a bleeding pseudoaneurysm of the PHA or CHA usually results in complete occlusion of hepatic arterial flow. Fortunately, we successfully performed TAE of the GDA in patient 4 because the patient had the replaced RHA from CA, and it was unaffected by TAE. Even if the CHA is occluded, the prognosis is good when hepatic inflow can be maintained by a replaced hepatic artery,^{6,13,14} but success is not uniform. In another case, hepatic inflow was narrowly maintained by the left subphrenic artery after TAE of the CHA (patient 6). A similar case has been described previously.¹⁶ The liver can tolerate considerable arterial embolization because of its multiple collateral pathways, mainly via the subphrenic arteries. Unless the surgical procedure includes mobilization of both lobes of the liver, as long as the subphrenic arteries are well developed, TAE proximal to the PHA should lead to a successful outcome. However, TAE proximal to the PHA usually risks occlusion of the CHA with the attendant risk of necrosis and liver failure.^{9,17} The authors believe that the presence of a few collateral pathways might make liver abscesses difficult to treat and may be associated with high morbidity and mortality rates (patient 7).¹⁰ Complete interruption of arterial inflow to the remaining liver after major hepatectomy usually causes imminent hepatic failure (patients 8 and 9). Emergency laparotomy and vascular reconstruction are the most certain treatments for this type of bleeding, but preoperative angiography is highly recommended to identify the bleeding site, although surgery should not be excessively delayed. Endovascular stenting is another option in reestablishing the continuity of the bleeding artery, such as GDA, PHA, or CHA.^{19–22} A covered stent makes it possible to arrest the bleeding, while preserving patency. Potential disadvantages include longer duration to obtain hemostasis than TAE, technical difficulties in negotiating tortuous arteries, and the risk of arterial rupture due to low flexibility and fragile vascular walls. In the case of a stented hepatic artery, the progressive occlusion of the stent due to intimal hyperplasia would not influence outcome because this process is gradual and allows for the formation of collateral pathways.²¹ Therefore, a stent-graft delivered into a bleeding artery proximal to PHA may be the treatment of choice. When this procedure is technically difficult, vascular reconstruction should be performed after temporary occlusion by interventional radiology. When vascular reconstruction is difficult and ligation is required to obtain hemostasis, creation of an ileocolic arteriportal shunt is another option,²⁶ which we performed successfully in patient 3. Thus, the indications for TAE proximal to the PHA are limited to cases where the replaced hepatic artery exists or the subphrenic arteries are well developed.

Pseudoaneurysm originating from the SPA is well described as a complication of pancreatitis,^{27,28} but this is

an unusual source of bleeding after pancreatobiliary surgery. Selective TAE is indicated because ischemia of the spleen is rare. However, when the origin of the pseudoaneurysm is close to the CA, selective TAE proximal to the SPA is as difficult as the case of bleeding from the GDA. Therefore, when the SPA is divided in surgery, it may be better to leave the proximal part of the ligation site in some degree. TAE of the CA is contraindicated as it will completely interrupt hepatic arterial flow in most cases (patient 11).

When the origin of a pseudoaneurysm is the SMA, it may be extremely difficult or even impossible to preserve mesenteric arterial flow. Hence, resection of the pseudoaneurysm with vascular reconstruction is indicated (patient 11). Endovascular stenting may be an alternative deserving further study.

Hemorrhagic shock is a potentially fatal complication that may result in hepatic failure (patient 10). Rebleeding after TAE is a poor prognostic factor. As rebleeding is often due to a pancreatic leak or intraperitoneal septic condition, pancreatic drainage and loculated fluid collections are mandatory.⁶ The management of anastomotic dehiscence after pancreatectomy, whether a completion pancreatectomy is necessary or not, is controversial.^{1,6,29–33} When management of the dehiscence is difficult or when severe organ failure is present, completion pancreatectomy is probably necessary.^{1,6,29–31}

Analysis of our experience and literature review suggests that management of a pseudoaneurysm must be individualized according to the site of bleeding (Fig. 4). We have developed a protocol for managing massive postoperative arterial hemorrhage and are evaluating it postoperatively in a prospective fashion. We hope to report the value of this approach in the future.

References

- Shankar S, Russell RCG. Hemorrhage in pancreatic disease. *Br J Surg* 1989;76:863–866.
- Brodsky JT, Tumbull AD. Arterial hemorrhage after pancreatoduodenectomy. The sentinel bleed. *Arch Surg* 1991;126:1037–1040.
- Rumstadt B, Schwab M, Korth P, Samman M, Trede M. Hemorrhage after pancreatoduodenectomy. *Ann Surg* 1998;227:236–241.
- van Berge Henegouwen MI, Allema JH, van Gulik TM, Verbeek PCM, Obertop H, Gouma DJ. Delayed massive haemorrhage after pancreatic and biliary surgery. *Br J Surg* 1995;82:1527–1531.
- Bassi C, Falconi M, Salvia R, Mascetta G, Molinari E, Pederzoli P. Management of complications after pancreaticoduodenectomy in a high volume center: Results on 150 consecutive patients. *Dig Surg* 2001;18:453–458.
- Santoro R, Carlini M, Carboni F, Nicolas C, Santoro E. Delayed massive arterial hemorrhage after pancreaticoduodenectomy for cancer. Management of a life-threatening complication. *Hepatogastroenterology* 2003;50:2199–2204.

7. Gmbiez LP, Ernst OJ, Merlier OA, Porte HL, Chambon JPM, Quandalle PA. Arterial embolization for bleeding pseudocysts: complicating chronic pancreatitis. *Arch Surg* 1997;132:1016–1021.
8. Gorich J, Rilinger N, Huppert P, et al. Non-operative management of arterial liver hemorrhages. *Eur Radiol* 1999;9:85–88.
9. Sato N, Yamaguchi K, Shimizu S, et al. Coil embolization of bleeding visceral pseudoaneurysms following pancreatectomy. The importance of early angiography. *Arch Surg* 1998;133:1099–1102.
10. Reber PU, Baer HU, Patel AG, Wildi S, Triller J, Büchler MW. Superselective microcoil embolization: Treatment of choice in high-risk patients with extrahepatic pseudoaneurysms of the hepatic arteries. *J Am Coll Surg* 1998;186:325–330.
11. Yoon YS, Kim SW, Her KH, et al. Management of postoperative hemorrhage after pancreatoduodenectomy. *Hepatogastroenterology* 2003;50:2208–2212.
12. Okuno A, Miyazaki M, Ito H, et al. Nonsurgical management of ruptured pseudoaneurysm in patients with hepatobiliary pancreatic diseases. *Am J Gastroenterol* 2001;96:1067–1071.
13. Otah E, Cushin BJ, Rozenblit GN, Neff R, Otah KE, Cooperman AM. Visceral artery pseudoaneurysms following pancreatoduodenectomy. *Arch Surg* 2002;137:55–59.
14. Sugimoto H, Kaneko T, Ishiguchi T, et al. Delayed rupture of a pseudoaneurysm following pancreatoduodenectomy: report of a case. *Surg Today* 2001;31:932–935.
15. Aranha GV, O’Neil S, Borge MA. Successful nonoperative management of bleeding hepatic artery pseudoaneurysm following pancreaticoduodenectomy. *Dig Surg* 1999;16:528–530.
16. Shibata T, Sagoh T, Ametani F, Maetani Y, Itoh K, Konishi J. Transcatheter microcoil embolotherapy for ruptured pseudoaneurysm following pancreatic and biliary surgery. *Cardiovasc Interv Radiol* 2002;25:180–185.
17. Choi SH, Moon HJ, Heo JS, Joh JW, Kim YI. Delayed hemorrhage after pancreaticoduodenectomy. *J Am Coll Surg* 2004;199:186–191.
18. de Weerth A, Buggisch P, Nicolas V, Maas R. Pancreaticoduodenal artery aneurysm—a life threatening cause of gastrointestinal hemorrhage: Case report and review of the literature. *Hepatogastroenterology* 1998;45:1651–1654.
19. Paci E, Antico E, Candelari R, Alborino S, Marmorale C, Landi E. Pseudoaneurysm of the common hepatic artery: Treatment with a stent-graft. *Cardiovasc Interv Radiol* 2000;23:472–484.
20. Tan M, di Carlo AD, Stein LA, Cantarovich M, Tchervenkov JI, Metrakos P. Pseudoaneurysm of the superior mesenteric artery after pancreas transplantation treated by endovascular stenting. *Transplantation* 2001;72:336–338.
21. Mansueto G, D’Onofrio M, Lacono C, Rozzanigo U, Serio G, Procacci C. Gastroduodenal artery stump haemorrhage following pylorus-sparing Whipple procedure: Treatment with covered stents. *Dig Surg* 2002;19:237–240.
22. Rami P, Williams D, Forauer A, Cwikiel W. Stent-graft treatment of patients with acute bleeding from hepatic artery branches. *Cardiovasc Interv Radiol* 2005;28:153–158.
23. Yamaguchi K, Tanaka M, Chijiwa K, Nagakawa T, Imamura M, Takada T. Early and late complications of pylorus-preserving pancreatoduodenectomy in Japan 1998. *J Hepatobil Pancreat Surg* 1999;6:303–311.
24. Balachandran P, Sikora SS, Raghavendra Rao RV, Kumar A, Saxena R, Kapoor VK. Haemorrhagic complications of pancreaticoduodenectomy. *ANZ J Surg* 2004;74:945–950.
25. Takahashi T, Shimada K, Kobayashi N, Kakita A. Migration of steel-wire coils into the stomach after transcatheter arterial embolization for a bleeding splenic artery pseudoaneurysm: Report of a case. *Surg Today* 2001;31:458–462.
26. Teramoto K, Kawamura T, Takamatsu S, Noguchi N, Arii S. A case of hepatic artery embolization and partial arterialization of the portal vein for intraperitoneal hemorrhage after a pancreaticoduodenectomy. *Hepatogastroenterology* 2003;50:1217–1219.
27. de Perrot M, Berney T, Buhler L, Delgado X, Mentha G, Morel P. Management of bleeding pseudoaneurysms in patients with pancreatitis. *Br J Surg* 1999;86:29–32.
28. Balsarkar DJ, Joshi MA. Rupture of splenic artery pseudoaneurysm presenting with massive upper gastrointestinal bleed. *Am J Surg* 2002;183:197–198.
29. Farley DR, Schwall G, Trede M. Completion pancreatectomy for surgical complications after pancreaticoduodenectomy. *Br J Surg* 1996;83:176–179.
30. Smith CD, Sarr MG, vanHeerden JA. Completion pancreatectomy following pancreaticoduodenectomy: Clinical experience. *World J Surg* 1992;16:521–524.
31. Sarr MG, Warshaw AL. Causes and management of pseudoaneurysms. *Surg* 1998;124:116–117.
32. Wu CC, Hwang CR, Yeh DC, Hwang YC, Liu TJ, P’eng FK. Treatment for dehiscence of pancreaticojejunostomy after pancreaticoduodenectomy: Is resection of the residual pancreas necessary? *Hepatogastroenterology* 1996;43:271–274.
33. Buchler MW, Friess H, Wagner M, Kulli C, Wagens V, Z’graggen K. Pancreatic fistula after pancreatic head resection. *Br J Surg* 2000;87:883–889.