

**Original  
Article**

# Utility of Ultrasonographic Assessment of Distal Femoral Arterial Flow during Minimally Invasive Valve Surgery

Mitsuharu Hosono, MD, PhD, Hiroshi Yasumoto, MD, Shintaro Kuwauchi, MD, Yoshino Mitsunaga, MD, Shinya Kanemoto, MD, PhD, Naoki Minato, MD, PhD, and Kohei Kawazoe, MD, PhD

**Purpose:** To evaluate the utility of ultrasonographic assessment of blood flow to the lower limb below the cannulation site in minimally invasive cardiac surgery (MICS).

**Methods:** Twenty-two patients who underwent ultrasonographic assessment in MICS were reviewed retrospectively. In all patients, the right femoral artery was used for arterial cannulation. Ultrasonographic assessment was performed using a 15-MHz ultrasonography small probe, and regional oxygen saturation was monitored by near-infrared spectroscopy (NIRS).

**Results:** The mean flow velocity at the distal side of the cannulation site was  $46.2 \pm 25.4$  cm/s. In six patients, a >40% decreased from baseline regional oxygen saturation was observed. In five of the six patients, the flow velocity was very slow, and spontaneous echo contrast was also observed in three cases. Their regional oxygen saturation was improved rapidly after distal leg perfusion. In the remaining case, the flow velocity was not decreased. In another one case, the stenosis at the cannulation site was detected after decannulation and repaired immediately. No limb ischemic complications were observed in this series.

**Conclusion:** Ultrasonographic assessment combined with the NIRS monitoring is useful to prevent lower limb ischemic complications after femoral arterial cannulation in MICS.

**Keywords:** minimally invasive cardiac surgery, ultrasonography, femoral artery, limb ischemia

## Introduction

The femoral artery is commonly used as a peripheral cannulation site in patients undergoing minimally invasive cardiac surgery (MICS). However, femoral

arterial cannulation is associated with possible complications, such as vessel injuries (perforation or dissection), cerebral infarction owing to retrograde perfusion, wound infection, groin seroma, and lower leg ischemia. Lower leg ischemia can be caused by reduced flow to the lower limb owing to arterial cannulation.<sup>1,2)</sup> Some reports about severe ischemic complications as a result of femoral cannulation have been reported previously.<sup>1-5)</sup> Ischemia may result in hemodynamic instability after cessation from the cardiopulmonary bypass owing to anaerobic products in the ischemic leg and irreversible damage to leg structures including nerve and muscle damage. To avoid these complications, monitoring the lower leg tissue oxygenation and assessing lower leg perfusion are important. For this purpose, both near-infrared spectroscopy (NIRS) and ultrasonography are used during MICS in our institute. In the present study,

*Department of Cardiovascular Surgery, Kansai Medical University, Hirakata, Osaka, Japan*

Received: February 28, 2021; Accepted: April 13, 2021

Corresponding author: Mitsuharu Hosono, MD, PhD. Department of Cardiovascular Surgery, Kansai Medical University, 2-5-1 Shinmachi, Hirakata, Osaka 573-1010, Japan  
Email: mi\_hosono@hotmail.com



This work is licensed under a Creative Commons Attribution-NonCommercial-NoDerivatives International License.

©2021 The Editorial Committee of *Annals of Thoracic and Cardiovascular Surgery*

we report utility of ultrasonographic assessment of blood flow to the lower limb below the cannulation site in MICS.

## Materials and Methods

### Patients

Twenty-two patients who underwent ultrasonographic assessment in MICS surgery were reviewed retrospectively. This retrospective study was approved by the Kansai Medical University institutional review board. Patients' demographic data were summarized in **Table 1**. In all patients, the right femoral artery was used as an arterial cannulation site. Eighteen patients underwent MICS mitral valve repair and one patient underwent closure of the atrial septal defect through mini-right thoracotomy, and two patients underwent aortic root reconstruction with aortic valve repair and one patient underwent aortic valve replacement through lower partial sternotomy. Concomitant tricuspid valve annuloplasty was performed in one patient and Maze procedure was performed in two patients.

### Operative procedures

In MICS valve surgery, the arterial cannula was placed into the right common femoral artery via an open technique and a venous cannula was placed into the right atrium via the right femoral vein. The femoral arterial cannula was inserted by directly puncturing the center of a 5-0 polypropylene purse-string suture on the common

femoral artery with a standard needle and guidewire as in Seldinger's technique. The tip of the arterial cannula was placed 5 cm from the insertion site. An additional venous cannula was inserted directly into the superior vena cava through the mini-thoracotomy incision. The arterial cannulas used in this study were OptiSite (18 and 20 Fr; Edwards Lifesciences LLC, Irvine, CA, USA) and Bio-Medicus NextGen (19 and 21 Fr; Medtronic Inc., Minneapolis, MN, USA). Cannula size determined by the right femoral arterial diameter measured by CT was designed to deliver the maximum required flow. If the required flow was not obtained with the single arterial cannula, an additional cannula was placed via the left common femoral artery. Body temperature was cooled to 30°C in patients with right mini-thoracotomy incision to avoid re-expansion pulmonary edema.

### Measurement

Ultrasonographic assessment was performed after cannulated and cardiopulmonary bypass were established. The VeriQ System (Medistim, Oslo, Norway) with a 15-MHz ultrasonography probe was used for this assessment. This small ultrasonography probe (**Fig. 1A**) was used on the distal side of the cannulation site, and the internal diameter and the flow velocity were recorded in 21 patients (**Fig. 1B** and **1C**). Perfusion flow by cardiopulmonary bypass and arterial blood pressure were also recorded. We used NIRS to monitor the lower leg regional oxygen saturation (rSO<sub>2</sub>) (INVOS 5100C; Covidien, Boulder, CO, USA). The NIRS sensor was placed on the skin of muscle area in the lower leg, and the rSO<sub>2</sub> of both limbs were measured sequentially.

### Statistics

Continuous variables were expressed as means and standard deviations, and categorical variables were expressed as frequencies and percentages, where appropriate. Differences in rSO<sub>2</sub> before and after cannulation was analyzed using a paired *t*-test. Linear single regression analysis was used for correlation analysis. Statistical analyses were performed using the JMP 11 software package (SAS Institute Inc., Cary, NC, USA), and *P*-value <0.05 was considered statistically significant.

## Results

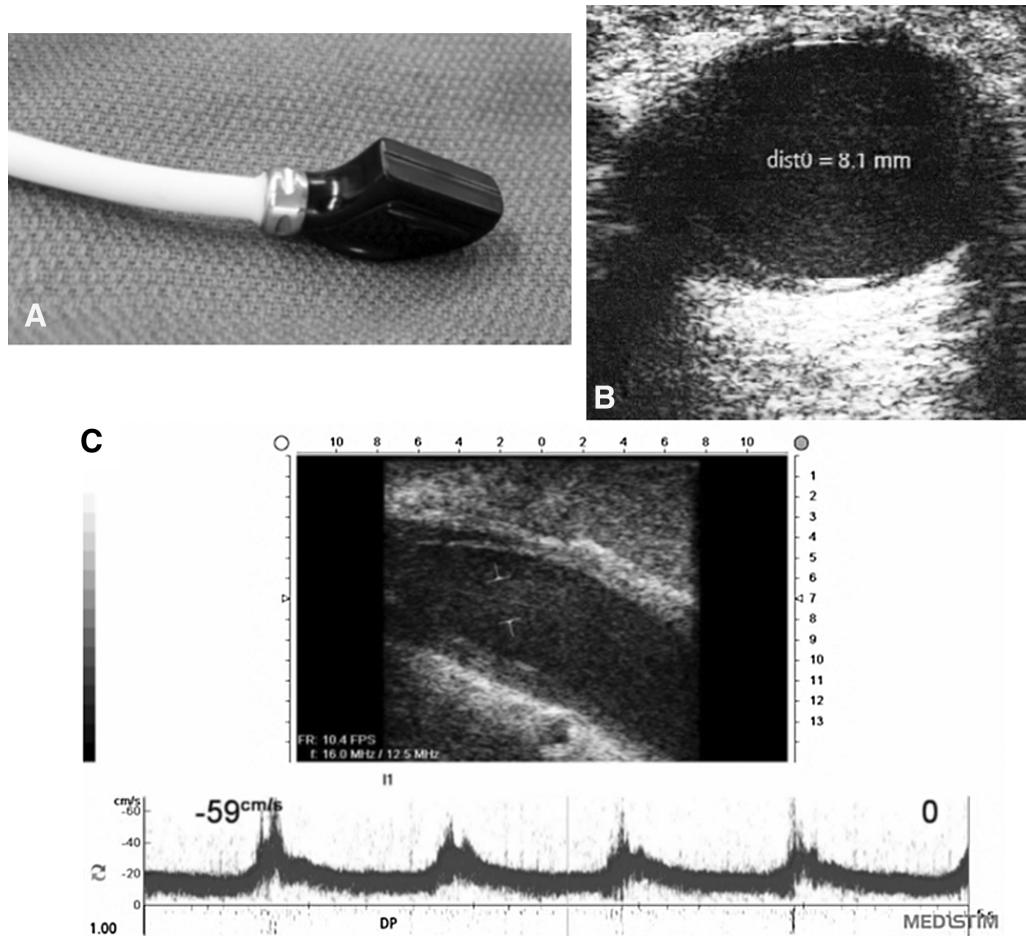
### Measurement

The mean right femoral artery diameter measured using CT was 9.92 ± 1.66 mm. The size of the arterial

**Table 1 Patients' profile**

n	22
Male:female	15:7
Age (years old)	53.7 ± 13.9
Body surface area (m <sup>2</sup> )	1.73 ± 0.21
Body mass index	22.7 ± 3.7
Obesity	2 (9.1)
Hypertension	11 (50.0)
Dyslipidemia	2 (9.1)
Diabetes mellitus	2 (9.1)
Smoking history	9 (40.9)
Peripheral artery disease	0
Atrial fibrillation	1 (4.6)
NYHA I	9 (40.9)
II	10 (45.5)
III	3 (13.6)
Left ventricular EF (%)	66.9 ± 12.4

EF: ejection fraction; NYHA: New York Heart Association functional class

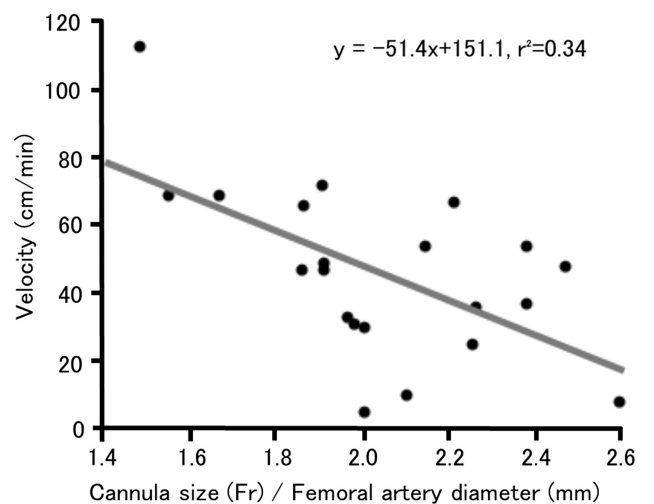


**Fig. 1** (A) A small 15-MHz ultrasonography probe used in this study. (B and C) The diameter and flow velocity were measured by ultrasonography.

cannula was 21 Fr in nine patients (40.9%), 20 Fr in five patients (22.7%), 19 Fr in five patients (22.7%), and 18 Fr in three patients (13.6%). There was no significant difference in rSO<sub>2</sub> before and after cannulation (before 69.7 ± 12.2%, after 67.1 ± 8.0%). The mean flow velocity distal to the cannulation site was 46.2 ± 25.4 cm/s, and the mean internal diameter at the same site was 6.24 ± 1.29 mm. The mean perfusion flow during the ultrasonographic assessment was 4.01 ± 0.58 L/min, and the mean arterial blood pressure was 58.3 ± 11.5 mmHg. There was a negative correlation between flow velocity and size index (size of the arterial cannula [Fr]/preoperative femoral arterial diameter measured in CT [mm]) ( $y = -51.4x + 151.1, r^2 = 0.34$ ) (**Fig. 2**).

**Cases**

In six patients, a >40% decrease from baseline rSO<sub>2</sub> was observed during cardiopulmonary bypass after femoral cannulation. In three of these cases, the rSO<sub>2</sub> decreased soon after initiation of cardiopulmonary



**Fig. 2** Results of regression analysis. There was a negative correlation between distal flow velocity and cannulation size index.

bypass. But in the other three cases, rSO<sub>2</sub> and flow velocity were normal at first. In five of these six patients, the flow velocity measured ultrasonographically was very

slow (0, 5, 8, 10 and 15 cm/s, respectively) when the  $rSO_2$  decreased. In three cases, spontaneous echo contrast was also observed (Fig. 3). Based on these findings, we diagnosed that the blood flow to the lower limb was reduced owing to arterial cannulation. In these cases,  $rSO_2$  improved rapidly after distal leg perfusion using a common 4-Fr arterial sheath. In the remaining one case, because the flow velocity was not decreased ultrasonographically, the NIRS sensor was checked and replaced, and the  $rSO_2$  subsequently improved. In another case, although there was no problems during the cardiopulmonary bypass, ultrasonography revealed stenosis at the decannulation site (Fig. 4) and the femoral artery was repaired immediately.

All operations were completed though the MICS approach. There were no hospital deaths, and ischemic complications of ipsilateral lower leg were not observed.

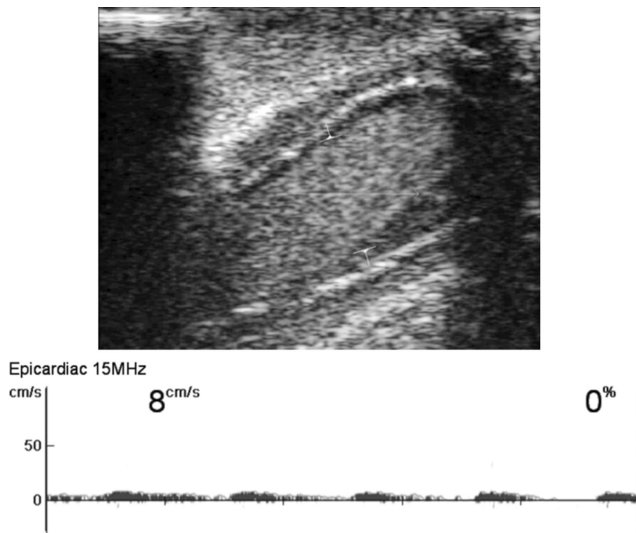


Fig. 3 Very slow flow velocity and spontaneous echo contrast.

Other complications such as seroma, dissection, bleeding, pseudoaneurysm, infection, and embolic events were not observed. Aortic dissection and cerebral infarction because of retrograde perfusion were also not observed.

## Discussion

As the femoral artery is commonly used as an arterial cannulation site in MICS, concerns about complications associated with this cannulation have increased. One of the inherent problems with femoral artery cannulation is compromised blood flow to the lower limb below the insertion site. Glower et al.<sup>6)</sup> experienced minor or major complications after femoral cannulation in up to 10% of their patients who underwent port-access MICS. However, a recent report showed acceptable complication rates, and the incidence of stroke was 1.17%, peripheral arterial trauma was 0.08%, lower extremity compartment syndrome was 0.08%, and seroma was 6.58% in MICS using femoral artery cannulation.<sup>7)</sup> Although the incidence of leg ischemia related to femoral artery cannulation in MICS has not been precisely defined, some case reports of severe ischemic complications have been reported.<sup>4,5)</sup> Decreased blood flow to the lower limb caused by cannulation of the femoral artery can lead to lower limb ischemic complications.<sup>3,4)</sup> Therefore, monitoring and/or ensuring adequate blood flow and oxygen delivery are necessary to prevent these complications. In order to establish assessment of the lower femoral artery flow using ultrasonography, it was necessary to know the standard value of the flow velocity. Thus ultrasonographic assessment was performed after cannulated and cardiopulmonary bypass were established and the flow

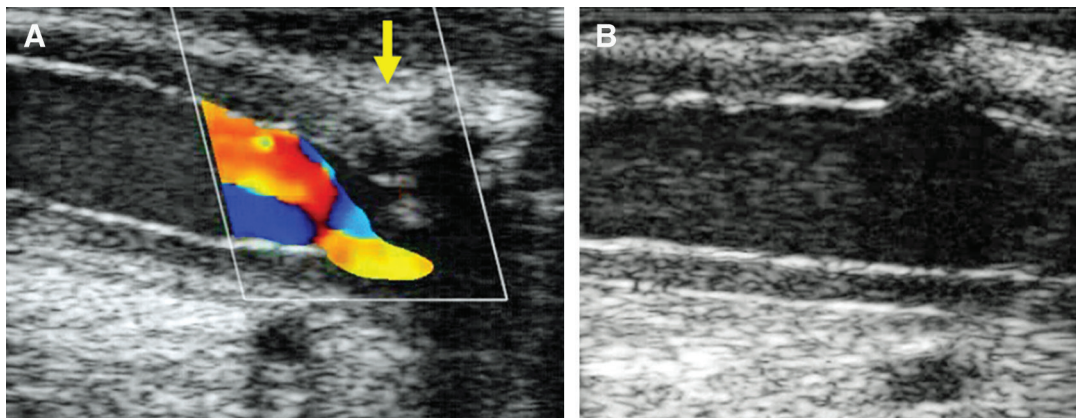


Fig. 4 (A) Ultrasonography revealed stenosis at the cannulation site after decannulation. The arrow indicates the stenosis. (B) Stenosis was not observed after the femoral artery was repaired.

velocity was recorded in the present study. We believe that using the results and findings in the present study combined with NIRS monitoring can make it easier to diagnose about lower leg blood flow and ischemia during MICS.

One of the methods used to monitor oxygenation in the lower leg is NIRS; this monitoring minimizes the risks associated with peripheral cannulation during MICS.<sup>8)</sup> Inadequate perfusion to the lower extremity can develop during femoral arterial cannulation, and may result from decreased blood flow owing to insertion of the arterial cannula, displacement of the cannula, temporary obstruction through kinking, embolic events, or arterial spasm. Using NIRS to continuously monitor blood flow, poor oxygenation due to inadequate perfusion can be treated immediately.<sup>9)</sup> We also routinely use NIRS during MICS along with the ultrasonographic assessment. Toya et al.<sup>8)</sup> reported that relative changes from the baseline value were more useful than the absolute rSO<sub>2</sub> value evaluating intraoperative lower limb ischemia in MICS. According to their report, we diagnosed the possibility of decreased blood flow to the lower leg when a >40% decrease from baseline rSO<sub>2</sub> values in the cannulated leg or in the non-cannulated opposite side value was observed. In that situation, we first assessed the blood flow using ultrasonic Doppler, because decreased flow velocity meant reducing blood flow. After other possible reasons for decreased flow were checked, lower leg perfusion was re-established through a 4-Fr common arterial sheath. In case of maintained flow velocity in Doppler, the other reason for decreased rSO<sub>2</sub> should be considered and the NIRS sensor should be checked first. Thus, because ultrasonographic assessment can directly check the flow velocity distal to the cannulation, we can easily diagnose decreased distal leg perfusion.

In addition to monitoring tissue oxygenation and blood flow, ensuring adequate distal perfusion after femoral cannulation is also important to prevent leg ischemia. Some reported methods of maintaining blood flow to the lower leg after femoral cannulation are inserting a downstream cannula,<sup>3,9,10)</sup> suturing a side graft,<sup>5,11)</sup> or using a bidirectional arterial cannula.<sup>12)</sup> Bonaros et al.<sup>9)</sup> reported that minor or major complications of leg perfusion occurred in only 1.7% with routine use of selective distal leg perfusion before placing the arterial cannula. Although distal perfusion was used to maintain adequate perfusion during cardiopulmonary bypass, lower leg ischemic complication owing to local dissection of the

ipsilateral iliac artery or vascular injury after removing the cannula was noted in previous report.<sup>9,13)</sup> Thus, ischemic complications can occur even after cannula removal. In the present study, arterial stenosis at cannulation site was also observed after cannula removal. Ultrasonography is also useful to detect such vascular complications.

Size discrepancy between the arterial cannula and the femoral artery is a suspected risk factor for lower limb ischemia.<sup>8,14)</sup> A correlation between the cannula size relative to the femoral artery diameter and distal femoral artery flow velocity was observed in the present study, but the correlation was weak. From our results, we considered there were other factors determining the blood flow below cannulation site. However, Foley et al.<sup>1)</sup> stated that body surface area, body mass index, and cannula size did not predict limb ischemia. Kawashima et al.<sup>15)</sup> reported that femoral artery anatomy was also associated with limb ischemia in MICS. The other possible factors are vasoactive reaction, spasm, distal flow demand, collateral flow, and position of the cannula. Furthermore, the measurement method might have affected our results, because we measured flow velocity but not the flow volume in the present study. Quantitative studies about the blood flow volume to the lower limb below the cannulation site are necessary to clarify the risk factor for lower leg ischemia with cannulation.

There were several limitations in this present study. First, as mentioned above, we were able to measure the diameter and flow velocity ultrasonographically, but flow volume could not be measured directly. Although it was possible to calculate flow volume from the diameter and velocity, we could easily diagnose reduced blood flow only from the flow velocity value clinically. Second, the cut-off value for low flow velocity to use for distal leg perfusion was not clarified in this study. Because flow velocity in the patients whose rSO<sub>2</sub> decreased was ≤15 cm/s, this value can be used as a reference value. To determine the exact cut-off value further investigation is necessary. Third, the diameter measured by ultrasonography was significantly smaller than the diameter measured using CT. The following possible reasons can be considered; ultrasonography might have indicated the diameter of the superficial femoral artery, or the femoral artery was shrunken because the flow was decreased after cannulation. The size of femoral artery might change depending on some conditions such as blood flow, spasm, temperature, and vasoactive agents. Because these conditions can easily change during operation, we

believe that the diameter measured using CT is more reliable than the other methods.

## Conclusion

Ultrasonographic assessment combined with NIRS monitoring is useful to prevent lower limb ischemic complications caused by cannulation of the femoral artery during MICS.

## Disclosure Statement

None of the authors had a conflict of interest concerning this study.

## References

- 1) Foley PJ, Morris RJ, Woo EY, et al. Limb ischemia during femoral cannulation for cardiopulmonary support. *J Vasc Surg* 2010; **52**: 850–3.
- 2) Bisdas T, Beutel G, Warnecke G, et al. Vascular complications in patients undergoing femoral cannulation for extracorporeal membrane oxygenation support. *Ann Thorac Surg* 2011; **92**: 626–31.
- 3) Jaski BE, McClendon PS, Branch KR, et al. Anterograde perfusion in acute limb ischemia secondary to vascular occlusive cardiopulmonary support. *Cathet Cardiovasc Diag* 1995; **35**: 373–6.
- 4) Hendrickson SC, Glower DD. A method for perfusion of the leg during cardiopulmonary bypass via femoral cannulation. *Ann Thorac Surg* 1998; **65**: 1807–8.
- 5) Satta J, Rimpiläinen J, Rainio P, et al. A feasible femoral cannulation method during cardiopulmonary bypass. *Ann Thorac Surg* 1998; **65**: 1194–5.
- 6) Glower DD, Clements FM, Debruijn NP, et al. Comparison of direct aortic and femoral cannulation for port-access cardiac operations. *Ann Thorac Surg* 1999; **68**: 1529–31.
- 7) Lamelas J, Williams RF, Mawad M, et al. Complications associated with femoral cannulation during minimally invasive cardiac surgery. *Ann Thorac Surg* 2017; **103**: 1927–32.
- 8) Toya T, Fujita T, Fukushima S, et al. Efficacy of regional saturation of oxygen monitor using near-infrared spectroscopy for lower limb ischemia during minimally invasive cardiac surgery. *J Artif Organs* 2018; **21**: 420–6.
- 9) Bonaros N, Wiedemann D, Nagiller J, et al. Distal leg protection for peripheral cannulation in minimally invasive and totally endoscopic cardiac surgery. *Heart Surg Forum* 2009; **12**: E158–62.
- 10) Madershahian N, Nagib R, Wippermann J, et al. A simple technique of distal limb perfusion during prolonged femoro-femoral cannulation. *J Card Surg* 2006; **21**: 168–9.
- 11) Vander Salm TJ. Prevention of lower extremity ischemia during cardiopulmonary bypass via femoral cannulation. *Ann Thorac Surg* 1997; **63**: 251–2.
- 12) Marasco SF, Tutungi E, Vallance SA, et al. A phase I study of a novel bidirectional perfusion cannula in patients undergoing femoral cannulation for cardiac surgery. *Innovations (Phila)* 2018; **13**: 97–103.
- 13) Muhs BE, Galloway AC, Lombino M, et al. Arterial injuries from femoral artery cannulation with port access cardiac surgery. *Vasc Endovascular Surg* 2005; **39**: 153–8.
- 14) Tarui T, Miyata K, Shigematsu S, et al. Risk factors to predict leg ischemia in patients undergoing single femoral artery cannulation in minimally invasive cardiac surgery. *Perfusion* 2018; **33**: 533–7.
- 15) Kawashima T, Okamoto K, Wada T, et al. Femoral artery anatomy is a risk factor for limb ischemia in minimally invasive cardiac surgery. *Gen Thorac Cardiovasc Surg* 2021; **69**: 246–53.