

## Falcine Myxoid Chondrosarcoma: A Rare Aggressive Case

### Abstract

Chondrosarcoma is the second most common primary malignancy of bone after osteosarcoma. Cranial primary chondrosarcomas mostly originate from the skull base cartilage formation zones. Parasagittal falcine origin is very rare for primary extra-skeletal intracranial chondrosarcomas. We report a rare case of primary myxoid chondrosarcoma at falx cerebri. The patient was a 35-year-old lady with right arm and leg weakness. Her brain magnetic resonance imaging depicted a left parasagittal mass lesion attached to the falx cerebri. En bloc resection via left frontal craniotomy was performed. Three more local recurrences occurred in 9 months' time since the index surgery, which were all managed with re-surgeries and/or adjuvant stereotactic radiosurgeries. This is the second case of myxoid type parasagittal chondrosarcoma but with the most protracted disease course. Even though surgery remains the mainstay of treatment for parasagittal chondrosarcomas, adjuvant therapy might be necessary in aggressive ones.

**Keywords:** Chondrosarcoma, falx, surgery, stereotactic radiosurgery

### Introduction

Chondrosarcoma is the second most common primary malignancy of bone.<sup>[1]</sup> The tumor evolves from cartilage tissue without any osteoid formation. Tumor characteristics are highly variable: While some chondrosarcomas are very aggressive, some others stay benign in nature. Basic determinant of the disease progress is the capacity of chondrosarcoma to metastasize, which cannot be determined with only tumor histology or tumor grade.<sup>[1]</sup>

Primary cranial chondrosarcomas mostly originate from skull base cartilage formation zones, and they compose 1% of all chondrosarcomas.<sup>[2-5]</sup> Parasagittal location for these tumors is very rare.<sup>[6]</sup> We report a rare case of primary myxoid chondrosarcoma at falx cerebri and discuss it with the current literature.

### Case Report

#### History and examination

A 35-year-old lady was admitted to the clinic with right arm and leg weakness that had started 1-week ago. She was fully alert and oriented. She had right hemiparesia (1/5). Her brain magnetic resonance imaging (MRI) depicted a left parasagittal mass lesion located at the

falx cerebri. The lesion was hyperintense on T2-weighted MRI with hypointense zones, and it had a rim-like enhancement on T1-weighted images [Figure 1a-d]. The lesion was hypointense, except a hyperintense central zone corresponding to calcification on diffusion-weighted MRI [Figure 1e].

#### Management

En bloc resection was accomplished through a left frontal craniotomy [Figure 1f]. Microscopic examination showed the characteristic features of myxoid chondrosarcoma: Multilobulated architecture separated by incomplete fibrous septae, relatively uniform oval to short spindle cells arranged in short anastomosing strands and cords embedded in the abundant myxoid matrix. Small hyperchromatic nuclei and a narrow rim of deeply eosinophilic cytoplasm reminiscent of chondroblasts characterized the individual cells. Occasionally, tumor cells had cytoplasmic vacuolization. Mitotic figures were 4/10 high-power fields. Prominent necrosis was present [Figure 2]. No infiltration into adjacent brain tissue was seen and the tumor was clearly distinct from adjacent brain tissue. Histochemically, Periodic acid-Schiff stain revealed glycogen in the cytoplasm of the tumor cells, the myxoid matrix was positive with Alcian blue stain. Immunohistochemically;

**Akın Akakin,  
Kamran Urgan<sup>1</sup>,  
Murat Şakir Ekşi<sup>2</sup>,  
Baran Yılmaz,  
Özlem Yapıcıer<sup>3</sup>,  
Mert Mestanoğlu<sup>4</sup>,  
Zafer Orkun Toktaş,  
Mustafa Kemal  
Demir<sup>5</sup>,  
Türker Kılıç**

Departments of Neurosurgery,  
<sup>3</sup>Pathology, <sup>4</sup>Medical Student  
and <sup>5</sup>Radiology, Bahçeşehir  
University Medical Faculty,  
<sup>1</sup>Department of Neurosurgery,  
Şişli Hamidiye Etfal Education  
and Research Hospital,  
Istanbul, Turkey, <sup>2</sup>Department  
of Orthopedic Surgery, Spine  
Center, University of California  
at San Francisco, San  
Francisco, California, USA

**Address for correspondence:**  
Dr. Murat Şakir Ekşi,  
Department of Orthopedic  
Surgery, University of  
California at San Francisco,  
500 Parnassus Avenue, MU 320  
West San Francisco,  
CA 94143-0728, USA.  
E-mail: muratsakireksi@gmail.  
com

#### Access this article online

**Website:** www.asianjns.org

**DOI:** 10.4103/1793-5482.181116

#### Quick Response Code:



**How to cite this article:** Akakin A, Urgan K, Ekşi MS, Yılmaz B, Yapıcıer Ö, Mestanoğlu M, *et al.* Falcine myxoid chondrosarcoma: A rare aggressive case. Asian J Neurosurg 2018;13:68-71.

This is an open access article distributed under the terms of the Creative Commons Attribution-NonCommercial-ShareAlike 3.0 License, which allows others to remix, tweak, and build upon the work non-commercially, as long as the author is credited and the new creations are licensed under the identical terms.

For reprints contact: reprints@medknow.com

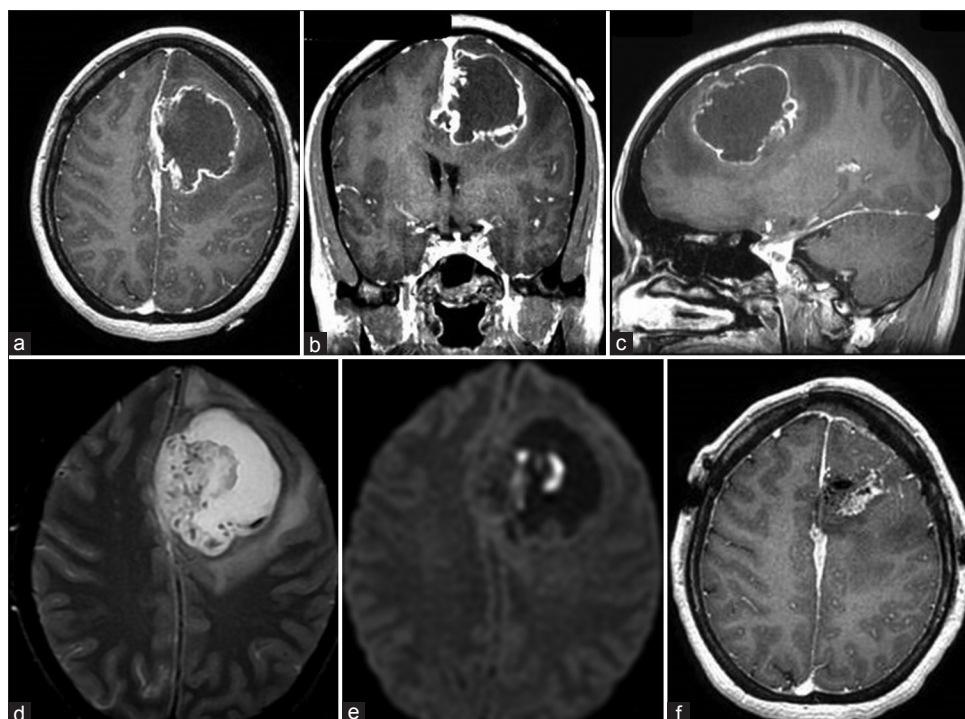


Figure 1: T1-weighted magnetic resonance images (a-c), T2-weighted magnetic resonance image (d), diffusion-weighted magnetic resonance imaging (e), postop magnetic resonance imaging (f)

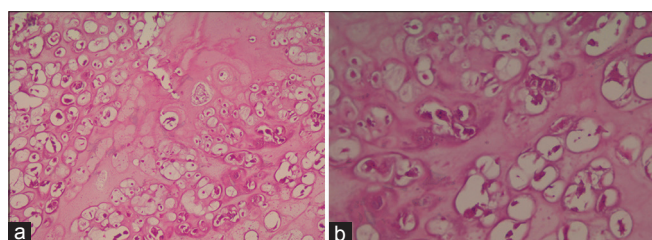


Figure 2: Microscopic photography of pathologic specimen (a) H and E,  $\times 200$ , (b) H and E,  $\times 400$

vimentin, S-100 protein, and epithelial membrane antigen were expressed in the tumor cells. Tumor cells were negative for glial fibrillary acidic protein, pan-cytokeratin, cytokeratin 5, cytokeratin 7, cytokeratin 20, chromogranin, and synaptophysin.

### Postoperative course and follow-up

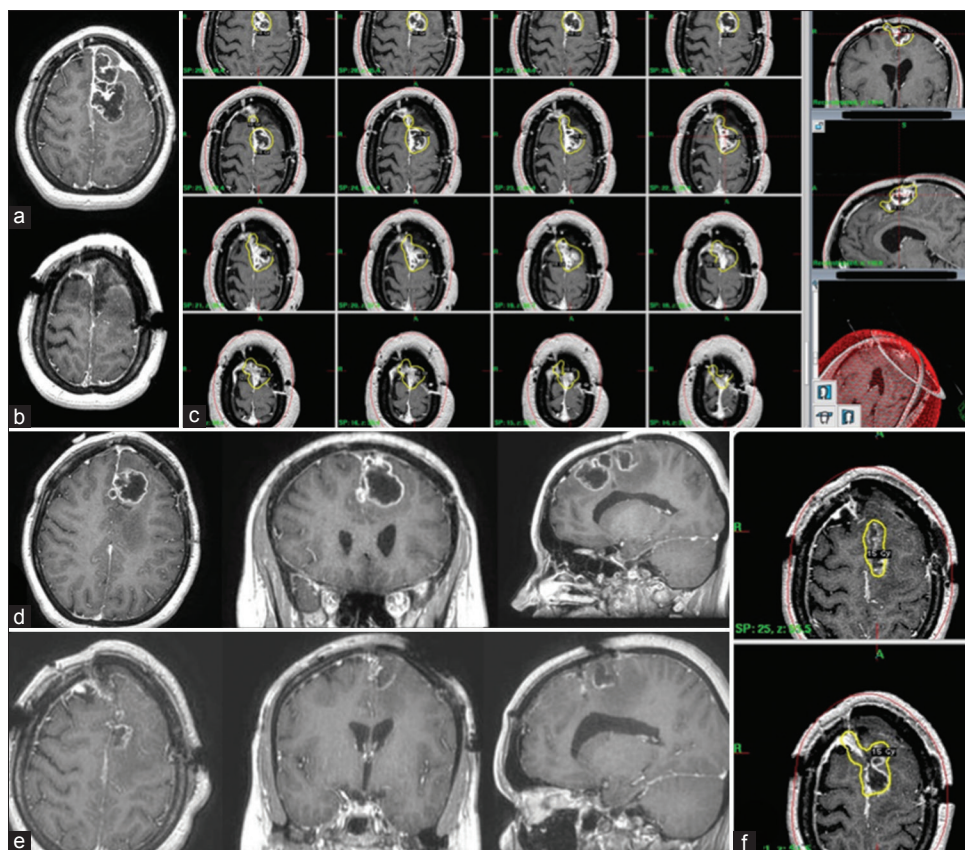
Postoperative course was uneventful. She was discharged to home 4 days later. She recovered from her right hemiparesia. She was readmitted to our clinic with a recurrent right hemiparesia 2 months postoperatively, after which a new recurrent lesion was identified on the new brain MRI [Figure 3a]. The tumor was resected through the same craniotomy side, and the pathology was compatible with the previous one [Figure 3b]. However, a second recurrence at the same locus happened 2 months after the second surgery. Stereotactic radiosurgery with Gamma-Knife (Elekta AB, Stockholm, Sweden) was conveyed at that time with a margin dose of 18 Gy (50% isodose line) [Figure 3c]. Her general status

was well until 9 months after the first surgery [Figure 3d]. However, a new local recurrence was observed with significant mass effect. A third surgery was performed and a second Gamma-Knife radiosurgery (GKR) was given to the tumor bed (15 Gy, 50% isodose line) [Figure 3e and f].

### Discussion

Primary intracranial chondrosarcomas arise mainly from skull base chondrocytes residing in synchondroses.<sup>[7]</sup> Multipotent mesenchymal progenitor cells in meninges are the other sources for chondrosarcomas arising from cerebral convexity, tentorium, and falx cerebri.<sup>[8,9]</sup> Including present case, 33 parasagittal chondrosarcoma cases have been reported in the literature.<sup>[6]</sup> Myxoid type at a parasagittal location is very rare; only one case beside the current one was presented in the literature.<sup>[10]</sup> In that case, Salcman *et al.* operated the patient and tumor recurred 8 months after the surgery. They re-operated the patient, and the patient became asymptomatic since then. In this case, the patient had 3 local recurrences for which 3 episodes of surgery and 2 episodes of stereotactic radiosurgery were conveyed. Myxoid type might actually be the most aggressive one in this location; however, there are not enough cases to make a comprehensive comparison between tumor types.

On brain computed tomography, parasagittal chondrosarcomas appear as iso- or hyperdense masses with variable enhancement patterns. Calcification pattern is in lesser amounts compared to skull base variant. These tumors



**Figure 3: Surgery for the 1<sup>st</sup> recurrence (a and b), Gamma knife radiosurgery for the 2<sup>nd</sup> recurrence (c), surgery, (d and e) and Gamma knife radiosurgery for the 3<sup>rd</sup> recurrence (f) have been accomplished**

are hypointense on T1-weighted MRI and hyperintense on T2-weighted MRI. Cartilage islands in the tumor tissue appear hypointense on T1-weighted MRI. Contrast enhancement is a honeycomb pattern with a rare occurrence of the dural-tail sign. Peritumoral edema is minimal.<sup>[11]</sup> Final diagnosis could be made by the histopathological analysis.<sup>[12-14]</sup> Myxoid type is common in soft tissues, yet rare within the cranium. There are only 2 cases of parasagittal myxoid chondrosarcoma.<sup>[11,10]</sup> Pathological representation of this type is ribbons of chondrocytes within a myxoid matrix, which has been shown in Figure 2.<sup>[11]</sup>

Primary approach for parasagittal chondrosarcomas is surgery, however, close proximity to sagittal sinus and motor cortex can be challenging. In cases with sinus invasion, a more conservative approach of surgical debulking and postoperative radiotherapy has been suggested.<sup>[6]</sup> Other reasons for adjuvant radiotherapy are tumor histology and tumor aggressiveness. In historical data, radiotherapy was mainly performed in patients with mesenchymal type. In recent years, with the development of stereotactic radiosurgery, more delicate treatment modalities could be planned with fewer side effects. Five-year overall survival rate and 2-year tumor volume change of skull base chondrosarcomas after Gamma Knife Radiosurgery (GKR) were 100% and 33.05%, respectively.<sup>[15]</sup> A margin dose of at least 14-15 Gy has

been advocated for long-term tumor control of skull base chondrosarcomas.<sup>[16,15]</sup> Despite the success of GKR in skull base chondrosarcomas, experience in parasagittal chondrosarcomas is very limited. Including the current case, there have been a total of 3 cases treated with adjuvant GKR.<sup>[6,17]</sup> A margin dose of 17.5-18 Gy was given to tumor bed in the previous cases, and we applied 18 and 15 Gy in consecutive recurrences.

## Conclusions

This is the second case of myxoid type parasagittal chondrosarcoma that had the most protracted disease course. Even though surgery remains the mainstay of treatment for parasagittal chondrosarcomas, adjuvant therapies might be necessary in aggressive types.

## Acknowledgments

Murat Şakir EKŞİ was supported by a grant from TÜBİTAK (The Scientific and Technological Research Council of Turkey), grant number: 1059B191400255.

## Financial support and sponsorship

Nil.

## Conflicts of interest

There are no conflict of interest.

## References

1. Leddy LR, Holmes RE. Chondrosarcoma of bone. *Cancer Treat Res* 2014;162:117-30.
2. Bingaman KD, Alleyne CH Jr, Olson JJ. Intracranial extraskelatal mesenchymal chondrosarcoma: Case report. *Neurosurgery* 2000;46:207-11.
3. Chow WA. Update on chondrosarcomas. *Curr Opin Oncol* 2007;19:371-6.
4. Paulus W, Scheithauer B. Mesenchymal, non-meningothelial tumours. Lyon: IARC Press; 2000.
5. Richardson MS. Pathology of skull base tumors. *Otolaryngol Clin North Am* 2001;34:1025-42, vii.
6. Safaee M, Clark AJ, Tihan T, Parsa AT, Bloch O. Falcine and parasagittal chondrosarcomas. *J Clin Neurosci* 2013;20:1232-6.
7. Korten AG, ter Berg HJ, Spincemaille GH, van der Laan RT, Van de Wel AM. Intracranial chondrosarcoma: Review of the literature and report of 15 cases. *J Neurol Neurosurg Psychiatry* 1998;65:88-92.
8. Bahr AL, Gayler BW. Cranial chondrosarcomas. Report of four cases and review of the literature. *Radiology* 1977;124:151-6.
9. Volpe NJ, Liebsch NJ, Munzenrider JE, Lessell S. Neuro-ophthalmologic findings in chordoma and chondrosarcoma of the skull base. *Am J Ophthalmol* 1993;115:97-104.
10. Salzman M, Scholtz H, Kristt D, Numaguchi Y. Extraskelatal myxoid chondrosarcoma of the falx. *Neurosurgery* 1992;31:344-8.
11. Kothary N, Law M, Cha S, Zagzag D. Conventional and perfusion MR imaging of parafalcine chondrosarcoma. *AJNR Am J Neuroradiol* 2003;24:245-8.
12. Alvira MM, McLaurin RL. Asymptomatic subdural chondrosarcoma. Case report. *J Neurosurg* 1978;48:825-8.
13. Cybulski GR, Russell EJ, D'Angelo CM, Bailey OT. Falcine chondrosarcoma: Case report and literature review. *Neurosurgery* 1985;16:412-5.
14. Forbes RB, Eljamel MS. Meningeal chondrosarcomas, a review of 31 patients. *Br J Neurosurg* 1998;12:461-4.
15. Kim JH, Jung HH, Chang JH, Chang JW, Park YG, Chang WS. Gamma Knife surgery for intracranial chordoma and chondrosarcoma: Radiosurgical perspectives and treatment outcomes. *J Neurosurg* 2014;121 Suppl: 188-97.
16. Hasegawa T, Ishii D, Kida Y, Yoshimoto M, Koike J, Iizuka H. Gamma Knife surgery for skull base chordomas and chondrosarcomas. *J Neurosurg* 2007;107:752-7.
17. Förander P, Rahn T, Kihlström L, Ulfarsson E, Mathiesen T. Combination of microsurgery and Gamma Knife surgery for the treatment of intracranial chondrosarcomas. *J Neurosurg* 2006;105 Suppl:18-25.