



Stereotactic MR-guided adaptive radiotherapy (SMART) for primary rectal cancer: evaluation of early toxicity and pathological response

Alessandra Castelluccia¹, Domenico Marchesano², Gianmarco Grimaldi², Ivan Annessi², Federico Bianciardi^{2,3}, Cristian Borrazzo², Annamaria Dipalma², Randa El Gawhary², Marica Masi², Maria Rago², Maria Valentino², Laura Verna², Maurizio Portaluri¹, PierCarlo Gentile^{2,3}

¹Radiation Oncology, Perrino Hospital, Brindisi, Italy

²Radiation Oncology, Provincia Religiosa di San Pietro Fatebenefratelli, Roma, Italy

³Radiation Oncology, UPMC Hillman Cancer Center San Pietro FBF, Rome, Italy

ABSTRACT

Background: The purpose of this study is to measure the effects of stereotactic MR-guided adaptive radiotherapy (SMART) for rectal cancer patients in terms of early toxicity and pathological response.

Materials and methods: For this prospective pilot study, patients diagnosed with locally advanced rectal cancer (LARC) with positive lymph node clinical staging underwent SMART on rectal lesion and mesorectum using hybrid MR-Linac (MRIdian ViewRay). Dose prescription at 80% isodose for the rectal lesion and mesorectum was 40 Gy (8 Gy/fr) and 25 Gy (5 Gy/fr), respectively, delivered on 5 days (3 fr/week). Response assessment by MRI was performed 3 weeks after SMART, then patients fit for surgery underwent total mesorectal excision. Primary endpoint was evaluation of adverse effect of radiotherapy. Secondary endpoint was pathological complete response rate. Early toxicity was graded according to the Common Terminology Criteria for Adverse Events (CTCAE v5.0).

Results: From October 2020 to January 2022, twenty patients underwent rectal SMART. No grade 3-5 toxicity was recorded. Twelve patients were eligible for total mesorectal excision (TME). Mean interval between the completion of SMART and surgery was 4 weeks. Pathological downstaging occurred in all patients; rate of pathological complete response (pCR) was 17%. pCR occurred with a prolonged time to surgery (> 7 weeks).

Conclusion: To our knowledge, this is the first study to use stereotactic radiotherapy for primary rectal cancer. SMART for rectal cancer is well tolerated and effective in terms of tumor regression, especially if followed by delayed surgery.

Key words: stereotactic radiotherapy; MR-guided RT; rectal cancer

Rep Pract Oncol Radiother 2023;28(4):437-444

Introduction

Short-course irradiation of locally advanced rectal cancer (LARC) as neoadjuvant treatment reduces the risk of local recurrence and showed overall survival improvement.

Advantages of short course radiotherapy (RT) for rectal cancer are huge. First of all, the short overall treatment time involves high compliance, related to the onset of toxicity generally after the end of the treatment. The small number of fractions makes it quick to administer and acceptable

Address for correspondence: Alessandra Castelluccia, Perrino Hospital, Radiation Oncology, Brindisi, Italy;
e-mail: alessandra.castelluccia@gmail.com

This article is available in open access under Creative Common Attribution-Non-Commercial-No Derivatives 4.0 International (CC BY-NC-ND 4.0) license, allowing to download articles and share them with others as long as they credit the authors and the publisher, but without permission to change them in any way or use them commercially

also to those patients with a poor performance status [1]. It is a flexible schedule that can be used with a palliative intent as well as a part of a neoadjuvant strategy.

The standard treatment of LARC typically consists of a combined-modality therapy, which includes a preoperative long-course chemoradiation of about 5 weeks followed by surgery and adjuvant chemotherapy. The overall treatment duration of approximately 1 year, a distant and local failure rate over 20% and a not-negligible high grade toxicity rate around 6–10% have, however, prompted the search for other more effective and more compliant alternative approaches [2].

In a recent phase III RAPIDO trial, short-course therapy and long-course therapy in patients with locally advanced rectal cancer showed similar efficacy. The rate of locoregional failure, the R0 resection rate and OS at 3 years were comparable in both arms. Adding sequential chemotherapy to short-course treatment, rates of distant metastasis and disease-related treatment failure were lower in the short-course therapy arm compared with the long-course therapy arm (respectively, 20.0% vs. 26.8%, $p = 0.005$; and 23.7% vs. 30.4%, $p = 0.019$) [3–5]. Short-course RT without sequential chemotherapy can be generally applied for operable rectal cancer (i.e. that with no involvement of mesorectal fascia), reducing local recurrence with acceptable toxicity [6]. This radiation treatment, used with a palliative intent, also demonstrated to successfully control rectal bleeding and pain in most cases and allowed colostomy to be avoided in majority of patients, without substantial acute toxicity [7]. Therefore, patients for a neoadjuvant program, upfront resectable or unfit for chemotherapy, and inoperable patients for a palliative intent were selected to perform SMART.

Pathological complete response (pCR) is a prognostic factor for disease-free survival [8, 9] and increased response rates have been reported with higher radiation doses [10]. Achievement of a pCR has been shown to confer a survival benefit in patients with local advanced rectal cancer and a dose-response relationship for rectal cancer has been confirmed, but escalated radiation doses must also result in reasonable toxicities without decreasing patient's quality of life.

MRI may prove a powerful tool in selective dose escalation for patients with rectal adenocarcinoma

[11]. The use of MR-hybrid technology for dose escalation neoadjuvant radiotherapy, with a good soft-tissue contrast and with the opportunity to adapt the plan to the anatomy of the day and to control target motion during delivery, could potentially lead to improved outcomes with low toxicity, increasing precision.

The purpose of this study was to analyze tolerability and response of dose-escalated short-course radiotherapy for the treatment of locally advanced rectal cancer in terms of safety and efficacy, using advanced stereotactic MR-guided adaptive radiotherapy (SMART) techniques.

Materials and methods

Patient selection

Patients newly diagnosed with histological proven primary adenocarcinoma of the rectum with positive lymph node clinical staging, resectable (cT3 with >5 mm extramural invasion and uninvolved MRF) or upfront unresectable (i.e., those with involvement of mesorectal fascia) unfit for chemotherapy or inoperable due to age and/or comorbidities were included in the study. The exclusion criteria included recurrent rectal cancer and being unfit for MRI examinations.

TNM staging

Staging of rectal cancer was carried out according to the Union for International Cancer Control/American Joint Committee of Cancer (UICC/AJCC) 8.0 [12]. The clinical stage of the neoplasm was assessed in preoperative examinations (colonoscopy, pelvic MRI and thoracic-abdominal CT) performed before radiotherapy.

Treatment modalities

Eligible patients received SMART on rectal lesion and mesorectum using hybrid MR-Linac (MRIdian ViewRay).

Treatment prescription at 80% isodose for the rectal lesion and mesorectum with clinical positive lymphnodes was 40 Gy (8 Gy/fr) and 25 Gy (5 Gy/fr), respectively, delivered on 5 days (3 fr/week). Figure 1 shows the targets' coverage from an original plan for rectal SMART. The gross target volume (GTV), the mesorectum (CTV) and the OARs were identified on a true fast imaging (TRUFI) MR scan acquired during simulation and prior to each frac-

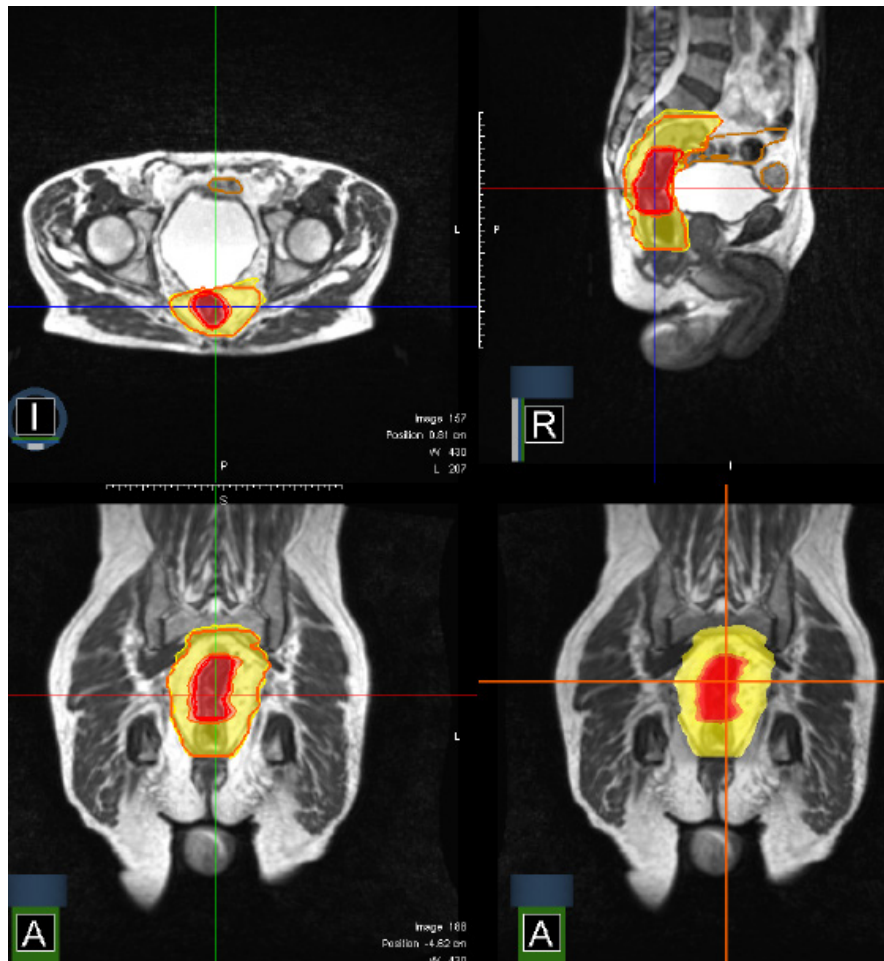


Figure 1. Original plan for rectal stereotactic MR-guided adaptive radiotherapy (SMART): mesorectum is covered by 25 Gy isodose (yellow area), gross target volume (GTV) is covered by 40 Gy isodose (red area)

tion to adapt the treatment plan of the day. An isotropic 3-mm margin was added to CTV to obtain PTV. New plans were calculated and delivered every fraction because of rectal and bowel motion. Step-and-shoot intensity-modulated radiotherapy (IMRT) using 6 MV FFF photons was used. An intrafraction motion management strategy was applied, consisting of an automated gating approach based on the real-time acquisition of a sagittal cine MRI during the whole delivery time (temporal resolution: 8 frames/s).

Response assessment

Response assessment by contrast-enhanced pelvic MRI was performed 3 weeks after SMART, then resectable patients fit for surgery underwent total mesorectal excision (TME). Radiological tumour response was evaluated for all patients, according to the MRI assessment of the Tumour Re-

gression Grade (mrTRG) system [13, 14]. The rectal tumor was removed by TME surgery or more extensive surgery if required because of tumor extent. Histopathological examination of the resected specimen was performed according to an established protocol. The evaluation of the tumour response to neoadjuvant treatment on surgical specimen was performed based on Mandard's classification of tumor regression grade (TRG). T and N downstaging was recorded when the pathological stage was lower than the clinical stage before neoadjuvant treatment. Complete pathological response (pCR) was defined as the absence of a residual tumor at the time of the histological examination of the resected specimen.

Follow up

Patients were followed up every day during radiation treatment. After SMART, patients fit for

surgery underwent a visit 15 days before and after surgery; inoperable patients were followed up at 3-monthly intervals. Toxicity was graded according to the Common Terminology Criteria for Adverse Events (CTCAE v5.0).

Primary endpoint was evaluation of adverse effect of radiotherapy. Secondary endpoint was pathological complete response rate.

Results

From October 2020 to January 2022 twenty patients underwent rectal SMART. The median age of the patients was 66 years (range 36–93). Patients (pts) baseline characteristics, clinical stage and treatment are listed in Table 1. All patients completed the radiation treatment. Median follow-up time was 12 months (range 4–21). No grade 3 or higher toxicity was recorded. No genitourinary symptoms were reported. Six patients (30%) complained of slight fatigue. Regarding gastrointestinal toxicity, the following symptoms were recorded: grade 1 rectal pain in 3 pts (15%), mild rectal hemorrhage in 1 (5%) patient, grade 1 and grade 2 proctitis in 4 (20%) and 3 (15%) pts, respectively; no enteritis occurred. Tenesmus with mild pain was the most reported acute symptom. More details about radiation-related toxicity are explained in Table 2. A moderate or good radiological response was observed: the mrTRG 1 or 2 were achieved in 9 pts (45%) and 11 pts (55%) achieved mrTRG 3; no mrTRG 4–5 was observed.

Eight patients were unfit for surgery due to age and/or comorbidities. Twelve patients were eligible for total mesorectal excision, 2 of whom had involvement of mesorectal fascia and were unfit

Table 1. Patients baseline characteristic and treatment

	N = 20	%
Gender		
Male	14	70
Female	6	30
Age (years)		
Mean	66	
Range	36-93	
Clinical stage at diagnosis		
cT3 MRF–	10	50
cT3 MRF+	9	45
cT4	1	5
cN1	5	25
cN2	15	75
cM0	16	80
cM1	4	20
Treatment		
SMART + surgery	12	60
Only SMART	8	40

SMART — stereotactic MR-guided adaptive radiotherapy

for chemotherapy. All patients were completely resected (R0). Mean interval between the completion of SMART and surgery was 4 weeks (range 3–12). A tumor and/or nodal downstaging occurred in all resected patients: out of 12 patients (pts), 17% (2 pts) were TRG 1, 33% (4 pts) were TRG 2, 33% (4 pts) were TRG 3, 17% (2 pts) were TRG 4; 92% (11 pts) were staged ypN0, one (8%) patient had a single nodal involvement on a surgical specimen. Two (17%) patients achieved complete response (pCR). The pCR occurred with a prolonged time to surgery (> 7 weeks). No postoperative complications were observed after

Table 2. Radiation-related toxicity according to Common Terminology Criteria for Adverse Events version 5th (CTCAE v.5)

Toxicity type	Grade 1	Grade 2	Grade 3	Grade 4	Grade 5
Gastrointestinal (n. pts)					
Proctitis	4 (20%)	3 (15%)	–	–	–
Rectal pain	3 (15%)	–	–	–	–
Rectal hemorrhage	1 (5%)	–	–	–	–
Enterocolitis	–	–	–	–	–
Genitourinary (n. pts)					
Dysuria	–	–	–	–	–
General disorders (n. pts)					
Fatigue	6 (30%)	–	–	–	–

Table 3. Pathological stage and response

	N = 12	%
Time to surgery (weeks)		
Mean	4	
Range	3-12	
Pathological stage		
ypT0	2	17
ypT1	2	17
ypT2	4	33
ypT3	4	33
ypN0	11	92
ypN1	1	8
Pathological response (sec. Mandard)		
TRG 1	2	17
TRG 2	4	33
TRG 3	4	33
TRG 4	2	17
TRG 5	0	0

SMART. Patients' pathological stage and response are listed in Table 3.

Discussion

Short course radiation therapy may represent a safe and effective treatment option to manage patients with rectal cancer not amenable for curative treatment as well as patients capable of receiving a neoadjuvant treatment.

Pathologic complete tumor response after chemoradiation in patients with locally advanced rectal cancer is associated with a favorable prognosis. Multiple factors have been postulated to be correlated with the degree of response, such as association of chemotherapy, time to surgery and radiation dose escalation. Studies confirmed that higher radiation doses are associated with a higher probability of pathologic tumor regression [15, 16]. Furthermore, pCR rates and long-term survival are linked in a dose-dependent manner and there seems to be a trend toward increased pCR rates and disease-free survival with increasing dose [17–19]. In addition, a previous meta-analysis showed that patients undergoing chemoradiation with doses over 60 Gy had increased pCR rates [20]. A total dose of 60 Gy using standard fractionation is equivalent to 40 Gy using extreme fractionation ($BED_{10} = 72$ Gy). Therefore, in this

study a dose of 8 Gy per fraction in 5 fractions was prescribed to treat rectal lesions.

In our study TME was planned to be performed at least 3 weeks after the end of SMART. Indeed, delaying surgery after short-course RT entailed similar oncological with lower postoperative complications, compared to short-course RT with early surgery in the interim report of the Stockholm III study [21]. Surgery performed between 10 and 21 days after the start of RT has also been reported to lead to increased toxicity due to an impaired leukocyte response after surgery [22]. With a median follow-up of 12 months (range 4–21), no postoperative complications were observed after SMART.

In Stockholm III trial [21], in the groups with a delay to surgery, about 6% of patients developed grade 3–4 radiation-induced toxicity. A recent meta-analysis about neoadjuvant radiotherapy dose escalation for LARC using innovative radiotherapy techniques found a rate of grade 3 or higher toxicity near 11% [19]. In our study, tenesmus with mild pain was the most reported acute symptom. It's noteworthy that symptoms were mostly pre-existing before treatment. Furthermore, as other authors reported [7], patients not undergoing surgery experienced a gradual symptom improvement, as during follow up they reported a reduction of pain, bleeding and/or mass effect signaled prior to treatment. Despite higher dose delivered, no high-grade toxicity (grade 3–5) and no genitourinary toxicity was recorded after SMART. It could be related to the accuracy of real time adaptive treatment strategies. Peculiar benefits of the use of MR-Linac are on-line daily optimization of the plan to manage tumor motion, automated gating to control organ motion in addition to optimal soft-tissue contrast to identify and treat lesions using high RT doses precisely. Because of rectal lesions' inter-fractional movement, as shown in Figure 2, and inter-fractional motion (i.e., when air passes through the rectum), daily adaptation of the plan and automated gating during delivery are essential for a safe dose-escalation.

Studies observed pCR after chemoradiation in 10–27% of patients, with clusters of studies reporting rates closer to 10% [23–26]. In the latest RAPIDO trial, the rate of pathologic complete response was higher in the short-course arm (28.4% vs. 14.3%; $p < 0.001$). This study found a pCR rate of 17%. It occurred when time to surgery was ex-

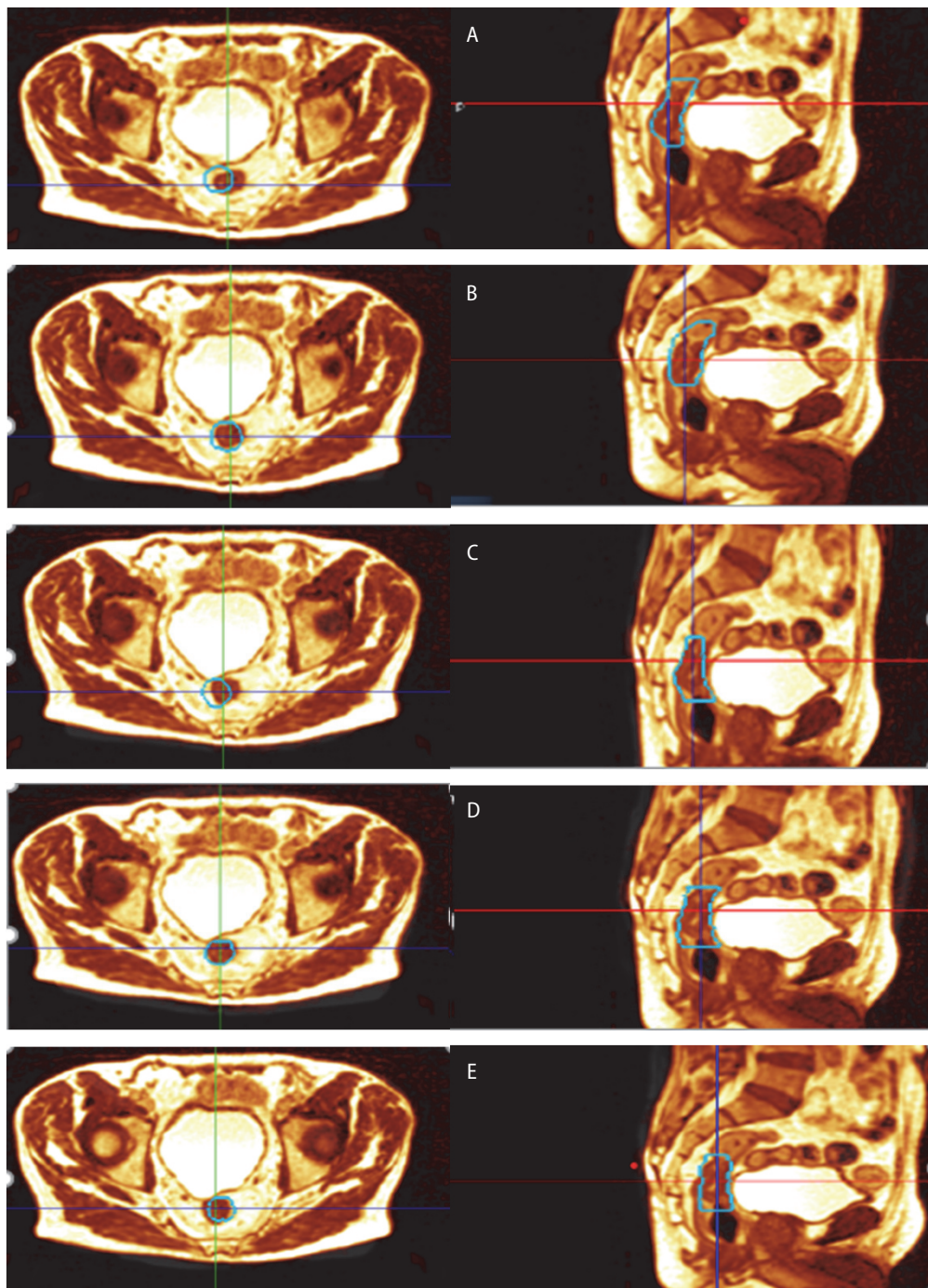


Figure 2. Inter-fractional motion of GTV : the rectal lesion (in cyan lines) assumes different positions from simulation MR for each fraction (a , b , c , d , e are fractions from first to fifth, respectively)

tended beyond 7 weeks for non-clinical reasons. This result is in line with literature [27]. Veenhof et al. found a pCR rate of 12% with short-course RT followed by TME after 45 days, then 4 days. Short-term morbidity was comparable for both groups. However, significantly higher numbers of complete remissions (12 vs. 0%) and tumor down-

staging (55 vs. 26%) were found when surgery was delayed [28].

SMART, using high doses per fraction, led to tumor and nodal radiological or pathological downstaging in all patients included in this study, probably related to higher BED. Interestingly, all patients had a clinical positive lymph node stag-

ing and all patients but 1 has a pathological nodal complete response. It can be related to a sort of bystander effect [29]. Further studies are required to demonstrate this hypothesis.

Adding subsequent chemotherapy after SMART and planning time-to-surgery longer than 6 weeks for all patients could improve these results. Larger studies with a longer follow-up are needed.

Conclusions

To our knowledge, this is the first study to use stereotactic radiotherapy for primary rectal cancer. SMART for rectal cancer is well tolerated and could help achieve a complete pathological response in selected patients, especially if followed by delayed surgery. Further study about the association of SMART with chemotherapy are warranted.

Conflict of interest

None declared.

Funding

None declared.

References

- Glynn-Jones R, Tan D, Moran B, et al. How to Select for Preoperative Short-course Radiotherapy, While Considering Long-course Chemoradiotherapy or Immediate Surgery, and Who Benefits? *Eur Oncol Haematol*. 2014; 10(01): 17, doi: [10.17925/eoh.2014.10.1.17](https://doi.org/10.17925/eoh.2014.10.1.17).
- Bujko K, Wyrwicz L, Rutkowski A, et al. Polish Colorectal Study Group. Long-course oxaliplatin-based preoperative chemoradiation versus 5 × 5 Gy and consolidation chemotherapy for cT4 or fixed cT3 rectal cancer: results of a randomized phase III study. *Ann Oncol*. 2016; 27(5): 834–842, doi: [10.1093/annonc/mdw062](https://doi.org/10.1093/annonc/mdw062), indexed in Pubmed: [26884592](https://pubmed.ncbi.nlm.nih.gov/26884592/).
- Nilsson PJ, van Etten B, Hospers GAP, et al. Short-course radiotherapy followed by neo-adjuvant chemotherapy in locally advanced rectal cancer—the RAPIDO trial. *BMC Cancer*. 2013; 13: 279, doi: [10.1186/1471-2407-13-279](https://doi.org/10.1186/1471-2407-13-279), indexed in Pubmed: [23742033](https://pubmed.ncbi.nlm.nih.gov/23742033/).
- Valk Mv, Marijnen C, Etten Bv, et al. Compliance and tolerability of short-course radiotherapy followed by preoperative chemotherapy and surgery for high-risk rectal cancer — Results of the international randomized RAPIDO-trial. *Radiother Oncol*. 2020; 147: 75–83, doi: [10.1016/j.radonc.2020.03.011](https://doi.org/10.1016/j.radonc.2020.03.011), indexed in Pubmed: [32240909](https://pubmed.ncbi.nlm.nih.gov/32240909/).
- Hospers G, Bahadoer R, Dijkstra E, et al. Short-course radiotherapy followed by chemotherapy before TME in locally advanced rectal cancer: The randomized RAPIDO trial. *J Clin Oncol*. 2020; 38(15_suppl): 4006–4006, doi: [10.1200/jco.2020.38.15_suppl.4006](https://doi.org/10.1200/jco.2020.38.15_suppl.4006).
- Ciria JP, Eguiguren M, Cañero S, et al. Could preoperative short-course radiotherapy be the treatment of choice for localized advanced rectal carcinoma? *Rep Pract Oncol Radiother*. 2015; 20(1): 1–11, doi: [10.1016/j.rpor.2014.06.003](https://doi.org/10.1016/j.rpor.2014.06.003), indexed in Pubmed: [25535578](https://pubmed.ncbi.nlm.nih.gov/25535578/).
- Picardi V, Deodato F, Guido A, et al. Palliative Short-Course Radiation Therapy in Rectal Cancer: A Phase 2 Study. *Int J Radiat Oncol Biol Phys*. 2016; 95(4): 1184–1190, doi: [10.1016/j.ijrobp.2016.03.010](https://doi.org/10.1016/j.ijrobp.2016.03.010), indexed in Pubmed: [27215449](https://pubmed.ncbi.nlm.nih.gov/27215449/).
- Lee YC, Hsieh CC, Chuang JP. Prognostic significance of partial tumor regression after preoperative chemoradiotherapy for rectal cancer: a meta-analysis. *Dis Colon Rectum*. 2013; 56(9): 1093–1101, doi: [10.1097/DCR.0b013e318298e36b](https://doi.org/10.1097/DCR.0b013e318298e36b), indexed in Pubmed: [23929020](https://pubmed.ncbi.nlm.nih.gov/23929020/).
- Maas M, Nelemans PJ, Valentini V, et al. Long-term outcome in patients with a pathological complete response after chemoradiation for rectal cancer: a pooled analysis of individual patient data. *Lancet Oncol*. 2010; 11(9): 835–844, doi: [10.1016/S1470-2045\(10\)70172-8](https://doi.org/10.1016/S1470-2045(10)70172-8), indexed in Pubmed: [20692872](https://pubmed.ncbi.nlm.nih.gov/20692872/).
- Gunther JR, Chadha AS, Shin Uis, et al. Preoperative radiation dose escalation for rectal cancer using a concomitant boost strategy improves tumor downstaging without increasing toxicity: A matched-pair analysis. *Adv Radiat Oncol*. 2017; 2(3): 455–464, doi: [10.1016/j.adro.2017.04.001](https://doi.org/10.1016/j.adro.2017.04.001), indexed in Pubmed: [29114614](https://pubmed.ncbi.nlm.nih.gov/29114614/).
- Van Wickle JD, Paulson ES, Landry JC, et al. Adaptive radiation dose escalation in rectal adenocarcinoma: a review. *J Gastrointest Oncol*. 2017; 8(5): 902–914, doi: [10.21037/jgo.2017.07.06](https://doi.org/10.21037/jgo.2017.07.06), indexed in Pubmed: [29184696](https://pubmed.ncbi.nlm.nih.gov/29184696/).
- Amin MB, Edge S, Greene F, Byrd DR, Brookland RK, Washington MK, Gershenwald JE, Compton CC, Hess KR. (eds.). *AJCC Cancer Staging Manual*. 8th ed. Springer International Publishing, American Joint Commission on Cancer 2017.
- Patel U, Blomqvist L, Taylor F, et al. MRI After Treatment of Locally Advanced Rectal Cancer: How to Report Tumor Response — The MERCURY Experience. *AJR Am J Roentgenol*. 2012; 199(4): W486–W495, doi: [10.2214/ajr.11.8210](https://doi.org/10.2214/ajr.11.8210), indexed in Pubmed: [22997398](https://pubmed.ncbi.nlm.nih.gov/22997398/).
- Patel U, Taylor F, Blomqvist L, et al. Magnetic Resonance Imaging–Detected Tumor Response for Locally Advanced Rectal Cancer Predicts Survival Outcomes: MERCURY Experience. *J Clin Oncol*. 2011; 29(28): 3753–3760, doi: [10.1200/jco.2011.34.9068](https://doi.org/10.1200/jco.2011.34.9068), indexed in Pubmed: [21876084](https://pubmed.ncbi.nlm.nih.gov/21876084/).
- Appelt AL, Pløen J, Vogeliuss IR, et al. Radiation dose-response model for locally advanced rectal cancer after preoperative chemoradiation therapy. *Int J Radiat Oncol Biol Phys*. 2013; 85(1): 74–80, doi: [10.1016/j.ijrobp.2012.05.017](https://doi.org/10.1016/j.ijrobp.2012.05.017), indexed in Pubmed: [22763027](https://pubmed.ncbi.nlm.nih.gov/22763027/).
- Van Wickle JD, Paulson ES, Landry JC, et al. Adaptive radiation dose escalation in rectal adenocarcinoma: a review. *J Gastrointest Oncol*. 2017; 8(5): 902–914, doi: [10.21037/jgo.2017.07.06](https://doi.org/10.21037/jgo.2017.07.06), indexed in Pubmed: [29184696](https://pubmed.ncbi.nlm.nih.gov/29184696/).
- Chan AK, Wong AO, Langevin J, et al. “Sandwich” preoperative and postoperative combined chemotherapy and radiation in tethered and fixed rectal cancer: impact of treatment intensity on local control and survival. *Int J Radiat Oncol Biol Phys*. 1997; 37(3): 629–637, doi: [10.1016/s0360-3016\(96\)00603-7](https://doi.org/10.1016/s0360-3016(96)00603-7), indexed in Pubmed: [9112462](https://pubmed.ncbi.nlm.nih.gov/9112462/).
- Hearn N, Atwell D, Cahill K, et al. Neoadjuvant Radiotherapy Dose Escalation in Locally Advanced Rectal Cancer:

- a Systematic Review and Meta-analysis of Modern Treatment Approaches and Outcomes. *Clin Oncol (R Coll Radiol)*. 2021; 33(1): e1–e14, doi: [10.1016/j.clon.2020.06.008](https://doi.org/10.1016/j.clon.2020.06.008), indexed in Pubmed: [32669228](https://pubmed.ncbi.nlm.nih.gov/32669228/).
19. Delishaj D, Fumagalli IC, Ursino S, et al. Neoadjuvant radiotherapy dose escalation for locally advanced rectal cancers in the new era of radiotherapy: A review of literature. *World J Clin Cases*. 2021; 9(30): 9077–9089, doi: [10.12998/wjcc.v9.i30.9077](https://doi.org/10.12998/wjcc.v9.i30.9077), indexed in Pubmed: [34786390](https://pubmed.ncbi.nlm.nih.gov/34786390/).
 20. Burbach JP, den Harder AM, Intven M, et al. Impact of radiotherapy boost on pathological complete response in patients with locally advanced rectal cancer: a systematic review and meta-analysis. *Radiother Oncol*. 2014; 113(1): 1–9, doi: [10.1016/j.radonc.2014.08.035](https://doi.org/10.1016/j.radonc.2014.08.035), indexed in Pubmed: [25281582](https://pubmed.ncbi.nlm.nih.gov/25281582/).
 21. Erlandsson J, Holm T, Pettersson D, et al. Optimal fractionation of preoperative radiotherapy and timing to surgery for rectal cancer (Stockholm III): a multicentre, randomised, non-blinded, phase 3, non-inferiority trial. *Lancet Oncol*. 2017; 18(3): 336–346, doi: [10.1016/S1473-0455\(17\)30086-4](https://doi.org/10.1016/S1473-0455(17)30086-4), indexed in Pubmed: [28190762](https://pubmed.ncbi.nlm.nih.gov/28190762/).
 22. Hartley A, Giridharan S, Srihari N, et al. Impaired postoperative neutrophil leucocytosis and acute complications following short course preoperative radiotherapy for operable rectal cancer. *Eur J Surg Oncol*. 2003; 29(2): 155–157, doi: [10.1053/ejso.2002.1364](https://doi.org/10.1053/ejso.2002.1364), indexed in Pubmed: [12633558](https://pubmed.ncbi.nlm.nih.gov/12633558/).
 23. Hiotis SP, Weber SM, Cohen AM, et al. Assessing the predictive value of clinical complete response to neoadjuvant therapy for rectal cancer: an analysis of 488 patients. *J Am Coll Surg*. 2002; 194(2): 131–5; discussion 135, doi: [10.1016/s1072-7515\(01\)01159-0](https://doi.org/10.1016/s1072-7515(01)01159-0), indexed in Pubmed: [11848629](https://pubmed.ncbi.nlm.nih.gov/11848629/).
 24. Maas M, Beets-Tan RGH, Lambregts DMJ, et al. Wait-and-see policy for clinical complete responders after chemoradiation for rectal cancer. *J Clin Oncol*. 2011; 29(35): 4633–4640, doi: [10.1200/JCO.2011.37.7176](https://doi.org/10.1200/JCO.2011.37.7176), indexed in Pubmed: [22067400](https://pubmed.ncbi.nlm.nih.gov/22067400/).
 25. Nyasavajjala SM, Shaw AG, Khan AQ, et al. Neoadjuvant chemo-radiotherapy and rectal cancer: can the UK watch and wait with Brazil? *Colorectal Dis*. 2010; 12(1): 33–36, doi: [10.1111/j.1463-1318.2009.02054.x](https://doi.org/10.1111/j.1463-1318.2009.02054.x), indexed in Pubmed: [19832875](https://pubmed.ncbi.nlm.nih.gov/19832875/).
 26. Seong J, Cho JH, Kim NK, et al. Preoperative chemoradiotherapy with oral doxifluridine plus low-dose oral leucovorin in unresectable primary rectal cancer. *Int J Radiat Oncol Biol Phys*. 2001; 50(2): 435–439, doi: [10.1016/s0360-3016\(00\)01585-6](https://doi.org/10.1016/s0360-3016(00)01585-6), indexed in Pubmed: [11380231](https://pubmed.ncbi.nlm.nih.gov/11380231/).
 27. Pach R, Kulig J, Richter P, et al. Randomized clinical trial on preoperative radiotherapy 25 Gy in rectal cancer—treatment results at 5-year follow-up. *Langenbecks Arch Surg*. 2012; 397(5): 801–807, doi: [10.1007/s00423-011-0890-8](https://doi.org/10.1007/s00423-011-0890-8), indexed in Pubmed: [22170083](https://pubmed.ncbi.nlm.nih.gov/22170083/).
 28. Veenhof AA, Kropman RHJ, Engel AF, et al. Preoperative radiation therapy for locally advanced rectal cancer: a comparison between two different time intervals to surgery. *Int J Colorectal Dis*. 2007; 22(5): 507–513, doi: [10.1007/s00384-006-0195-5](https://doi.org/10.1007/s00384-006-0195-5), indexed in Pubmed: [17009009](https://pubmed.ncbi.nlm.nih.gov/17009009/).
 29. Shemetun O, Pilinska M. Radiation-induced bystander effect — modeling, manifestation, mechanism, persistence, cancer risk (literature review). *Probl Radiat Med Radiobiol*. 2019; 24: 65–92, doi: [10.33145/2304-8336-2019-24-65-92](https://doi.org/10.33145/2304-8336-2019-24-65-92).