

This is an Open Access article licensed under the terms of the Creative Commons Attribution-NonCommercial 3.0 Unported license (CC BY-NC) ([www.karger.com/OA-license](http://www.karger.com/OA-license)), applicable to the online version of the article only. Distribution permitted for non-commercial purposes only.

# Keratitis with *Kocuria palustris* and *Rothia mucilaginosa* in Vitamin A Deficiency

R.M. Mattern · Jiayi Ding

Department of Ophthalmology, Ross Eye Institute, State University of New York at Buffalo, Buffalo, N.Y., USA

## Key Words

*Kocuria palustris* · *Rothia mucilaginosa* · Peripheral ulcerative keratitis · Vitamin A deficiency

## Abstract

**Purpose:** To present a case of unusual corneal infection early in the course of peripheral ulcerative keratitis in a patient with severe vitamin A deficiency. **Method:** Single observational case report in urban USA. **Case Presentation:** An alcoholic patient with pancreatitis, chronic diarrhea, and vitamin A deficiency presented with a marginal corneal ulcer from which two bacteria of the family Micrococcaceae were cultured and identified by genome sequence analysis, namely *Kocuria palustris* and *Rothia mucilaginosa*. Soon after, severe bilateral peripheral ulcerative keratitis developed, later accompanied by eyelid cellulitis of one lid. These conditions improved with antibiotics, treatment of the underlying gastrointestinal conditions, and treatment of the vitamin deficiency. **Conclusion:** Susceptibility to keratitis with unusual bacteria of the Micrococcaceae family can occur in the setting of alcoholism-related gastrointestinal disease with severe vitamin A deficiency. To our knowledge, *K. palustris* is a species not previously identified in any human disease, and the *Kocuria* genus has not previously been reported as a participant in eye infection. Documented cases of *R. mucilaginosa* in ocular disease are rare. These unusual infections heralded the onset of severe marginal corneal melts.

© 2014 S. Karger AG, Basel

## Introduction

Vitamin A deficiency with corneal involvement is common in parts of the world where malnutrition is widespread, but is limited in the developed world to cases of poor dietary intake, malabsorption, or other rare conditions [1, 2]. Ulcerative keratitis has been reported

R.M. Mattern, MD, PhD  
Department of Ophthalmology, Ross Eye Institute  
State University of New York at Buffalo  
1176 Main Street, Buffalo, NY 14209 (USA)  
E-Mail SUNYABeye@gmail.com

in several prior cases of alcoholic pancreatitis with vitamin A deficiency in the developed world [3–5]. Patients with alcoholism are susceptible to vitamin A deficiency both because of erratic eating habits and because alcoholism predisposes to gastrointestinal disease that impedes absorption and utilization of vitamin A.

### Case Presentation

A 58-year-old African-American female presented to a hospital emergency room with a superotemporal marginal corneal ulcer of the left eye two clock hours in length, with mild corneal thinning. Uncorrected visual acuity on the initial exam was 20/30 in the right eye and 20/50 in the left. Both eyes showed diffuse punctate corneal epitheliopathy in the palpebral fissure. Her past medical history included alcohol use since the age of 14, serious alcoholism since the age of 34, and chronic pancreatitis and diarrhea since the age of 52. She reported that she drank 6–12 beers per day. She had a smoking history of >50 pack-years as well as a history of gastrointestinal bleed, liver cirrhosis, cholecystectomy, chronic obstructive pulmonary disease, and anaphylactic reaction to peanuts. She had lived in urban USA since birth.

After corneal culture, the patient was started on hourly topical moxifloxacin 0.5% eyedrops in the left eye as well as artificial tears in both eyes. Culture was positive for alpha-hemolytic streptococcus and catalase-positive Gram-positive cocci in groups with preliminary identification as coagulase-negative *Staphylococcus*. She returned 3 days later, with an unchanged exam except for mild injection of the right eye, and was maintained on the same antibiotic drops but with an increase in artificial tears in the right eye. Three days after that (6 days after the initial visit), she presented to an outpatient office with bilateral marginal corneal ulcers (fig. 1, fig. 2, fig. 3), both with a thinning >50% and parallel to the limbus. The left eye also had a small hypopyon. Uncorrected visual acuity was 20/40 right, 20/80 left. She did not complete workup or treatment and was lost to follow up for over 1 week. She returned to the emergency room 17 days after initial presentation, with a complaint of bilateral severe vision decrease and painful swelling of the left lower lid of 2 days duration. She was hospitalized at that point.

On admission, vision was hand motions in both eyes. The right eye had deep marginal thinning for 6 clock hours inferiorly. The left cornea had a marginal area of deep stromal thinning temporally for 5 clock hours, and the inferior lid showed tender erythema and edema. Diffuse severe bilateral corneal edema and hypopyon (1.5 mm in the right eye and 1.0 mm in the left eye) were present. B-scan ultrasound of the fundus of both eyes was unremarkable.

After corneal culture, the patient was placed on bilateral topical ocular application of fortified vancomycin eyedrops (25 mg/ml) every hour (for Gram-positive coverage) and moxifloxacin 0.5% eyedrops every hour (for Gram-negative coverage). Cultures from admission grew *Pseudomonas aeruginosa* and *Staphylococcus hominis* from the right eye and *Staphylococcus warneri* and *Staphylococcus lugdunensis* from the left eye. On the third day of hospitalization, when culture results were available, the eyedrops were changed to fortified vancomycin every 2 h and fortified tobramycin (14 mg/ml) every 2 h. Tobramycin was started because of its potency against *Pseudomonas*. The presence of three *Staphylococcus* species in the cultures warranted continuation of the vancomycin eyedrops, but we decreased the frequency to every 2 h around the clock to reduce epithelial toxicity and patient stress. The left lower lid cellulitis did not yield any material for culture, but the patient received IV cefazolin (1 g every 8 h) for 2 weeks with resolution of the cellulitis. Due

to the severe corneal ulceration, bilateral amniotic membrane grafts (AmbioDisk; IOP Ophthalmics, Costa Mesa, Calif., USA) with an overlying 16.0-mm Kontur bandage contact lens (Kontur Contacts, Hercules, Calif., USA) were placed on the fourth day of hospitalization. A urinary tract infection found during hospitalization was culture-positive for vancomycin-resistant *Enterococcus* and was treated with linezolid.

Testing revealed a marked vitamin A deficiency, with a level of 0 µg/dl (reference range 18–77). Vitamin A analysis was performed by LabCorp using high performance liquid chromatography. The patient had mild protein malnutrition with total protein 6.5 g/dl (reference range 6.6–8.7). Her BMI was 21.4 (normal range 18.5–25). Laboratory analysis showed hypokalemia, hyponatremia, hypomagnesemia, and hypocalcemia. Testing ruled out HIV, tuberculosis, syphilis, sarcoidosis, rheumatoid arthritis, hepatitis A, B, C, and Wegener granulomatosis. The ANA titer was elevated (40) with a fine speckled pattern, but not to the level of significance (80). Sjogren syndrome testing for SS-A/Ro, SS-B/La, Smith antibody, and ribonucleoprotein antibodies were all negative by microparticle multiple immunoassay. Erythrocyte sedimentation rate and C-reactive protein were normal.

Intramuscular vitamin A was not available, so it was repleted with 100,000 IU orally for 3 days, followed by 50,000 IU orally every day for 2 weeks. After initial treatment of the infections and after ruling out systemic tuberculosis, systemic steroids were given (IV methylprednisone starting at 50 mg daily and tapered over 2 weeks). The patient also received thiamine, folate, ascorbate, calcium, vitamin D, multivitamins, topical cyclosporine 0.05% eyedrops, and intensive eye lubrication. The patient's diarrhea, pancreatic enzyme deficiencies, electrolyte abnormalities, and protein malnutrition were treated, and she received extensive nutritional and alcoholism counseling.

## Results

With treatment, the corneal infiltrate, hypopyon, and diffuse corneal edema all resolved, along with the lower lid cellulitis. The marginal guttering in both corneas filled in and epithelialized, though with some residual thinning and vascularization. Uncorrected visual acuity improved to 20/40 in the right eye and 20/80 in the left.

Repeat vitamin A level was ordered after the patient finished treatment of the vitamin deficiency, but the patient did not comply with testing. She was followed for a total of 10 weeks from the initial emergency room visit, but was then lost to further follow-up in the clinic. She was intermittently in contact with the ophthalmology service, however, and admitted that she had resumed heavy alcohol use despite a stay in rehab. At the last contact, 13 months after initial presentation, she reported that her vision was good and that she had no eye complaints.

From the culture of the left eye cornea on initial emergency room presentation, the catalase-positive Gram-positive cocci forming white colonies were further identified by API Staph Identification Panel (Biomerieux) as *Kocuria/Rothia* (Biocode Profile 6510154). The colonies were sent to the New York State Department of Health (Wadsworth Center, Albany, N.Y., USA), where bacterial gene sequence analysis was performed. The 16S rRNA gene sequence identified *Kocuria palustris* and *Rothia mucilaginosa*. Homology >99% using multiple gene databases is the criterion for gene sequence identification in this laboratory.

## Discussion

Initial infectious keratitis of the left eye involved two unusual bacteria of the family Micrococcaceae: *K. palustris* and *R. mucilaginosa*. *K. palustris*, a bacterial species first isolated from a cattail in a tributary of the Danube River in Hungary in 1999 [6], is an organism subsequently found to occur in rice [7], soil [8], and marine sponges [9]. To our knowledge, *K. palustris* has not previously been reported in any human disease process.

Some bacteria in the *Kocuria* genus other than *K. palustris* have been reported as occasional pathogens, usually in patients with immunosuppression or indwelling foreign bodies [10]. To our knowledge, no member of the *Kocuria* genus has previously been reported in eye infection, however.

*R. mucilaginosa*, previously called *Stomatococcus mucilaginosus*, is part of the normal flora of the upper respiratory tract and oral cavity. This organism has been reported in a prior case of eye infection, a postoperative endophthalmitis in a 91-year-old male [11]. In this case, the identification of *R. mucilaginosa* was made only by biochemical characteristics of the organism in the culture.

A growing body of case reports since 1978 implicates *R. mucilaginosa* in a variety of infections (including endocarditis, pneumonia, arthritis, and central nervous system disease), usually in patients who are immunocompromised or have an indwelling foreign body [12–15]. In the present case, the infection with *R. mucilaginosa* may also fit the pattern of infection in patients with compromised host defenses, as our patient experienced infections at four different sites within a short time period. The underlying vitamin A deficiency may have contributed to a weakening of host defenses and allowed for corneal infection with unusual organisms.

The patient's eyes were first examined when the ulcer in the left eye was superficial and the ulcer in the right eye had not yet developed. Just a few days later, severe bilateral, deep, peripheral corneal ulceration was observed. Isolating the two micrococcal organisms very early in the course of vitamin A deficiency-related peripheral ulcerative keratitis, this case points to the need for further study of the role bacteria of the family Micrococcaceae might play in corneal ulceration.

The present case study expands the known clinical spectrum of the genus *Kocuria* to include the eye, which is a novel presentation. It also presents what may be the first documented case of *K. palustris* in human disease. This case report provides another example of eye involvement of *R. mucilaginosa*, rarely reported in that setting. This case highlights the importance of including vitamin A deficiency in the differential diagnosis of keratitis patients with gastrointestinal disease and alcoholic patients with dry eye keratopathy. Prompt culturing of corneal ulcers in such cases may reveal unexpected infections, which can be a harbinger of further infections and serious corneal melts.

## Acknowledgments

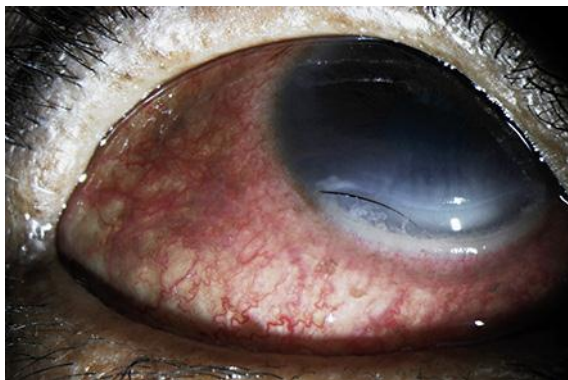This work was supported in part by an unrestricted grant from Research to Prevent Blindness (RPB). We acknowledge the helpful assistance of the staff of the Microbiology Laboratory of Erie County Medical Center. We are also grateful for the contribution of the microbiology laboratory staff of the New York State Department of Health, Wadsworth Center.

## Disclosure Statement

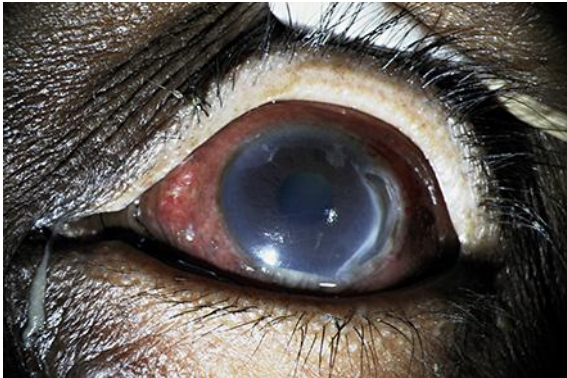
The authors declare that they have no competing interests.

## References

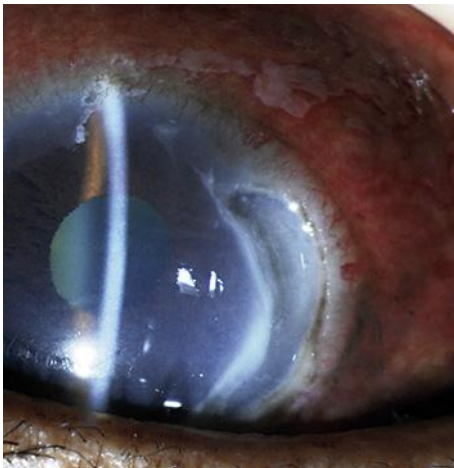- 1 Donaldson KE, Fishler J: Corneal ulceration in a LASIK patient due to vitamin a deficiency after bariatric surgery. *Cornea* 2012;31:1497–1499.
- 2 Lange AP, Moloney G, Sheldon CA, Sasaki S, Holland SP: Bilateral corneal ulceration caused by vitamin A deficiency in eosinophilic gastroenteropathy. *Case Rep Ophthalmol* 2011;2:302–306.
- 3 Macsai MS, Agarwal S, Gamponia E: Bilateral corneal ulcers in primary vitamin A deficiency. *Cornea* 1998;17:227–229.
- 4 Benitez Cruz S, Gomez Candela C, Ruiz Martin M, Cos Blanco AI: Bilateral corneal ulceration as a result of caloric-protein malnutrition and vitamin A deficit in a patient with chronic alcoholism, chronic pancreatitis and cholecystectomy (in Spanish). *Nutr Hosp* 2005;20:308–310.
- 5 Suan EP, Bedrossian EH Jr, Eagle RC Jr, Laibson PR: Corneal perforation in patients with vitamin A deficiency in the United States. *Arch Ophthalmol* 1990;108:350–353.
- 6 Kovacs G, Burghardt J, Pradella S, Schumann P, Stackebrandt E, Marialigeti K: *Kocuria palustris* sp. nov., and *Kocuria rhizophila* sp. nov., isolated from the rhizoplane of the narrow-leaved cattail (*Typha angustifolia*). *Int J Syst Bacteriol* 1999;49:167–173.
- 7 Kaga H, Mano H, Tanaka F, Watanabe A, Kaneko S, Morisaki H: Rice seeds as sources of endophytic bacteria. *Microbes Environ* 2009;24:154–62.
- 8 Caliz J, Vila X, Marti F, Sierra J, Nordgren J, Lindgren PE, Baneras L, Montserrat G: The microbiota of an unpolluted calcareous soil faces up chlorophenols: evidence of resistant strains with potential for bioremediation. *Chemosphere*, 2011;83:104–116.
- 9 Martin J, da S Sousa T, Crespo G, Palomo S, Gonzalez T, Tormo JR, de la Cruz M, Anderson M, Hill RT, Vincente F, Genilloud O, Reyes F: Kocurin, the true structure of PM181104, an anti-methicillin-resistant *Staphylococcus aureus* (MRSA) thiazoyl peptide from the marine-derived bacterium *Kocuria palustris*. *Mar Drugs* 2013;11:387–398.
- 10 Becker K, Rutsch F, Uekoetter A, Kipp F, Koenig J, Marquardt T, Peters G, von Eiff C: *Kocuria rhizophila* adds to the emerging spectrum of micrococcal diseases involved in human infections. *J Clin Microbiol* 2008;46:3537–3539.
- 11 Tan R, White V, Servais G, Bryce EA: Postoperative endophthalmitis caused by *Stomatococcus mucilaginosus*. *Clin Infect Dis* 1994;18:492–493.
- 12 Rubin SJ, Lyons RW, Murcia AJ: Endocarditis associated with cardiac catheterization due to a Gram-positive coccus designated *Micrococcus mucilaginosus incertae sedis*. *J Clin Microbiol* 1978;7:546–549.
- 13 Fusconi M, Conti C, De Virgilio A, De Vincentiis M: Paucisymptomatic pneumonia due to *Rothia mucilaginosa*: case report and literature review (in Italian). *Infez Med* 2009;17:100–104.
- 14 Kaasch AJ, Saxler G, Seifer H: Septic arthritis due to *Rothia mucilaginosa*. *Infection* 2011;39:81–82.
- 15 Goldman M, Chaudhary UB, Greiss A, Fausel CA: Central nervous system infection due to *Stomatococcus mucilaginosus* in immunocompromised hosts. *Clin Infect Dis* 1998;27:1241–1246.



**Fig. 1.** Right eye, 6 days after initial presentation. Three days before this photograph, the eye was examined and no ulceration was found.



**Fig. 2.** Left eye, 6 days after initial presentation. This photograph shows the hypopyon and expanded area of the temporal marginal ulceration, which was limited to the superotemporal cornea on initial presentation.



**Fig. 3.** Left eye, 6 days after initial presentation. Initially an ulcer with minimal thinning, the marginal guttering has deepened considerably.