

RESEARCH ARTICLE

Using Skin Markers for Spinal Curvature Quantification in Main Thoracic Adolescent Idiopathic Scoliosis: An Explorative Radiographic Study

Stefan Schmid^{1,2*}, Daniel Studer³, Carol-Claudius Hasler³, Jacqueline Romkes⁴, William R. Taylor¹, Reinald Brunner^{3,4}, Silvio Lorenzetti¹

1 ETH Zurich, Institute for Biomechanics, Zurich, Switzerland, **2** Bern University of Applied Sciences, Health Division, Bern, Switzerland, **3** University of Basel Children's Hospital, Orthopaedic Department, Basel, Switzerland, **4** University of Basel Children's Hospital, Laboratory for Movement Analysis, Basel, Switzerland

* stefanschmid79@gmail.com



OPEN ACCESS

Citation: Schmid S, Studer D, Hasler C-C, Romkes J, Taylor WR, Brunner R, et al. (2015) Using Skin Markers for Spinal Curvature Quantification in Main Thoracic Adolescent Idiopathic Scoliosis: An Explorative Radiographic Study. *PLoS ONE* 10(8): e0135689. doi:10.1371/journal.pone.0135689

Editor: Han-Chiao Isaac Chen, University of Pennsylvania, UNITED STATES

Received: January 30, 2015

Accepted: July 26, 2015

Published: August 13, 2015

Copyright: © 2015 Schmid et al. This is an open access article distributed under the terms of the [Creative Commons Attribution License](https://creativecommons.org/licenses/by/4.0/), which permits unrestricted use, distribution, and reproduction in any medium, provided the original author and source are credited.

Data Availability Statement: All relevant data are within the paper.

Funding: SS was supported by the Health Division at Bern University of Applied Sciences, Switzerland and the Swiss Physiotherapy Association (physioswiss). The funders had no role in study design, data collection and analysis, decision to publish, or preparation of the manuscript.

Competing Interests: The authors have declared that no competing interests exist.

Abstract

Background and Purpose

Although the relevance of understanding spinal kinematics during functional activities in patients with complex spinal deformities is undisputed among researchers and clinicians, evidence using skin marker-based motion capture systems is still limited to a handful of studies, mostly conducted on healthy subjects and using non-validated marker configurations. The current study therefore aimed to explore the validity of a previously developed enhanced trunk marker set for the static measurement of spinal curvature angles in patients with main thoracic adolescent idiopathic scoliosis. In addition, the impact of inaccurate marker placement on curvature angle calculation was investigated.

Methods

Ten patients (Cobb angle: 44.4±17.7 degrees) were equipped with radio-opaque markers on selected spinous processes and underwent a standard biplanar radiographic examination. Subsequently, radio-opaque markers were replaced with retro-reflective markers and the patients were measured statically using a Vicon motion capture system. Thoracolumbar / lumbar and thoracic curvature angles in the sagittal and frontal planes were calculated based on the centers of area of the vertebral bodies and radio-opaque markers as well as the three-dimensional position of the retro-reflective markers. To investigate curvature angle estimation accuracy, linear regression analyses among the respective parameters were used. The impact of inaccurate marker placement was explored using linear regression analyses among the radio-opaque marker- and spinous process-derived curvature angles.

Results and Discussion

The results demonstrate that curvature angles in the sagittal plane can be measured with reasonable accuracy, whereas in the frontal plane, angles were systematically underestimated, mainly due to the positional and structural deformities of the scoliotic vertebrae. Inaccuracy of marker placement had a greater impact on thoracolumbar / lumbar than thoracic curvature angles. It is suggested that spinal curvature measurements are included in marker-based clinical gait analysis protocols in order to enable a deeper understanding of the biomechanical behavior of the healthy and pathological spine in dynamic situations as well as to comprehensively evaluate treatment effects.

Introduction

Upper-body kinematics during daily activities such as walking are known to be important for movement control [1]. A comprehensive assessment of gait function including within-trunk and spinal movements can therefore be beneficial in specific patient groups. However, evidence of spinal movement during gait, measured using skin marker-based motion capture systems is still limited to a handful of studies, of which the majority was conducted on healthy subjects and without an appropriate evaluation of the spinal curvature [2–12]. Standard trunk marker sets used in clinical gait analysis such as the “Plug-in Gait full body marker set” [13, 14] do not allow the tracking of spinal curvature and are hence not suitable for the quantification of abnormal spinal movement in patients with complex spinal deformities such as adolescent idiopathic scoliosis (AIS) or pathologies that affect spinal movement in the context of passive or active secondary deviations [15].

For these reasons, an enhanced trunk marker set (IfB marker set) was introduced and validated for the assessment of sagittal lumbar and thoracic curvature in healthy adults [16]. Although the validity was reported as low for the measurement of absolute spinal curvature angles, the marker set appeared to be suitable for the reliable assessment of change in sagittal lumbar and thoracic curvature.

An important aspect to consider in AIS is that the spinal deformity is always three-dimensional with the basic components being intervertebral lordosis (sagittal plane), lateral inclination (frontal plane) and axial rotation (transverse plane), i.e. the vertebral bodies rotate toward the convex side and the spinous processes toward the concave side [17, 18]. In addition, AIS patients were shown to have a distinct asymmetrical intravertebral deformity with its maximum being in the apical region of the curve [19]. Taking these factors into consideration, it is reasonable to assume that a superficial tracking of the spinal curvature with markers placed on the spinous processes will underestimate the curvature formed by the vertebral bodies in the frontal plane. Evidence for this assumption was provided by Herzenberg et al. [20], who radiographically demonstrated that the angle derived from the spinous processes significantly underestimated the Cobb-angle. However, it is plausible that this underestimation of curvature is systematic throughout normal functional activities, thereby still allowing the tracking of spinal movement and the dynamic assessment of changes in curvature.

In addition to the malrotation of vertebral bodies, inaccurate marker placement might also contribute to an under- or overestimation of the spinal curvature. Studies showed that the rate of accurately locating the spinous processes by palpation was somewhere between 45% and 83% with a mean distance of inaccurate identification either above or below the targeted level

of 19.3 ± 18.6 mm [21–24]. This suggests that the correct identification of the spinous processes is difficult. In addition, all of the mentioned studies have only quantified the accuracy of spinous process identification in the vertical axis. No evidence is available that describes the accuracy of spinous process identification in the horizontal axis, i.e. lateral displacement from the designated location, which is crucial for understanding scoliosis, particularly in dynamic situations.

Using biplanar radiography and marker-based motion capture techniques, the primary aim of the current study was to explore the static validity of skin marker-based measurements of sagittal and frontal plane spinal curvature angles in a group of patients with AIS. In a secondary aim, the accuracy of spinous process identification by palpation and the impact of inaccurate marker placement on curvature angle measurements in the frontal plane were addressed.

Methods

Ethics statement

This study was approved by the local ethics committee (Ethikkommission Nordwest- und Zentralschweiz (EKNZ), Ref.-No.: 33/13). All patients as well as their legal guardians provided written informed consent to participate in this study.

Subjects

A consecutive sample of ten patients with AIS participated in the current study (Table 1). All participants were scheduled for a routine radiographic examination and were therefore not exposed to additional radiation. Inclusion criteria were an age between 10 and 18 years and the diagnosis of an idiopathic scoliosis with a structural (major) main thoracic curve (types 1–3 according to the Lenke classification [25]), whereas exclusion criteria included any other types of scoliosis (e.g. of neurological origin), previous surgical treatments or injuries to the locomotor system which led to persistent deformities in the lower extremities and the trunk.

Instrumentation

Standard biplanar radiographic examinations (posterior-anterior and lateral images) of the entire spine while standing were performed, including spherical radio-opaque markers (diameter: 5 mm) that were attached to the skin in a configuration described below. Measurements in the motion analysis laboratory were carried out using standard retro-reflective markers (diameter: 9–14 mm) and a 12-camera motion capture system (Vicon, Oxford, UK) at a sampling rate of 300 Hz.

Selected markers from a previously developed trunk marker set (IfB marker set) [26], placed on the spinous processes of C7, T3, T5, T7, T9, T11 as well as L1–L5, were considered.

Procedures

Spinous processes of interest were located and marked by an experienced physiotherapist using a skin-compatible pen and with the patient in an upright seated position. First, the spinous process of C7 was located using two different methods: palpation of the two most prominent cervical spinous processes and identification of C7 by 1) flexion and assisted extension of the cervical spine (spinous process that remained stationary) [24, 27, 28] and 2) flexion and assisted rotation of the head (greater movement of spinous processes of C6 and C7 than T1) [29]. In a second step, spinous processes were counted down until L5 was identified. Finally, locations were confirmed when the spinous process of L4 corresponded to the level of the imaginary line between the two iliac crests [21, 28] and all identified spinous processes still

Table 1. Subject demographics and marker selection for the estimation of the curvature angles in the frontal plane.

Subject	Gender	Age [years]	Height [m]	Mass [kg]	Lenke type	Sagittal Curvature [degrees]		Thoracolumbar/Lumbar Frontal Curvature		Thoracic Frontal Curvature					
						Cobb Angle		Convex.	Cobb Angle [degrees]	Convex.	Cobb Angle [degrees]	Selected Markers			
						Lumbar	Thoracic						Lumbar	Thoracic	Lumbar
1	female	12	1.57	38.5	1	45.1	22.1	left	9.2	T12-L4	T11-L4	right	14.0	T6-T11	T5-T11
2	female	14	1.60	50.8	1	59.1	18.9	left	31.0	T12-L4	T11-L4	right	39.9	T5-T12	T5-T11
3	female	16	1.64	58.8	1	65.1	2.9	left	38.5	T12-L4	T11-L4	right	51.1	T6-T12	T5-T11
4	female	14	1.65	55.5	1	33.5	0.4	left	42.2	T12-L4	T11-L4	right	66.9	T6-T12	T5-T11
5	female	16	1.70	53.0	3	82.6	21.1	left	55.6	T10-L3	T9-L3	right	70.9	T4-T9	T3-T9
6	male	16	1.71	58.4	1	36.9	16.9	left	41.1	L1-L5	L1-L5	right	58.1	T8-L1	T7-L1
7	female	15	1.60	57.3	3	33.6	34.3	left	35.2	T11-L3	T11-L3	right	39.5	T7-T11	T5-T11
8	female	15	1.65	54.4	1	48.1	18.9	right	49.0	T8-L2	T7-L2	left	29.6	T2-T7	C7-T7
9	female	14	1.52	40.9	3	33.0	12.9	left	39.2	L1-L4	L1-L4	right	43.5	T6-T12	T5-T11
10	male	16	1.84	85.5	1	36.0	26.2	right	28.0	T8-T12	T5-T11	left	30.9	T2-T7	C7-T7
8 female		14.8	1.65	55.3		47.3	17.5	2 right	36.9±12.6			8 right	44.4±17.7		
2 male		±1.3	±0.1	±12.7		±16.8	±10.1	8 left				2 left			

The bottom row contains counts and means ± standard deviations.

doi:10.1371/journal.pone.0135689.t001

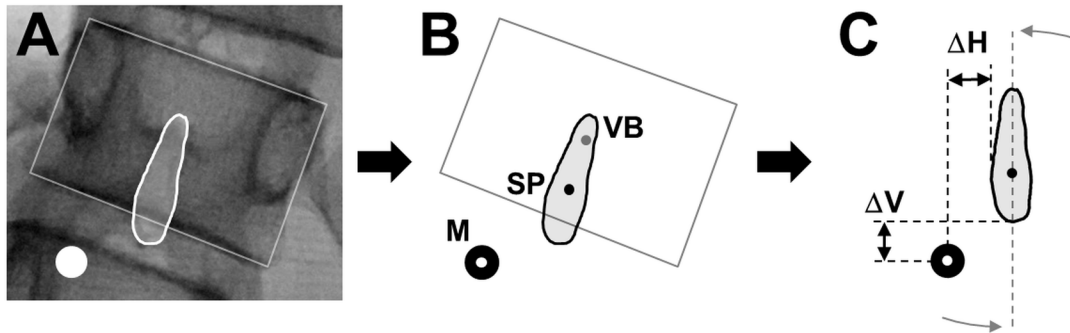


Fig 1. Illustration of the data extraction procedures from the posterior-anterior radiographic images. A) Identification of the shapes of the marker, vertebral body and spinous process, B) calculation of the centers of area (CoA) of the marker (M), vertebral body (VB) and spinous process (SP) and C) calculation of the horizontal (ΔH) and vertical (ΔV) distance between the marker's CoA and the spinous process boundaries.

doi:10.1371/journal.pone.0135689.g001

corresponded to the respective spinal levels in a standing position. Subsequently, radio-opaque markers were placed directly onto the skin and the participants underwent the radiographic examination. After the examination, the radio-opaque markers were replaced with retro-reflective markers and the participants underwent an upright standing static measurement for the period of 2 seconds in the motion analysis laboratory.

Data analysis/reduction

Radiographic images were processed using the software ImageJ (version 1.47, U. S. National Institutes of Health, Bethesda, MD, USA). Cobb-angles were determined as described in the literature [30]. The centers of area (CoA) of the vertebral bodies and the markers in both planes as well as the spinous processes in the frontal plane were calculated based on their manually identified shapes (Fig 1A and 1B). Possible errors resulting from the geometry of a diverging x-ray beam were not corrected because of too many unknown variables. The positions of the retro-reflective markers in the sagittal and frontal planes were extracted as the mean values during the 2 seconds static trial using the software Nexus (version 1.8.5, Vicon, OMG, Oxford, UK). All subsequent calculations were carried out using a custom-built MATLAB routine (R2013b, MathWorks Inc., Natick, MA, USA).

Curvature angle calculation in the sagittal and frontal planes was based on the radiographic (vertebral bodies and radio-opaque markers) and motion capture data (retro-reflective markers). In the sagittal plane, the lumbar curve was defined by the vertebral bodies T12-L5 and the markers placed on T11, L1-L5, while the thoracic curve was defined by the vertebral bodies T3-T12 and the markers placed on T3, T5, T7, T9 and T11. In the frontal plane, thoracolumbar / lumbar and thoracic curves were defined by the vertebral bodies and markers that corresponded to the Cobb-angle boundaries (Table 1), with a minimum of four markers selected for each curve. Circular segments were then established using the combination of a second order polynomial and a circle fit function (Taubin method [31]) and curvature angles were calculated based on the central angle theorem.

The accuracy of marker placement by palpation was evaluated on the basis of the posterior-anterior radiographic images (spinous processes and radio-opaque markers). Due to the laterally deviated spine, the calculated CoA's of the spinous processes and the markers were vertically aligned according to the tilt angle of the longitudinal axis of the respective spinous process (Fig 1C). Vertical accuracy was then determined by measuring the absolute distances (in mm) from a marker's CoA to the upper and lower boundaries of the respective spinous

process and horizontal accuracy by the absolute distances (in mm) from a marker's CoA to the lateral boundaries of the spinous process. If a marker's CoA fell between the upper and lower and/or lateral boundaries, the spinous process was considered as correctly identified in the respective direction.

Statistical analyses

Statistical calculations were performed using the software package SPSS 21 (SPSS Inc., Chicago, IL, USA) and statistical significance was set at $p = 0.05$.

Primary outcomes: To determine the validity of skin marker-based curvature angle measurements, linear regression analyses among the parameters vertebral body (VB)-, radio-opaque marker (RO)- and retro-reflective marker (RR)-derived curvature angles were carried out.

Secondary outcomes: The accuracy of marker placement by palpation was analyzed descriptively and expressed as numbers and percentages. In addition, absolute displacement values of the markers that were not correctly identified were presented. To explore the impact of inaccurate marker placement on curvature angle measurements in the frontal plane, linear regression analyses among the parameters spinous process (SP)-, RO- and RR-derived curvature angles were carried out with higher correlations indicating a smaller impact and lower correlations a greater impact.

Results

Primary outcomes: Statistically significant moderate to strong correlations between the VB- and RO- as well as RR-derived curvature angles were found for the sagittal as well as frontal curves (Fig 2). Considering the attributes of the fitted regression lines, the VB-derived curvature angles of the sagittal lumbar and thoracic spines showed no substantial over- or underestimation by the RO and RR markers with slope-values ranging from 0.913 to 1.252 and y-intercept-values of below 10 degrees. In the frontal plane, however, VB-derived curvature angles were systematically underestimated when derived from the markers with slope-values between 0.882 and 1.308 and y-intercept-values of 20.4 to 34.4 degrees. The qualitative consideration of the spread of the sagittal curvature angles in the lumbar spine indicated a more accurate estimation of values less than 40 degrees. In addition, frontal thoracic curvature angles showed a slightly increased underestimation by the RR- compared to the RO-derived values.

Secondary outcomes: Six of the 110 radio-opaque markers were not visible on the radiographs and could therefore not be included in the evaluation. A total of 57.7% of the spinous processes were palpated correctly in the vertical and 38.4% in the horizontal direction (Table 2). Mean displacement values indicated palpatory inaccuracies between 5–18 mm in the vertical and up to 9 mm in the horizontal direction. Spinous processes were generally identified below the designated locations and towards the concave sides of the curves. Regression analyses between the SP- and skin marker-derived curvature angles in the frontal plane showed higher correlations for the thoracic than the thoracolumbar / lumbar spine (Fig 3). In addition, the attributes of the fitted regression lines for the thoracolumbar / lumbar curve indicated a tendency for underestimation of the SP-derived curvature angles, whereas for the thoracic curve, no substantial under- or overestimation could be found.

Discussion

The current study aimed at validating skin marker-based measurements of spinal curvature angles in the sagittal and frontal planes in patients with main thoracic AIS. In addition, the

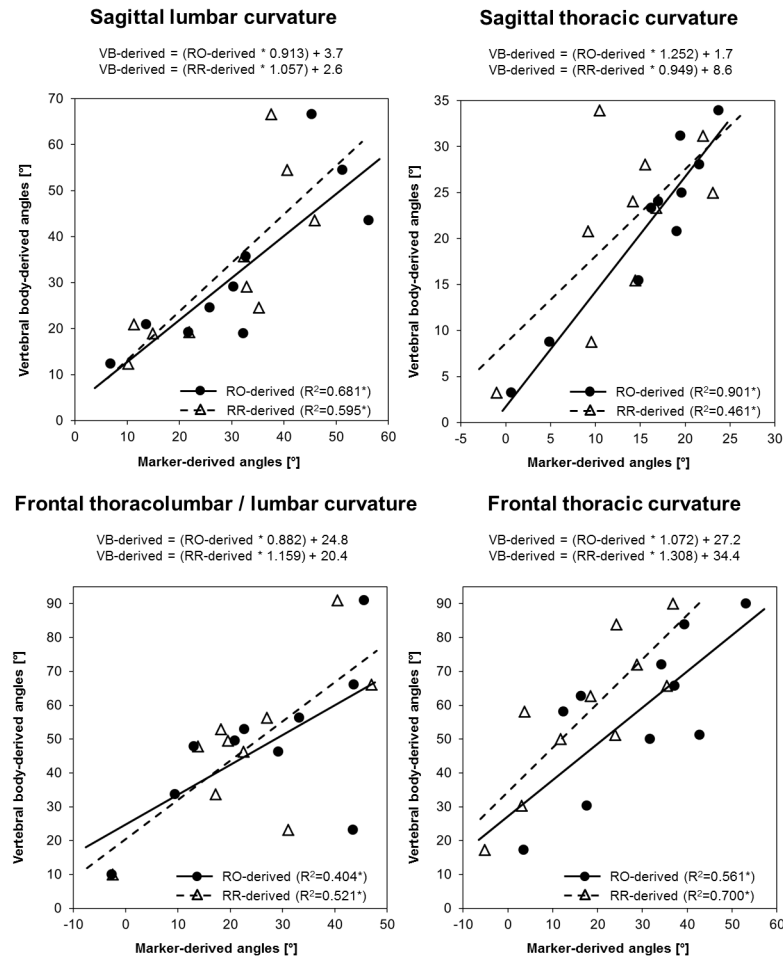


Fig 2. Scatterplots and regression equations illustrating curvature angle estimation accuracy. VB: vertebral body-derived curvature angles; RO: radio-opaque marker-derived curvature angles; RR: retro-reflective marker-derived curvature angles. The asterisks (*) indicate statistical significance at the level $p \leq 0.05$.

doi:10.1371/journal.pone.0135689.g002

accuracy of marker placement by spinous process palpation and the impact of inaccurate placement on spinal curvature angle measurements were addressed.

In the sagittal plane, lumbar and thoracic curvature angles could be estimated with a reasonable accuracy by both the RO- and RR-markers, whereas in the frontal plane, thoracolumbar / lumbar and thoracic curvature angles were systematically underestimated by the skin markers. About half of the spinous processes were not identified correctly by palpation in the vertical and another half in the horizontal direction, but with fairly low displacement values. Inaccurate placement of markers appeared to have a greater impact on curvature angle estimation in the thoracolumbar / lumbar than the thoracic spine. While the consequence of these results for assessing the kinematics of the spine during dynamic activities remains to be elucidated in further studies, these data suggest that it might be possible to perform a systematic correction of the marker data or to focus on movement patterns (relative angular differences) in order to provide clinical understanding to dynamic data.

Table 2. Accuracy of spinous process identification by palpation.

Region	Marker	Vert. +Horiz. correct		Only vert. displaced		Only horiz. displaced		Vert. +Horiz. displaced		Missing marker	Displacement* [mm]			
		N	%	N	%	N	%	N	%		Vertical		Horizontal	
											Mean	SD	Mean	SD
Cervical	C7	0	0.0	5	100.0	0	0.0	0	0.0	5				
	T3	2	22.2	0	0.0	5	55.6	2	22.2	1	5.8	1.2	-1.6	0.8
Thoracic	T5	3	30.0	2	20.0	3	30.0	2	20.0	0	-6.3	8.1	-3.4	2.3
	T7	0	0.0	2	20.0	6	60.0	2	20.0	0	-6.3	14.1	-8.8	7.2
	T9	0	0.0	1	10.0	6	60.0	3	30.0	0	-7.2	4.7	-4.7	4.7
	T11	1	10.0	2	20.0	4	40.0	3	30.0	0	-17.4	14.2	3.1	2.3
	T3-T11	6	12.2	7	14.3	24	49.0	12	24.5	1	-6.3	8.2	-3.1	4.4
	L1	2	20.0	1	10.0	5	50.0	2	20.0	0	-13.3	13.2	0.5	0.2
Lumbar	L2	2	20.0	1	10.0	4	40.0	3	30.0	0	-11.9	8.8	2.5	1.2
	L3	5	50.0	2	20.0	1	10.0	2	20.0	0	-8.6	3.5	0.6	0.4
	L4	3	30.0	2	20.0	3	30.0	2	20.0	0	-7.3	1.7	1.3	1.0
	L5	2	20.0	2	20.0	3	30.0	3	30.0	0	-11.8	2.1	-0.4	1.7
	L1-L5	14	28.0	8	16.0	16	32.0	12	24.0	0	-10.6	2.5	0.9	1.1
All	C7-L5	20	19.2	20	19.2	40	38.5	24	23.1	6	-8.2	5.9	-1.3	3.5

Numbers and percentages: markers that were placed correctly in both directions and those that were displaced in only the vertical, only the horizontal and both the vertical and horizontal directions. Displacement values: vertical displacement: positive = above designated spinous process, negative = below; horizontal displacement: positive = towards the convex side of upper curve, negative = towards concave side of upper curve.

doi:10.1371/journal.pone.0135689.t002

Only few studies evaluated the validity of skin marker-derived spinal curvature measurements [16, 32, 33]. In the late 80's, Bryant et al. [32] investigated the accuracy of estimating sagittal thoracic and lumbar spine curvatures using RO markers and upright standing lateral view radiographic images in healthy adolescents. Their results suggested accurate estimation of

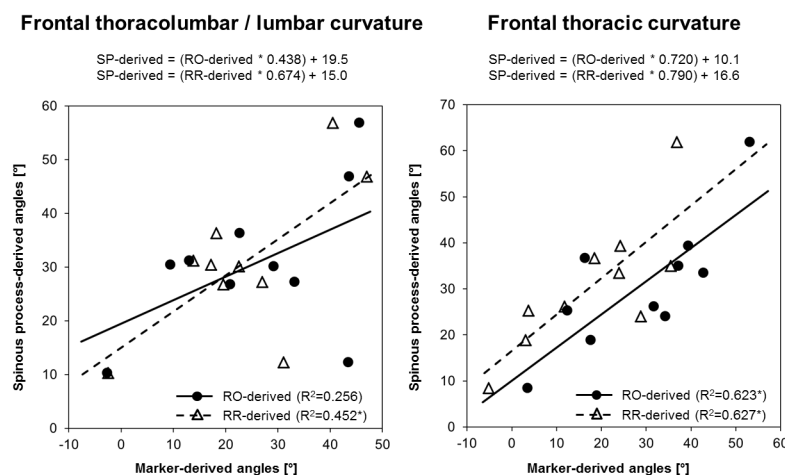


Fig 3. Illustration of the impact of marker placement error on curvature angle estimation. SP: spinous process-derived curvature angles; RO: radio-opaque marker-derived curvature angles; RR: retro-reflective marker-derived curvature angles. The asterisks (*) indicate statistical significance at the level $p \leq 0.05$.

doi:10.1371/journal.pone.0135689.g003

vertebral centroid curves by the RO markers. The thoracic kyphosis was more reliably measured than the lumbar lordosis, possibly due to a greater soft tissue thickness in the lumbar region. Despite the slightly different methodological approach, the current findings on AIS patients largely support these results. Moreover, the fact that a lumbar lordosis of more than approximately 40 degrees was less accurately estimated in AIS patients indicated that the issue of greater soft tissue thickness in the lumbar region seems to also depend upon the extent of the lordotic posture.

To investigate the validity of skin marker-based measurements for the quantification of spinal movement in the sagittal plane, Mörl and Blickhan [34] used MRI images of healthy adults in different seating postures and showed that lumbar vertebral position and spatial orientation could be estimated using skin markers. Using a similar method, Zemp et al. [16] examined soft tissue artifacts as well as estimation accuracies of skin markers (same placement as in the current study) for the measurement of lumbar and thoracic curves. They concluded that skin markers were suitable for the assessment of change in the sagittal curvature angles, but that absolute values suffered from uncertainty. Considering the tendency for lower estimation accuracy with increasing lumbar lordosis as reported in the current study, their suggestions to use skin markers for the assessment of postural change rather than absolute angles should also be followed for measurements in AIS patients.

While the two MRI-based studies above only described spinal curvature measurements in the sagittal plane, Hashemirad et al. [33] validated spinal curvature measurements in the frontal plane using posterior-anterior fluoroscopy images in a neutral and a lateral bending position. Their results suggested that skin markers could be confidently used for the estimation of lumbar spine curvature during lateral bending. Therefore, even though frontal curvatures in the current study were clearly underestimated mainly due to the rotational deformities in AIS patients (i.e. axial rotation and intrinsic axial torsional deformity of the vertebrae), skin markers might still be used for the assessment of movement in this plane.

The current study further showed that VB-derived sagittal thoracic curvature angles could be better estimated by the RO than the RR markers. This might be explained by the fact that in the movement analysis laboratory, the standing position of some patients did not exactly match the posture during the radiographic examination. For the lateral view images, patients were required to hold on to a horizontal bar elevating their arms to the front, which might have caused slight positional differences especially in the upper thoracic spine. If possible, future validations should therefore aim to perform the radiographic and motion capturing measurements simultaneously.

Concerning the differences between RO- and RR-derived measurements, the slightly increased underestimation of the frontal plane curvature angles by the RR compared to the RO markers might be due the fact that the RR markers were mounted on a plastic socket that allowed slight tilting towards the concave side when placed on the paravertebral muscles in the area of the curvature's apex. In general, regardless of the different types of markers, the underestimation of the curvatures in the frontal plane could be explained mainly by the pathology related structural deformity of the vertebrae as well as a systematic marker placement error towards the concave side of the curvatures. The fact that the palpable parts of the spinous processes were in most cases approximately one level below the position of the respective vertebral body (especially in the lower thoracic spine) might have led to an additional falsification of the actual frontal plane curvature.

Considering the available evidence on the identification accuracy of selected spinous processes, the results of the current study seem to be in agreement for the lumbar but not for the cervical spine. Harlick et al. [21] evaluated the identification accuracy of lumbar spine levels in adults (in the vertical direction), which were identified correctly in 47% of the cases (current

study: 60%). The average absolute displacement of the markers that were not identified correctly was 19.3 ± 18.6 mm (current study: 10.6 ± 2.5 mm). Other studies on adult and elderly subjects showed palpatory accuracies of 36–61% for the L5 (current study: 50%) and 55–77% for the C7 spinous process (current study: 0%) [22, 24, 28]. The low accuracy for the identification of C7 in the current study might be explained by the fact that the discrimination between C6 and C7 might have been harder in children and adolescents as compared to adults due to the size of the structures. In addition, five out of six markers that were not visible on the radiographs applied to C7. The placement of the thoracic markers could not be compared to the literature since no studies were available investigating the identification accuracy of thoracic spinous processes.

Conclusions

Skin marker-based motion capture techniques can be used for the non-invasive assessment of spinal curvature angles in the sagittal and frontal planes in patients with AIS. However, while absolute values in the sagittal plane could be measured with reasonable accuracy, frontal plane angles were systematically underestimated, mainly due to the rotational deformities of the scoliotic vertebrae. Skin markers on the trunk should therefore be used for the assessment of movement and postural change (i.e. during dynamic tasks such as walking) rather than for the measurement of absolute angles.

Inaccuracy of marker placement by palpation had a greater impact on the determination of the thoracolumbar / lumbar than the thoracic curvature angles. In order to keep such inaccuracies minimal, only health care professionals with experience in palpation should place markers.

Based on the current and previous findings, it is suggested that spinal curvature measurements are included in marker-based clinical gait analysis protocols. This would enable a deeper understanding of the behavior of the healthy and pathological spine in dynamic situations and would open up the possibility for a more comprehensive evaluation of treatment effects as movement seems to be detected reasonably well. In addition, the data can be used to drive complex spinal models in order to get an insight into the dynamic loading of the spine during movement.

Acknowledgments

The authors acknowledge Dr. Daniel Brandenberger, Dr. Stefan Demarmels, Dr. Bernhard Speth and Marie Freslier-Bossa for assistance in patient recruitment, Dino Causevic for technical assistance, Beat Goepfert for assistance in the data collection and the Department of Radiology at the University of Basel Children's Hospital in Basel, Switzerland.

Author Contributions

Conceived and designed the experiments: SS CH JR WRT RB SL. Performed the experiments: SS. Analyzed the data: SS DS CH JR WRT RB SL. Contributed reagents/materials/analysis tools: RB SL. Wrote the paper: SS DS CH JR WRT RB SL.

References

1. Krebs DE, Wong D, Jevsevar D, Riley PO, Hodge WA. Trunk kinematics during locomotor activities. *Phys Ther.* 1992; 72(7):505–14. PMID: [1409883](#)
2. Crosbie J, Vachalathiti R, Smith R. Patterns of spinal motion during walking. *Gait Posture.* 1997; 5:6–12.
3. Crosbie J, Vachalathiti R, Smith R. Age, gender and speed effects on spinal kinematics during walking. *Gait Posture.* 1997; 5:13–20.

4. Frigo C, Carabalona R, Dalla Mura M, Negrini S. The upper body segmental movements during walking by young females. *Clin Biomech (Bristol, Avon)*. 2003; 18(5):419–25.
5. Heyrman L, Feys H, Molenaers G, Jaspers E, Monari D, Meyns P, et al. Three-dimensional head and trunk movement characteristics during gait in children with spastic diplegia. *Gait Posture*. 2013; 38(4):770–6. doi: [10.1016/j.gaitpost.2013.03.019](https://doi.org/10.1016/j.gaitpost.2013.03.019) PMID: [23597939](https://pubmed.ncbi.nlm.nih.gov/23597939/)
6. Heyrman L, Feys H, Molenaers G, Jaspers E, Monari D, Nieuwenhuys A, et al. Altered trunk movements during gait in children with spastic diplegia: Compensatory or underlying trunk control deficit? *Research in developmental disabilities*. 2014; 35(9):2044–52. doi: [10.1016/j.ridd.2014.04.031](https://doi.org/10.1016/j.ridd.2014.04.031) PMID: [24864057](https://pubmed.ncbi.nlm.nih.gov/24864057/)
7. Heyrman L, Feys H, Molenaers G, Jaspers E, Van de Walle P, Monari D, et al. Reliability of head and trunk kinematics during gait in children with spastic diplegia. *Gait Posture*. 2012; 37(3):424–9. doi: [10.1016/j.gaitpost.2012.08.021](https://doi.org/10.1016/j.gaitpost.2012.08.021) PMID: [23062729](https://pubmed.ncbi.nlm.nih.gov/23062729/)
8. Kakushima M, Miyamoto K, Shimizu K. The Effect of Leg Length Discrepancy on Spinal Motion during Gait: Three-Dimensional Analysis in Healthy Volunteers. *Spine (Phila Pa 1976)*. 2003; 28(21):2472–6.
9. Konz RJ, Fatone S, Stine RL, Ganju A, Gard SA, Ondra SL. A kinematic model to assess spinal motion during walking. *Spine (Phila Pa 1976)*. 2006; 31(24):E898–906.
10. Leardini A, Biagi F, Merlo A, Belvedere C, Benedetti MG. Multi-segment trunk kinematics during locomotion and elementary exercises. *Clin Biomech (Bristol, Avon)*. 2011; 26(6):562–71.
11. Needham R, Chockalingam N, Dunning D, Healy A, Ahmed EB, Ward A. The effect of leg length discrepancy on pelvis and spine kinematics during gait. *Stud Health Technol Inform*. 2012; 176:104–7. PMID: [22744469](https://pubmed.ncbi.nlm.nih.gov/22744469/)
12. Chan PY, Wong HK, Goh JC. The repeatability of spinal motion of normal and scoliotic adolescents during walking. *Gait Posture*. 2006; 24(2):219–28. PMID: [16226029](https://pubmed.ncbi.nlm.nih.gov/16226029/)
13. Romkes J, Peeters W, Oosterom AM, Molenaar S, Bakels I, Brunner R. Evaluating upper body movements during gait in healthy children and children with diplegic cerebral palsy. *J Pediatr Orthop B*. 2007; 16(3):175–80. PMID: [17414776](https://pubmed.ncbi.nlm.nih.gov/17414776/)
14. Schweizer K, Brunner R, Romkes J. Upper body movements in children with hemiplegic cerebral palsy walking with and without an ankle-foot orthosis. *Clin Biomech (Bristol, Avon)*. 2014; 29(4):387–94.
15. Schmid S, Schweizer K, Romkes J, Lorenzetti S, Brunner R. Secondary gait deviations in patients with and without neurological involvement: A systematic review. *Gait Posture*. 2013; 37(4):480–93. doi: [10.1016/j.gaitpost.2012.09.006](https://doi.org/10.1016/j.gaitpost.2012.09.006) PMID: [23022156](https://pubmed.ncbi.nlm.nih.gov/23022156/)
16. Zemp R, List R, Gulay T, Elsig JP, Naxera J, Taylor WR, et al. Soft tissue artefacts of the human back: comparison of the sagittal curvature of the spine measured using skin markers and an open upright MRI. *PloS one*. 2014; 9(4):e95426. doi: [10.1371/journal.pone.0095426](https://doi.org/10.1371/journal.pone.0095426) PMID: [24748013](https://pubmed.ncbi.nlm.nih.gov/24748013/)
17. Rigo M. Patient evaluation in idiopathic scoliosis: Radiographic assessment, trunk deformity and back asymmetry. *Physiother Theory Pract*. 2011; 27(1):7–25. doi: [10.3109/09593985.2010.503990](https://doi.org/10.3109/09593985.2010.503990) PMID: [21198403](https://pubmed.ncbi.nlm.nih.gov/21198403/)
18. Hong JY, Suh SW, Tr E, Hong SJ, Yoon YC, Kang HJ. Clinical anatomy of vertebrae in scoliosis: global analysis in four different diseases by multiplanar reconstructive computed tomography. *Spine J*. 2013; 13(11):1510–20. doi: [10.1016/j.spinee.2013.06.047](https://doi.org/10.1016/j.spinee.2013.06.047) PMID: [23992938](https://pubmed.ncbi.nlm.nih.gov/23992938/)
19. Liljenqvist UR, Allkemper T, Hackenberg L, Link TM, Steinbeck J, Halm HF. Analysis of vertebral morphology in idiopathic scoliosis with use of magnetic resonance imaging and multiplanar reconstruction. *J Bone Joint Surg Am*. 2002; 84-A(3):359–68. PMID: [11886904](https://pubmed.ncbi.nlm.nih.gov/11886904/)
20. Herzenberg JE, Waanders NA, Closkey RF, Schultz AB, Hensinger RN. Cobb angle versus spinous process angle in adolescent idiopathic scoliosis. The relationship of the anterior and posterior deformities. *Spine (Phila Pa 1976)*. 1990; 15(9):874–9.
21. Harlick JC, Milosavljevic S, Milburn PD. Palpation identification of spinous processes in the lumbar spine. *Manual therapy*. 2007; 12(1):56–62. PMID: [16781182](https://pubmed.ncbi.nlm.nih.gov/16781182/)
22. Merz O, Wolf U, Robert M, Gesing V, Rominger M. Validity of palpation techniques for the identification of the spinous process L5. *Manual therapy*. 2013; 18(4):333–8. doi: [10.1016/j.math.2012.12.003](https://doi.org/10.1016/j.math.2012.12.003) PMID: [23414963](https://pubmed.ncbi.nlm.nih.gov/23414963/)
23. Snider KT, Snider EJ, Degenhardt BF, Johnson JC, Kribs JW. Palpatory accuracy of lumbar spinous processes using multiple bony landmarks. *Journal of manipulative and physiological therapeutics*. 2011; 34(5):306–13. doi: [10.1016/j.jmpt.2011.04.006](https://doi.org/10.1016/j.jmpt.2011.04.006) PMID: [21640254](https://pubmed.ncbi.nlm.nih.gov/21640254/)
24. Shin S, Yoon DM, Yoon KB. Identification of the correct cervical level by palpation of spinous processes. *Anesthesia and analgesia*. 2011; 112(5):1232–5. doi: [10.1213/ANE.0b013e3182110f9f](https://doi.org/10.1213/ANE.0b013e3182110f9f) PMID: [21346160](https://pubmed.ncbi.nlm.nih.gov/21346160/)

25. Lenke LG, Betz RR, Harms J, Bridwell KH, Clements DH, Lowe TG, et al. Adolescent idiopathic scoliosis: a new classification to determine extent of spinal arthrodesis. *J Bone Joint Surg Am.* 2001; 83-A(8):1169–81. PMID: [11507125](#)
26. List R, Gulay T, Stoop M, Lorenzetti S. Kinematics of the Trunk and the Lower Extremities during Restricted and Unrestricted Squats. *J Strength Cond Res.* 2013; 27(6):1529–38. doi: [10.1519/JSC.0b013e3182736034](#) PMID: [22990570](#)
27. Ernst MJ, Rast FM, Bauer CM, Marcar VL, Kool J. Determination of thoracic and lumbar spinal processes by their percentage position between C7 and the PSIS level. *BMC research notes.* 2013; 6:58. doi: [10.1186/1756-0500-6-58](#) PMID: [23398934](#)
28. Robinson R, Robinson HS, Bjorke G, Kvale A. Reliability and validity of a palpation technique for identifying the spinous processes of C7 and L5. *Manual therapy.* 2009; 14(4):409–14. doi: [10.1016/j.math.2008.06.002](#) PMID: [18793865](#)
29. Masaracchio M, Frommer C. *Clinical Guide to Musculoskeletal Palpation.* Champaign, IL: Human Kinetics; 2014.
30. Studer D. Clinical investigation and imaging. *J Child Orthop.* 2013; 7(1):29–35. doi: [10.1007/s11832-012-0461-8](#) PMID: [24432056](#)
31. Taubin G. Estimation of planar curves, surfaces, and nonplanar space curves defined by implicit equations with applications to edge and range image segmentation. *IEEE Trans Pattern Anal Mach Intell.* 1991; 13(11):1115–38.
32. Bryant JT, Reid JG, Smith BL, Stevenson JM. Method for determining vertebral body positions in the sagittal plane using skin markers. *Spine (Phila Pa 1976).* 1989; 14(3):258–65.
33. Hashemirad F, Hatef B, Jaberzadeh S, Ale Agha N. Validity and reliability of skin markers for measurement of intersegmental mobility at L2-3 and L3-4 during lateral bending in healthy individuals: A fluoroscopy study. *J Bodyw Mov Ther.* 2013; 17(1):46–52. doi: [10.1016/j.jbmt.2012.04.010](#) PMID: [23294683](#)
34. Morl F, Blickhan R. Three-dimensional relation of skin markers to lumbar vertebrae of healthy subjects in different postures measured by open MRI. *Eur Spine J.* 2006; 15(6):742–51. PMID: [16047207](#)