

Acute Carpal Tunnel Syndrome Due to Pyogenic Flexor Tenosynovitis without Any Antecedent Injury

Hirofumi Yoshida¹, Haruki Imura², Taiga Goto³, Takeharu Nakamata³,
Mohamud R. Daya⁴ and Toru Kamiya^{1,2}

Abstract

We herein report a case of acute carpal tunnel syndrome due to pyogenic flexor tenosynovitis in the absence of any antecedent injury whose rapid progression and course was similar to that seen with necrotizing fasciitis. This potentially disastrous clinical condition must be promptly recognized, since it needs early surgical management to prevent morbidity.

Key words: carpal tunnel syndrome, pyogenic flexor tenosynovitis, necrotizing fasciitis, *Staphylococcus aureus*

(Intern Med 56: 1439-1442, 2017)

(DOI: 10.2169/internalmedicine.56.7584)

Introduction

Carpal tunnel syndrome is a common chronic compressive neuropathy of the hand involving the median nerve. Although less common, carpal tunnel syndrome can also occur acutely due to trauma, coagulopathy, inflammation or infection (1). We review the literature and report a case of acute carpal tunnel syndrome that was characterized by no antecedent puncture injury to the hand, the presence of hypoesthesia in all five fingers and a rapidly progressive clinical presentation that resembled necrotizing fasciitis.

Case Report

A previously healthy 48-year-old Japanese woman presented to the emergency department with severe pain in her dominant right hand and wrist. She worked as an office assistant but denied any blunt or penetrating trauma to the hand. She did not take any medications and had no animal contact. Fifteen hours prior, she described the gradual onset of a tingling sensation at the tips of the fingers along with mild clumsiness in her hand. She tried loxoprofen (non-steroidal anti-inflammatory drug) without any improvement

in her symptoms.

On an examination, her vital signs were normal, and the hand was noted to be held in a partially flexed position at the wrist (Fig. 1). The skin of the volar aspect of the right wrist appeared red and edematous. The radial and ulnar artery pulses were palpable, and the capillary refill time was normal. A neurological examination revealed subjective hypoesthesia in all five fingers with positive Tinel and Phalen tests. Plain wrist radiographs were unremarkable, but an unenhanced computed tomography (CT) scan of the wrist demonstrated edematous changes around the digital flexor tendons within the wrist (Fig. 2). Laboratory studies were consistent with an acute infectious or inflammatory process with a white blood cell count of 11,000/ μ L with 87% neutrophils. Over the ensuing two hours, the patient's pain and edema rapidly worsened, and the erythema began to extend up her arm. Due to the rapid progression and pain out of proportion, an emergent surgical consultation was obtained for possible necrotizing fasciitis. In addition to necrotizing fasciitis, the surgery team was also concerned about pyogenic flexor tenosynovitis, and she was taken promptly to the operating room.

The intraoperative findings revealed a blood-stained purulent exudate as well as edematous changes within the com-

¹Department of General Internal Medicine, Rakuwakai Otowa Hospital, Japan, ²Department of Infectious Diseases, Rakuwakai Otowa Hospital, Japan, ³Department of Orthopedics, Rakuwakai Otowa Hospital, Japan and ⁴Department of Emergency Medicine, Oregon Health and Science University, USA

Received for publication April 14, 2016; Accepted for publication September 19, 2016

Correspondence to Dr. Hirofumi Yoshida, hirofumi.1623.yoshida@gmail.com

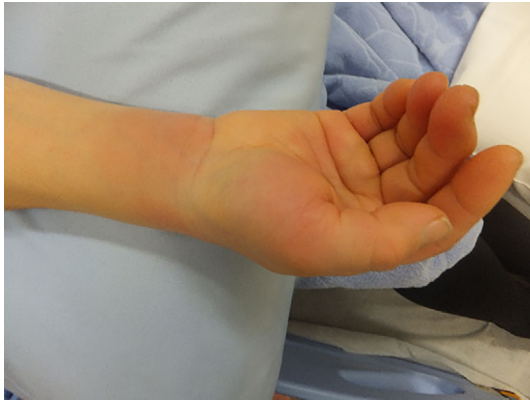


Figure 1. Hand held in partially flexed position at the wrist.

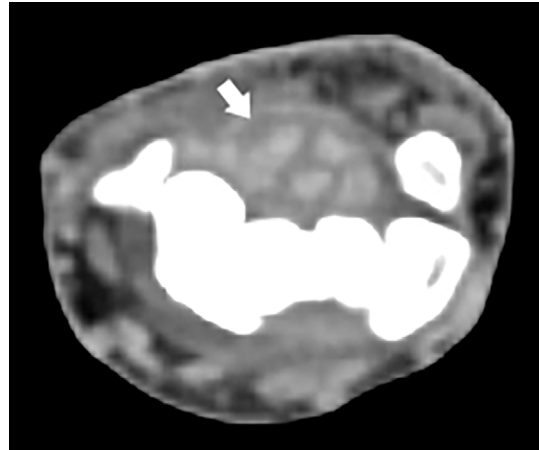


Figure 2. CT scan without contrast of the wrist showing edema around the digital flexor tendons at the wrist.

mon flexor tendon sheath (ulnar bursa) with secondary median nerve compression but no evidence of necrotizing fasciitis. The ulnar bursa was incised, debrided, and irrigated with saline and an external drainage catheter was placed. Two sets of blood cultures failed to grow any organisms, but a Gram stain of the exudate showed the presence of Gram-positive cocci, subsequently identified as penicillin-resistant but methicillin-susceptible *Staphylococcus aureus*. Preoperatively, she received meropenem, vancomycin and clindamycin and the antibiotic coverage was narrowed to first-generation cephalosporin based on the microbiological susceptibility pattern. She had an uncomplicated postoperative course, and antibiotic treatment was continued for 20 days. At her two-month follow-up, she had almost completely regained the motor and sensory function in the hand. The final diagnosis was acute carpal tunnel syndrome secondary to pyogenic flexor tenosynovitis.

Discussion

Carpal tunnel syndrome is a common chronic compressive neuropathy of the hand involving the median nerve. Although rare, carpal tunnel syndrome can also occur acutely due to trauma, coagulopathy, inflammation or infection (1). To date, there have been 15 cases of acute carpal tunnel syndrome related to bacterial infection reported in the English literature (Table) (2-11). Most of these patients were in good health, although one was immunocompromised due to a prior splenectomy. The disease developed mainly in middle-aged and older patients but across a wide age range, from 10 to 69 years old (median: 52 years old), and was almost equally observed in men (7/15 cases) as in women (8/15 cases). In 11 cases, a preceding injury was thought to be the source of infection, whereas 4 patients had no prior history of antecedent trauma. The initial clinical presentation ranged from an acute course of a few hours to symptoms developing up to eight days following injury. The etiological organism most commonly involved was *Staphylococcus*

aureus (6/15 cases, all of which were methicillin-sensitive) but also included β -hemolytic streptococci, coagulase-negative staphylococci, *Enterococcus faecalis*, *Clostridium histolyticum* and *Pasteurella multocida*. Our case is remarkable in that there was no antecedent puncture injury to the hand, hypoesthesia was present in all five fingers and the rapidly progressive clinical presentation resembled necrotizing fasciitis.

The severe and rapid worsening of pain, edema and erythema raised concerns of possible necrotizing fasciitis; however, the patient's clinical examination findings were also consistent with pyogenic flexor tenosynovitis due to the presence of Kanavel's four classic signs (fusiform symmetric swelling of the entire digit, digit held in partial flexion, tenderness along the flexor tendon sheath, pain along the tendon with passive digit extension) at the wrist (Fig. 1). While median nerve compression classically causes paresthesia in the first three fingers and the radial portion of the fourth finger, the intermediate bursa connects the radial and ulnar bursa in 80% of individuals (12). This permits a continuous link between the tendon sheaths of the flexor pollicis longus and that of the fifth finger. We suspect that the involvement of ulnar bursa in addition to compression of the median nerve resulted in paresthesia in all five fingers in our case. Although, we performed unenhanced CT on this patient due to our concern for necrotizing fasciitis, another useful imaging technique to consider is a focused point-of-care ultrasound of the wrist, since this has been found to be valuable in the early diagnosis of flexor tenosynovitis associated with digits (13). While a physical examination and imaging may help distinguish necrotizing fasciitis from acute carpal tunnel syndrome, an early surgical consultation is a must, since in both instances surgery is an essential part of the definitive diagnosis and therapy.

Initial empiric therapy should be targeted to cover skin organisms, including methicillin-resistant *Staphylococcus aureus*, given its increasing prevalence and the potentially disastrous nature of acute pyogenic carpal tunnel syndrome.

Table. Characteristics of Cases of Acute Pyogenic Carpal Tunnel Syndrome with Bacterial Cause.

Patient number	Age	Sex	Medical history	Injury	Surgery	Intraoperative culture results	Duration	Reference
1	58	F	Gout, Early osteoarthritis	Yes	Yes	Coagulase-negative staphylococci	10 days	2
2	53	F	Unknown	Yes	Yes	No growth	14 days	2
3	68	F	Unknown	No	Yes	β -hemolytic streptococci	Unknown	3
4	52	M	Unknown	Yes	Yes	<i>Staphylococcus aureus</i> , <i>Streptococcus faecalis</i>	Unknown	3
5	50	F	Unknown	Yes	Yes	No growth	Unknown	3
6	10	F	Unknown	Yes	Yes	<i>Staphylococcus aureus</i>	Unknown	4
7	23	M	Healthy	No	Yes	<i>Clostridium histolyticum</i>	6 weeks	5
8	62	F	Subtotal pancreatectomy for chronic pancreatitis, Splenectomy	Yes	Yes	<i>Staphylococcus aureus</i>	3 weeks	6
9	68	M	Unknown	Yes	Yes	Coagulase-negative staphylococci	8 days	6
10	59	M	Unknown	Yes	Yes	<i>Staphylococcus aureus</i>	Unknown	7
11	43	M	Unknown	Yes	Yes	Coagulase-negative staphylococci	Unknown	8
12	47	M	Unknown	No	Yes	<i>Staphylococcus aureus</i>	1 day	9
13	52	M	Unremarkable PMH, Penicillin allergy	Yes	Yes	group G streptococci	Unknown	10
14	56	F	Unknown	Yes	Yes	<i>Pasteurella multocida</i>	Unknown	11
15	48	F	Healthy	No	Yes	<i>Staphylococcus aureus</i>	20 days	Present case

The duration of treatment with prior cases has ranged from one day to five weeks. Neither blood stream infections nor disseminated lesions have been reported, regardless of whether an antecedent injury exists or not. Our patient also showed no systemic symptoms indicative of bacteremia, such as fever or shaking chills, and had neither positive blood culture results nor distant organ involvement. Based on the reported cases, it is reasonable to presume that acute pyogenic carpal tunnel syndrome most likely arises from contiguous spread through visible or invisible wounds rather than hematogenously. While we treated this patient for 20 days, Nourissat et al. suggested that, in the absence of any causative injury, prolonged treatment with systemic antibiotics may be unnecessary following total excision of the infected tissue in a healthy patient (9). We suggest that the duration of therapy should be guided by the culture results and clinical response following surgery.

In conclusion, this case highlights two important clinical teaching points. First, acute carpal tunnel syndrome due to pyogenic flexor tenosynovitis can be a cause of acute onset and rapid progression of wrist pain, even in the absence of injury. Second, unlike chronic carpal tunnel syndrome, acute pyogenic carpal tunnel syndrome can present with paresthesia in all five fingers due to the involvement of the interconnected radial and ulnar bursae. Since acute pyogenic carpal tunnel syndrome can lead to permanent median nerve injury as well as finger and/or hand amputation, early recognition and prompt operative management is essential.

The authors state that they have no Conflict of Interest (COI).

References

- Rick T, Asif MI. Acute carpal tunnel syndrome. *Orthop Clin N Am* **43**: 459-465, 2012.
- Bailey D, Carter JF. Median-nerve palsy associated with acute infections of the hand. *Lancet* **268**: 530-532, 1955.
- Oates GD. Median-nerve palsy as a complication of acute pyogenic infections of the hand. *Br Med J* **1**: 1618-1620, 1960.
- Williams LF Jr, Geer T. Acute carpal tunnel syndrome secondary to pyogenic infection of the forearm. *JAMA* **185**: 409-410, 1963.
- Gerardi JA, Mack GR, Lutz RB. Acute carpal tunnel syndrome secondary to septic arthritis of the wrist. *J Am Osteopath Assoc* **89**: 933-934, 1989.
- Flynn JM, Bischoff R, Gelberman RH. Median nerve compression at the wrist due to intracarpal canal sepsis. *J Hand Surg Am* **20**: 864-867, 1995.
- Rieger H, Grünert J, Brug E. A severe infection following endoscopic carpal tunnel release. *J Hand Surg Br* **21**: 672-674, 1996.
- Charalambous CP, Zipitis CS, Kumar R, Paul AS. Acute carpal tunnel syndrome: two rare cases. *Hand Surg* **8**: 117-118, 2003.
- Nourissat G, Fournier E, Werther JR, Dumontier C, Doursounian L. Acute carpal tunnel syndrome secondary to pyogenic tenosynovitis. *J Hand Surg Br* **31**: 687-688, 2006.
- Simon DA, Taylor TL. Horseshoe abscess associated with acute carpal tunnel syndrome: somebody wake up the hand surgeon. *CJEM* **14**: 124-127, 2012.
- Sbai MA, Dabloun S, Benzarti S, Khechimi M, Jenzeri A, Maalla R. Acute carpal tunnel syndrome of the hand following a cat bite. *Pan Afr Med J* **21**: 206, 2015.
- Reid WD, Donald KB Jr. Flexor tendon sheath infections of the hand. *J Am Acad Orthop Surg* **20**: 373-382, 2012.

13. Padrez K, Bress J, Johnson B. Bedside ultrasound identification of infectious flexor tenosynovitis in the emergency department. *J Emerg Med* **16**: 260-262, 2015.

The Internal Medicine is an Open Access article distributed under the Creative Commons Attribution-NonCommercial-NoDerivatives 4.0 International License. To view the details of this license, please visit (<https://creativecommons.org/licenses/by-nc-nd/4.0/>).

© 2017 The Japanese Society of Internal Medicine
<http://www.naika.or.jp/imonline/index.html>