

Idiopathic CD4⁺ T-lymphocytopenia with bronchiectasis and hyperimmunoglobulin A

Mehmet Kose, Mustafa Ozturk, Turkan Patiroglu, Bahadir Konuskan

From the Department of Pediatrics, Erciyes University, Kayseri, Turkey

Correspondence and reprints: Mehmet Kose, MD · Department of Pediatrics, Faculty of Medicine, Erciyes University, Kayseri 38000, Turkey · mhmtkose@yahoo.com · Accepted for publication October 2007

Ann Saud Med 2008; 28(5): 390-393

Since 1989, unusual cases of opportunistic infections and CD4⁺ T-lymphocytopenia in the absence of human immunodeficiency virus (HIV) infection have been reported. Patients with idiopathic CD4⁺ T-lymphocytopenia (ICL) may be asymptomatic or may suffer from opportunistic infections that are very similar to those found in patients with acquired immunodeficiency syndrome.¹ We describe a 12-year-old male without known risk factors for decreased cellular immunity, who presented with bronchiectasis, candidiasis, clubbing and hyperimmunoglobulin A. There were similar findings in his brother.

CASE

A 12-year-old male was admitted to our hospital with a productive cough for 15 days. He had been treated several times for pneumonia. His parents were first-degree cousins. He had one sister and one brother. While his parents and sister were normal, his brother had similar findings. Physical examination revealed crackles in the left and right bases of the lung, white-yellow plaques on the oral mucosa and clubbing in his fingers (Figure 1a). A chest x-ray showed atelectasis at the base of the left lung and paracardiac infiltrates on the right lung (Figure 1b). Computed tomography showed bronchiectasis at the base of the left lung (Figure 1c). Laboratory findings included a hemoglobin of 13.6 g/dL, a platelet count of $321 \times 10^9/L$ and white blood cells of $8.2 \times 10^9/L$ with 82% neutrophils and 18% lymphocytes. Serum glucose, creatinine, electrolytes, liver enzymes and blood urea nitrogen levels were normal. Culture of the oral mucosa, sputum and bronchoalveolar lavage (BAL) fluid revealed *Candida albicans*. *Candida albicans* was susceptible to amphotericin B and fluconazole, and therapy was started with fluconazole. Because of opportunistic infection and bronchiectasis, a series of immunological investigations were undertaken (Table 1). Results of repeated serologic evaluation for antibodies specific for HIV-1 and -2 on three occasions (including ELISA and Western blot) were negative. Acid-fast organisms were not obtained

on the Erlich-Ziehl-Nelson staining from the sputum and BAL and there was no evidence of mycobacterium in cultures. The tuberculin skin test was negative. Antibodies for hepatitis B and C virus were negative. After 15 days of fluconazole therapy, he recovered and was discharged. At the 6th and 9th months of follow-up, the values for CD4 were 18.2% and 19.1%; CD8, 48.8% and 47.2% and IgA, 945 mg/dL and 921 mg/dL, respectively. CD4/CD8 ratios were 0.37 and 0.40.

His brother was 18 years old and had been suffer-

Table 1. Results of immunological tests.

Parameter	Measured value	Normal range
IgG (mg/dL)	1850	700-1600
IgG1 (mg/dL)	923	432-1060
IgG2 (mg/dL)	201	72-355
IgG3 (mg/dL)	53.8	12-173
IgG4 (mg/dL)	9.4	1.9-115
IgA (mg/dL)	1150	85-220
IgM (mg/dL)	335	65-206
IgE (U/mL)	12	0-200
IgD (mg/dL)	5.5	1-8
Alpha-1 antitrypsin (mg/dL)	199	90-200
Sweat test (mmol/L)	33	<40
CD45 (%)	99.9	88-100
CD3 (%)	85.57	60-85
CD4 (%)	16.2	29-59
CD8 (%)	43.8	19-48
CD16 (%)	5.9	7-20
CD19 (%)	12.7	11-16
CD4/CD8 ratio	0.37	1.2-1.8

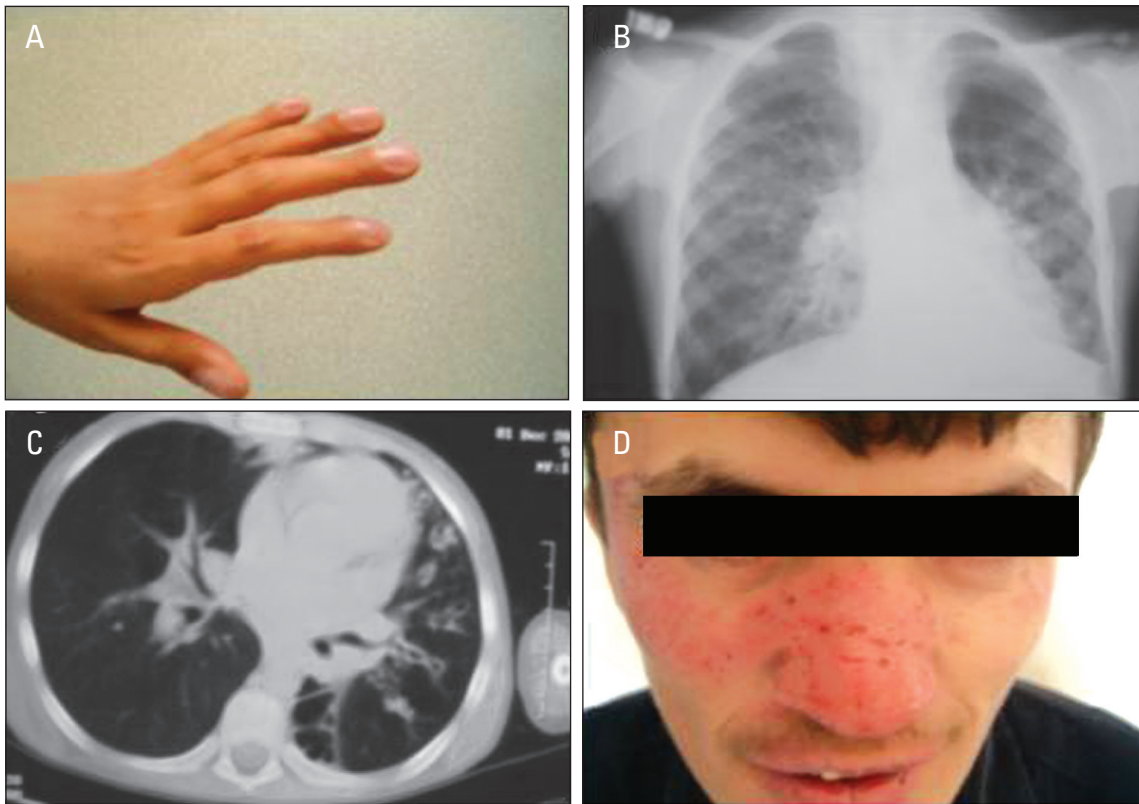


Figure 1. Shows the clubbing in his fingers (a), atelectasis at the base of the left lung and paracardiac infiltrates on the right lung (b), bronchiectasis at the base of the left lung (c), and the brother's dermatitis, which had been present on his nose for two years (d).

ing from dermatitis on his nose for 2 years (Figure 1d). Laboratory findings included a hemoglobin of 13.6 g/dL, and white blood cells, $8.2 \times 10^9/L$ with 54% neutrophils, 38% lymphocytes and 8% monocytes; and platelet count, $8.2 \times 10^9/L$; CD4, 22.2% and 24.6%; CD8, 38.9% and 39.3%; CD4/CD8 ratios 0.57 and 0.62; and IgA, 650 mg/dL and 621 mg/dL. IgG, IgG subgroups, IgM, IgD and IgE were within normal levels. Antinuclear antibodies, HIV and *Leishmania* serologies were negative. In direct microscopy, we could not obtain a fungal component. Dermal biopsy was performed and the patient was diagnosed with chronic dermatitis.

DISCUSSION

Idiopathic CD4⁺ T-lymphocytopenia (ICL) is defined as a CD4⁺ T-cell count of less than $300 \times 10^9/L$ or a CD4⁺ cell count <20% and a CD4⁺/CD8⁺ cell ratio of less than one on two occasions in the absence of HIV-1, HIV-2 and human T-cell leukemia virus infection, and of known immune deficiency disease or therapy associated with lymphopenia.^{2,3} This syndrome is extremely rare. No explanation of the possible origin of this syndrome has yet been found. The disease has a broad spec-

trum of potentially associated diseases from completely asymptomatic immunological disorder to the occurrence of opportunistic infections, hematological and solid malignancies, neurological disorders, autoimmune diseases and other illnesses.⁴ A genetic background may be hypothesized after the recent description of idiopathic CD4⁺ T-lymphocytopenia in two siblings in another report.^{1,5} The siblings' parents were cousins and thus a familial inherited disease could be suspected. Although ICL syndrome is a very heterogeneous entity, familial cases suggest involvement of a transmissible agent.

Laurence et al demonstrated that increased spontaneous and activation-induced apoptosis was associated with symptomatic ICL, and this might represent one pathophysiological mechanism of the disease.⁶ Netea et al postulated that decreased production of tumor necrosis factor α and interferon-gamma might be the mechanism responsible for the immune defect in HIV-seronegative patients with CD4 lymphopenia.⁷ Cunningham-Rundles et al reported that low-dose interleukin-2 therapy for 5 years resulted in marked long-term immunological improvement with normalized T-cell functions and increased CD4⁺ T-cell numbers.⁸

These limited case reports postulated that cytokine abnormalities might play an important role in the etiological pathways of ICL.

Opportunistic infections, such as a *Mycobacterium kansasii* pneumonia,⁹ *Salmonella arizonae* sepsis and esophageal candidiasis,¹⁰ *Fusobacterium nucleatum* hepatic abscess and local complications,¹¹ various tuberculosis localizations,¹² disseminated tuberculosis,¹³ cryptococcal meningoen- cephalitis, cerebral cryptococcoma,¹⁴ and musculoskeletal cryptococcosis,¹⁵ usually represent the first clinical sign of an underlying primary CD4⁺ lymphocytopenia. We demonstrated *Candida albicans* as the opportunistic agent from the culture of the oral mucosa, sputum and BAL.

We believe that our case fulfilled the criteria for ICL for the following reasons: 1) the patient showed no evidence of HIV infection and never received immunosuppressive drugs; 2) he suffered from opportunistic infection (*Candida albicans*); 3) the CD4⁺ T-lymphocyte count was below 20% on three occasions for 6 months after admission. Freier et al described two siblings suffering from mental retardation, progressive bronchiectasis, extensive warts, persistent hepatitis B and ICL.⁵ Our patient had bronchiectasis and ICL, but the other clinical features were absent. Additional clinical features in our patient were *Candida albicans* infection, clubbing, and a persistent hyperimmunoglobulin-A level.

An interesting finding was that our patient's brother had dermatitis on his nose for two years. The CD4⁺ T-cell count was below the normal level, the CD4⁺/CD8⁺

ratio was less than 1 and the IgA level was also high. An association with atopic and allergic contact dermatitis was described in 1993, with emphasis on the possible cutaneous features of this syndrome,¹⁶ but the patient's brother did not fulfill the criteria for ICL because his CD4⁺ T-cell counts were more than 20% (22.2% and 24.6%).

Hematological and solid malignancies, such as Kaposi's sarcoma,¹⁷ intravascular lymphoma,¹⁸ malignant lymphoma,¹⁹ vulvar carcinoma,²⁰ squamous cell carcinoma,²¹ and basal cell carcinomas²² are associated with ICL and might be the first clinical sign of ICL. Wilhelm et al described a woman with ICL and in the follow-up period the patient developed interstitial nephritis associated with a plasma cell dyscrasia with a monoclonal IgA gammopathy and a shifting immunoglobulin pattern that included IgG and IgA monoclonal proteins and increased urinary light chains. IgA levels increased to 2640 mg/dL. He postulated that monoclonal proliferation of B cells or plasma cells might be under T cell control.²³ We examined our patients for IgA gammopathy, could not find any evidence for monoclonal gammopathy. We found no explanation for ICL and hyperimmunoglobulin-A in our cases. To our knowledge, this is the first observation of ICL with hyperimmunoglobulin-A and bronchiectasis. Our patient had different clinical and immunologic characteristics, although he met the criteria for ICL syndrome, confirming that this is a very heterogeneous entity.

REFERENCES

1. Lin SJ, Chao HC, Yan DC, Kuo ML. Idiopathic CD4⁺ T lymphocytopenia in two siblings. *Pediatr Hematol Oncol.* 2001;18:153-6.
2. Laurence J, Siegal FP, Schattner E, Lynch DH, Siegal FP, Staiano-Coico L. Acquired immunodeficiency without evidence of infection with human immunodeficiency virus types 1 and 2. *Lancet.* 1992;340:273-4.
3. Smith DK, Neal JJ, Holmberg SD. Unexplained opportunistic infections and CD4⁺ T-lymphocytopenia without HIV infection. An investigation of cases in the United States. The Centers for Disease Control Idiopathic CD4⁺ T-lymphocytopenia Task Force. *N Engl J Med.* 1993;328:373-9.
4. Manfredi R, Calza L, Chiodo F. A new syndrome of long-term idiopathic, severe CD4⁺ lymphocytopenia: isolated paraparesis and conjunctival ischemic microangiopathy. *J Biol Regul Homeost Agents.* 2004;18:33-7.
5. Freier S, Kerem E, Dranitzki Z, Schlesinger M, Rabinowitz R, Brautbar C, et al. Hereditary CD4⁺ T lymphocytopenia. *Arch Dis Child.* 1998;78:371-2.
6. Laurence J, Mitra D, Steiner M, Lynch DH, Siegal FP, Staiano-Coico L. Apoptotic depletion of CD4⁺ T cells in idiopathic CD4⁺ T lymphocytopenia. *J Clin Invest.* 1996;97:672-80.
7. Netea MG, Brouwer AE, Hoogendoorn EH, Van der Meer JW, Koolen M, Verweij PE, et al. Two patients with cryptococcal meningitis and idiopathic CD4 lymphopenia: defective cytokine production and reversal by recombinant interferon- gamma therapy. *Clin Infect Dis.* 2004;39:83-7.
8. Cunningham-Rundles C, Murray HW, Smith JP. Treatment of idiopathic CD4 T lymphocytopenia with IL-2. *Clin Exp Immunol.* 1999;116:322-5.
9. Anzalone G, Cei M, Vizzaccaro A, Tramma B, Bisetti A. M. Kansai pulmonary disease in idiopathic CD4⁺ T-lymphocytopenia. *Eur Respir J.* 1996;9:1754-6.
10. Galie M, Cassone M, Ausiello C, Serra P. Idiopathic CD4⁺ T-lymphocyte deficiency: the clinical evolution of a case. *Ann Ital Med Int.* 1997;12:233-7.
11. Etienne M, Gueit I, Abboud P, Pons JL, Jacquot S, Caron F. Fusobacterium nucleatum hepatic abscess with pylephlebitis associated with idiopathic CD4 (+) T lymphocytopenia. *Clin Infect Dis.* 2001;32:326-8.
12. Kony SJ, Hane AA, Larouze B, Samb A, Cissoko S, Sow PS, et al. Tuberculosis-associated severe CD4⁺ T-lymphocytopenia in HIV-seronegative patients from Dakar. *SIDAK Research Group. J Infect.* 2000;41:167-71.
13. De Socio GV, Gerli R, Menichetti F. Disseminated tuberculosis and idiopathic CD4⁺ T-lymphocytopenia. *Clin Microbiol Infect.* 1999;5:653-654.
14. Ho CL, Chang BC, Hsu GC, Wu CP. Pulmonary cryptococcoma with CD4 lymphocytopenia and meningitis in an HIV-negative patient. *Respir Med.* 1998;92:120-2.
15. Zanelli G, Sansoni A, Ricciardi B, Ciacci C, Cellesi C. Muscular-skeletal cryptococcosis in a patient with idiopathic CD4⁺ lymphopenia. *Mycopathologia.* 2001;149:137-9.
16. Goodrich AL, Tigelaar RE, Watsky KL, Heald PW. Idiopathic CD4⁺ lymphocyte deficiency. Report of an unusual case associated with atopic dermatitis and allergic contact dermatitis and review of the literature. *Arch Dermatol.* 1993;129:876-8.
17. Fierro MT, Savoia P, Quaglini P, Bernengo MG. Disseminated Kaposi's sarcoma associated with idiopathic CD4⁺ lymphocytopenia and low dose steroid therapy. *Clin Exp Dermatol.* 2005;30:395-7.
18. Guilloton L, Drouet A, Bernard P, Berbineau A, Berger F, Kopp N, et al. Cerebral intravascular lymphoma during T CD4⁺ idiopathic lymphopenia syndrome. *Presse Med.* 1999;28:1513-5.
19. Hanamura I, Wakita A, Harada S, Tsuboi K, Komatsu H, Banno S, et al. Idiopathic CD4⁺ T-lymphocytopenia in a non-Hodgkin's lymphoma patient. *Intern Med.* 1997;36:643-6.
20. Rijnders RJ, van den Ende IE, Huikeshoven FJ. Suspected idiopathic CD4⁺ T-lymphocytopenia in a young patient with vulvar carcinoma stage IV. *Gynecol Oncol.* 1996;61:423-6.
21. Michel JL, Perrot JL, Mitanne D, Boucheron S, Fond L, Cambazard F. Metastatic epidermoid carcinoma in idiopathic CD4⁺ T lymphocytopenia syndrome. *Ann Dermatol Venereol.* 1996;123:478-82.
22. Ohashi DK, Crane JS, Spira TJ, Courrege ML. Idiopathic CD4⁺ T-cell lymphocytopenia with verrucae, basal cell carcinomas, and chronic tinea corporis infection. *J Am Acad Dermatol.* 1994;31:889-91.
23. Wilhelm M, Weissinger F, Kunzmann V, Muller JG, Fahey JL. Idiopathic CD4⁺ T cell lymphocytopenia evolving to monoclonal immunoglobulins and progressive renal damage responsive to IL-2 therapy. *Clin Immunol.* 2001;99:298-304.