

Laparoscopic Approach to a Large Ovarian Fibroma: A Case Report

Zahra Najmi¹, Abolfazl Mehdizadehkashi^{2*}, Maryam Kadivar³, Zeinab Tamannaie¹, Shahla Chaichian^{2,4}

1- Minimally Invasive Surgery Research Center, Iran University of Medical Sciences, Tehran, Iran

2- Endometriosis Research Center, Iran University of Medical Sciences, Tehran, Iran

3- Department of Pathology, Rasoul-e-Akram Hospital, Iran University of Medical Sciences, Tehran, Iran

4- Minimally Invasive Techniques Research Center of Tehran Medical Sciences Branch, Islamic Azad University, Tehran, Iran

Abstract

* *Corresponding Author:*
Abolfazl Mehdizadehkashi,
Minimally Invasive Sur-
gery Research Center,
Maziyar Mansoori St.,
Niayesh Ave., Sattar Khan
St., Tehran, Iran
E-mail:
amehdizadehkashi@yahoo.
com

Received: Nov. 26, 2013

Accepted: Dec. 29, 2013

Background: Ovarian fibroma is the most common benign solid tumor of the ovary, which is often difficult to diagnose preoperatively. The choice treatment for ovarian fibroma is surgical removal, but discussions for the operative approach, laparoscopic or open, in the literature seem to be scant.

Case Presentation: We presented a unique clinical experience of laparoscopic approach to a case of 15 cm unilateral ovarian fibroma in a 24 year old patient, with a successful and complete resection of the tumor beside ovarian tissue preservation in December 2012 in Rasoul-e-Akram hospital, Tehran, Iran.

Conclusion: In conclusion, we should not forget the role of laparoscopy as a diagnostic procedure even in suspicious cases of ovarian fibroma with solid tumor, ascites, and pleural effusion.

Keywords: Benign ovarian neoplasm, Laparoscopy, Ovarian fibroma, Thecoma.

To cite this article: Najmi Z, Mehdizadehkashi A, Kadivar M, Tamannaie Z, Chaichian Sh. Laparoscopic Approach to a Large Ovarian Fibroma: A Case Report. *J Reprod Infertil.* 2014;15(1):57-60.

Introduction

Ovarian fibroma is a solid tumor that belongs to sex-cord stromal cell tumors of the ovary and comprises spindle shape fibroblastic cells and abundant collagen (1, 2). Furthermore they are the most common benign solid tumors of the ovary, which account for 1–4% of benign ovarian tumors (1, 3–4). Ovarian fibroma is often difficult to diagnose preoperatively and usually misdiagnosed as uterine myoma, because of the solid nature of the mass on examination, and the ultrasonic similarities between the two anomalies. Ascites is occasionally present and is sometimes complicated by plural effusion, which is called Meig's syndrome. Occasionally the serum level of CA125 increases, which may lead to misdiagnosis of endometriosis or malignant tumors of the ovary (5, 6). This tumor occurs generally in elderly patients. In one study, 80.9% of the women were

over 40 years old, and 49.0% of the patients were postmenopausal (7). Although rare, ovarian fibroma has been reported in young people too, in which the possibility of Gorlin syndrome, also known as nevoid basal cell carcinoma syndrome, must be considered (8–10).

The choice treatment for ovarian fibroma is surgical removal, but the operative approach, whether laparoscopic or open has not been discussed sufficiently. Surgeons are reluctant to use laparoscopic surgical management, as the benign nature of the tumor cannot be definitely diagnosed preoperatively and it might be difficult to laparoscopically resect the tumor safely with preservation of ovarian function, especially in young patients.

In this case report, we presented a 24 year old patient with this tumor.

Case Presentation

A 24 year old Gravida 1 Para1 (G₁P₁) lady presented to the gynecology clinic of Rasoul-e-Akram hospital with pelvic discomfort for one year, which was recently exacerbated and dominantly located on right lower quadrant of the abdomen. The patient had no medical or surgical history, except for one Pfannenstiel-kerr cesarean section about 3 years ago. Primary physical examinations revealed a mobile solid mass of nearly 12–14 cm in diameter, which couldn't be differentiated from a uterine myoma. Pelvic ultrasonography showed a mixed echo mass of 117×83 mm in right adnexa, with vascular flow and pressure on posterior wall of the uterus. There was no sign of ascites or plural effusion. Preoperatively, tumor markers were assessed, which were within normal range and patient was scheduled for laparoscopic resection of the lesion on December 2012 in Rasoul-e-Akram hospital.

Procedure: Abdominal access was achieved by primary puncture with a 10 mm diameter umbilical cannula. Two other 5 mm diameter ancillary cannulas were introduced after creation of pneumoperitoneum by nearly 2.5 L of carbon dioxide.

A rigid video laparoscope was entered via umbilical port and two grasping forceps were introduced via two ancillary cannulas. During the procedure, the patient was placed in Trendelenburg position. Several adhesion bundles were seen between uterus, adnexa, omentum and abdominal wall that were lysed. The right ovary contained a huge (10×15 cm), multiloculated, mobile and well circumscribed mass with laparoscopic features similar to a benign ovarian mass especially an ovarian fibroma or thecoma (Figure 1).

We sent a sample for frozen section examination which proved the benign nature of the tumor, ovarian fibroma. Despite the size of the mass and tight adhesion of the capsule to the ovarian tissue,

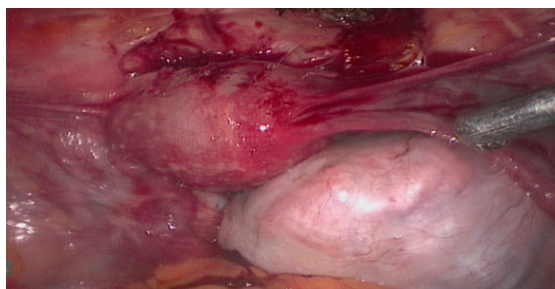


Figure 1. Primary laparoscopy feature of the tumor in a 24 year old patient, December 2012, Rasoul-e-Akram hospital, Tehran, Iran

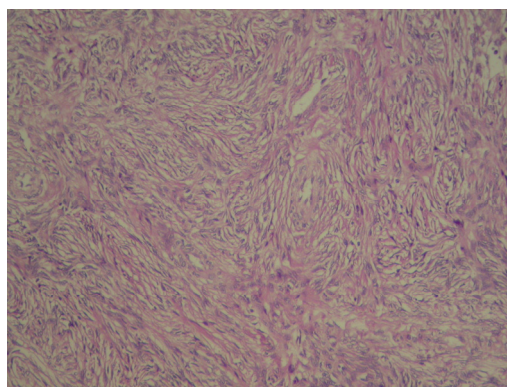


Figure 2. Pathologic feature of the tumor in a 24 year old patient, December 2012, Rasoul-e-Akram hospital, Tehran, Iran

with a careful dissection and desiccation of the tumor, we could preserve the ovary during complete excision of the fibroma. After the excision of the ovarian fibroma, under direct vision of a 5 mm telescope, it was morcellated and removed through the umbilical port.

Pneumoperitoneum was then deflated and ports were removed under direct vision. Finally, the rectus sheath and skin were closed with vicryl 2/0. Operating time from incision to closure was nearly 50 min, with no intraoperative complication. Postsurgical recovery was uneventful and the patient was discharged on the second day of surgery. There were also no immediate postoperative complications. Histopathologic examination revealed proliferation of spindle cells with blended nucleus in stratiform pattern with no pleomorphism or mitotic activity, which confirmed the diagnosis of ovarian fibroma (Figure 2).

Discussion

As occurred in our case, ovarian fibroma is often difficult to diagnose and the tumor is not often diagnosed accurately until the time of surgery. There are no characteristic symptoms and the ultrasonographic findings cannot easily distinguish ovarian fibroma from uterine myoma or even other types of ovarian mass. It has been reported that 34% of ovarian fibromas were misdiagnosed preoperatively as uterine myoma (11). On the other hand, up to 67% of these patients suffered from ascites, even in a very small-sized tumor. Also, high levels of serum CA125 in many of these cases may frequently cause misdiagnosis of malignant ovarian neoplasia (12, 13).

Surgery is the unique treatment for ovarian fi-

broma. Salpingo-oophorectomy can be considered in perimenopausal or postmenopausal women, and cystectomy should be performed in youths.

Previous reports showed the tendency to non-conservative approach in older ages, especially in laparoscopic surgery (7, 14). Eop Son et al. reported only 5 cases of ovarian cystectomy with laparoscopic approach in a retrospective review on 47 women with confirmed ovarian fibromas. Others underwent more invasive approaches, in which the ovary was sacrificed. The median tumor diameter in laparoscopic group was 7 cm in one study (7). In other reported series of ovarian fibromas with mean diameter of 12.82 cm, no ovarian preservation was reported (14). Son recently reported a case of bilateral salpingo oophorectomy, or a large 10 cm ovarian fibroma, using a single port laparoscopic approach in a 64 year old woman (7).

Ovarian preservation was mostly reported in younger patients and accompanied with Gorlin syndrome, which is present mostly with multiple and recurrent fibromas (8–10). For example, Ball et al. have reported 10 laparoscopic removals of ovarian fibromas, ranging from 3 mm to 7 cm in size (8). Seracchioli et al. reported laparoscopic removal of nine stony ovarian fibromas with ovarian tissue preservation, in a 22 year old girl (10). Although it was accepted to perform the surgery, either by laparotomy or laparoscopy, we recommend laparoscopy as the method of choice, especially in young patients, even in cases of very large ovarian fibromas.

Comparative analysis of the outcomes between the laparoscopy and laparotomy group showed that laparoscopic surgery has several advantages including careful preservation of ovarian tissue, lower rate of adhesion—that is very important in young nulliparous patients (for preventing infertility due to tubal factor), shorter hospital stay, faster normalization of bowel activities, faster return to social life, less morbidity and better cosmetic results (7).

Although there is a steady evolution towards less invasive techniques, laparoscopic approach to ovarian fibroma, especially in large tumors, may be challenging. However, we preserved nearly all normal ovarian tissue and safely removed the tumor by morcellator through a 10 mm trocar.

In conclusion, we should not forget the role of laparoscopy as a diagnostic procedure even in suspicious cases of ovarian fibroma with solid tumor, ascites, and plural effusion.

Conclusion

In these cases, the benefits of using laparoscopy should not be neglected since we are able to change the laparoscopy to laparotomy in large malignant stage I tumors.

Conflict of Interest

The authors declare no conflict of interest.

References

1. Chechia A, Attia L, Temime RB, Makhoul T, Koubaa A. Incidence, clinical analysis, and management of ovarian fibromas and fibrothecomas. *Am J Obstet Gynecol.* 2008;199(5):473.e1-4.
2. Nocito AL, Sarancone S, Bacchi C, Tellez T. Ovarian thecoma: clinicopathological analysis of 50 cases. *Ann Diagn Pathol.* 2008;12(1):12-6.
3. Gargano G, De Lena M, Zito F, Fanizza G, Mattioli V, Schittulli F. Ovarian fibroma: our experience of 34 cases. *Eur J Gynaecol Oncol.* 2003;24(5):429-32.
4. Leung SW, Yuen PM. Ovarian fibroma: a review on the clinical characteristics, diagnostic difficulties, and management options of 23 cases. *Gynecol Obstet Invest.* 2006;62(1):1-6.
5. Sivanesaratnam V, Dutta R, Jayalakshmi P. Ovarian fibroma—clinical and histopathological characteristics. *Int J Gynaecol Obstet.* 1990;33(3):243-7.
6. Patsner B. Meigs syndrome and "false positive" preoperative serum CA-125 levels: analysis of ten cases. *Eur J Gynaecol Oncol.* 2000;21(4):362-3.
7. Son CE, Choi JS, Lee JH, Jeon SW, Hong JH, Bae JW. Laparoscopic surgical management and clinical characteristics of ovarian fibromas. *JSLs.* 2011;15(1):16-20.
8. Ball A, Wenning J, Van Eyk N. Ovarian fibromas in pediatric patients with basal cell nevus (Gorlin) syndrome. *J Pediatr Adolesc Gynecol.* 2011;24(1):e5-7.
9. Aram S, Moghaddam NA. Bilateral ovarian fibroma associated with Gorlin syndrome. *J Res Med Sci.* 2009;14(1):57-61.
10. Seracchioli R, Bagnoli A, Colombo FM, Missiroli S, Venturoli S. Conservative treatment of recurrent ovarian fibromas in a young patient affected by Gorlin syndrome. *Hum Reprod.* 2001;16(6):1261-3.
11. Leung SW, Yuen PM. Ovarian fibroma: a review on the clinical characteristics, diagnostic difficulties, and management options of 23 cases. *Gynecol Obstet Invest.* 2006;62(1):1-6.
12. Moran-Mendoza A, Alvarado-Luna G, Calderillo-Ruiz G, Serrano-Olvera A, Lopez-Graniel CM, Gallardo-Rincon D. Elevated CA125 level associ-

- ated with Meigs' syndrome: case report and review of the literature. *Int J Gynecol Cancer*. 2006;16 Suppl 1:315-8.
13. Sevinc A, Camci C, Turk HM, Buyukberber S. How to interpret serum CA 125 levels in patients with serosal involvement? A clinical dilemma. *On*
cology. 2003;65(1):1-6.
 14. Tarcoveanu E, Dimofte G, Niculescu D, Vasilescu A, Moldovanu R, Ferariu D, et al. Ovarian fibroma in the era of laparoscopic surgery: a general surgeon's experience. *Acta Chir Belg*. 2007;107(6):664-9.