


CLINICAL IMAGE

Hemivertebra of the cervical spine: an uncommon background for neck pain, cervical scoliosis, and torticollis

Stylios Kapetanakis¹ , Grigorios Gkadaris¹, Evangelos Nastoulis² & Vladimir Stavrev³

¹Spine Department and Deformities, Interbalkan Medical Center, Thessaloniki, Greece

²Forensic Department, General Hospital of Messinia, Kalamata, Greece

³Department of Orthopedics and Traumatology, Medical University, Plovdiv, Bulgaria

Correspondence

Stylios Kapetanakis, Spine Department and Deformities, Interbalkan Medical Center, Thessaloniki, Greece. Tel: +306972707384; Fax: +302541067200; E-mail: stkapetanakis@yahoo.gr

Funding Information

No sources of funding were declared for this study.

Received: 30 April 2017; Accepted: 26 July 2017

Clinical Case Reports 2017; 5(10): 1718–1719

doi: 10.1002/ccr3.1144

Key Clinical Message

A 15-year-old female patient presented with neck pain accompanied by cervical scoliosis, on the existence of torticollis. Although rare, hemivertebra of the cervical spine is a congenital deformation associated with these three clinical features.

Keywords

Cervical scoliosis, hemivertebra, neck pain, torticollis.

Case Description

A 15-year-old female patient, with known history of torticollis, presented with mild neck pain existing over the last 2 years. From her medical history, there was nothing noteworthy. Physical examination did not reveal any neurologic deficit or any other findings. Static X-rays revealed the presence of cervical scoliosis, malformation of the atlanto-axial joint with indication of inadequate fusion of the odontoid process to C2 body, and a suspicion of an additional rib attached to C7. C3–C6 intervertebral foramina presented mild foraminal stenoses. C3 vertebra appeared hypoplastic and partially fused to C2 (Fig. 1). Dynamic X-rays did not show significant instability. MRI did not present any indication of spinal canal stenosis. 3D CT confirmed the presence of a C3 lateral hemivertebra (Fig. 2). Conservative treatment with physical therapy was the chosen therapeutic strategy. After 6 months, her clinical condition had been significantly improved.

Hemivertebra is a congenital failure in the formation and fusion of vertebral body ossification nuclei, resulting in the development of one side of the vertebral body. Its incidence is estimated at ~0.3 per 1000 live births [1].

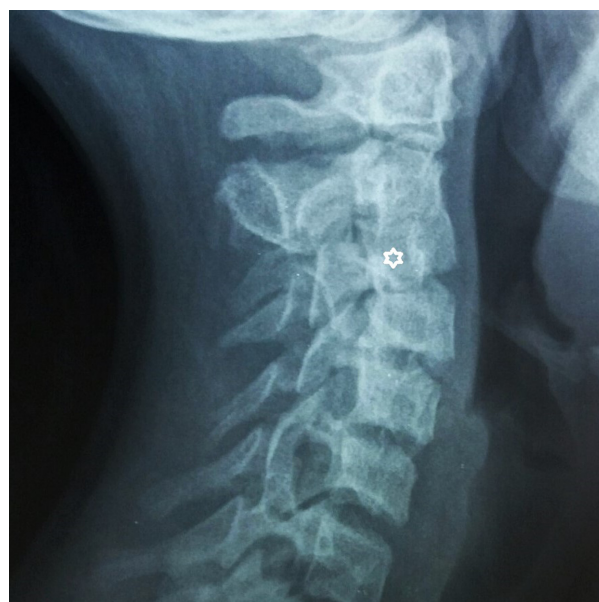

Figure 1. Static lateral X-ray of the cervical spine. The C3 hemivertebra is marked with a white asterisk.

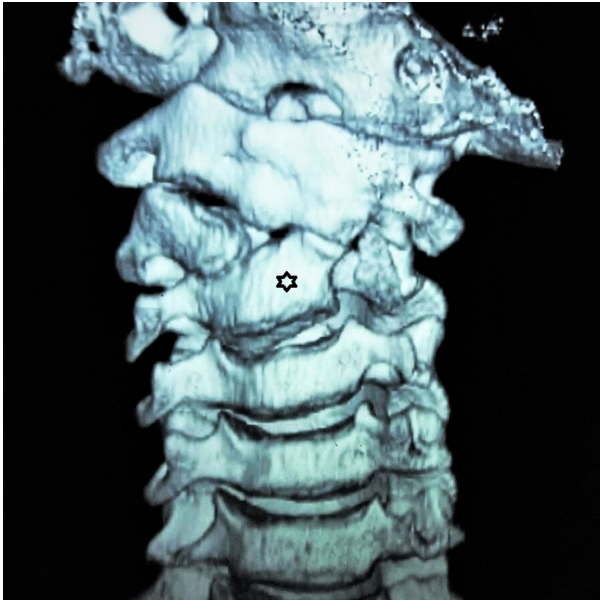


Figure 2. 3D CT reconstruction of the cervical spine. The C3 hemivertebra is marked with a black asterisk.

Hemivertebra of the cervical spine is even rarer and has been associated with cervical scoliosis and instability, neck pain, and torticollis [2].

Authorship

SK: designed and drafted the manuscript. GG: wrote the manuscript. EN: acquired all examination images and other pertinent patient data. VS: contributed to critical analysis of the submitted material.

Conflict of Interests

The authors have none to declare.

References

1. Goldstein, I., I. R. Makhoul, A. Weissman, and A. Drugan. 2005. Hemivertebra: prenatal diagnosis, incidence and characteristics. *Fetal Diagn. Ther.* 20:121–126.
2. Otero-López, R., M. Rivero-Garvía, J. Márquez-Rivas, and J. Valencia. 2016. Cervical subluxation associated with posterior cervical hemivertebra. *Childs Nerv. Syst.* 32:387–390.