

# A rare cause of myocardial infarction with non-obstructive coronary arteries—case report of ST-segment elevation myocardial infarction caused by a mediastinal mass

Ying X. Gue<sup>1</sup>, Majid Anwar<sup>1</sup>, and Diana A. Gorog<sup>1,2,3\*</sup>

<sup>1</sup>Cardiology Department, Lister Hospital, East and North Hertfordshire NHS Trust, Stevenage, UK; <sup>2</sup>Department of Postgraduate Medicine, University of Hertfordshire, Hertfordshire, UK; and <sup>3</sup>National Heart & Lung Institute, Imperial College, Dovehouse Street, London SW3 6LR, UK

Received 27 October 2017; accepted 6 January 2018; online publish-ahead-of-print 5 February 2018

## Introduction

ST-segment elevation myocardial infarction (STEMI) is attributable to an occluded coronary artery in almost 90% of patients. Accordingly, restoration of coronary perfusion as early as possible, preferably with primary percutaneous coronary intervention, is the recommended treatment by the European Society of Cardiology, to maximise myocardial salvage. However, not all cases of STEMI are because of coronary artery occlusion. ST-segment elevation myocardial infarction that occurs in the absence of obstructive coronary artery disease on angiography has been termed myocardial infarction with non-obstructive coronary arteries (MINOCA).

## Case presentation

A 44-year-old man was admitted with retrosternal chest pain radiating to the left arm and jaw, and electrocardiography showed extensive anterior ST-segment elevation. Emergency coronary angiography showed all three coronary arteries were patent with Thrombolysis in Myocardial Infarction-3 flow and no evidence of dissection or thrombus. The ST-elevation and pain resolved spontaneously. Troponin-T level rose from <3 ng/L on arrival to 549 ng/L at 12 h. Subsequent cardiac magnetic resonance imaging (MRI) showed a structurally normal heart (without late gadolinium enhancement) but detected an incidental large, lobulated (90 × 31 × 71 mm) mediastinal mass containing multiple cysts in the anterior mediastinum with inflammation and oedema of the parietal pericardium. Tissue biopsy confirmed Hodgkin's lymphoma and the patient was initiated on chemotherapy.

## Discussion

Some 3% of ST-segment myocardial infarctions occur in the absence of obstructive coronary disease (MINOCA), is more frequent in younger patients. Cardiac MRI is a useful tool to both identify some of the potential causes of MINOCA and also to confirm the diagnosis of infarction. Some 26% of MINOCA patients have significant biochemical evidence of myocardial injury but have a normal cardiac MRI. This case illustrates a very rare cause of myocardial infarction in a young patient with unobstructed coronary arteries, and highlights the need in such cases for further detailed imaging of the myocardium and thorax to establish the diagnosis and initiate appropriate treatment.

## Keywords

Case report • Myocardial infarction • ST-elevation • MINOCA • Lymphoma • Mediastinum

\*Corresponding author. Tel: +44(0)1707 247512, Email: [d.gorog@imperial.ac.uk](mailto:d.gorog@imperial.ac.uk). This article was peer reviewed by Klaus Distelmaier, Vijay Kunadian and Albert Galyavich.

© The Author(s) 2018. Published by Oxford University Press on behalf of the European Society of Cardiology.

This is an Open Access article distributed under the terms of the Creative Commons Attribution Non-Commercial License (<http://creativecommons.org/licenses/by-nc/4.0/>), which permits non-commercial re-use, distribution, and reproduction in any medium, provided the original work is properly cited. For commercial re-use, please contact [journals.permissions@oup.com](mailto:journals.permissions@oup.com)

## Learning points

- ST-segment elevation myocardial infarction can present without any angiographic evidence of coronary artery disease [myocardial infarction with non-obstructive coronary arteries (MINOCA)]
- MINOCA warrants further investigations including detailed imaging of the myocardium and thorax to establish diagnosis and initiate appropriate treatment.

## Introduction

ST-segment elevation myocardial infarction (STEMI) is attributable to an occluded coronary artery in almost 90% of patients. Accordingly, restoration of coronary artery perfusion as early as possible, preferably with primary percutaneous coronary intervention (PPCI), is the recommended treatment by the European Society of Cardiology (ESC), to maximise myocardial salvage.<sup>1</sup> However, not all cases of STEMI are because of coronary artery occlusion. ST-segment elevation myocardial infarction that occurs in the absence of obstructive coronary artery disease on angiography has been termed myocardial infarction with non-obstructive coronary arteries (MINOCA).<sup>1</sup> In this case, we demonstrate a highly unusual cause of STEMI, where myocardial infarction (reduction in blood flow to cardiac myocytes) associated with typical electrocardiography (ECG) changes (ST-segment elevation) and troponin rise occurs due to a different underlying pathomechanism of infarction, and in the absence of obstructive coronary disease. It highlights the importance of thorough and systematic use of investigations to reach a definite diagnosis.

## Timeline

Upon presentation	Admission as PPCI Coronary angiogram showing no significant obstructive lesion
48 hours after presentation	Discharged with outpatient follow up
8 weeks post discharge	Cardiac MR was performed revealing mediastinal mass Seen in clinic
10 weeks post discharge	CT scan confirms mediastinal mass and lymph node involvement Referred to Haematology
12 weeks post discharge	Biopsy confirms Hodgkin's Lymphoma and initiated on chemotherapy

## Case presentation

A 44-year-old man without any past medical history or cardiac risk factors presented with retrosternal chest pain radiating to the left arm and jaw. An ECG performed by the paramedic ambulance crew

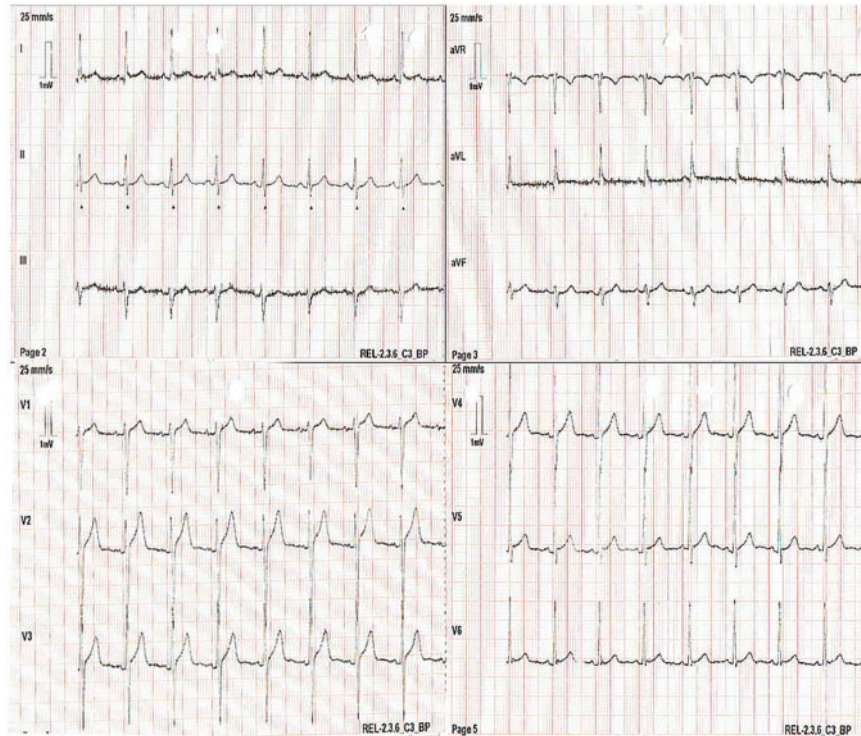
showed sinus rhythm with hyper-acute T-waves in the anterior leads with borderline ST-segment elevation (*Figure 1*). On further questioning, the patient denied any chest pain symptoms prior to presentation. Suspected as having an evolving STEMI, the PPCI pathway was activated, in line with the 2017 ESC guidelines on management of ST-elevation myocardial infarction (MI),<sup>2</sup> and the patient was transferred as an emergency to the cardiac catheterisation laboratory of our heart attack centre.

On arrival, the patient was haemodynamically stable and the chest pain had subsided to 1/10 in severity. Systemic examination was unremarkable. The patient was afebrile, with a heart rate of 90 b.p.m., with a blood pressure of 110/72 mmHg and venous pressure was not elevated. Cardiovascular examination was normal with an undisplaced apex beat, normal heart sounds, no murmurs or pericardial rub, and normal breath sounds on auscultation.

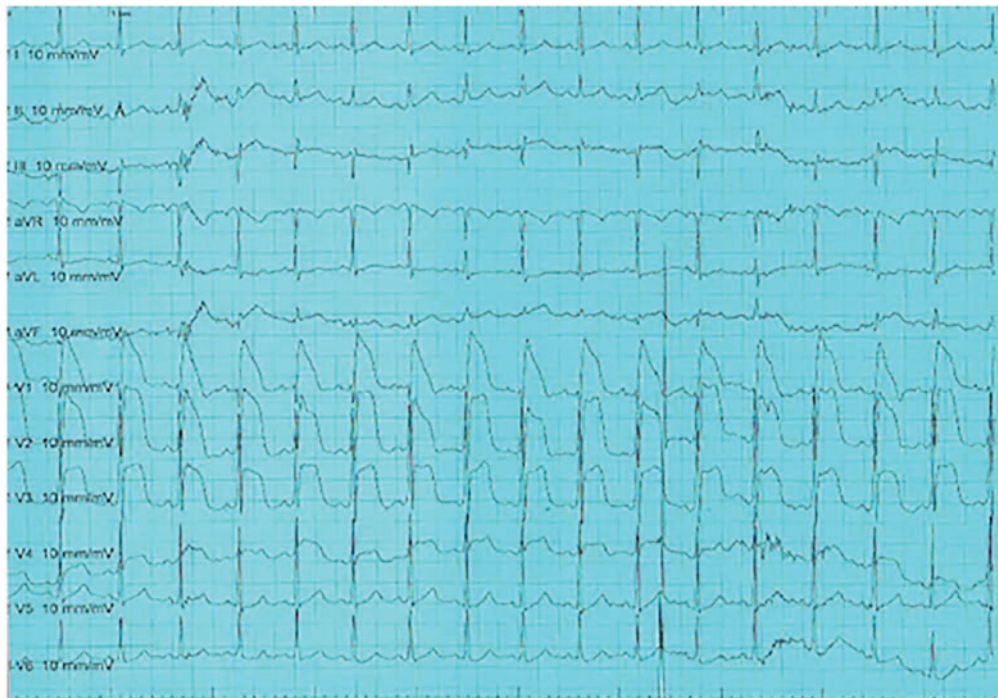
Subsequently, there was recurrence of severe chest pain and profound anterior ST-segment elevation (*Figure 2*). Emergency coronary angiography showed unobstructed coronary arteries (*Figure 3*). Emergency coronary angiogram showed all three coronary arteries were patent with Thrombolysis in Myocardial infarction-3 flow and there was no evidence of dissection or thrombus. The ST-elevation and pain resolved spontaneously over the next 15 min (*Figure 4*). On-table echocardiography showed no evidence of pericardial effusion or any ventricular regional wall motion abnormality. Troponin-T level rose from <3 ng/L on arrival to 549 ng/L at 12 h. Blood results were as follows: haemoglobin 139 g/L (130–170 g/L), white cell count  $12.9 \times 10^9/L$  ( $4-11 \times 10^9/L$ ) (differential count of 73% neutrophils, 17% lymphocytes, 7% monocytes, 2% eosinophils, and 1% basophils), platelet count  $302 \times 10^9/L$  ( $150-400 \times 10^9/L$ ), C-reactive protein 83 mg/L (0–5 mg/L), prothrombin time 13.5 s (9–12 s), activated partial thromboplastin time 40.4 s (23–31 s), lactate 1.4 mmol/L (0.6–2.5 mmol/L), urea 3.2 mmol/L (2.5–7.8 mmol/L), creatinine 55  $\mu\text{mol/L}$  (59–104  $\mu\text{mol/L}$ ), eGFR >90 mL/min sodium 138 mmol/L (133–146 mmol/L), potassium 4.4 mmol/L (3.5–5.3 mmol/L), bilirubin 5  $\mu\text{mol/L}$  (0–21  $\mu\text{mol/L}$ ), alanine transaminase 17 U/L (7–40 U/L), alkaline phosphatase 132 U/L (30–130 U/L), and albumin 42 g/L (35–50 g/L).

The patient was transferred to the cardiac ward and managed as a possible acute coronary syndrome or coronary artery spasm and initiated on dual anti-platelet therapy with aspirin 75 mg o.d., ticagrelor 90 mg b.i.d., diltiazem 90 mg b.i.d. and atorvastatin 20 mg o.d. Transthoracic echocardiography was normal, with normal left ventricle size and function, and no evidence of regional wall motion abnormality. He was discharged after 48 hours of monitoring, after he remained stable and symptom free.

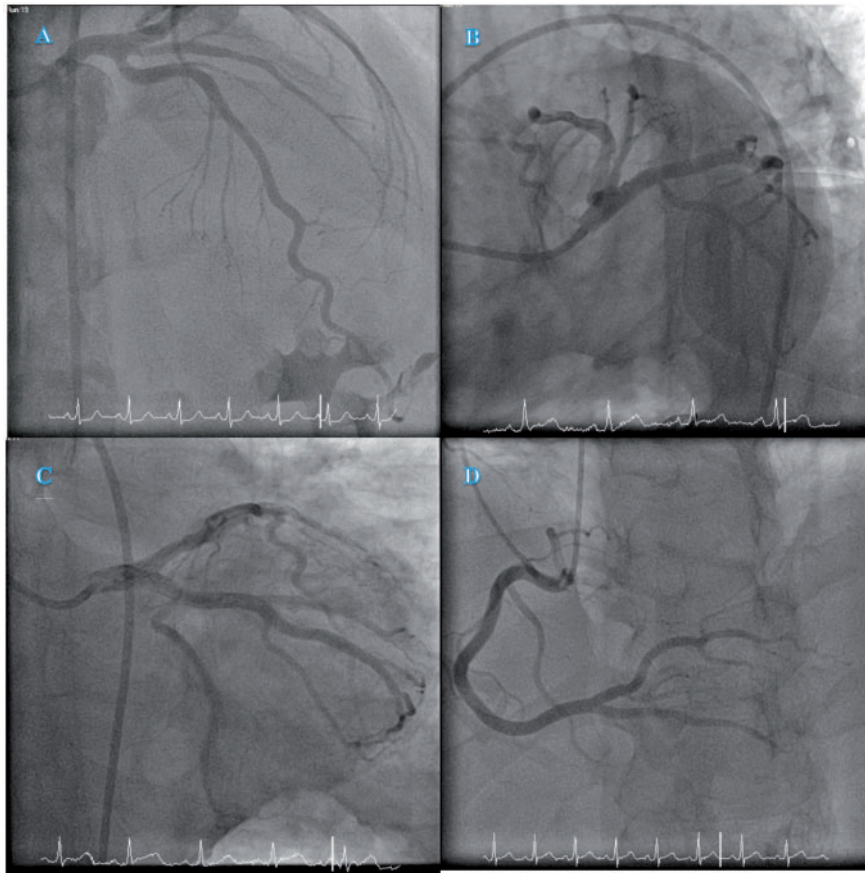
Given that there was no evidence of coronary artery disease on angiography to explain the reason for the acute coronary syndrome, a cardiac magnetic resonance imaging (MRI) scan was requested, to look for evidence of MI, fibrosis, or inflammation such as myocarditis. An outpatient cardiac MRI showed a structurally normal heart but detected an incidental large mediastinal mass (*Figure 5*), measuring 90 mm × 31 mm × 74 mm that was lobulated, containing multiple cysts. The mass abutted, but did not invade, the great vessels in the anterior mediastinum. Inflammation and oedema of the parietal pericardium was observed anterior to the right ventricle confluent with some of the mass. There was no myocardial late gadolinium



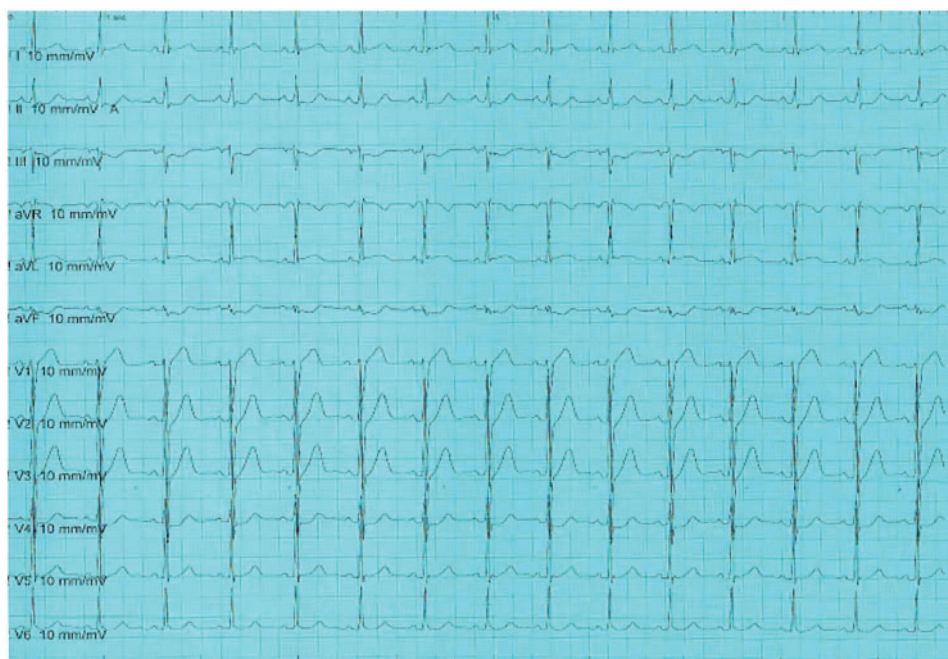
**Figure 1** Electrocardiography obtained by ambulance paramedics showing hyperacute T-waves with mild upsloping ST-segment elevation in the anterior leads.



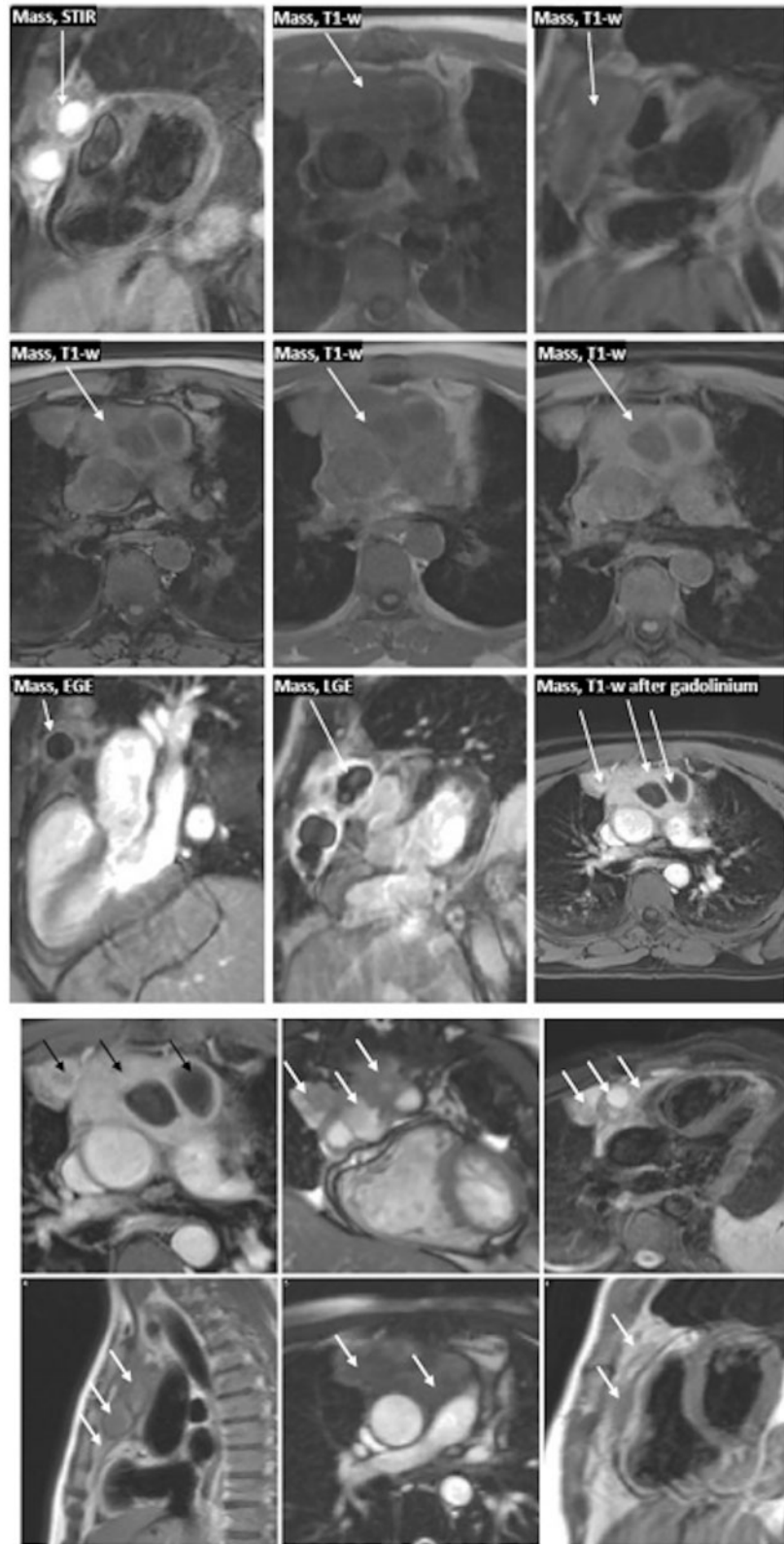
**Figure 2** Electrocardiography showing profound anterior ST-segment elevation.



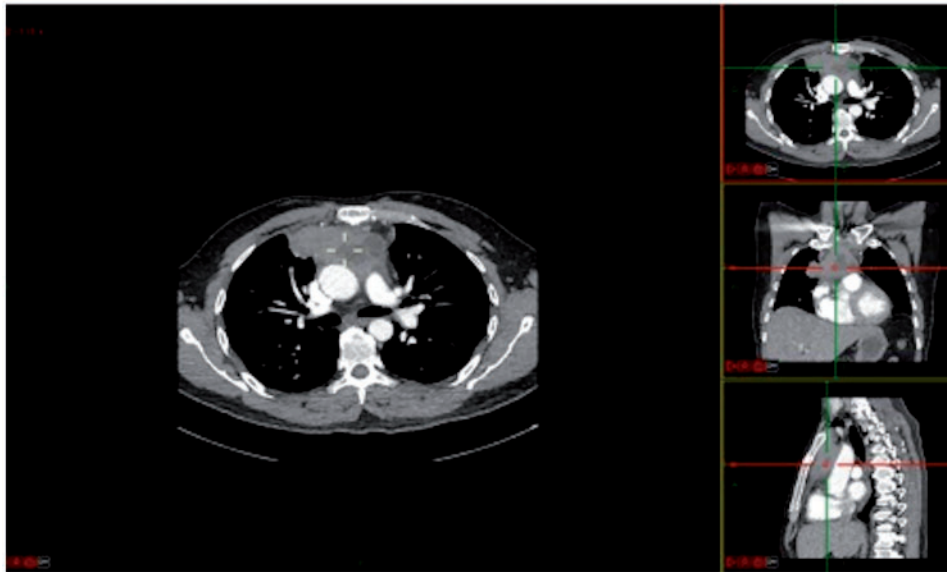
**Figure 3** Angiogram showing unobstructed coronary arteries. (A) RAO cranial view of the left coronary system. (B) LAO caudal view of left coronary system. (C) PA caudal view of left coronary system. (D) LAO view of right coronary artery.



**Figure 4** Electrocardiography showing spontaneous resolution of ST changes.



**Figure 5** Cardiac magnetic resonance imaging showing large, lobulated, and cystic anterior mediastinal mass (arrows).



**Figure 6** Computed tomography scan showing anterior mediastinal mass.

enhancement. The patient was reviewed in clinic where dual antiplatelet therapy was stopped and a chest computed tomography (CT) scan was arranged.

The chest CT scan was requested to better characterize the lesion. This showed a poorly defined anterior mediastinal mass with cystic areas with large area of contact with the great vessels and infiltrating between the ascending aorta and main pulmonary artery (Figure 6). Adjacent abnormal lymph nodes were also present. Tissue biopsy confirmed Hodgkin's lymphoma and the patient was initiated on chemotherapy (Adriamycin, Bleomycin, Vinblastine and Dacarbazine, or ABVD regime). The patient was seen following five cycles of chemotherapy, 7 months following the index event and was responding well to the chemotherapy with no further symptoms of chest pain.

## Discussion

The triad of symptoms of myocardial ischaemia, dynamic ST-segment elevation and rise in troponin, fits the Third Universal definition of MI as published by the *European Heart Journal*.<sup>3</sup> Given the absence of angiographic evidence of coronary artery disease, this case fits the diagnostic criteria of MINOCA<sup>1</sup> which is characterized by the diagnosis of acute MI without evidence of obstructive coronary disease on angiography and no clinically apparent cause for presentation. The ESC has defined MINOCA as a working diagnosis that should lead the treating physician to investigate underlying causes.

Myocardial infarction in the absence of obstructive coronary disease is an uncommon but well documented phenomenon. It has a prevalence of about 3%, but this varies depending on age (more common in younger patients).<sup>4</sup> Potential causes include coronary artery spasm, emboli, myocardial oxygen demand-supply disproportion, coronary artery vasculitis, radiation associated fibrosis, cocaine abuse,

external compression,<sup>5–8</sup> and non-cardiac pathology such as subarachnoid haemorrhage<sup>9</sup> and acute pancreatitis.<sup>10</sup> Cardiac MRI is a useful tool as it can identify some of these potential causes and also confirm the diagnosis of infarction. However, there remains a small group of MINOCA patients with evidence of significant biochemical evidence of myocardial injury but who have a normal cardiac MRI, without evidence of subendocardial scarring, myocardial oedema, wall motion abnormalities or myocarditis.<sup>11</sup> Some 26% of MINOCA patients fall into this category.<sup>12</sup>

This patient's chest pain with ST-segment elevation on the ECG and a significant rise in troponin-T was likely to be secondary to external compression of the heart by the mediastinal mass. External compression of coronary arteries can be caused by muscle bridging, sinus of Valsalva aneurysms and neoplasms.<sup>13</sup> External compression of the myocardium and pericardium can also lead to pain, ECG changes, and a rise in troponin. Most neoplasms that are responsible for MI relate to metastatic deposits to the heart (e.g. lung, breast, and thymoma), whereas primary cardiac tumours are extremely rare. In this case, the neoplastic mediastinal mass did not physically infiltrate the heart or pericardium, which is the usual mechanism that has been described when tumours lead to MI due to compression of the coronaries.<sup>14–16</sup> Understandably, this often has a very poor prognosis with the full extent of tumour involvement not recognised until autopsy.

Other possible mechanisms of MI in this patient's case include arterial thrombosis due to a prothrombotic state, or indeed coronary artery spasm. A meta-analysis has shown that 9% of thrombotic complications in patients with lymphoma are acute MIs.<sup>17</sup> However, the absence of thrombus during angiography in the presence of symptoms and ECG changes, and the presence of the compressive mass, makes it less likely. Furthermore, in the aforementioned meta-

analysis, only 9% of all thrombotic complications were due to MI, with 85% of thrombotic complications in patients with lymphoma being attributable to venous thrombosis, with 95% of events occurring during treatment, 3.8% at presentation of the disease, before initiating chemotherapy, and only 1.2% after completion of the treatment, with the highest grade lymphoma patients being most at risk of thrombotic complications.

This case illustrates a very rare cause of MI in a young patient with unobstructed coronary arteries, and highlights the need in such cases for further detailed imaging of the myocardium and thorax to establish the diagnosis and initiate appropriate treatment.

**Consent:** The author/s confirm that written consent for submission and publication of this case report including image(s) and associated text has been obtained from the patient in line with COPE guidance.

**Conflicts of interest:** none declared.

## References

- Agewall S, Beltrame JF, Reynolds HR, Niessner A, Rosano G, Caforio ALP, De Caterina R, Zimarino M, Roffi M, Kjeldsen K, Atar D, Kaski J, Sechtem U, Tornvall P. ESC working group position paper on myocardial infarction with non-obstructive coronary arteries. *Eur Heart J* 2016;**38**:ehw149.
- Ibanez B, James S, Agewall S, Antunes MJ, Bucciarelli-Ducci C, Bueno H, Caforio A, Crea F, Goudevenos J, Halvorsen S, Hindricks G, Kastrati A, Lenzen M, Valgimigli M, Varenhorst C, Vranckx P, Widimsky P. 2017 ESC guidelines for the management of acute myocardial infarction in patients presenting with ST-segment elevation. *Eur Heart J* 2017; doi:10.1093/eurheartj/ehx393.
- Thygesen K, Alpert JS, Jaffe AS, Simoons ML, Chaitman BR, White HD, Thygesen K, Alpert JS, White HD, Jaffe AS, Katus HA, Apple FS, Lindahl B, Morrow DA, Chaitman BR, Clemmensen PM, Johanson P, Hod H, Underwood R, Bax JJ, Bonow RO, Pinto F, Gibbons RJ, Fox KA, Atar D, Newby LK, Galvani M, Hamm CW, Uretsky BF, Gabriel Steg P, Wijns W, Bassand J-P, Menasche P, Ravkilde J, Ohman EM, Antman EM, Wallentin LC, Armstrong PW, Simoons ML, Januzzi JL, Nieminen MS, Gheorghiade M, Filippatos G, Luepker RV, Fortmann SP, Rosamond WD, Levy D, Wood D, Smith SC, Hu D, Lopez-Sendon J-L, Robertson RM, Weaver D, Tendera M, Bove AA, Parkhomenko AN, Vasilieva EJ, Mendis S, Bax JJ, Baumgartner H, Ceconi C, Dean V, Deaton C, Fagard R, Funck-Brentano C, Hasdai D, Hoes A, Kirchhof P, Knuuti J, Kolh P, McDonagh T, Moulin C, Popescu BA, Reiner Z, Sechtem U, Sirnes PA, Tendera M, Torbicki A, Vahanian A, Windecker S, Morais J, Aguiar C, Almahmeed W, Amar DO, Barili F, Bloch KD, Bolger AF, Botker HE, Bozkurt B, Bugiardini R, Cannon C, de Lemos J, Eberli FR, Escobar E, Hlatky M, James S, Kern KB, Moliterno DJ, Mueller C, Neskovic AN, Pieske BM, Schulman SP, Storey RF, Taubert KA, Vranckx P, Wagner DR. Third universal definition of myocardial infarction. *Eur Heart J* 2012;**33**:2551–2567.
- Da Costa A, Isaz K, Faure E, Mourou S, Cerisier A, Lamaud M. Clinical characteristics, aetiological factors and long-term prognosis of myocardial infarction with an absolutely normal coronary angiogram; a 3-year follow-up study of 91 patients. *Eur Heart J* 2001;**22**:1459–1465.
- Waller B, Waller BF, Fry ETA, Hermiller JB, Peters T, Slack JD. Nonatherosclerotic causes of coronary artery narrowing—Part II. *Clin Cardiol* 1996;**19**:587–591.
- Lang NN, Newby DE. Cardiac compression causing fatal acute ST-segment elevation myocardial infarction. *QJM* 2012;**105**:883–885.
- Gard JJ, Bader W, Enriquez-Sarano M, Frye RL, Michelena HI. Uncommon cause of ST elevation. *Circulation* 2011;**123**:e259–e261.
- Wang K, Asinger RV, Marriott HJL. ST-segment elevation in conditions other than acute myocardial infarction. *N Engl J Med* 2003;**349**:2128–2135.
- Gu YL, Svilaas T, van der Horst ICC, Zijlstra F. Conditions mimicking acute ST-segment elevation myocardial infarction in patients referred for primary percutaneous coronary intervention. *Neth Heart J* 2008;**16**:325–331.
- Hung SC, Chiang CE, Chen JD, Ding PY. Pseudo-myocardial infarction. *Circulation* 2000;**101**:2989–2990.
- Camastra GS, Sbarbati S, Danti M, Cacciotti L, Semeraro R, Della Sala SW, Ansalone G. Cardiac magnetic resonance in patients with acute cardiac injury and unobstructed coronary arteries. *World J Radiol* 2017;**9**:280–286.
- Pasupathy S, Air T, Dreyer RP, Tavella R, Beltrame JF. Systematic review of patients presenting with suspected myocardial infarction and nonobstructive coronary arteries. *Circulation* 2015;**131**:861–870.
- Waller BF, Fry ETA, Hermiller JB, Peters T, Slack JD. Nonatherosclerotic causes of coronary artery narrowing—Part III. *Clin Cardiol* 1996;**19**:656–661.
- Das A, Das SK, Pandit S, Karmakar RN. Bronchogenic carcinoma with cardiac invasion simulating acute myocardial infarction. *Case Rep Oncol Med* 2016;**2016**:1–4.
- Ozaki T, Chiba S, Annen K, Kawamukai Y, Kohno N, Horimoto M. Acute coronary syndrome due to coronary artery compression by a metastatic cardiac tumor. *J Cardiol Cases* 2010;**1**:e52–e55.
- Raju P, Nair R, Kaid K. Invasive thymoma causing acute ST-segment elevation myocardial infarction. *Chest* 2008;**134**:1C.
- Caruso V, Di Castelnuovo A, Meschengieser S, Lazzari MA, de Gaetano G, Storti S, Iacoviello L, Donati MB. Thrombotic complications in adult patients with lymphoma: a meta-analysis of 29 independent cohorts including 18 018 patients and 1149 events. *Blood* 2010;**115**:5322–5328.