



Catamenial hemoptysis: A case report of pulmonary endometriosis

Nour Aboujaoude ^{a,*}, Maria Iskandar ^{a,1}, Fadi Tannouri ^{b,2}

^a Department of Radiology, Notre Dame des Secours CHU, Byblos, Lebanon

^b Department of Radiology, Hospital Erasme, Brussels, Belgium

ARTICLE INFO

Keywords:

Thoracic endometrial syndrome
Pulmonary endometriosis
Catamenial hemoptysis
Computed tomography
Menstrual cycle

ABSTRACT

We report a case of a patient diagnosed with pulmonary endometriosis and successfully treated with a GnRH agonist. This 34-year-old mother presented cyclic hemoptysis since 4-month. A non-enhanced computed tomography made at the end of the luteal phase revealed a solitary lung nodule with no other abnormalities. A contrast enhanced computed tomography conducted during menses revealed a ground glass opacity extending from the nodule towards hilum. The diagnosis of pulmonary endometriosis was established taking into account the clinical presentation and the imaging findings. Medical treatment by Triptorelin pamoate (Decapeptyl LP® 3 mg Ipsen Pharma, France), a GnRH agonist, was proposed for a period of 6 months. A CT scan performed 3 months after the end of the treatment shows a complete disappearance of the endometriosis nodular lesion.

1. Introduction

Thoracic endometrial syndrome (TES) is a group of clinical entities including implantation pulmonary, pleural and diaphragmatic endometrial-like tissue [1]. It is a rare disease with unclear causes and pathogenesis affecting 2–10% of women [2]. This case is being reported to provide imaging literature regarding such a rare disease and alert clinicians on the non-necessity of an invasive thoracic biopsy in such patients. The diagnosis can be made based on the cyclic clinical symptoms, the patient's anamnesis, history of pelvic endometriosis, and catamenial changes noticed on computer tomography during menstruation.

2. Case report

A 34-year-old, mother of 3 children, was referred to our imaging department after 4-month history of cyclic hemoptysis, beginning on the 2nd or 3rd day of menstrual cycle and lasting 3 days.

The patient was known to have pelvic endometriosis for which she underwent surgery 10 years ago with no recurrence since. She denied any thoracic pain, fever, night sweats or respiratory distress. She was a non-smoker with up-to-date vaccination status. Her physical

examination was unremarkable.

A HRCT (Fig. 1) was performed on presentation with the following parameters: Axial acquisition on GE Optima™ CT660, 5mAs, 120 kV, 1.25 mm slice thickness and MPR reconstructions on thin sliced in parenchymal coronal and sagittal views.

At the moment of the examination, the patient was at the end of her luteal phase, and she had no hemoptysis. CT showed a posterior segment right upper lobe (RUL), sub-pleural solitary nodule of 6.6 mm of diameter, of soft tissue density and with well-defined margins. No mediastinal, hilar or axillary lymphadenopathies were noted and no other abnormal finding.

The patient returned for another examination 4 days later, on the 2nd day of menses. She was suffering from hemoptysis and pelvic pain. Pelvis was shielded during both examinations. The following parameters were used: Axial acquisition obtained during arterial phase, on GE Optima™ CT660, 4mAs, 100 kV, 2.5 mm slice thickness with 100 ml Omnipaque™ (Iohexol) 350 contrast media injected intravenously and MPR reconstructions on thin slices in parenchymal coronal and sagittal views. CT (Fig. 2) revealed a hyperdense ill-defined ground glass opacity extending from the posterior segment of the right upper lobe nodular lesion to the hilum, highly suggestive of pulmonary hemorrhage.

The agreement was made on a pulmonary endometriosis without

Abbreviations: GnRH, gonadotropin-releasing hormone; CT, computed tomography; HRCT, high resolution computed tomography; CECT, contrast enhanced computed tomography; TES, thoracic endometriosis syndrome.

* Corresponding author.

E-mail addresses: nour.aj@hotmail.com (N. Aboujaoude), skandarmaria@hotmail.com (M. Iskandar), faditannouri@gmail.com (F. Tannouri).

¹ Postal Mail: Service d'imagerie médicale, Rue 93, Hôpital Notre Dame des Secours, Jbeil, Mont-Liban, Liban.

² Postal Mail: Service d'imagerie médicale, Route de Lennik 808, 1070 Bruxelles, Belgium.

<https://doi.org/10.1016/j.ejro.2020.100302>

Received 18 November 2020; Received in revised form 28 November 2020; Accepted 30 November 2020

2352-0477/© 2020 The Author(s). Published by Elsevier Ltd. This is an open access article under the CC BY-NC-ND license

(<http://creativecommons.org/licenses/by-nc-nd/4.0/>).

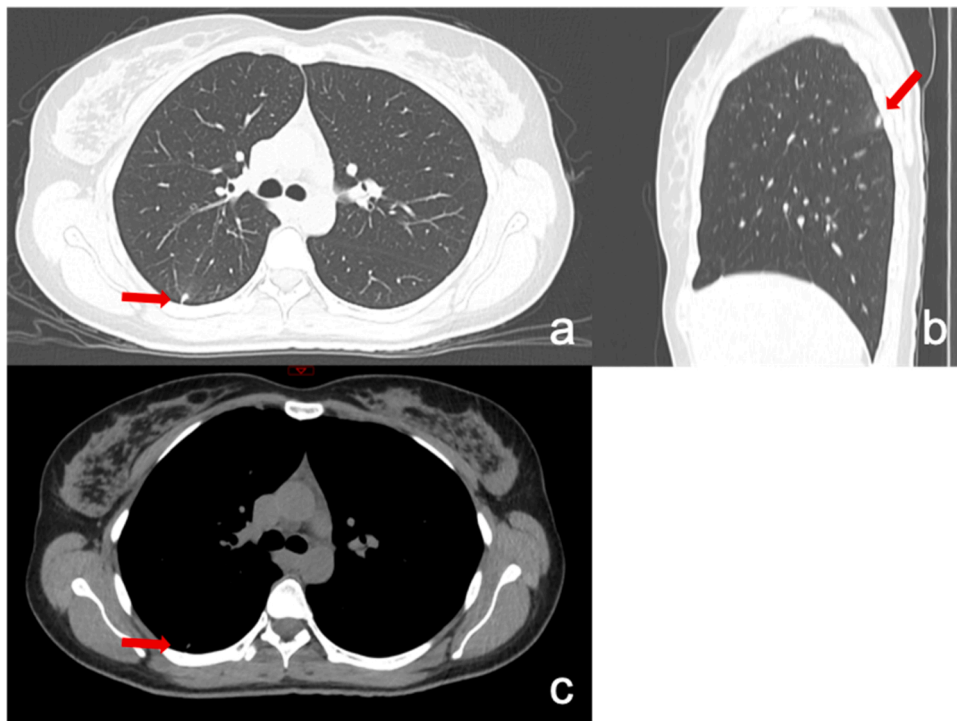


Fig. 1. HRCT realised on presentation, few days prior to menstruation, showing a posterior RUL nodule (red arrow) on axial parenchymal view (a), reconstructed sagittal parenchymal vies (b). The nodule is of soft tissue density on mediastinal view (c).

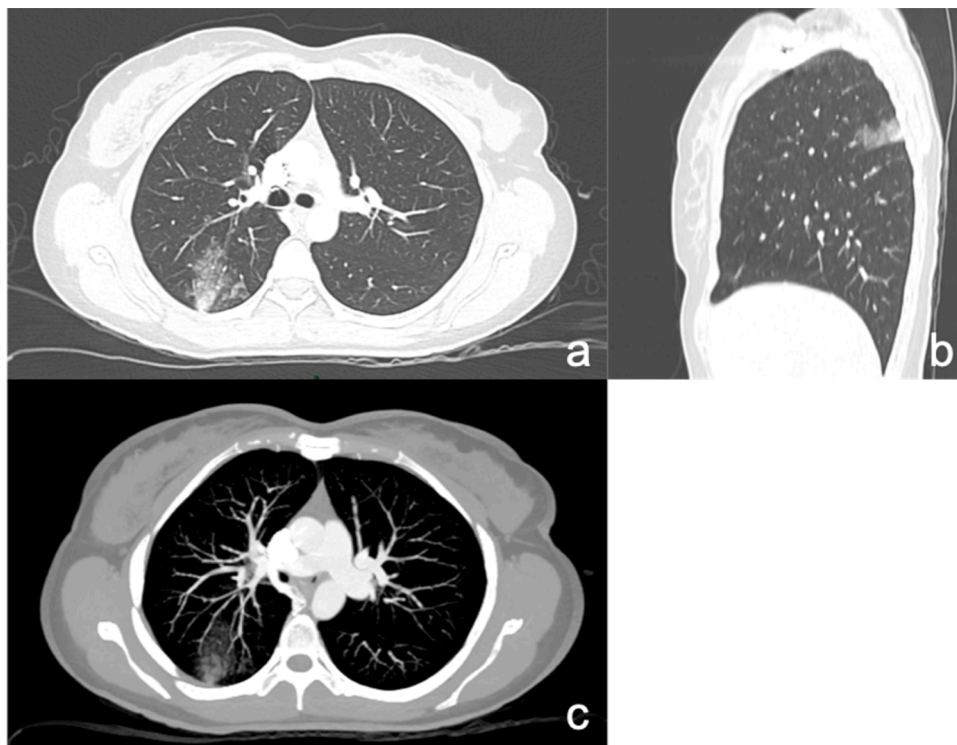


Fig. 2. CE-CT showing a hyperdense ground glass opacity extending from the posterior RUL nodule on axial parenchymal view (a), MPR sagittal parenchymal reconstruction (b) and MIP view (c).

conduction of other examinations and medical treatment was started. Triptorelin pamoate (Decapeptyl LP® - 3 mg Ipsen Pharma, France) was administered intramuscularly every month for a duration of 6 months. Starting the first dose, menses were interrupted and there were no pulmonary symptoms. The patient denied any side effect.

Three months after the end of treatment, the patient came back for a CT scan (Fig. 3) showing the total disappearance of the solitary sub-pleural endometriosis nodule. No recurrence of hemoptysis was noted until the end of our 10 months follow-up.

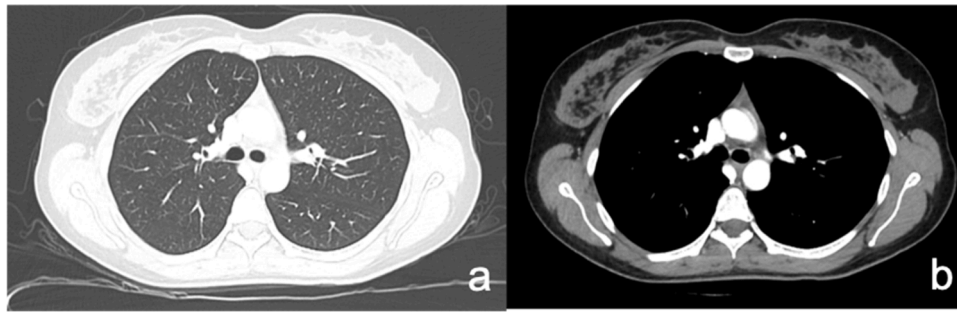


Fig. 3. CECT realised 3 months after the end of treatment showing the complete disappearance of the sub-pleural RUL nodule on axial parenchymal (a) and mediastina (b) views.

3. Discussion

Thoracic endometriosis syndrome (TES) is a group of clinical entities [3] all characterized by the presence of endometrial-like tissue in the bronchial tree, pulmonary tissue, pleura or diaphragm [4]: the most common being catamenial pneumothorax, followed by catamenial hemothorax, hemoptysis, and lung nodules. Pleural implantation is by far the most common but in the case of pulmonary endometriosis, however, catamenial hemoptysis is more frequent than pneumothorax [1].

Lung nodules is the least common entity found in thoracic endometriosis, accounting only for 6% of TE [5] whereas on the other hand, it is a very common CT finding accounting for 13 % of chest CT exams, with a long list of differential diagnosis [6]. TES should always be included in our differential diagnosis in any reproductive age woman with symptoms such as chest pain, scapular pain, cough, hemoptysis or dyspnea exacerbating during menses [7] even more so with a history of pelvic endometriosis that is known to be associated with TES in 53 % of the cases with a mean time lapse of 5 years [1] and with the thorax being the most frequent extra-pelvic endometrial implantation site [8].

Computer tomography, although non-specific, is nowadays considered the modality of choice for localization and characterization of thoracic endometrial lesions [9]. Chest CT performed during menses revealing parenchymal ground glass opacity, with or without nodules [10], in presence of characteristic history and clinical symptoms, is considered diagnostic of pulmonary endometriosis.

Distant spread of endometrial cells is still not fully established but it is explained by hypothesis of venous or lymphatic circulation. Right lobe is believed to be due to a more extensive lymphatic drainage on the right side of the diaphragm [5].

Once pulmonary endometriosis is suspected, a chest CT during menses revealing pulmonary hemorrhage and the catamenial changes compared to the sequences outside of menses. Chest CT realized after menstrual period helps characterize the nodular lesion and show the complete resolution of pulmonary hemorrhage, an essential criteria for the diagnosis [11].

In our case, diagnosis was established based on these findings and treatment was initiated without any other investigation.

Magnetic resonance imaging MRI, even though considered superior to CT [9] was not performed in our patient, nor bronchoscopic lavage considered too invasive.

Medical treatment was first considered with triptorelin pamoate, a GnRH agonist, for a duration of 6 months. Gonadotropin releasing hormone agonist are prescribed as first line treatment and considered as the most effective in suppressing the hypothalamic-pituitary-ovarian axis with numerous alternatives available without any superiority proved among them in the literature [4].

3 months after the end of treatment, a CECT shows the total disappearance of the endometriosis nodular lesion. There was no recurrence of symptoms until the end of the 9 months follow up.

We did not undergo any further intervention, but in case of severe

hemoptysis, bronchial artery embolization could be an alternative treatment. Surgery is reserved for severe cases in which conservative treatment fails or in women with multiple recurrences [12].

4. Conclusion

Clinical history, catamenial symptoms and suggestive findings on computer tomography can be sufficient for pulmonary endometriosis diagnosis. Catamenial changes visualized on CT during menses compared to sequences outside menses help confirm the diagnosis when in doubt. Medical treatment is to be considered first with complete remission in some cases.

Authors' contributions

Nour Abou Jaoude: Currently PGY2 in diagnostic radiology at Notre Dame des Secours CHU, I am the author of the article and was rotating in thoracic imaging at the time of this patient's diagnosis. I followed up with the patient by phone call every 2 months and was present at all the CT examination, taking the clinical history and examining the patient.

Maria Iskandar: Fellow resident at Notre Dame des Secours CHU. She contributed to the diagnosis and follow up of the patient.

Fadi Tannouri: Currently working as head of vascular and interventional unit in Hospital Erasme in Brussels. He was head of Interventional unit and cardio-thoracic imaging at Notre Dame des Secours CHU at the time of the diagnosis that he established. He supervised the work.

Funding statement

There has been no financial support for this work that could have influenced its outcome.

Ethical statement

Written informed consent was obtained from the patient.

All identifying information have been removed and CT images were entirely anonymized.

Declaration of Competing Interest

The authors report no declarations of interest.

References

- [1] M.P. Andres, F.V.L. Arcoverde, C.C.C. Souza, L.F.C. Fernandes, M. Sim, R.M. Kho, Extrapelvic endometriosis: a systematic review, *J. Minim. Invasive Gynecol.* (2020), <https://doi.org/10.1016/j.jmig.2019.10.004>.
- [2] G.A.J. Dunselman, N. Vermeulen, C. Becker, et al., ESHRE guideline: management of women with endometriosis, *Hum. Reprod.* 29 (3) (2014) 400–412, <https://doi.org/10.1093/humrep/det457>.
- [3] A. Bobbio, E. Canny, A.M. Lupo, et al., Thoracic endometriosis syndrome other than pneumothorax: clinical and pathological findings, *Ann. Thorac. Surg.* (2017), <https://doi.org/10.1016/j.athoracsur.2017.06.049>.

- [4] C. Nezhat, S.R. Lindheim, L. Backhus, et al., Thoracic endometriosis syndrome: a review of diagnosis and management, *JSL J. Soc. Laparoendosc. Surg.* 23 (3) (2019), <https://doi.org/10.4293/JSL.2019.00029>.
- [5] J. Joseph, S.A. Sahn, Thoracic endometriosis syndrome: new observations from an analysis of 110 cases, *Am. J. Med.* 100 (2) (1996) 164–170, [https://doi.org/10.1016/S0002-9343\(97\)89454-5](https://doi.org/10.1016/S0002-9343(97)89454-5).
- [6] M.E.J. Callister, D.R. Baldwin, A.R. Akram, et al., British Thoracic Society guidelines for the investigation and management of pulmonary nodules, *Thorax* 70 Suppl 2 (Suppl 2) (2015) ii1–ii54, <https://doi.org/10.1136/thoraxjnl-2015-207168>.
- [7] S.M. Hwang, C.W. Lee, B.S. Lee, J.H. Park, Clinical features of thoracic endometriosis: a single center analysis, *Obstet. Gynecol. Sci.* 58 (3) (2015) 223, <https://doi.org/10.5468/ogs.2015.58.3.223>.
- [8] L.P. Chamié, D.M.F.R. Ribeiro, D.A. Tiferes, A.C. de Macedo Neto, P.C. Serafini, Atypical sites of deeply infiltrative endometriosis: clinical characteristics and imaging findings, *RadioGraphics* 38 (1) (2018) 309–328, <https://doi.org/10.1148/rg.2018170093>.
- [9] P. Rousset, C. Rousset-jablonski, M. Alifano, A. Mansuet-lupo, B. Lyon, Thoracic endometriosis syndrome: CT and MRI features, *Clin. Radiol.* 69 (3) (2014) 323–330, <https://doi.org/10.1016/j.crad.2013.10.014>.
- [10] E. Exhibit, Nodular ground-glass opacity at thin-section CT: histologic correlation and evaluation of change at follow-up, *Radiographics* (2007) 391–409.
- [11] S.Y. Chung, S.J. Kim, T.H. Kim, et al., Computed tomography findings of pathologically confirmed pulmonary parenchymal endometriosis, *J. Comput. Assist. Tomogr.* 29 (6) (2005) 815–818, <https://doi.org/10.1097/01.rct.0000176014.37051.c7>.
- [12] Y. Gil, T. Tulandi, Diagnosis and treatment of catamenial pneumothorax: a systematic review, *J. Minim. Invasive Gynecol.* (2020), <https://doi.org/10.1016/j.jmig.2019.08.005>.