




Extrapulmonary tuberculosis and COVID-19 infection coexisting in concurrent necrotising fasciitis with deep space infection of neck: an unusual presentation

Subham S Agarwal ¹, Hafiz Md Nasimuddin Ansari,¹ Santhosh Rao ¹, Virat Galhotra ²

¹Dentistry—Oral & Maxillofacial Surgery, All India Institute of Medical Sciences, Raipur, Chhattisgarh, India

²Dentistry, All India Institute of Medical Sciences, Raipur, Chhattisgarh, India

Correspondence to

Dr Santhosh Rao;
santhosh@aiimsraipur.edu.in

Accepted 3 June 2022

SUMMARY

Ludwig's angina is a rapidly spreading, potentially fatal infection of deep fascial spaces of the neck leading to airway oedema and death. This, in recent times when associated with COVID-19 infection, possess treatment challenges making the patient susceptible to opportunistic infections with reduced healing potential. Owing to the multifactorial aetiology in our case and addressing them at the earliest, it is important to achieve favourable outcomes. The space infection that seeded with untreated trivial dental caries progressed to necrotising fasciitis of neck with mycobacterial growth on cartridge-based nucleic acid amplification test for tuberculosis testing. The presence of *Mycobacterium* organisms should be speculated in patients with pulmonary signs of tuberculosis (TB) because a suppurative TB lymphadenitis of neck could also have the same presentation. The decisive moment in successful outcome was identification of mycobacteria in COVID-19 infected patient, thereby allowing to initiate the antitubercular therapy along with surgical debridement. Thus, medical management of patient with cohabiting infections is difficult task and needs appropriate addressal.

BACKGROUND

This case emphasises the significance of considering multiple aetiologies in necrotising fasciitis of neck. Although the disease started with one aetiology, it progressed to a more destructive form due to different additive cause. In recent times, a third factor like COVID-19 infection altering the immune response could also add to the morbidity and can hamper healing.

CASE PRESENTATION

A man in his 60s presented to emergency room with a chief complaint of neck swelling and tooth ache. It was associated with a history of lancinating intermittent pain of the lower left tooth for over a week. Patient had sought medical care for his problem and was started on broad-spectrum antibiotics. History of topical application of hot medicinal oil over the swollen neck for about 3–4 days before he presented to the hospital.

Systemically, the patient's vitals were stable, and no signs suggestive of septic shock at initial presentation. No known history of diabetes mellitus, hypertension and recent weight loss was present.

Mild crepitations on bilateral chest auscultation were noted.

On local examination, the patient had limited mouth opening of less than a finger width with diffuse tense brawny swelling of the neck extending from the lower border of mandible to the upper border of thyroid cartilage with posterior extension limited by the angle of mandible and sternocleidomastoid muscle bilaterally. The patient had a typical bull's neck appearance. The tongue was raised from the floor of mouth, and excessive drooling and slurred speech were also noticeable ([figure 1](#)).

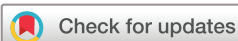Colour of the overlying skin was dark and well demarcated from surrounding normal skin, measuring about 8×6 cm in dimension. The skin seemed detached from the underlying bed with fluid accumulation in the intermediate layer. This developed shortly after application of medicinal oils ([figure 2](#)). There was no sign suggestive of respiratory distress or glottic oedema. Provisionally, all features inclined towards diagnosing Ludwig's angina secondary to odontogenic causes.

The patient was planned for emergency incision and drainage of the bilateral submandibular, submental and sublingual spaces with corrugated rubber drain to be left in situ. The overlying darkened skin was although thought to be secondary to ischaemia of subdermal plexus; it did not absolutely necessitate immediate debridement.

About 100 mL pus was drained from different spaces and was sent for culture and sensitivity. All the possible dental foci of infection were extracted. Patient was started on empirical antibiotics in the combination of ceftriaxone with sulbactam IV 12th hourly and metronidazole IV 8th hourly.

INVESTIGATIONS

1. Complete blood profile to check for acute inflammatory response suggested a trend of malignant thrombocytosis (platelets >1 000 000 cells/ μ L) presenting over a week after initial presentation of normal blood profile at the time of incision and drainage. Total leucocyte count raised from 7.04 to 16.39×10^3 cells/ μ L.
2. Hypoalbuminaemia (~ 2.8 g/dL).
3. Chest radiograph depicted lower left lobe opacity and sputum acid fast staining (AFB), cartridge-based nucleic acid amplification test for tuberculosis (CBNAAT), culture for mycobacteria was done which detected no organism ([figure 3](#)).



© BMJ Publishing Group Limited 2022. No commercial re-use. See rights and permissions. Published by BMJ.

To cite: Agarwal SS, Ansari HMN, Rao S, et al. *BMJ Case Rep* 2022;**15**:e250382. doi:10.1136/bcr-2022-250382

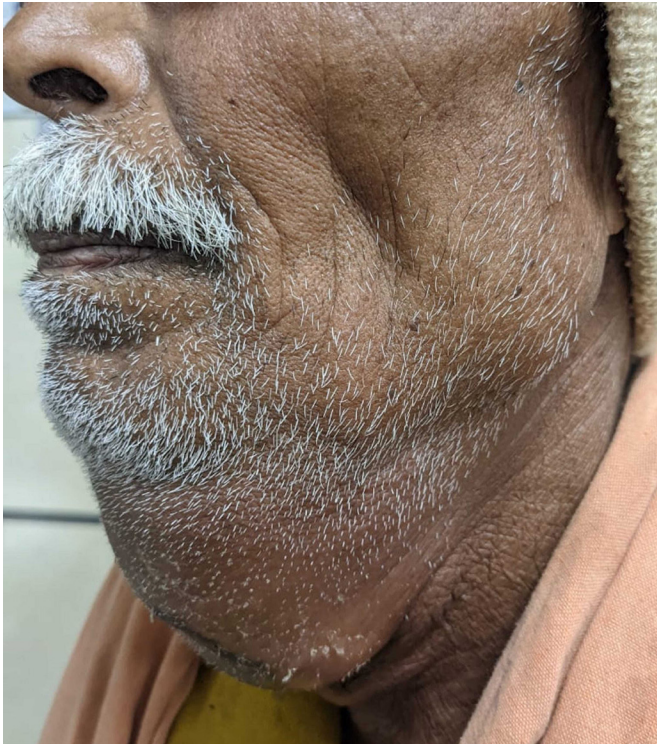

Figure 1 Initial clinical presentation with bull's neck and signs of Ludwig's angina.

4. C reactive protein levels raised over 41.5 mg/L after a period of 1 week.
5. Glycosylated haemoglobin was well within normal range and had glycaemic control throughout the course of treatment without any need of medicinal support.
6. The darkened overlying skin and underlying necrotic fascial tissues were sent for AFB, CBNAAT and culture. Although AFB showed no organisms, CBNAAT was sensitive enough to detect *Mycobacterium tuberculosis* from the necrotic tissue.
7. This sudden surge in inflammatory state after a week was associated with chills, fever and cough. Real-time PCR for the SARS-CoV-2 yielded positive results.

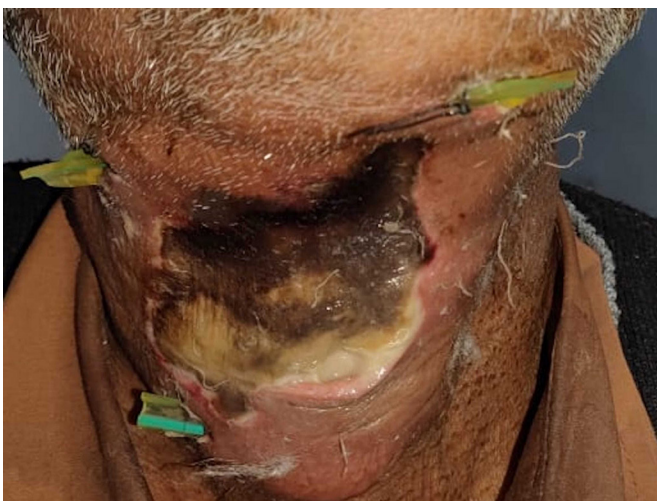

Figure 2 Postincision and drainage, the colour change of the overlying skin evident in areas with previous hot oil application.

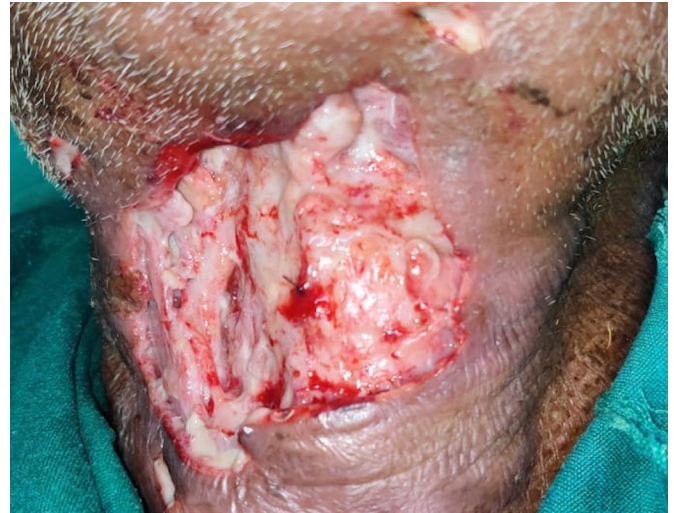

Figure 3 Debridement of necrotized skin and underlying fascia with positive finger test. The sample of tissue for CBNAAT testing was sent at this stage.

8. Contrast-enhanced CT scans of neck revealed destructive soft tissue planes of central compartment in infrahyoid region with evidence of necrosis (figure 4).

DIFFERENTIAL DIAGNOSIS

The working diagnosis of Ludwig's angina seemed far more certain, secondary to odontogenic cause initially. Even after initial drainage of pus and subsequent debridement of necrotic tissue, infection progressed with signs of toxic systemic involvement. Necrotising fasciitis of the neck was a definitive diagnosis, but the aetiology had to be determined. Odontogenic cause was negated by removing all the periodontally and endodontically compromised teeth. Continued suppuration directed towards

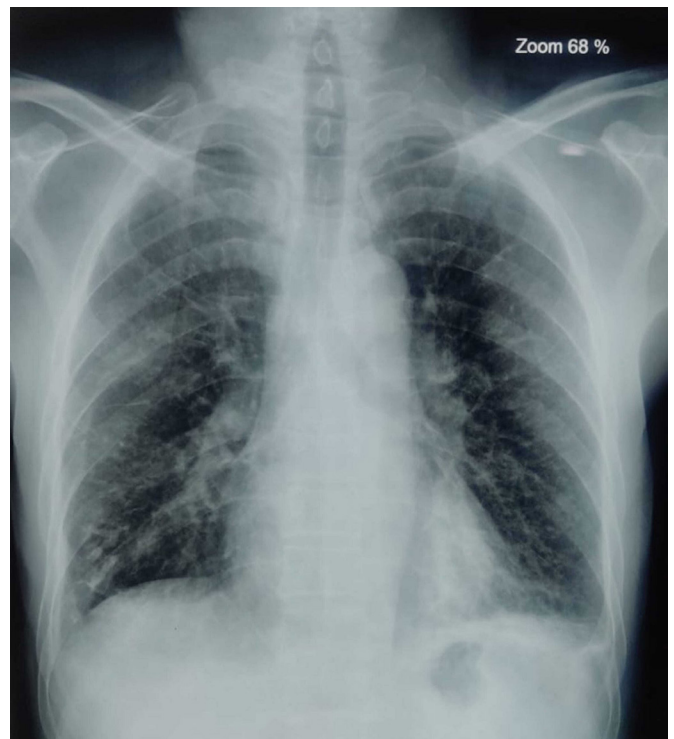


Figure 4 Chest Xray showing opacification of left lower lobe.

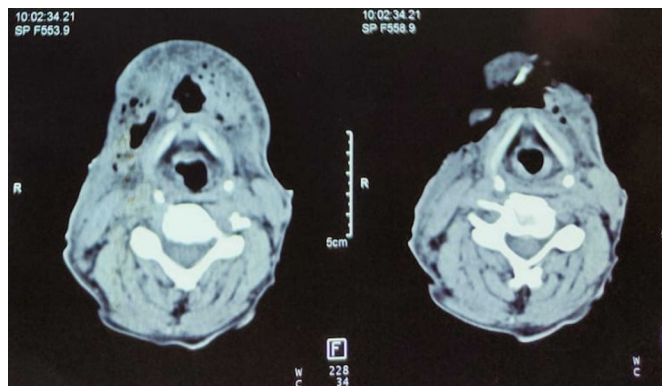


Figure 5 Contrast enhanced CT scan of neck revealing necrotized deep soft tissue planes in the pre-tracheal and infrahyoid region.

non-odontogenic cause; chest findings were also suggestive of pulmonary infection, so differential diagnosis of suppurative tuberculosis (TB) lymphadenitis was established.

TREATMENT

Emergency incision and drainage followed by empirical antibiotics is the first line of management in any case of Ludwig's angina as it can have fatal outcomes if not treated timely. Non-resolving infection and pus culture lead to the isolation of *Pseudomonas*, and *Klebsiella* organisms from neck were appropriately managed with sensitive antibiotics ranging from vancomycin, meropenem and ultimately with collistimethate sodium.

Necrotising fasciitis that developed secondary to multitude causes viz odontogenic, extrapulmonary TB; use of hot medicinal oils required debridement to create a healthy tissue bed and regular dressing with acriflavine paste for over 1 month.

Intensive debridement and regular dressing still did not yield desirable treatment outcomes. Isolation of *Mycobacterium* from CBNAAT testing was a transformer in adjusting the broad-spectrum antibacterial therapy to a more discrete regimen of antitubercular drugs (figure 5).

Pulmonary TB coinfection with COVID-19 and its systemic response must be meticulously balanced with suppurative necrotising fasciitis secondary to extrapulmonary TB. Steroids were started for a short span to prevent the development of systemic inflammatory response syndrome and multiorgan dysfunction syndrome.

Managing patients with multiple co-infections is challenging and must be dealt with promptly to avoid any adverse outcomes.

OUTCOME AND FOLLOW-UP

Properly guided treatment led to the resolution of necrotising fasciitis with a healthy ulcer bed and granulating wound after 40 days (figure 6). The patient is currently undergoing antitubercular therapy for 3 months and is being planned for reconstructive therapy with local flaps owing to wound contraction (figure 7).

DISCUSSION

Ludwig's angina is a rapidly spreading, potentially fatal infection of deep fascial spaces of the neck leading to airway oedema and death if not intervened at an early stage.¹ It is an acute emergency state associated with multitude risk factors and aetiologies. The highest incidence rate of such deep space neck infections occurs as a result of odontogenic infections. Other factors that exponentiate trivial dental infection include uncontrolled blood

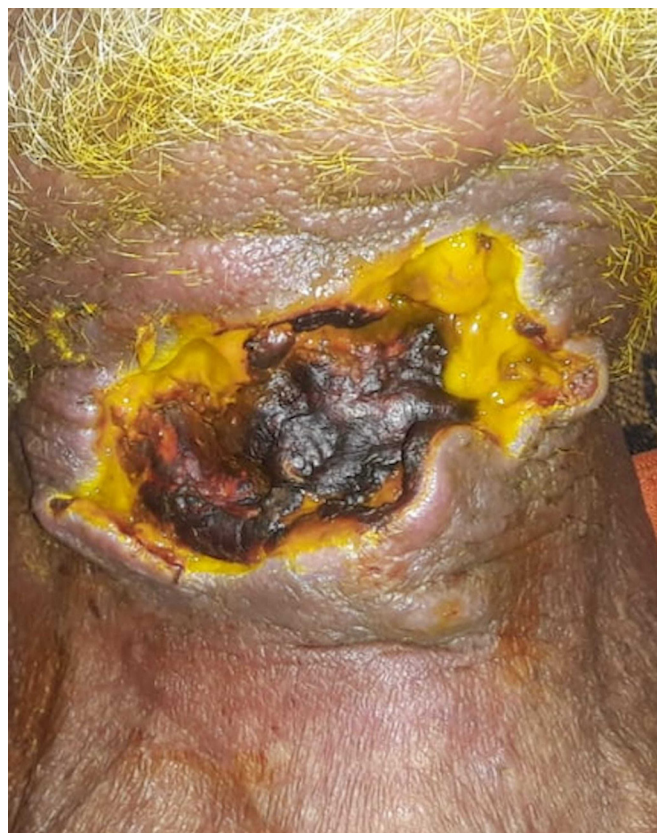

Figure 6 Picture showing healing ulcerative floor after multiple surgical debridement, HRZE therapy and local acriflavine dressings.

glucose levels, malnourishment, hypogammaglobulinaemia and other immunodeficiency states.²

The infection is usually polymicrobial, primarily including oral cavity flora. Viridians group *Streptococci* are found in over 40% of cases, followed by *Staphylococcus aureus* (27%) and *Staphylococcus epidermidis* (23%). Other commonly involved bacteria include *Enterococcus* species, *Escherichia coli*, *Fusobacterium*, *Streptococcus* species, *S. aureus*, *Klebsiella pneumoniae* and *Actinomyces* species. *Klebsiella* may be present in over half of cases involving diabetes mellitus. Immunocompromised patients are at high risk of gram-negative aerobic infection as well as methicillin-resistant *S. aureus*.³

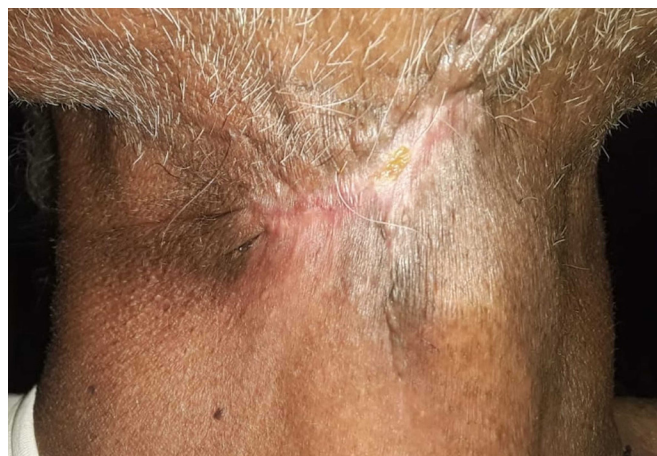

Figure 7 Post 6 months follow-up picture showing healed neck wound with minimal contracture.

When the nidus of infection is not eliminated, the infection scours the deep fascia of neck and complicates presentation with pain, swelling and persistent erythema ultimately scavenging the tissues. Necrotising fasciitis is one such complication of Ludwig's angina caused due to polymicrobial activity. While odontogenic infections are common, their progression to life-threatening necrotising fasciitis is relatively rare and insidious.

The laboratory risk indicator for necrotising fasciitis (LRINEC) score is capable of detecting early cases of necrotising among patients with severe soft tissue infections. A LRINEC score of 6 should raise the suspicion of necrotising fasciitis, and a score of 8 is strongly predictive of this disease.⁴ The biochemical and haematological biomarker in our case was as low as 1, yet what led to fatal deterioration of the neck tissues was still a diagnostic dilemma. Our case seemed to progress uncontrollably even after odontogenic infection foci was removed. Neck tissues were positive for finger test with suppuration and had to be debrided.

Persistence and progression of disease state often speculates correlation of other factors compromising immune response and upscaling the morbid condition. The factors to investigate in the present case was history of cough, fever and recent weight loss with chest findings showing opacity in lower left lobe of lung inclining towards a diagnosis of pulmonary TB. However, AFB and CBNAAT were negative for bronchoalveolar lavage and sputum samples. Organisms isolated from debrided tissue sent from neck for CBNAAT testing detected mild presence of *Mycobacterium*. Dental infection superadded with extrapulmonary TB could have resulted in aggressive spread of infectious disease in cervicofacial region.

Literature evidence shows cases of necrotising fasciitis with recurrence and slow response to surgical debridement involving chest wall and abdomen in extrapulmonary TB with the debrided tissue showing positive acid-fast bacilli.⁵ The disease process that was initiated by dental infection could have progressed by a suppurating cervical TB lymphadenitis. Thus, it becomes important to investigate other distant sources of infection and add to differential aetiology. The multimodal treatment will only seem to benefit such multibacterial infections of neck.

In a cohort study of necrotising soft tissue infection caused by group A *Streptococcus* and *Streptococcus dysgalactiae*, it was found that mortality rate was high with increasing age, men and association with septic shock. Non-administration of intravenous immunoglobulin therapy was associated with high 90-day mortality rate.⁶ In another study correlating factors affecting patients with concurrent deep neck infection and cervical necrotising fasciitis (CNF), patients with concurrent CNF infection have significant differences in the length of the hospital stay. Therapeutic management predisposed by risk factors like old age, raised C reactive protein levels, uncontrolled blood sugar and diabetes mellitus.⁷ In the present case, old age and male gender were certain non-modifiable risk factors that poorly prognosticate and added to the burden of disease.

Patient although initially screened and found negative for usual risk factors turned out to be infected with SARS-CoV-2 infection in synergism with extrapulmonary *M. tuberculosis*. Age-related changes influence the host immune response and therefore not only weaken the ability to fight respiratory infections but also mount effective responses to other antibiotics/vaccines. Immunosenescence and inflammaging are considered key features of the ageing immune system wherein accumulation of senescent immune cells contribute to its decline and simultaneously increased inflammatory phenotypes cause immune dysfunction.

These changes determine not only the susceptibility to infections but also disease progression and clinical outcomes thereafter.⁸

The presence of a proinflammatory state in older adults suggests a need to modulate balance between viral clearance and excessive inflammation, which may be achieved using corticosteroids.⁹ Thus to weaken and prevent excessive stimulation and exhaustion of immune responses, low doses of steroids are usually administered. However, a meta-analysis by Russel *et al* of corticosteroid use in SARS-CoV-2 patients with variable timing and dosage of treatment found overwhelming harmful effects, including increased length of stay in an intensive care unit, higher rate of secondary infection and higher mortality.¹⁰

Thus managing patient with deep neck space infection and concomitant pulmonary infections where immunomodulation is performed using steroids can further deteriorate the disease progression can pose dilemma to the clinician. A risk versus benefit analysis is required to control the mortality rate. Steroids were administered to help regulate the immune response alongside the antitubercular drug regimen (HRZE) to help combat concomitant *Mycobacterium* infection, with intravenous colistimethate sodium regulating the multidrug resistant superinfection of neck. This halted the disease process after a period of 1 month of intensive surgical debridement with topical acriflavine dressing to help with fastened secondary healing.

Combination of repeated surgical debridement and medical management is time tested algorithm for necrotising fasciitis. Significance of coexisting pulmonary infections needs to be adequately addressed making timely diagnosis essential to halt the disease process in a case of odontogenic related deep neck infection with concurrent necrotising fasciitis. The coexisting distant infection and multicomponent involvement makes it essential to rule out pulmonary and extrapulmonary TB.

Learning points

- ▶ Infections of neck may have multiple coexisting aetiologies which necessitates simultaneous antibacterial therapy to act against local oral microflora and extrapulmonary tuberculosis along with surgical debridement.
- ▶ To effectively reduce viral load and avoid exhaustion of adaptive immune response in COVID-19 infection presenting with simultaneous necrotising fasciitis is challenging and requires certain expertise.
- ▶ An otherwise immunocompetent patient with no comorbidities can be endangered to progressive neck infections when associated with COVID-19 infection having an impact on immune response.

Contributors SA wrote the initial manuscript and did literature search. HMNA did the proofreading and documentation. SR was the operating surgeon and final proofread the manuscript, literature search. VG did the literature search and documentation.

Funding The authors have not declared a specific grant for this research from any funding agency in the public, commercial or not-for-profit sectors.

Competing interests None declared.

Patient consent for publication Consent obtained directly from patient(s).

Provenance and peer review Not commissioned; externally peer reviewed.

Case reports provide a valuable learning resource for the scientific community and can indicate areas of interest for future research. They should not be used in isolation to guide treatment choices or public health policy.

ORCID iDs

Subham S Agarwal <http://orcid.org/0000-0003-2018-150X>

Santhosh Rao <http://orcid.org/0000-0003-0274-7442>
Virat Galhotra <http://orcid.org/0000-0003-4753-1960>

REFERENCES

- 1 Pak S, Cha D, Meyer C. Ludwig's angina case presentation. *Cureus* 2017;9:8–11.
- 2 Baez-Pravia OV, Díaz-Cámara M, De La O, *et al*. Should we consider IgG hypogammaglobulinemia a risk factor for severe complications of Ludwig angina?: a case report and review of the literature. *Medicine* 2017;96:e8708.
- 3 Bridwell R, Gottlieb M, Koyfman A, *et al*. Diagnosis and management of Ludwig's angina: an evidence-based review. *Am J Emerg Med* 2021;41:1–5.
- 4 Wong C-H, Khin L-W, Heng K-S, *et al*. The LRINEC (laboratory risk indicator for necrotizing fasciitis) score: a tool for distinguishing necrotizing fasciitis from other soft tissue infections. *Crit Care Med* 2004;32:1535–41.
- 5 Hefny AF, Abu-Zidan FM. Necrotizing fasciitis as an early manifestation of tuberculosis: report of two cases. *Ulus Travma Acil Cerrahi Derg* 2010;16:174–6.
- 6 Bruun T, Rath E, Madsen MB, *et al*. Risk factors and predictors of mortality in streptococcal necrotizing soft-tissue infections: a multicenter prospective study. *Clin Infect Dis* 2021;72:293–300.
- 7 Chen S-L, Chin S-C, Wang Y-C, *et al*. Factors affecting patients with concurrent deep neck infection and cervical necrotizing fasciitis. *Diagnostics* 2022;12:443.
- 8 Bajaj V, Gadi N, Spihlman AP, *et al*. Aging, immunity, and COVID-19: how age influences the host immune response to coronavirus infections? *Front Physiol* 2020;11:571416.
- 9 Rea IM, Gibson DS, McGilligan V, *et al*. Age and age-related diseases: role of inflammation triggers and cytokines. *Front Immunol* 2018;9:586.
- 10 Russell CD, Millar JE, Baillie JK. Clinical evidence does not support corticosteroid treatment for 2019-nCoV lung injury. *Lancet* 2020;395:473–5.

Copyright 2022 BMJ Publishing Group. All rights reserved. For permission to reuse any of this content visit <https://www.bmj.com/company/products-services/rights-and-licensing/permissions/>
BMJ Case Report Fellows may re-use this article for personal use and teaching without any further permission.

Become a Fellow of BMJ Case Reports today and you can:

- ▶ Submit as many cases as you like
- ▶ Enjoy fast sympathetic peer review and rapid publication of accepted articles
- ▶ Access all the published articles
- ▶ Re-use any of the published material for personal use and teaching without further permission

Customer Service

If you have any further queries about your subscription, please contact our customer services team on +44 (0) 207111 1105 or via email at support@bmj.com.

Visit casereports.bmj.com for more articles like this and to become a Fellow