

Ultrasound-Guided Lumbar Paravertebral Block After Pre-Designed Route on X-Ray Film for Radicular Pain Following Failed Back Surgery Syndrome: A Case Report

This article was published in the following Dove Press journal:
Journal of Pain Research

Danxu Ma¹
Huili Li¹
Rong Shi¹
Yinan Yang¹
Haoda Liu²
Xiaodong Ge¹ 

¹Department of Anesthesiology, Beijing Chaoyang Hospital, Capital Medical University, Beijing, People's Republic of China; ²Department of Anesthesiology, Beijing Huairou Maternal and Child Health Care Hospital, Beijing, People's Republic of China

Background: Persistent or recurring radicular pain after lumbar surgery is a clinical condition of failed back surgery syndrome (FBSS) that seriously affects the life quality of patients. Conventional medication and physiotherapy do not fully relieve this pain. A simpler, safer, and less invasive option is lumbar selective nerve root block or paravertebral block. Here, we share our experience regarding lumbar paravertebral block for a patient with FBSS, which successfully alleviated radicular pain after lumbar surgery.

Case Presentation: An 80-year-old man with left lower limb radicular pain diagnosed as L4-5, L5-S1 intervertebral disc protrusion, spinal canal stenosis, and degenerative scoliosis underwent lumbar surgery. Four months after surgery, he experienced left lower limb radicular pain. After designing the puncture route based on X-ray film, we performed a combined ultrasound-guided L4 and L5 paravertebral block. With his improved pain control, his functional status and ability to perform daily activities also markedly improved.

Conclusion: Real-time ultrasound-guided lumbar paravertebral block performed with a pre-designed route on X-ray film can provide a simple and safe way to relieve radicular pain in FBSS.

Keywords: lumbar paravertebral block, failed back surgery syndrome, ultrasound-guided, pre-designed route

Introduction

Failed back surgery syndrome (FBSS) is characterized by persistent or recurring low back pain, with or without radicular pain after one or more spine surgeries. It may result in reduced function, and is often associated with conditions such as depression and anxiety disorder. The rate of FBSS after lumbar laminectomy has been reported at 10% to 40%.¹ The most common causes of FBSS are epidural fibrosis, spinal stenosis, arachnoiditis, foraminal stenosis, and recurrent herniation.² Conventional medication and physiotherapy do not fully relieve this pain.^{3,4} Depending on the cause, options to manage FBSS include image-guided interventions such as epidural/caudal steroid injection, facet joint injection, selective nerve root block, radiofrequency ablation, and spinal cord stimulation.² Recent studies have highlighted the use of ultrasound in chronic spinal pain, being as it is portable, guided in real time, and without radiation. However, few cases on the application of ultrasound in FBSS have been reported, due to obstruction by the implant to the

Correspondence: Xiaodong Ge
Department of Anesthesiology, Beijing Chaoyang Hospital, Capital Medical University, No. 8, Gongtinan Road, Chaoyang District, Beijing 100020, People's Republic of China
Email xiaodongge2005@163.com

ultrasound. Here, we report a case of radicular pain after lumbar surgery that was successfully treated with real-time ultrasound-guided L4 and L5 paravertebral block (PVB), combined with a pre-designed route on X-ray film.

Case Presentation

The patient provided written informed consent for publication of the case details and accompanying images. The publication of this case and accompanying pictures were approved by the ethics committee of Beijing Chaoyang Hospital, Capital Medical University.

An 80-year-old man was referred to our pain clinic for radicular pain of the left lower limb. Just over 6 months previously, he had presented with severe radicular pain in his left leg. Magnetic resonance (MR) images revealed lumbar intervertebral disc protrusion (migrated to the left, L4-5, L5-S1) (Figure 1A and B), lumbar spinal canal stenosis, and degenerative lumbar scoliosis. At that time, he received posterior lumbar decompression interbody fusion plus spinal stabilization (L1-5), and his symptoms disappeared after surgery.

Four months later, the radiating pain in the lateral aspect of the left lower limb and the dorsum of the foot recurred, at the same sites as pre-surgery. The worst visual analogue scale (VAS) was 9/10. He could hardly stand up and walk. Weakness of dorsiflexion and plantarflexion was found in the foot. The lying straight leg raise test was positive, and the Achilles reflex was absent.

The previous medication included oral nonsteroidal anti-inflammatory drugs and physiotherapy, but neither treatment was effective. All the symptoms and physical examinations suggested problems of the L4-5, L5-S1 intervertebral discs, likely due to insufficient surgical decompression, recurrent disc herniation, or foraminal stenosis.

Ultrasound-guided experimental L4 and L5 PVB was then planned for this patient. The difficulty in this case was that the anatomical structure could not be located by body-surface land markers, due to the removal of spinous processes during the prior surgery. In addition, the anatomical structure could not be seen clearly through ultrasound, because of echogenic artifacts due to the surgical instruments, and the disordered fascia and muscle structure due to the surgical incision. Fortunately, on the X-ray film we found that the last-but-one pedicle screw and the terminal of the left rod were just next to the needle pathway we designed for the block, and might be used as markers for the puncture (Figure 1C and D).

The patient was placed lateral with the affected side upward. A convex type transducer (Wisonic Medical Technology, Shenzhen, China) was placed in a longitudinal orientation at the level of L5-S1, 3 cm lateral to the midline. With the probe sliding upward, the pedicle screws and the rods could be identified (Figure 2). Surface landmarks, such as iliac crest and locations for the pedicle screws and the rods were made on the skin. At the caudal side of the last-but-one pedicle screw and terminal of the rod, two lines were drawn perpendicular to the spine.

A paramedian transverse oblique scanning approach with needle in-plane was chosen for the L4 PVB.⁵ After proper sterile technique, the gel was applied to the ultrasound transducer. The transducer and cable were covered with a sterile sleeve, and placed along the vertical line with the caudal side of the target pedicle screw. The bone structure and fascia between muscles could not be seen clearly, because of the previous lumbar surgery. The pedicle screw was the most easily recognizable structure for hyperechoic. After local anesthetic (2 mL lidocaine 1%) infiltration to the skin and subcutaneous tissue, a 22G 90-mm needle (TuoRen Medical Instrument Finty, Zhengzhou, China) was inserted in a medial to lateral direction, overstride the pedicle screw, and reached the outboard of the foramen intervertebral (Figure 3). After confirmation of the needle tip with 2 mL normal saline, 5 mL of 0.1% lidocaine mixed with 3 mg betamethasone was injected.

Because of the obstruction of the iliac bone, a paramedian transverse oblique scanning with needle in-plane approach could not be used for L5 PVB. Instead, we chose a paramedian transverse scanning with needle out-plane approach. The transducer was placed along the vertical line with the terminal of the rod, beneath the space between the iliac bone and the nail rod. A hyperechoic area was observed, which was assumed to be L5 paravertebral space. After the puncture point was anesthetized with 2 mL of 1% lidocaine, the needle was inserted towards the hyperechoic area, out the plane of the ultrasound beam in a cephalad-to-caudal direction (Figure 4). Considering that the entire needle with an out-plane approach could not be confirmed by ultrasonography, the depth of the needle tip was referenced according to the previous measurement on the X-ray film. Another 5 mL solution was injected.

After 20 minutes of observation, the patient felt well enough to return home. At the third day after the block, the patient reported that his daily baseline level of pain had diminished to 50% of its original severity. We repeated this procedure every 14 days, three times in total. Three months after the last procedure, his visual analogue scale

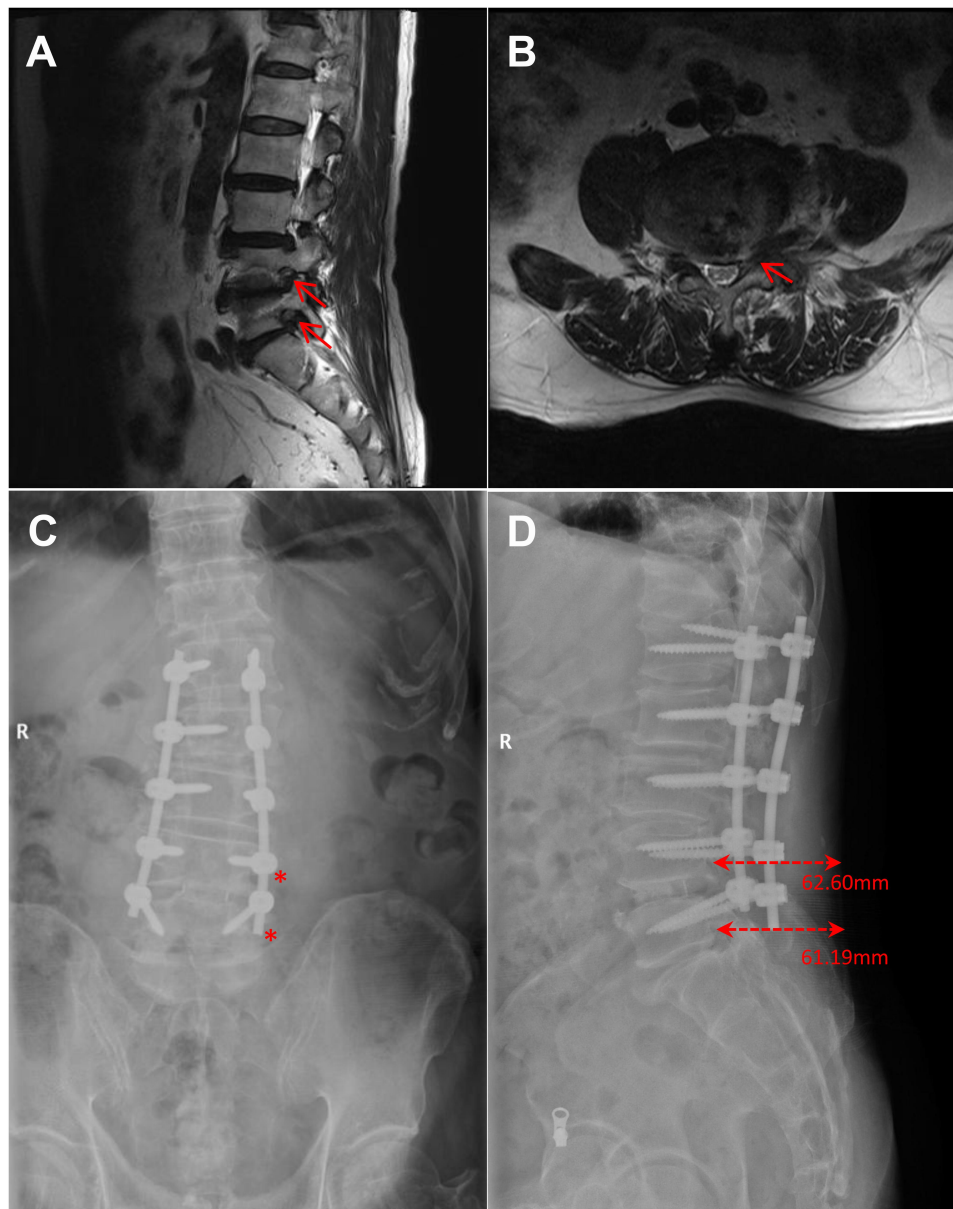


Figure 1 Radiographs. (A) Sagittal plane of the lumbar MR image showed stenosis of the L4-5, L5-S1 left intervertebral foramen (red arrows). (B) Axial plane of the lumbar MR image showed that the herniated disc of L4-5 compressed the nerve root. (C) Anteroposterior lumbar radiograph after surgery. The L4 paravertebral space was just lateral inferior to the last-but-one pedicle screw. The target of the L5 paravertebral space was just in the lateral rod terminal. (D) Lateral lumbar radiograph after surgery. The last-but-one pedicle screw and the terminal of the rod were just next to the needle paths we designed for L4 or L5 PVB. The depth of the needle from the skin to the target was measured, according to the scale.

(VAS) was 2/10, and he could go for walks, and he was satisfied with the extent of pain control.

Discussion

Over recent years, the use of ultrasound in procedures to manage chronic pain has become more widespread, as it provides imaging of neurovascular structures, with real-time continuous visualization of the needle, without any radiation exposure.⁶ For lumbar PVB, the relevant levels are determined with ultrasound by counting the laminae, facet

joints or transverse processes (caudal to cephalad), further then the paravertebral space is determined according to the relative position of the transverse process, articular process, and vertebral body in the sonoanatomy image.

However, in the present patient after lumbar surgery, penetration of the ultrasound beam energy to the deeper structures (transverse process, articular process, and vertebral body) was hindered by the implants placed previously. Furthermore, his L1-L5 spinous processes had been removed, and scoliosis was not completely corrected during

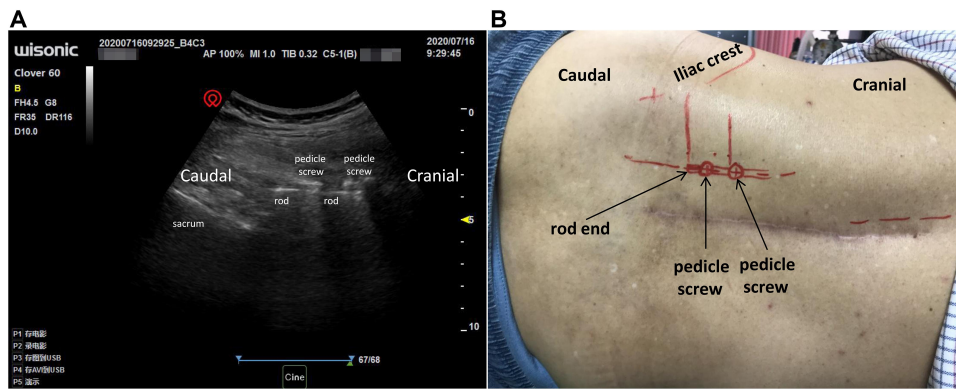


Figure 2 Localization of pedicle screw and the rod. **(A)** The pedicle screw and the rod were identified. **(B)** The iliac crest, and locations of the pedicle screws and the rods were marked on the skin. Two lines perpendicular to the spine were drawn, at the caudal side of the last-but-one pedicle screw and the terminal of rod.

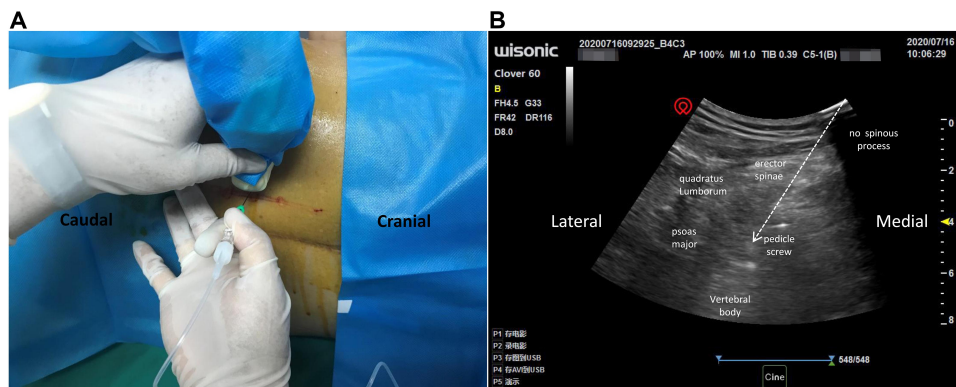


Figure 3 Ultrasound and patient set-up for L4 PVB. **(A)** Performance of the L4 PVB using paramedian transverse oblique scanning with needle in-plane approach. **(B)** Sonoanatomy of L4 PVB. The vertebral body, pedicle screw, erector spinae, psoas major, and quadratus lumborum were visible. The white arrow indicates the needle path.

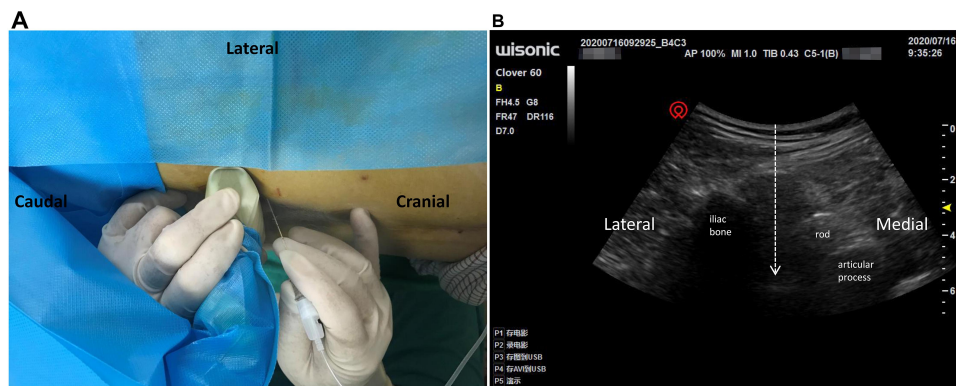


Figure 4 Transducer position and corresponding ultrasound image of L5 PVB. **(A)** Position of patient, needle, and probe of the ultrasound apparatus under the left L5 PVB. The needle is pointed cephalad-to-caudal toward the target with ultrasound guidance. **(B)** Transverse ultrasonographic view shows a hyperechoic area between the rod and the iliac bone. The white arrow indicates the out-plane needle path.

the operation. It was impossible to confirm the relevant level and the midline. This made it more difficult to determine the insertion site and route. Nevertheless, ultrasound still served as a real-time guiding tool in this patient.

Firstly, an ideal puncture route was drawn on X-ray film from the skin to the target paravertebral space. Secondly, the

relationship between the route and the implants was observed carefully, for the pedicle screws, the rods, and any other implants could be used as landmark instead of bony structures. Thirdly, the position of the selected implants were determined by ultrasound, and marked on the skin. Lastly, under the real-time guidance of ultrasound, the needle was

inserted along the pre-designed route and injection site. Obviously, this method decreases the exposure of surgical staff to X-ray. Furthermore, it helps to monitor the depth and direction of the puncturing needle, which is important for the success of lumbar PVB. Pre-designing the puncture route on X-ray film improved the accuracy and shortened the operational time of the puncture, and ensured security during the ultrasound-guided lumbar PVB.

In general, pain physicians prefer lumbar selective nerve root block/radiofrequency or transforaminal injection under fluoroscopic guidance for radicular pain caused by lumbar disc herniation.^{6,7} After the puncture needle is in place, the contrast agent is injected, and the contrast agent can be seen spreading along the nerve root and epidural space. However, PVB involves injection of local anesthetic in a space immediately lateral to where the spinal nerves emerge from the intervertebral foramina. The paravertebral space is known to communicate with the epidural space through intervertebral foramina.⁸ The solutions of PVB may spread to nerve roots, even the epidural space, to achieve the therapeutic effect.⁹ With no fluoroscopic guidance, we chose real-time ultrasound-guided lumbar PVB after determining a pre-designed route on X-ray film for this patient.

Similarly, we believed that lumbar erector spinae plane (ESP) block, a research hotspot in recent years, could be an alternative, safer, and simple method for this patient. The injection of local anesthetics into the transverse process provides analgesia by blocking the dorsal and ventral branches of the spinal nerves.¹⁰ It has been used for the treatment of FBSS low back pain. The injection of 20 mL local anesthetics into the L2 transverse process can block the dorsal rami of the spinal nerves from T12 to L5.¹¹ Imaging evidence also confirmed that a lumbar ESP block at the L4 transverse process with a high volume drug could spread to the epidural space, leading to a similar effect as transforaminal injection, for the treatment of radicular pain caused by L3–L4 and L4–L5 intervertebral disc herniation.¹² However, the efficiency of ESP block depends on the slow infiltration and diffusion of local anesthetics to the target nerve. A higher volume and higher concentration of local anesthetics is needed for a better blocking effect. We think that the puncture target of the PVB is closer to the lesion sites (nerve roots), and the side effects of local anesthetics and steroids may be reduced.

In conclusion, the success of this case suggests that real-time ultrasound-guided lumbar PVB with a pre-designed route on X-ray film is a viable, simple, and safe method to relieve radicular pain in FBSS.

Author Contributions

All authors made substantial contributions to the conception and design, acquisition of data, or analysis and interpretation of data; took part in drafting the article or revising it critically for important intellectual content; agreed to submit to the current journal; gave final approval of the version to be published; and agree to be accountable for all aspects of the work.

Funding

This work was supported by the clinical research project supported by Beijing Municipal Science & Technology Commission (Z181100001718222) to Dr. Ma.

Disclosure

The authors report no conflicts of interest in this work.

References

- Ahn Y, Keum HJ, Shin SH, Choi JJ. Laser-assisted endoscopic lumbar foraminotomy for failed back surgery syndrome in elderly patients. *Lasers Med Sci.* 2020;35(1):121–129. doi:10.1007/s10103-019-02803-7
- Hussain A, Erdek M. Interventional pain management for failed back surgery syndrome. *Pain Pract.* 2014;14(1):64–78. doi:10.1111/papr.12035
- Baber Z, Erdek MA. Failed back surgery syndrome: current perspectives. *J Pain Res.* 2016;9:979–987. doi:10.2147/JPR.S92776
- Daniell JR, Osti OL. Failed back surgery syndrome: a review article. *Asian Spine J.* 2018;12(2):372–379. doi:10.4184/asj.2018.12.2.372
- Karmakar MK, Li JW, Kwok WH, Soh E, Hadzic A. Sonoanatomy relevant for lumbar plexus block in volunteers correlated with cross-sectional anatomic and magnetic resonance images. *Reg Anesth Pain Med.* 2013;38(5):391–397. doi:10.1097/AAP.0b013e31829e52cc
- Kanna RM, Shetty AP, Rajasekaran S. Predictors of successful outcomes of selective nerve root blocks for acute lumbar disc herniation. *Global Spine J.* 2019;9(5):473–479. doi:10.1177/2192568218800050
- Arun-Kumar K, Jayaprasad S, Senthil K, Lohith H, Jayaprakash KV. The outcomes of selective nerve root block for disc induced lumbar radiculopathy. *Malays Orthop J.* 2015;9(3):17–22. doi:10.5704/MOJ.1511.002
- Bang YJ, Park HJ, Sim WS, Lee DW, Lee JY. Correlation between paravertebral spread of injectate and clinical efficacy in lumbar transforaminal block. *Sci Rep.* 2020;10(1):11508. doi:10.1038/s41598-020-68474-5
- Karmakar MK. Thoracic paravertebral block. *Anesthesiology.* 2001;95(3):771–780. doi:10.1097/0000542-200109000-00033
- Tulgar S, Senturk O. Ultrasound guided Erector Spinae Plane block at L-4 transverse process level provides effective postoperative analgesia for total hip arthroplasty. *J Clin Anesth.* 2018;44:68. doi:10.1016/j.jclinane.2017.11.006
- Takahashi H, Suzuki T. Erector spinae plane block for low back pain in failed back surgery syndrome: a case report. *JA Clin Rep.* 2018;4(1):60. doi:10.1186/s40981-018-0198-6
- Celik M, Tulgar S, Ahiskalioglu A, Alper F. Is high volume lumbar erector spinae plane block an alternative to transforaminal epidural injection? Evaluation with MRI. *Reg Anesth Pain Med.* 2019;44(9):906–907. doi:10.1136/rapm-2019-100514

Journal of Pain Research

Dovepress

Publish your work in this journal

The Journal of Pain Research is an international, peer reviewed, open access, online journal that welcomes laboratory and clinical findings in the fields of pain research and the prevention and management of pain. Original research, reviews, symposium reports, hypothesis formation and commentaries are all considered for publication. The manuscript

management system is completely online and includes a very quick and fair peer-review system, which is all easy to use. Visit <http://www.dovepress.com/testimonials.php> to read real quotes from published authors.

Submit your manuscript here: <https://www.dovepress.com/journal-of-pain-research-journal>