



## Renal artery denervation suppresses intractable ventricular arrhythmia in patients with left heart thrombosis

Marianna A Vander<sup>1,2</sup>, Petr A Fedotov<sup>3</sup>, Tamara A Lyubimtseva<sup>2</sup>, Maria A Bortsova<sup>3</sup>,  
Maria Yu Sitnikova<sup>3</sup>, Dmitry S Lebedev<sup>2</sup>, Evgeny N Mikhaylov<sup>1,2,\*</sup>

<sup>1</sup>Neuromodulation Unit, Almazov National Medical Research Centre, Saint-Petersburg, Russia

<sup>2</sup>Arrhythmia Department, Almazov National Medical Research Centre, Saint-Petersburg, Russia

<sup>3</sup>Heart Failure Department, Almazov National Medical Research Centre, Saint-Petersburg, Russia

*J Geriatr Cardiol* 2017; 14: 587–589. doi:10.11909/j.issn.1671-5411.2017.09.005

**Keywords:** Renal nerve denervation; Sympathetic nerve activity; Ventricular tachyarrhythmias

Transcutaneous renal artery denervation (RND) has been initially developed for destruction of efferent nerve fires with luminal delivery of radiofrequency or ultrasonic energy aiming blood pressure reduction in patients with refractory hypertension.<sup>[1]</sup> However, other positive results of RND were described afterwards, and they include suppression of atrial fibrillation and ventricular tachycardia (VT) storm.<sup>[1,2]</sup> RND for management of heart rhythm disturbances has been used in combination with other widely accepted techniques, such as pulmonary vein isolation for atrial fibrillation, and substrate modification for drug-refractory VT.<sup>[2,3]</sup>

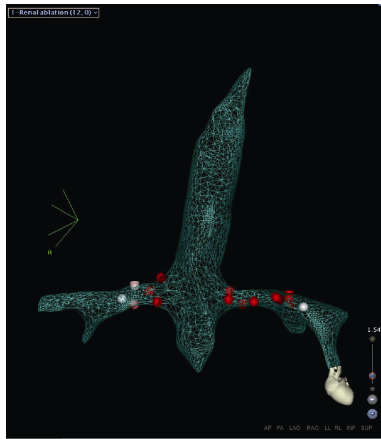
Here, we report on two cases of intractable VTs in patients with severely depressed left ventricle (LV) systolic function and congestive heart failure (HF), in whom endocardial arrhythmia substrate ablation was contraindicated due to intracardiac thrombosis, and other neuromodulation approaches were not feasible due to systemic anticoagulation.

For the first case, a 37-year-old male patient with ischemic cardiomyopathy was admitted due to recently decompensated chronic HF and recurrent syncope during the last two days. At admission, ECG showed sinus rhythm, transthoracic echocardiography demonstrated depressed left ventricle ejection fraction (LVEF) 18%, and three hypokinetic LV segments. There was a thin loose thrombus attached to the anterior wall of the LV. Patient history included three remote myocardial infarctions (two years ago: antero-lateral, one year ago: antero-septal, five months ago: apical) and multiple coronary interventions with stenting in the past. Coronarography showed 80% stenosis of the right coronary artery, and subsequent stenting of this lesion was

performed. Two days after the patient developed syncope in the hospital, and a fast VT was documented. Amiodarone treatment was initiated and implantable cardioverter-defibrillator (ICD) placement was scheduled. However, the patient developed VT storm in the following day. Intravenous amiodarone, lidocaine were ineffective. Deep sedation with mechanic ventilation, and intravenous vasopressors were initiated. Despite intensive treatment, multiple episodes of fast VT (> 30 a day) requiring external cardioversions were associated with exaggerated decompensation. Notably, all VT episodes were induced by monomorphic premature ventricular contractions (PVCs). However, catheter ablation was contraindicated due to soft LV thrombosis. Neuromodulation techniques were discussed by the heart team and neurologists (including spinal cord interventions and sympathetic block/denervation) but were not attempted due to anticoagulation. Renal denervation was considered as a bailout procedure, and the procedure was performed using an open irrigated tip electrophysiology ablation catheter (NaviStar ThermoCool, Biosense Webster, Diamond Bar, CA, USA) under electroanatomical guidance (CARTO 3, Biosense Webster). Five and seven radiofrequency applications, 2 min each, 10 W, were delivered to the right and left renal arteries, correspondingly (Figure 1). The procedure was initiated during recurrent fast VT episodes and first applications in the right artery immediately terminated arrhythmia. Interestingly, the same morphology PVCs were continuously registered, but did not induce VT.

The patient remained stable during the following four days, extubated, and vasopressors were withdrawn. On the day 5, he was ready for heart transplantation. Before the operation, dental management was performed and tooth

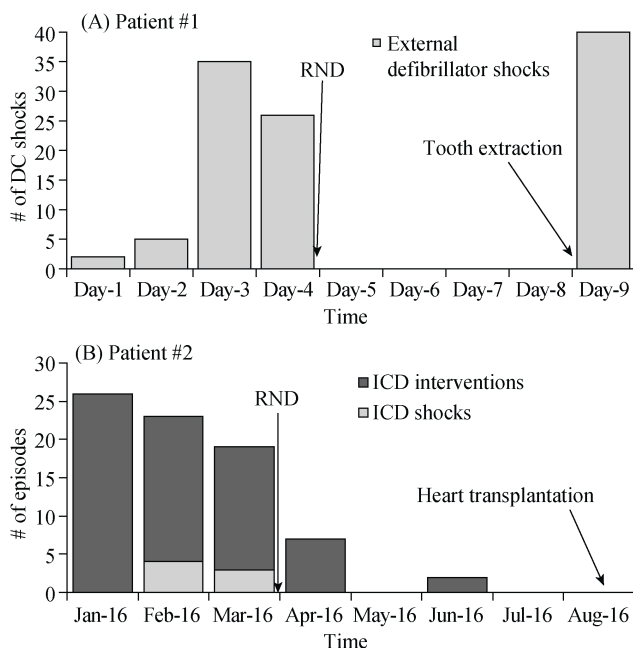
\*Correspondence to: e.mikhaylov@almazovcentre.ru



**Figure 1.** A three-dimensional reconstruction of the aorta and renal arteries in patient #1. Red points represent radiofrequency ablation spots in the arteries. White points depict sites of main arteries bifurcation.

extraction was required due to periodontitis. During extraction, the patient developed incessant ventricular fibrillation, refractory to multiple external defibrillator shocks and intravenous treatment by a combination of amiodarone, beta-blockers, lidocaine and IC class antiarrhythmics (Figure 2A). Ultimately, the patient died.

For the second case, a 36-year-old male patient with dilated cardiomyopathy (DCM) was referred due to repetitive



**Figure 2.** Dynamics of the number of external defibrillator shocks before and after RND in patient #1 (A); and dynamics of ventricular arrhythmia episodes and ICD intervention types before and after RND in patient #2 (B). ICD: implantable cardioverter-defibrillator; RND: renal artery denervation;

ICD shocks. The patient was diagnosed with DCM two years ago, and received an ICD for secondary prevention one year ago. At admission, echocardiography showed LVEF 16% and a soft thrombus in the left atrial appendage. ECG demonstrated sinus rhythm with narrow QRS. Over the last five months, the patient experienced repetitive VT shocks and anti-tachycardia ICD interventions for fast polymorphic VTs and ventricular fibrillation. The patient had already been on optimal medical therapy for HF. Oral anticoagulation was initiated at admission. A VT catheter ablation procedure was scheduled. However, after one month follow-up, LAA thrombus persisted, and catheter ablation was still contraindicated. The patient continued to develop VTs with hemodynamic instability despite appropriate ICD detection and therapy, and renal denervation was performed. Renal angiography demonstrated two right arteries of small diameter. Therefore, unilateral left-sided artery ablation was carried out using the same technique as in the patient #1 (six radiofrequency applications delivered). After the procedure, there was a dramatic reduction in the number of VT episodes with their subsequent disappearance; no ICD shocks were required, and successful heart transplantation was performed within 5 months (Figure 2B).

According to the results of our case series, RND can suppress intractable VTs in severely ill patients with ischemic and non-ischemic cardiomyopathy. Usually, in patients with hemodynamically intolerable drug-refractory VTs, arrhythmia substrate ablation is performed as early as possible; however, left heart thrombosis precluded intracardiac interventions in our cases.

Non-pharmacological neuromodulation approaches have been proposed for the management of VT and HF (spinal anesthesia or stimulation, RND, left sympathetic cardiac denervation). Preclinical studies have demonstrated their efficacy in reducing ventricular arrhythmia and improving LVEF. Spinal cord interventions are contraindicated in patients under continuous anticoagulation, as in our patients with left heart thrombosis. Percutaneous RND is thought to affect VT inducibility by a reduction in sympathetic nerve activity, and has demonstrated its potential in VT burden reduction in previous reports.<sup>[3,4]</sup>

Transcatheter RND using a point-by-point approach has inherent limitation in terms of consistency of denervation.<sup>[5]</sup> Moreover, the use of non-dedicated catheter precluded us from delivering radiofrequency applications in the distal part of arteries, and this might partly explain temporal effect of VT termination in the first patient. On the other hand, recurrence of incurable ventricular fibrillation during emotional stress triggered by tooth extraction, once again confirms the importance of sympathetic over-activity in ventricular arrhythmia induction and persistence.

In conclusion, stand-alone RND is associated with termination of intractable VTs when other invasive interventions are contraindicated. RND has at least temporal effect, and conditions causing sympathetic hyperactivation (for instance, tooth extraction) can be associated with an escape effect.

### Acknowledgement

Dr. Evgeny Mikhaylov has received speaker and consultation honoraria from Biosense Webster. Other authors have nothing to declare.

### References

- 1 Remo BF, Preminger M, Bradfield J, *et al.* Safety and efficacy of renal denervation as a novel treatment of ventricular tachycardia storm in patients with cardiomyopathy. *Heart Rhythm* 2014; 11: 541–546.
- 2 Hoffmann BA, Steven D, Willems S, Sydow K. Renal sympathetic denervation as an adjunct to catheter ablation for the treatment of ventricular electrical storm in the setting of acute myocardial infarction. *J Cardiovasc Electrophysiol* 2013; 24: 1175–1178.
- 3 Armaganijan LV, Staico R, Moreira DA, *et al.* 6-month outcomes in patients with implantable cardioverter-defibrillators undergoing renal sympathetic denervation for the treatment of refractory ventricular arrhythmias. *JACC Cardiovasc Interv* 2015; 8: 984–990.
- 4 Hilbert S, Rogge C, Papageorgiou P, *et al.* Successful single-sided renal denervation in drug-resistant hypertension and ventricular tachycardia. *Clin Res Cardiol* 2015; 104: 279–281.
- 5 Esler M, Guo L. The future of renal denervation. *Auton Neurosci* 2017; 204: 131–138.

This article is part of a Special Issue “**Arrhythmia management in elderly patients**”.  
Guest Editors: Evgeny N Mikhaylov, Tamas Szili-Torok and Dmitry S Lebedev