

Clinico-Radiological Efficacy of Posterior Instrumentation, Decompression, and Transpedicular Bone Grafting in Osteoporotic Burst Fracture Associated with Neurological Deficit

Abstract

Objective: The aim of this study is to evaluate clinico-radiological outcomes of posterior surgery (decompression + instrumentation + transpedicular bone graft) in osteoporotic burst fracture associated with neurological deficit [OFND]. **Materials and Methods:** Forty patients with neurological deficit due to delayed osteoporotic vertebral collapse managed by posterior surgery (decompression + instrumentation + transpedicular bone graft) with minimum 2 years follow-up were included in the study. Approval from the Institutional Review Board was taken. Demographic data (age, sex, mode of injury, and the severity of osteoporosis); clinical parameters (Visual Analog Score [VAS], Oswestry Disability Index [ODI], Frankel grade), radiological parameters (local kyphosis), and surgical variables (blood loss, surgery duration, and intraoperative events) were recorded. Neurological worsening/improvement, complications, and implant failures were noted. **Results:** Significant improvement was noted in VAS (preoperative 8.20 ± 0.65 /postoperative 4.1 ± 0.64) and ODI (preoperative 76.54 ± 6.96 /postoperative 30.5 ± 6.56). Complete neurological recovery was noted in 37 patients (Frankel Grade E), three patients remained nonambulatory (Frankel Grade C). Significant improvement was noted in local kyphosis angle (preoperative = 21.80 ± 2.70 ; postoperative 11.40 ± 1.80), with 10% loss of correction (2.5 ± 0.90) at final follow-up. Symptomatic implant failure was noted in two patients and proximal junctional failure in one patient requiring an extension of fixation. **Conclusions:** OFND can be managed with a single posterior-only surgery with significant improvement in neurology and functional scores of patients. Aggressive kyphosis correction is often not required and optimal correction of kyphosis is noticed due to prone-positioning alone. Transpedicular grafting is safe and simple alternative to cement augmentation or anterior surgery for collapsed vertebrae.

Keywords: *Kyphosis, neurological deficit, osteoporotic burst fracture, posterior surgery, surgical outcomes, transpedicular bone-graft*

Introduction

The incidence of osteoporotic spine fractures is gradually increasing with increasing life expectancy.^[1,2] Majority of these fractures are effectively managed conservatively.^[2,3] However, a small fraction of these innocuous fractures are associated with delayed collapse giving rise to progressive kyphosis and delayed neurological deficit.^[3-6] These cases need to be managed surgically with decompression and stabilization. The ideal surgical procedure remains controversial.^[3,7,8,9,10] Numerous authors have documented the efficacy of anterior or posterior or combined anterior plus posterior approaches. Morbidity of anterior approach in these fragile patients is well

documented in the literature.^[11,9] Obtaining sufficient purchase power of implants in the osteoporotic spine is technically demanding, and failure may lead to implant loosening, construct failure, and proximal junctional kyphosis.^[12-14] Cement augmentation of fracture vertebral body is also not recommended in these cases.^[15,9] We conducted a prospective study to evaluate a single, simple, and effective procedure for delayed neurological deficit associated with osteoporotic burst fractures utilizing a single posterior approach with transpedicular bone grafting (TPBG) of fractured vertebrae and instrumented fusion. We aimed to evaluate the clinico-radiological outcomes of posterior surgery, i.e., decompression, instrumentation, and TPBG in osteoporotic burst fracture associated with neurological deficit.

This is an open access journal, and articles are distributed under the terms of the Creative Commons Attribution-NonCommercial-ShareAlike 4.0 License, which allows others to remix, tweak, and build upon the work non-commercially, as long as appropriate credit is given and the new creations are licensed under the identical terms.

For reprints contact: reprints@medknow.com

How to cite this article: Mehta G, Patel A, Jain S, Merchant ZA, Kundnani V. Clinico-radiological efficacy of posterior instrumentation, decompression, and transpedicular bone grafting in osteoporotic burst fracture associated with neurological deficit. *Asian J Neurosurg* 2019;14:1207-13.

**Gaurav Mehta,
Ankit Patel,
Sanyam Jain,
Zahir Abbas
Merchant,
Vishal Kundnani**

*Bombay Hospital and Medical
Research Centre, Mumbai,
Maharashtra, India*

Address for correspondence:

*Dr. Sanyam Jain,
Bombay Hospital and Medical
Research Centre, Mumbai,
Maharashtra, India.
E-mail: jainsanyam933@gmail.
com*

Access this article online

Website: www.asianjns.org

DOI: 10.4103/ajns.AJNS_95_19

Quick Response Code:



Materials and Methods

Forty-nine (37 females and 12 males) consecutive patients presented with delayed onset neurological deficit following osteoporotic burst fracture underwent surgical management by posterior approach, decompression, TPBG, and posterior instrumentation during 2009–2016 with strict inclusion and exclusion criteria. Approval from the institutional review board and ethics was taken with informed patient consent.

Inclusion criteria

- Single level fracture due to trivial fall
- Osteoporosis dual-energy X-ray absorptiometry scan (DEXA) scan T score < -2.5
- Neurological deficit (Frankel Grade C, D)
- Burst fracture Magerl Type A with $>50\%$ collapse of the vertebral body
- Minimum 2 years follow-up.

Exclusion criteria

- Nonosteoporotic, other pathological fractures
- Patients not followed for 24 months
- Normal neurology.

Of 49 patients, six patients were lost to follow-up and three patients died due to medical causes in <12 months postoperatively. Forty patients were available for minimum 24 months follow-up and were included for the analysis and formed the study cohort.

Comprehensive clinico-radiological assessment was undertaken to ascertain the diagnosis of osteoporotic vertebral fracture, and all secondary causes of vertebral collapse were ruled out. Demographic data (age, sex, mode of injury, duration of injury to presentation, duration of neurological deficit, DEXA), clinical parameters (pain score - Visual Analog Score [VAS], functional score - Oswestry Disability Index [ODI], ambulatory status), neurological deficit (Frankel grade) were noted and recorded. Radiological evaluation included radiographs and magnetic resonance imaging of every patient. Radiological parameters – kyphosis angle was noted and recorded preoperatively and at each follow-up. Sagittal local kyphosis was measured from superior end plate of immediate, intact cephalic vertebrae, and inferior end plate of intact caudal vertebrae.^[9] Surgical parameters –operative time, intraoperative blood loss, and intraoperative complications were noted.

All patients underwent posterior approach for decompression, stabilization, and anterior vertebral cleft/body grafting by transpedicular approach using iliac crest autograft. No kyphoplasty, vertebroplasty, or cement augmentation of pedicle screw was done in any patient. No anterior surgery for decompression or reconstruction was done in any patient.

Patients were followed up for 24 months with regular sequential follow-up at 3 months, 6 months, 1, and 2 years

after surgery and annually then on. Neurological improvement, ambulatory status, and complications during this course were noted and documented. Localized kyphosis correction was assessed using radiographs of the spine. Fracture healing and fusion were assessed by dynamic plain radiograph and computed tomograms (CT) scans. Implant failure, pull out, proximal junctional failures, or adjacent level fractures were noted during the course of follow-up.

Surgical procedure

A standard midline posterior approach is used. Pedicle screws are inserted in two vertebral levels above and two vertebral levels below fracture and a screw in the fracture vertebrae is utilized as an additional anchor after transpedicular grafting. Often, the localized kyphosis gets corrected due to fracture site mobility in the prone position. No osteotomy is undertaken to correct the residual deformity. Both pedicles of fracture vertebrae are probed and serially expanded with blunt curettes (maximum up to 5 mm \times 5 mm) to facilitate TPBG. Anterior intravertebral cleft is addressed with debridement using angled curettes under fluoroscopic guidance. This debridement is carried out bilaterally from both pedicles [Figure 1].

After connecting rods and screw, unilateral hemilaminectomy at fracture level, with care to preserve midline and ipsilateral medial one-third facetectomy is performed. Anterior bony compression by retropulsed fragment, if any, indenting the canal is pushed anteriorly with a reverse-angled curette without causing any undue retraction of dura/conus. A 2 cm incision is placed over the posterior superior iliac spine (PSIS) to harvest the cancellous graft. The morcellized cancellous bone graft (around 10–12 cc) is placed into defect under fluoroscopic control till the vertebral cleft is packed with autograft.^[16] Posterolateral fusion with facet fusion of the stabilized segment is performed in all patients.

Postoperatively, patients are encouraged to sit up in bed 24 h after surgery and mobilized out of bed on the 2nd postoperative day using a thoracolumbar orthosis (TLSO). All patients are protected using TLSO for approximately 3 months after surgery. All patients started on standard anti-osteoporotic medications.

The statistical analysis was carried out using the paired Student's *t*-test. Differences were considered statistically significant at $P < 0.05$. Statistical analysis was performed using the SPSS software version 20.0 (SPSS Inc., Chicago, IL, USA).

Results

A total of 40 patients (36 females, 4 males) with a mean age 72.19 ± 7.43 years (65–93 years) were presented to us with delayed neurological deficit following osteoporotic burst fracture [Table 1 and Figure 2]. On presentation, neurological status was assessed using

Frankel grade (Frankel grade C = 21, grade D = 19). The most common mechanism of injury was a history of trivial fall (*N* = 18) followed by outdoor slips (*N* = 18), weight lifting (*N* = 2), and other causes were unknown (*N* = 2). The mean duration of delay in the presentation was 14.3 ± 2.9 weeks (10–21 weeks). The mean duration of the neurological deficit was 3.05 ± 1.0 weeks (1–4 weeks). All

patients underwent DEXA scan preoperatively, and mean T score was -3.79 ± -1.12 (-2.6 to -5.1).

Radiographs of spine demonstrated fracture at thoracolumbar junction with the following frequency: T10 *N* = 9, T11 *N* = 8, T12 fractures *N* = 14, L1 *N* = 7, L2 *N* = 2. Mean preoperative local kyphotic angle was $21.8^\circ \pm 2.7^\circ$.

Table 1: Patient demographic data

Variable	Value
Age years (range)	Mean 72.19 (65-93)
Male:female	4:36
Follow-up duration (month)	24 minimum (24-36)
Injury mechanism	
Trivial fall	
Outdoor slips	18
Weight lifting	2
Motor vehicle accident	0
Unknown	2
Delay in presentation (weeks)	Mean 14.3 (10-21)
Duration of neurological deficit	Mean 3 (1-4)
Dexa scan T score	Mean -3.79 (-2.6--5.1)
Fracture level	
T 10	<i>n</i> =9
T 11	<i>n</i> =8
T 12	<i>n</i> =14
L 1	<i>n</i> =7
L 2	<i>n</i> =2

Neurological evaluation

Preoperative neurological status assessed using Frankel grade (Frankel Grades C = 21 patients, Grade D = 19 patients). Postoperatively, 37 patients showed complete neurological recovery. One patient deteriorated neurologically from Grade D to Grade C and two patients did not show improvement in neurology, i.e., remained Frankel Grade C. At final follow-up, three patients remained nonambulatory [Table 2].

Radiological evaluation

Significant improvement in kyphosis from $21.8^\circ \pm 2.7^\circ$ preoperatively to $11.4^\circ \pm 1.8^\circ$ at immediate postoperative and $13.9^\circ \pm 2.0^\circ$ at 2 years follow-up noted. There was a significant difference between the preoperative local kyphosis angle and immediate postoperative local kyphosis angle and 2 years postoperative local kyphosis angle (*P* < 0.01). Final follow-up showed 10% loss of correction, i.e., mean $2.5^\circ \pm 0.9^\circ$ [Table 3] and [Figure 3]. All patients showed healing of fractures

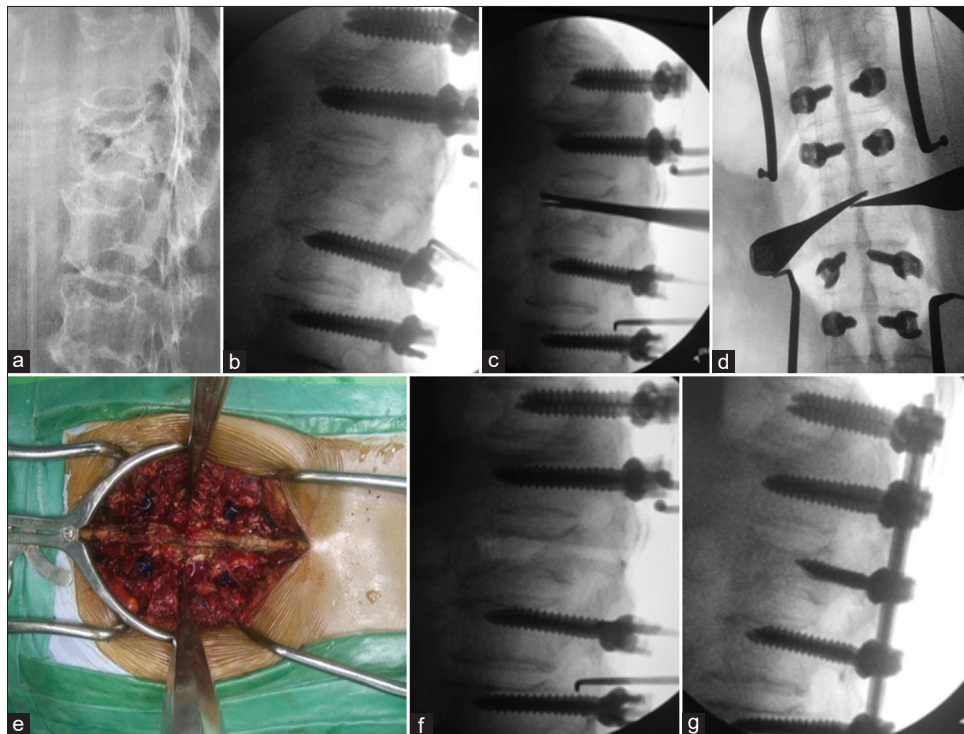


Figure 1: (a) Preoperative radiograph shows osteoporotic fracture with kummel's lesion and local kyphosis; (b) intra-operative radiographic image showing fracture site mobility and correction of local kyphosis after prone position on operative table; (c-e) serial expansion and dilatation of both pedicles of fracture vertebrae and debridement and preparation of Kummel's lesion with blunt tip curettes; (f) fracture vertebrae after debridement and preparation; (g) after uniform cancellous bone grafting and instrumentation of previously debrided and prepared fracture vertebrae

by 6–9 months follow-up as demonstrated on X-rays and CT scans [Figures 4 and 5].

Surgery

The mean surgical duration was 114.7 ± 20.1 min (range 90–145 min) and mean intra-operative blood loss was 329.6 ± 40.3 ml (range 270–400 ml). The hospital stay lasted a mean of 8 ± 3 days (range 5–11 days)

Complications

Early

Following surgery two patients developed superficial infection that resolved with antibiotics and regular dressing. Three patients developed urinary tract infection, one patient developed pneumonia; all managed by antibiotics alone. No patient developed intra-operative dural injury or nerve root injury.

Late

One patient developed proximal junctional failure at 11 months follow-up, and two patients developed screw pull out/failure at 5th and 7th months follow-up, respectively, and presented with increasing back pain and kyphosis which required revision surgery in the form of extension of the level of fixation. Hence, only three patients demonstrated implant-related complications which

is 7.5% and is fairly acceptable considering the poor bone stock of this subset of patients.

Two patients developed adjacent level fractures. These patients are asymptomatic without any evidence of further implant failure at recent follow-up.

Functional results

VAS demonstrated significant improvement from the preoperative value of mean 8.2 ± 0.65 to 3 weeks postoperative mean of 4.10 ± 0.64 and mean value of 3.20 ± 0.54 at final follow-up [Table 4]. ODI scores improved to mean value 30.5 ± 6.5 at 3 months follow-up, from preoperative mean value of 76.5 ± 6.9

Table 2: Pre- and post-operative neurological status using Frankel grading

Preoperative	Number of patients	Postoperative				
		A	B	C	D	E
A						
B						
C	21			2		19
D	19			1		18
E						

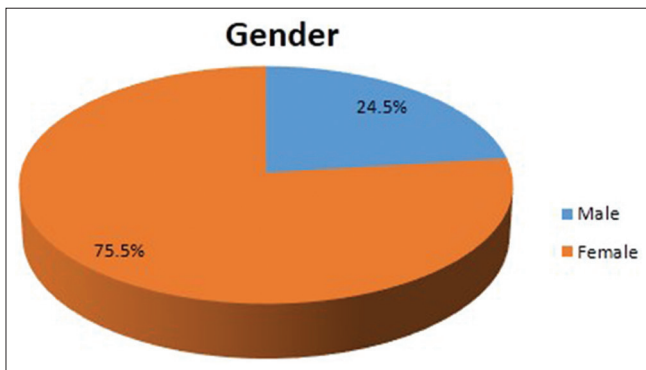


Figure 2: Patient's gender demographics

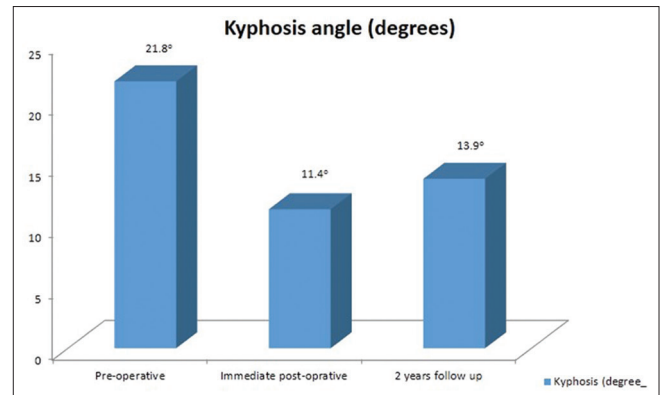


Figure 3: Radiological characteristics

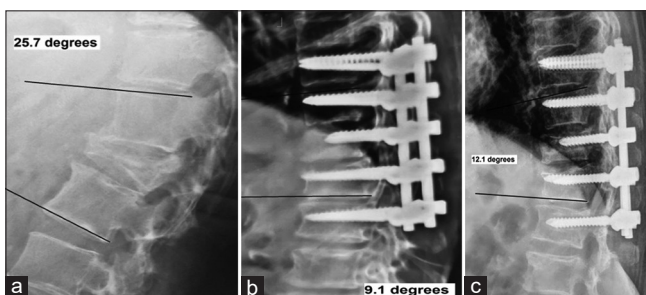


Figure 4: (a) A 75-year-old female presented with Frankel Grade C neurology. Preoperative radiograph depicted osteoporotic D12 fracture with local kyphosis of 25.7°; (b) 6 weeks postoperative radiograph with posterior fixation and instrumentation of fracture body with correction of local kyphosis to 9.1°; (c) two years follow-up lateral radiograph demonstrating healed fracture with slight loss of correction. Patient is ambulatory and able to perform activities of daily living

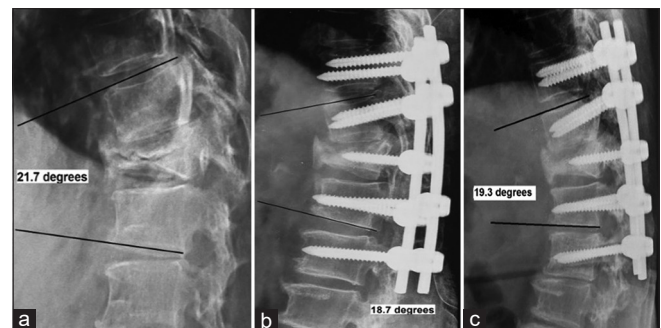


Figure 5: (a) A 64-year-old female presented with Frankel Grade C neurology. Preoperative radiograph depicted osteoporotic L1 fracture with kummel's lesion and local kyphosis of 21.7°; (b) 6 weeks post-operative radiograph with posterior fixation and instrumentation of fracture body with correction of local kyphosis to 18.7°; (c) two years follow-up lateral radiograph demonstrating healed fracture with minimal loss of correction. Patient is ambulatory without any support

Table 3: Radiological characteristics, surgery duration, and blood loss

Variable	Value
Kyphosis	
Preoperative	21.8±2.7°
Immediate postoperative	11.4±1.8°
Final follow-up	13.9±2.0°
Correction	7.9±0.7°
Loss of correction	2.5±0.9°
Surgery duration	114.7±20.1 min
Intraoperative blood loss	329.6±40.3 ml
Hospital stay	8±3 days

Table 4: Functional results of patients

	Mean±SD	P
VAS		
Preoperative	8.20±0.65	
Postoperative 3 weeks	4.10±0.64	Preoperative versus postoperative <0.05
Final follow-up	3.20±0.54	Preoperative versus final follow up <0.05
ODI		
Preoperative	76.50±6.9	<0.05; statistically significant
Postoperative 3 months follow-up	30.5±6.5	

VAS – Visual Analog Score; ODI – Oswestry Disability Index; SD – Standard deviation

and all, but three patients were nonambulatory at final follow-up [Table 4].

Discussion

Vertebral fractures are considered benign entity and are managed conservatively.^[1-3] However, in some patients, these benign fractures are associated with delayed collapse and insidious neurology involvement and kyphotic deformity.^[3-6] The study deals with this subset of patients with osteoporotic fractures with delayed collapse and neurological involvement with delayed presentation who were managed with posterior surgical decompression, fixation, and TPBG.

The specific operative intervention for patients with osteoporotic burst fracture and neurology involvement is controversial.^[3,7,8,9] Instrumentation of vertebrae in osteoporotic patients has been associated with a significant risk of failure like screw pull out, screw loosening, proximal junction failure, and adjacent segment fractures.^[8-15] Furthermore, there is controversy whether approach and stabilization should be anterior, posterior, or combined anterior-posterior.^[2,4,6,17,18,19,10] Various surgeons have evaluated their techniques and have made recommendations. Kaneda *et al.*^[6] asserted successful results with anterior decompression fusion using anterior instrumentation. Anterior surgery has the advantage of direct decompression of canal and reconstruction of the

anterior column. However, anterior surgery has been associated with morbidity and mortality as demonstrated in various studies.^[8,9,20]

Posterior surgery has some merits over anterior surgery. It poses insignificant risk of iatrogenic injury to thoracic and abdominal organs, also most spine surgeons are familiar with the posterior approach.^[20] Correction of kyphotic deformity is feasible using pedicle screws and is less technically demanding, have greater pull-out strength than anterior vertebral body screws as the body is affected more than pedicles in osteoporosis. Singh *et al.*^[21] in their series of osteoporotic vertebral burst fracture and medullary canal stenosis conducted osteosynthesis using posterior approach and had a good result with 20% complication rate, including neurological worsening. Uchida *et al.*^[9] demonstrated better kyphosis correction with the posterior approach but progressive loss of correction and results equivalent to anterior approach at final follow-up, without any difference in neurological status improvement.

Choma *et al.*^[15] and Kim *et al.*^[17] advocated cement augmentation of pedicle screws to increase the success rate of instrumentation, but according to Hu,^[13] the use of exothermic material in proximity to nerve roots should be avoided. Furthermore, Soshi *et al.*^[14] concluded that pull-out strength of pedicle screw did not mediate positive effect in biomechanical cadaveric vertebral bodies in severe cases of osteoporosis despite reinforcement with bone cement.

TPBG is a safer option as compared to kyphoplasty^[22] or vertebroplasty^[23,24] instead of adverse complications like leakage or embolism and is effective treatment tool.^[3,16,25] Previously, some studies^[26,27] have projected inconsistent outcomes after TPBG of fracture vertebrae, but Ma *et al.*^[28] in a systematic review have established the role of TPBG for the management of thoracolumbar fractures and it provides best bone healing.

Harvesting of graft from PSIS has been associated with donor site pain postoperatively, but according to Robertson and Wray,^[19] its incidence decreases significantly by 12 months. None of the patient in our study at 9 months follow-up complained of donor site pain, which is in agreement with the study of Liao *et al.*^[25]

Review of literature shows gross loss of correction in various studies after anterior/posterior surgeries. Knop *et al.*^[27] analyzed 76 patients and found that the mean loss of kyphosis correction was 9.7°, 63% of the initial correction was lost. Takenaka *et al.*^[11] concluded mean kyphosis correction loss of 11.2° ± 8.6°, 50% loss of correction in anterior surgery and mean correction loss of 11.1° ± 12.6°, i.e., 32.9% in the posterior surgery group. Uchida *et al.*^[9] had mean loss of kyphosis correction 4.6° ± 4.5° after posterior surgery group and mean loss of 4.5° ± 5.9° in the anterior surgery group, but at final follow-up kyphosis angle was not significantly different

between two groups. The mean kyphosis angle in our series before surgery was $21.8^\circ \pm 2.7^\circ$, immediate correction after surgery was to $11.4^\circ \pm 1.8^\circ$ and $13.9^\circ \pm 2.0^\circ$ at final follow-up. There was a significant difference in preoperative and immediate postoperative kyphotic angle ($P < 0.05$) and before surgery and at final follow-up ($P < 0.05$). The loss of correction was 10%, i.e., mean $2.5^\circ \pm 0.9^\circ$ in our series at final 2 years follow-up. Our technique demonstrates consistent result with lesser loss of kyphosis correction at final follow-up which is attributed to the instrumentation of fracture body, transpedicular autograft healing, and added posterolateral fusion. The interference screws offloaded TPBG during the healing phase and prevented collapse.^[29]

Adequate purchase of implant in osteoporotic vertebrae is an issue and complications like pull out are a great concern and implant-related complications have been demonstrated to be in range of 9%–54%.^[2,8,12,23] Wu *et al.*^[30] in their series of 157 patients demonstrated 12.9% failure rate of pedicle screw instrumentation in osteoporotic spine. DeWald and Stanley^[31] in their study documented 7% rate of implant breakage and 11% rate of pseudoarthrosis. Instrumentation failure noticed in only two patients in our series, i.e., 5%, which is comparatively lower and can be accounted to lesser stress on implant due to added posterolateral fusion, anterior column support by bone graft after healing^[16,9,25,28] and not trying to achieve full correction of kyphotic deformity by any maneuver, thus reducing stress on implants.^[31] Furthermore, all patients were kept in TLSO for 3 months duration postoperatively and were started anti-osteoporotic treatment, which increased both bone mass and quality of the bone marrow and pedicle cortex, thus helping to prevent implant loosening.

Suk *et al.*^[8] in series of 93 patients and Uchida *et al.*^[9] in series of 83 patients with osteoporotic delayed vertebral collapse with neurological deficit showed no significant difference in neurological recovery for anterior surgery versus posterior surgery. Similarly, Kashii *et al.*^[32] did not find significant difference in neurology improvement and pain scores between anterior and posterior surgery. Verlaan *et al.*,^[10] in their systemic review, concluded potential for neurological recovery was nondependent on the surgical approach. In our series, of 40 patients, 37 patients improved in neurology from Frankel Grade C to Grade E, 1 worsened from Grade D to Grade C, whereas two patients did not improve and remained Frankel Grade C. About 92.5% of patients in the study group demonstrated improvement in neurology which is statistically significant ($P < 0.05$).

Verlaan *et al.*,^[10] in their systemic review and Kashii *et al.*,^[32] demonstrated equivalent pain relief and functional status when comparing posterior surgery versus anterior surgery. Takenaka *et al.*^[11] showed better outcomes in terms of back pain and ambulatory status with posterior surgery than anterior surgery. In our series, we preferred only posterior surgery, and VAS pain scores improved from

preoperative value of 8.20 ± 0.65 to 1-week postoperative VAS score 4.10 ± 0.64 , which on final follow-up was 3.20 ± 0.54 ($P < 0.05$). Preoperative ODI functional scores also significantly improved ($P < 0.05$) from 76.5 ± 6.9 to 3 months postoperative value of 30.5 ± 6.5 .

The study is limited by small sample size, absence of any randomized control patient cohort and relatively shorter follow-up. Studies with the larger patient cohort and longer follow-up are required for confirmation of our results, which in the present study are concluded from valid outcome measures.

Conclusions

The management of osteoporotic fracture with collapse and delayed neurology involvement is controversial and challenging. The outcome of this study suggests that posterior decompression, TPBG, and pedicle screw fixation is reliable technique in terms of neurological, morbidity, deformity, and functional improvement for patients. It presents the advantages of posterior approach and maintained kyphosis correction with significantly less operative time and blood loss. It is a better alternative to other surgical modalities for the management of this subset of patients.

We believe the following are advantages of our technique:

1. Reliable improvement in neurology in the majority of patients
2. Shorter operative time and less intra-operative blood loss
3. Decreased postoperative morbidity
4. Reliable correction of the kyphotic deformity
5. Comparable improvement in functional scores.

Financial support and sponsorship

Nil.

Conflicts of interest

There are no conflicts of interest.

References

1. Keen RW. Burden of osteoporosis and fractures. *Curr Osteoporos Rep* 2003;1:66-70.
2. Frost HM. Clinical management of the symptomatic osteoporotic patient. *Orthop Clin North Am* 1981;12:671-81.
3. Nakashima H, Yukawa Y, Ito K, Machino M, Ishiguro N, Kato F, *et al.* Combined posterior-anterior surgery for osteoporotic delayed vertebral fracture with neurologic deficit. *Nagoya J Med Sci* 2014;76:307-14.
4. Baba H, Maezawa Y, Kamitani K, Furusawa N, Imura S, Tomita K, *et al.* Osteoporotic vertebral collapse with late neurological complications. *Paraplegia* 1995;33:281-9.
5. Korovessis P, Maraziotis T, Piperis G, Spyropoulos P. Spontaneous burst fracture of the thoracolumbar spine in osteoporosis associated with neurological impairment: A report of seven cases and review of the literature. *Eur Spine J* 1994;3:286-8.
6. Kaneda K, Asano S, Hashimoto T, Satoh S, Fujiya M. The

- treatment of osteoporotic-posttraumatic vertebral collapse using the Kaneda device and a bioactive ceramic vertebral prosthesis. *Spine (Phila Pa 1976)* 1992;17:S295-303.
7. Sudo H, Ito M, Abumi K, Kotani Y, Takahata M, Hojo Y, *et al.* One-stage posterior instrumentation surgery for the treatment of osteoporotic vertebral collapse with neurological deficits. *Eur Spine J* 2010;19:907-15.
 8. Suk SI, Kim JH, Lee SM, Chung ER, Lee JH. Anterior-posterior surgery versus posterior closing wedge osteotomy in posttraumatic kyphosis with neurologic compromised osteoporotic fracture. *Spine (Phila Pa 1976)* 2003;28:2170-5.
 9. Uchida K, Nakajima H, Yayama T, Miyazaki T, Hirai T, Kobayashi S, *et al.* Vertebroplasty-augmented short-segment posterior fixation of osteoporotic vertebral collapse with neurological deficit in the thoracolumbar spine: Comparisons with posterior surgery without vertebroplasty and anterior surgery. *J Neurosurg Spine* 2010;13:612-21.
 10. Verlaan JJ, Diekerhof CH, Buskens E, van der Tweel I, Verbout AJ, Dhert WJ, *et al.* Surgical treatment of traumatic fractures of the thoracic and lumbar spine: A systematic review of the literature on techniques, complications, and outcome. *Spine (Phila Pa 1976)* 2004;29:803-14.
 11. Takenaka S, Mukai Y, Hosono N, Fuji T. Major surgical treatment of osteoporotic vertebral fractures in the elderly: A comparison of anterior spinal fusion, anterior-posterior combined surgery and posterior closing wedge osteotomy. *Asian Spine J* 2014;8:322-30.
 12. Halvorson TL, Kelley LA, Thomas KA, Whitecloud TS 3rd, Cook SD. Effects of bone mineral density on pedicle screw fixation. *Spine (Phila Pa 1976)* 1994;19:2415-20.
 13. Hu SS. Internal fixation in the osteoporotic spine. *Spine (Phila Pa 1976)* 1997;22:43S-48S.
 14. Soshi S, Shiba R, Kondo H, Murota K. An experimental study on transpedicular screw fixation in relation to osteoporosis of the lumbar spine. *Spine (Phila Pa 1976)* 1991;16:1335-41.
 15. Choma TJ, Pfeiffer FM, Swope RW, Hirner JP. Pedicle screw design and cement augmentation in osteoporotic vertebrae: Effects of fenestrations and cement viscosity on fixation and extraction. *Spine (Phila Pa 1976)* 2012;37:E1628-32.
 16. Van Herck B, Leirs G, Van Loon J. Transpedicular bone grafting as a supplement to posterior pedicle screw instrumentation in thoracolumbar burst fractures. *Acta Orthop Belg* 2009;75:815-21.
 17. Kim HS, Park SK, Joy H, Ryu JK, Kim SW, Ju CI, *et al.* Bone cement augmentation of short segment fixation for unstable burst fracture in severe osteoporosis. *J Korean Neurosurg Soc* 2008;44:8-14.
 18. Sasso RC, Cotler HB, Reuben JD. Posterior fixation of thoracic and lumbar spine fractures using DC plates and pedicle screws. *Spine (Phila Pa 1976)* 1991;16:S134-9.
 19. Robertson PA, Wray AC. Natural history of posterior iliac crest bone graft donation for spinal surgery: A prospective analysis of morbidity. *Spine (Phila Pa 1976)* 2001;26:1473-6.
 20. Kim KT, Suk KS, Kim JM, Lee SH. Delayed vertebral collapse with neurological deficits secondary to osteoporosis. *Int Orthop* 2003;27:65-9.
 21. Singh K, Heller JG, Samartzis D, Price JS, An HS, Yoon ST, *et al.* Open vertebral cement augmentation combined with lumbar decompression for the operative management of thoracolumbar stenosis secondary to osteoporotic burst fractures. *J Spinal Disord Tech* 2005;18:413-9.
 22. Blondel B, Fuentes S, Metellus P, Adetchessi T, Pech-Gourg G, Dufour H, *et al.* Severe thoracolumbar osteoporotic burst fractures: Treatment combining open kyphoplasty and short-segment fixation. *Orthop Traumatol Surg Res* 2009;95:359-64.
 23. Chen JF, Wu CT, Lee ST. Percutaneous vertebroplasty for the treatment of burst fractures. Case report. *J Neurosurg Spine* 2004;1:228-31.
 24. Katsumi K, Hirano T, Watanabe K, Ohashi M, Yamazaki A, Ito T, *et al.* Surgical treatment for osteoporotic thoracolumbar vertebral collapse using vertebroplasty with posterior spinal fusion: A prospective multicenter study. *Int Orthop* 2016;40:2309-15.
 25. Liao JC, Fan KF, Keorochana G, Chen WJ, Chen LH. Transpedicular grafting after short-segment pedicle instrumentation for thoracolumbar burst fracture: Calcium sulfate cement versus autogenous iliac bone graft. *Spine (Phila Pa 1976)* 2010;35:1482-8.
 26. Alanay A, Acaroğlu E, Yazici M, Aksoy C, Surat A. The effect of transpedicular intracorporeal grafting in the treatment of thoracolumbar burst fractures on canal remodeling. *Eur Spine J* 2001;10:512-6.
 27. Knop C, Fabian HF, Bastian L, Blauth M. Late results of thoracolumbar fractures after posterior instrumentation and transpedicular bone grafting. *Spine (Phila Pa 1976)* 2001;26:88-99.
 28. Ma Y, Li X, Dong J. Is it useful to apply transpedicular intracorporeal bone grafting to unstable thoracolumbar fractures? A systematic review. *Acta Neurochir (Wien)* 2012;154:2205-13.
 29. Farrokhi MR, Razmkon A, Maghami Z, Nikoo Z. Inclusion of the fracture level in short segment fixation of thoracolumbar fractures. *Eur Spine J* 2010;19:1651-6.
 30. Wu ZX, Gong FT, Liu L, Ma ZS, Zhang Y, Zhao X, *et al.* A comparative study on screw loosening in osteoporotic lumbar spine fusion between expandable and conventional pedicle screws. *Arch Orthop Trauma Surg* 2012;132:471-6.
 31. DeWald CJ, Stanley T. Instrumentation-related complications of multilevel fusions for adult spinal deformity patients over age 65: Surgical considerations and treatment options in patients with poor bone quality. *Spine (Phila Pa 1976)* 2006;31:S144-51.
 32. Kashii M, Yamazaki R, Yamashita T, Okuda S, Fujimori T, Nagamoto Y, *et al.* Surgical treatment for osteoporotic vertebral collapse with neurological deficits: Retrospective comparative study of three procedures – Anterior surgery versus posterior spinal shorting osteotomy versus posterior spinal fusion using vertebroplasty. *Eur Spine J* 2013;22:1633-42.