



## CASE REPORT

# Combination of a leadless pacemaker and subcutaneous implantable cardioverter defibrillator therapy for a Japanese patient with prosthetic valve endocarditis

Ryo Ito MD<sup>1</sup> | Yusuke Kondo MD, PhD<sup>2</sup>  | Joachim Winter MD, PhD<sup>3</sup> |  
Tomohiko Hayashi MD<sup>1</sup> | Miyo Nakano MD<sup>1</sup> | Takatsugu Kajiyama MD, PhD<sup>1</sup>  |  
Masahiro Nakano MD, PhD<sup>2</sup> | Yoshio Kobayashi MD, PhD<sup>1</sup>

<sup>1</sup>Department of Cardiovascular Medicine, Chiba University Graduate School of Medicine, Chiba, Japan

<sup>2</sup>Department of Advanced Cardiorhythm Therapeutics, Chiba University Graduate School of Medicine, Chiba, Japan

<sup>3</sup>Department of Cardiology and Rhythmology, Augusta Hospital, Duesseldorf, Germany

**Correspondence**

Yusuke Kondo, Department of Advanced Cardiovascular Therapeutics, Chiba University Graduate School of Medicine, Chiba, Japan.  
Email: yuusukondou-circ@umin.ac.jp

**Abstract**

The subcutaneous implantable cardioverter defibrillator (S-ICD) system was developed for defibrillation therapy that does not affect the heart and vasculature. S-ICD is preferred over transvenous ICD for patients with a history of recurrent infection presenting with life-threatening rhythms. Patients with bradycardia pacing indications are excluded from S-ICD therapy, as S-ICD lacks the capability of defibrillation in this patient group. Implantation of an S-ICD with a leadless pacemaker (LP) was proposed to overcome this issue. We describe the first case of successful implantation of S-ICD and LP in a Japanese patient with a history of recurrent prosthetic valve endocarditis.

**KEYWORDS**

Bradycardia, infection, leadless pacemaker, prosthetic valve endocarditis, subcutaneous implantable cardioverter defibrillator

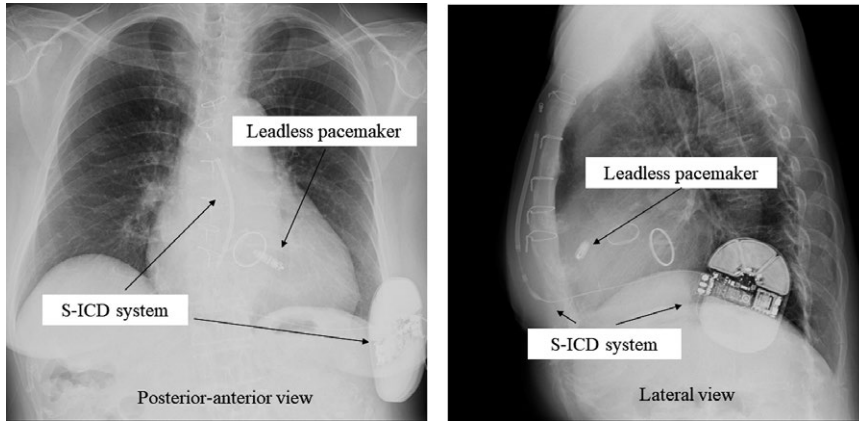
## 1 | INTRODUCTION

Entirely subcutaneous implantable cardioverter defibrillators (S-ICD™; Boston Scientific Corp., Marlborough, MA, USA) provide effective defibrillation and reduce the risk of infection or lead problems.<sup>1-3</sup> However, as patients with bradycardia pacing indications are excluded from S-ICD therapy because the device lacks the capability for defibrillation in this patient group, they are used less than transvenous implantable cardioverter defibrillators (ICDs). Leadless pacemaker (LP) systems have recently been developed, and their combined use with S-ICD provides a potential solution to the problem with S-ICD use without transvenous leads for patients with an ICD together with pacing indications.<sup>1</sup> The LP system was approved for use in Japan in September 2017.

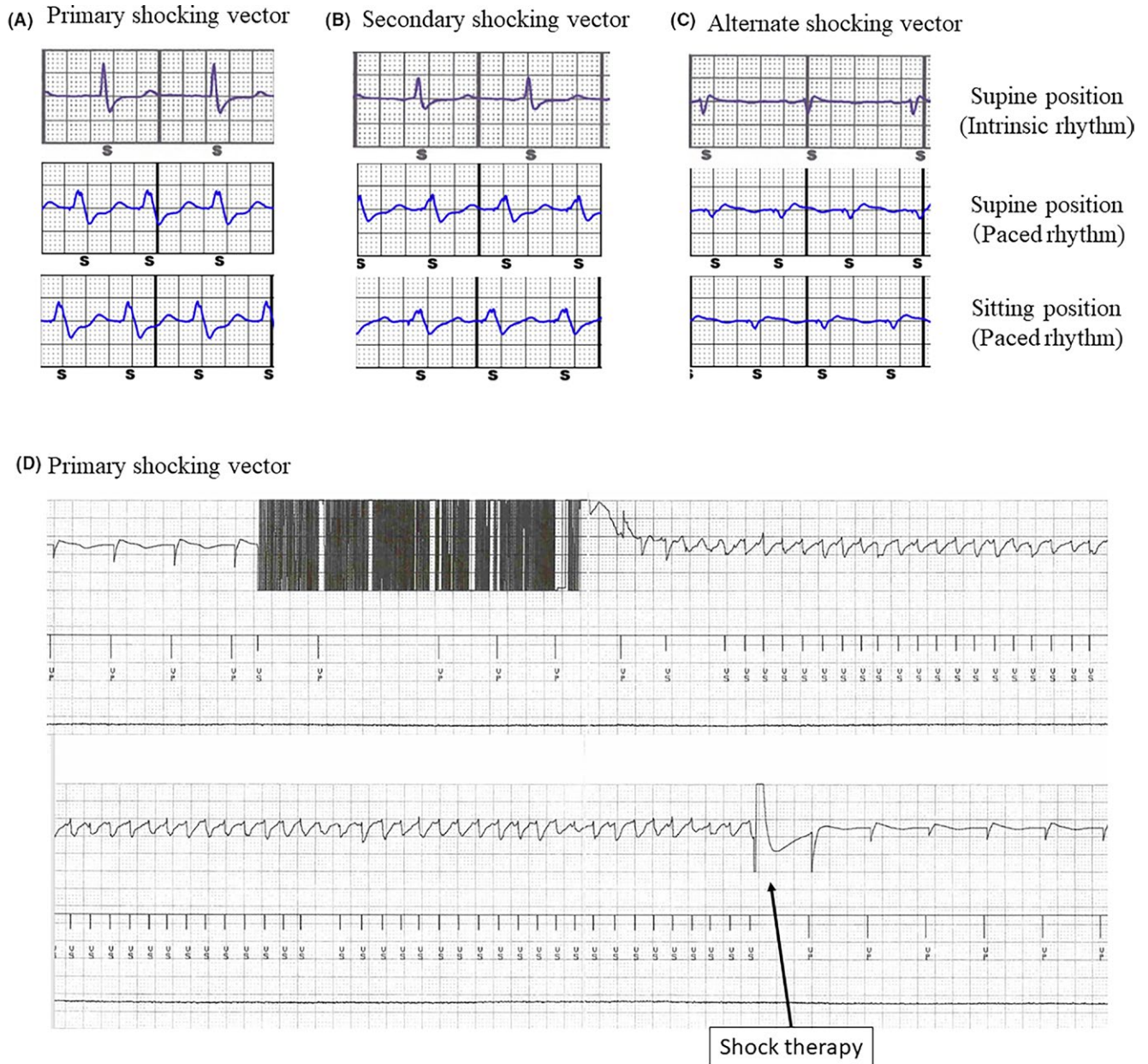
## 2 | CASE REPORT

A 72-year-old woman who underwent aortic valve replacement surgery because of aortic valve regurgitation with heart failure in 2010 and aortic valve re-replacement and mitral valve replacement surgery because of prosthetic valve endocarditis (PVE) in 2014 presented to our department. It was determined that she needed life-long antibiotic therapy because she had repetitive PVE caused by *Staphylococcus agaraetiae*.

In 2018, she experienced sustained ventricular tachycardia, and her left ventricular ejection fraction was 45%. Considering the history of recurrent infection, S-ICD was preferred over transvenous ICD. Therefore, she received an S-ICD for secondary prophylaxis against sudden cardiac death. The generator automatically selected a secondary shocking vector as the optimal sensing and gain selection



**FIGURE 1** Posterior-anterior and lateral views of the leadless pacemaker and subcutaneous implantable cardioverter defibrillator systems



**FIGURE 2** Subcutaneous cardioverter defibrillator recordings in primary (A), secondary (B), and alternate (C) shock vectors during intrinsic and paced rhythms (VOO 100 ppm; 5.0 V at 1.0 milliseconds) in the supine and sitting positions. Leadless pacemaker electrogram recording during and after the defibrillation threshold testing (VOO 90 bpm, bipolar, output 5.0 V at 1.0 milliseconds) (D)

configuration. At the end of the procedure, ventricular fibrillation (50 Hz burst stimulation between shock coil and generator) was induced and successfully terminated by a 65 J shock (15 J safety margin).

After S-ICD implantation, she started taking oral antiarrhythmic drugs (amiodarone 200 mg/d and carvedilol 5 mg/d); however, sinus bradycardia prevented her from taking sufficient amounts of antiarrhythmic drugs. Twenty-seven days after S-ICD implantation, she received appropriate shock therapy for ventricular tachycardia. Therefore, she received a LP (Micra™; Medtronic Plc, Minneapolis, MN). This pacemaker was implanted on the right ventricular septum via the right femoral vein (Figure 1). The measured R wave was 10.1 mV; impedance, 840 Ohms; and threshold, 0.50 V at 0.24 milliseconds. The lower rate limit was programmed to 40 beats/min, and the rate adaptive pacing was also programmed. No interactions were observed when the LP was programmed to a high output (5.0 V at 1.0 milliseconds). The S-ICD was tested in primary, secondary, and alternative sensing vectors. All three vectors were suitable without any signs of cross talk between the S-ICD and the LP. The pulse generator automatically selected the secondary vector as the optimal sensing configuration (Figure 2). We performed a conversion test (50 Hz burst stimulation) again. Unfortunately, we were not able to induce ventricular fibrillation. Ventricular tachycardia could be induced and was successfully terminated by a 65 J shock (15 J safety margin) twice. The S-ICD was programmed at the secondary sensing configuration: 65 J output, standard polarity, shock zone 170 bpm, and post shock pacing off. No device interactions were noted in this worst-case scenario as the LP (VOO 90 ppm, bipolar, output 5.0 V at 1.0 milliseconds) continued to function as programmed during and after the shock (Figure 2). Pacing enabled the patient to start optimal antiarrhythmic medical therapy. The assessment of the LP revealed 44% ventricular pacing. At 6 months follow-up, life-threatening arrhythmia and signs of infection were not observed.

### 3 | DISCUSSION

The LP is expected to reduce cardiac implantable electronic device infections because this system has no physical connection between the endocardium and subcutaneous pocket.<sup>2</sup> Moreover, the contact surface is small, and the composition of the device's surface was not adequately viable for bacteria. Indeed, there have been no reports of uncontrollable infection with LPs so far. No device has to be explanted despite infection.<sup>4</sup>

There have been reports that the problem associated with S-ICD use in bradycardic patients could be solved by combining it with LPs.<sup>1</sup> Key concerns with S-ICD and LP combined therapy are that pacing pulses might be sensed by the S-ICD and may interfere with ventricular arrhythmia or post shock pacing support. Therefore, pacemakers should be programmed to stimulate in a bipolar mode in order to avoid double counting by the S-ICD when using these two technologies.

In this article, we reported an S-ICD implantation and LP for the first time in a Japanese patient with recurrent PVE. There were no associated complications with the device implantation and no interaction between the S-ICD and LP during telemetry communication at

the time of implantation. The combination of the S-ICD and LP may expand the indication of device implantation for cases wherein an intravenous lead is difficult to place. Although reports of these implants are currently increasing, there is a possibility that unexpected responses may be obtained when treating arrhythmia or that the sensitivity may change, so it is necessary to carefully follow the clinical course of the patient. For patients in need of antitachycardia pacing (ATP) therapy, there are no leadless solutions available to date. Recently, a preclinical study described the results of performance of the combined implantation of an S-ICD and ATP-enabled LP.<sup>5</sup> In the immediate future, ATP delivery may be demonstrable by the LP in clinical practice.

### 4 | CONCLUSIONS

We report the first case of successful implantation of an S-ICD and a LP in a Japanese patient with recurrent PVE. There were no associated complications with the device implantation, and there was no interaction between the S-ICD and LP.

#### CONFLICT OF INTEREST

Authors declare no conflict of interests for this article.

#### ORCID

Yusuke Kondo  <https://orcid.org/0000-0003-4985-6929>

Takatsugu Kajiyama  <http://orcid.org/0000-0003-3990-7120>

#### REFERENCES

1. Ahmed FZ, Cunningham C, Motwani M, et al. Totally leadless dual-device implantation for combined spontaneous ventricular tachycardia defibrillation and pacemaker function: a first report. *Can J Cardiol*. 2017;33(8):1066; e-7.
2. Kondo Y, Ueda M, Kobayashi Y, et al. New horizon for infection prevention technology and implantable device. *J Arrhythm*. 2016;32(4):297-302.
3. Kondo Y, Ueda M, Winter J, et al. Successful intermuscular implantation of subcutaneous implantable cardioverter defibrillator in a Japanese patient with pectus excavatum. *J Arrhythm*. 2016;33(1):63-5.
4. El-Chami MF, Al-Samadi F, Clementy N, et al. Updated performance of the Micra transcatheter pacemaker in the real-world setting: a comparison to the investigational study and a transvenous historical control. *Heart Rhythm*. 2018;15(6):841-6.
5. Tjong FVY, Brouwer TF, Koop B, et al. Acute and 3-month performance of a communicating leadless antitachycardia pacemaker and subcutaneous implantable defibrillator. *JACC Clin Electrophysiol*. 2017;3(13):1487-98.

**How to cite this article:** Ito R, Kondo Y, Winter J, et al. Combination of a leadless pacemaker and subcutaneous implantable cardioverter defibrillator therapy for a Japanese patient with prosthetic valve endocarditis. *J Arrhythmia*. 2019;35:311-313. <https://doi.org/10.1002/joa3.12152>