



The nodule in the emphysematous lung: an appeal for surgery in a lung volume reduction concept

Till Plönes¹, Alexis Slama¹, Gernot Seebacher¹, Jan Viehof¹, Özlem Okumus¹, Dirk Theegarten², Kaid Darwiche³, Christian Taube³, Clemens Aigner¹

¹Department of Thoracic Surgery and Thoracic Endoscopy, Ruhrlandklinik, West German Cancer Center, University Hospital Essen, University Duisburg-Essen, Essen, Germany; ²Institute of Pathology, West German Cancer Center, University Hospital Essen, University Duisburg-Essen, Essen, Germany; ³Department of Pulmonary Medicine, Ruhrlandklinik, West German Lung Center, University Hospital Essen, University Duisburg-Essen, Essen, German

Contributions: (I) Conception and design: T Plönes; (II) Administrative support: C Aigner; (III) Provision of study materials or patients: T Plönes, C Aigner; (IV) Collection and assembly of data: T Plönes, Ö Okumus, G Seebacher, A Slama, J Viehof; (V) Data analysis and interpretation: T Plönes; (VI) Manuscript writing: All authors; (VII) Final approval of manuscript: All authors.

Correspondence to: Till Plönes, MD. National Center for Tumor Diseases (NCT/UCC), Dresden, Germany; German Cancer Research Center (DKFZ), Heidelberg, Germany; Faculty of Medicine and University Hospital Carl Gustav Carus, Technische Universität Dresden, Dresden, Germany; Helmholtz-Zentrum Dresden - Rossendorf (HZDR), Dresden, Germany. Email: Till.Ploenes@uk-essen.de.

Background: Emphysema patients, who are candidates for lung volume reduction surgery (LVRS) usually present with an extensive smoking history and thus have an increased risk for lung. The incidence of pulmonary nodules in emphysematous lungs is high. We therefore aimed to analyse the incidence and histological findings of pulmonary nodules in our LVRS program.

Methods: We conducted a retrospective review of all patients who underwent LVRS between 2016 and 2018. Data concerning preoperative workup, 30 days mortality and histopathological findings analysed.

Results: Between 2016 and 2018, LVRS was performed in 66 patients. In 18 (27%) a nodule was found in the preoperative computed tomography (CT) scan. Histological findings revealed in two cases squamous cell lung cancer. In two other cases, histopathological findings revealed an anthracotic intrapulmonary lymph node. In eight cases, a tuberculoma was found with a positive culture in one case. The other six histopathological findings were hamartoma, granuloma or sequelae of pneumonia.

Conclusions: Malignancy was found in 11.1% of patients presenting with a nodule in preoperative LVRS workup. The relative risk of lung cancer in emphysema patients is increased and if LVRS criteria are fulfilled surgical resection of a pulmonary nodule is a meaningful way to verify the histology.

Keywords: Lung volume reduction surgery (LVRS); bronchoscopic lung volume reduction (BLVR); national emphysema treatment (NETT) trial; non-small cell lung cancer (NSCLC); chronic obstructive pulmonary disease (COPD)

Submitted Jul 02, 2022. Accepted for publication Feb 03, 2023. Published online May 11, 2023.

doi: 10.21037/jtd-22-915

View this article at: <https://dx.doi.org/10.21037/jtd-22-915>

Introduction

Pulmonary emphysema is characterized by hyperinflation of the lungs and consecutive impairment of in chest wall and diaphragmatic breathing mechanics. It decreases quality of life and increases mortality significantly. Chronic obstructive pulmonary disease (COPD) affects over 60 million people

worldwide and is therefore a high socio-economic burden. Therapeutical approaches include smoking cessation, pulmonary rehabilitation and pharmacological therapies, but response to these therapies is limited. Lung volume reduction surgery (LVRS) is a viable treatment for end stage emphysema. It decreases dyspnea, improves lung

functional parameter and quality of life. In 2003 the National Emphysema Treatment Trial (NETT) confirmed these results and proofed a prolonged survival in patients with heterogeneous emphysema and low exercise capacity treated with LVRS. However due to misinterpretation of the study results LVRS remained an underused procedure (1,2). Despite the demonstrated benefits there was an initial decline in the number of LVRS procedures performed in the United States since the publication of the NETT trial (3) and bronchoscopic lung volume reduction (BLVR) using endobronchial valves evolved as an alternative to surgery (4). BLVR aims to induce unilateral lobar atelectasis to achieve the volume reduction effect. Besides valves other approaches like sclerosing therapies with foam/hydrogel or thermal vapor, stents, occluders and coils were studied, however evidence remains limited and due to side effects the use of some devices was discontinued (5). Trials directly comparing LVRS to BLVR are ongoing, however no results have been published yet [CELEB (ISRCTB19684749), SINCERE (NCT04537182), CLUB-HE (NCT04781582)]. Most patients with emphysema are current or former smokers and these patients have a high risk for lung cancer (6). If additional nodules or CT findings are present valves are not recommended and LVRS allows resection of the suspicious finding if located in a target area. There are only few studies dealing with this topic (7-9). The aim of this study was to investigate the incidence of pulmonary nodules and the histopathological diagnosis in a cohort of LVRS patients. We present this article in accordance with the STROBE reporting checklist (available at <https://jtd.amegroups.com/article/view/10.21037/jtd-22-915/rc>).

Highlight box

Key findings

- Pulmonary nodules in the emphysematous lungs have a high probability of malignancy even if usual CT criteria are not applicable.

What is known and what is new?

- There are only little data dealing with this, but in a study with 325 patients screened for LVRS 16% had a pulmonary nodule.
- If a node exists in a patient with emphysema, there is a high probability that it is clinically relevant

What is the implication, and what should change now?

- A surgical lung volume reduction is the treatment of choice if a nodule is detected in the target zone. BLVR should not be performed.

Methods

A retrospective review of our institutional LVRS database between 2016 and 2018 was performed. The study was conducted in accordance with the Declaration of Helsinki (as revised in 2013). The study was approved by Institutional Ethics Committee of University Hospital Essen (No. 19-8993-BO) and individual consent for this retrospective analysis was waived.

Patients who underwent LVRS and simultaneous resection of a pulmonary nodule were further analyzed. All patients underwent a standardized preoperative workup and were discussed in our internal emphysema board (10). In case of malignancy, histopathological findings were classified according to World Health Organization (WHO) criteria (11). Lung function parameters like forced expiratory volume in one second (FEV1), forced vital capacity (FVC), vital capacity (VC), residual capacity (RV), diffusion capacity of CO (DL_{CO}) and total lung capacity (TLC) were assessed according to the guidelines of ERS/ATS (12,13). Each parameter was specified in percentage (%). Pulmonary function was measured prior to surgery. Evaluation included computed tomography (CT) of the chest, perfusion scan, blood gas analysis, bodyplethysmography, spirometry, diffusion capacity and a cardiac functional assessment. Each case was discussed in our emphysema conference. The indication for surgery was based on the NETT criteria, although an individual indication at lower parameters was also possible if clinical success was achievable. All patients were also evaluated for transplantation. But transplanted patients were excluded from the study.

Statistical analysis

All patients also undergo statistical analysis which was conducted by using MedCalc software Version 11.6.1.0 (MedCalc software, Broekstraat 52, 9030 Mariakerke, Belgium). Parameter was given as median with its range.

Results

Between 2016 and 2018, 66 patients underwent LVRS (Figure 1). There were 31 male and 35 female patients. COPD III/IV was prevalent in all patient and emphysema morphology was heterogeneous as defined by Bloch *et al.* (14). Median age was 61.5 years (range, 37–77) at the time of surgery and median body mass index (BMI) was 23 kg/m² (range, 15–30). Median FEV1% was 27.8%

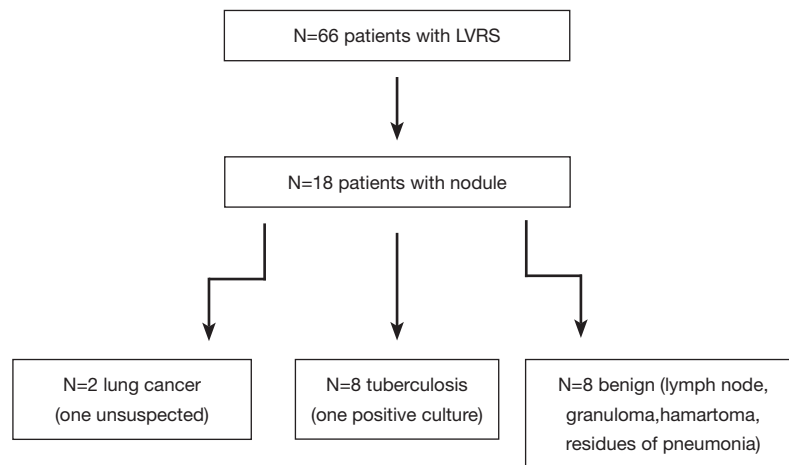


Figure 1 The LVRS cohort operated in our department between 2016 and 2018 and subgroup with the further analyzed 18 patients with a pulmonary nodule in the region of interest according to the final histology. LVRS, lung volume reduction surgery.

Table 1 Patients characteristics of 18 patients with pulmonary nodule in the emphysematous lung

Characteristics	Value
Gender (female/male)	6/12
Median age, years	65 (51 to 78)
Median FEV1 in %	25% (21% to 33%)
Median RV in %	264% (161% to 324%)
Median TLC in %	133% (117% to 171%)
Median DL _{CO} in %	20% (12.5% to 39%)

FEV1 in %, forced expiratory volume in 1 second predicted in percent; RV in %, residual volume predicted in percent; TLC in %, total lung capacity predicted in percent; DL_{CO} in %, diffusing capacity.

(range, 15–43%) and median DL_{CO} was 26.5% (range, 12.5–45.8%). Out of these 66 patients 18 patients (29%) had a pulmonary nodule (Table 1). In this further analyzed subgroup 12 patients were male and 6 female patients. All but three had a thoracoscopic approach (Table 2). In the three remaining patients, anterolateral thoracotomy was performed due to adhesions. In all cases LVRS was performed in the upper lobe (3 on the left and 15 on the right side). Median hospital stay was 14 days (range, 7–33 days) with no 30-days mortality. A prolonged air leak of more than 5 days postoperative was documented in nine cases and in one case a postoperative pneumonia. Histological findings revealed in two cases squamous lung cancer (Table 3). In two other cases, histopathological

Table 2 Characteristics of the LVRS procedure of the subgroup with nodule

Characteristics	Value
Side	
UL	16
UL and LL	2
Location	
Left side	3
Right side	15
Surgical approach	
aTht	4
VATS	14
LAD	5
Complications	
Air leak >5 days	5
Pneumonia	1
30-day mortality	None
Median hospital stay, days	14

LVRS, lung volume reduction surgery; UL, upper lobe; LL, lower lobe; aTht, anterolateral thoracotomy; VATS, video-assisted thoracoscopy; LAD, radical lymphadenectomy.

findings revealed an anthracotic intrapulmonary lymph node. In eight cases a tuberculoma was with a positive culture in one case. The other six histopathological findings were hamartoma, granuloma or sequelae of pneumonia.

Table 3 Characteristics of the resected nodule

Characteristics in preoperative CT scan	Size of the nodule in CT scan, mm	Size of the nodule in pathological report, mm	Histology
Oval, well-demarcated	20	18	Squamous lung cancer
Round, smooth-shaped	6	ND	Anthraxotic lymph node
Ragged, irregular margin	14	17	Tuberculosis
Ragged, irregular margin	8	ND	Tuberculosis
Ragged, irregular margin	3	9	Post-pneumonic
Halo with ground-glass like zones	3.2	ND	Tuberculosis
Ragged, irregular margin	3.5	4.6	Squamous lung cancer
Consolidation	2	1.6	Tuberculosis
Round, sharp margin	5	7	Tuberculosis
Spiculated	1.3	1.5	Post-pneumonic
Spiculated	2	1.5	Tuberculosis
Round, sharp margin	9	ND	Tuberculosis
Cavernous	10	ND	Bronchiectasis
Spiculated	10	8	Tuberculosis
Ragged, irregular margin	9	ND	Anthraxotic lymph node
Ragged, irregular margin	5	6	Hamartoma
Ragged, irregular margin	5	5	Post-pneumonic
Round, smooth-shaped	8	5	Tuberculosis

ND, not documented.

Discussion

LVRS is a valuable treatment in end stage emphysema and has a clear benefit patients fulfilling well defined selection criteria (15). In times of organ shortage LVRS is also used as a bridge to lung transplantation. Benefit beyond NETT criteria was also demonstrated in patients with homogenous emphysema (16), moderate pulmonary hypertension (17) and impaired diffusion capacity (18). BLVR is used increasingly complementary to LVRS, however, no prospective randomized comparisons with regard to functional outcome, morbidity or mortality are available yet (19).

Smoking is the main reason for emphysema in almost 90% of patients undergoing lung volume reduction. Thus, candidates for LVRS have a high risk for lung cancer and histopathological findings may have a relevant impact on evaluation for lung transplantation or further medical treatment. In a study investigating 281 patients who underwent LVRS, Hazelrigg *et al.* found at least

one pulmonary node in 39.5% (20). The incidence of malignancy in the cohort was 6.4%. In another study published 1996 by McKenna *et al.*, the authors screened 325 patients for LVRS and found in 16% a pulmonary node, 2% had a previous undiagnosed lung cancer (21). In our cohort 18 patients had a pulmonary node and among those we found an 11.1% incidence of previously undiagnosed lung cancer diagnosed in the histopathological examination. The incidental findings were neither intraoperatively suspected and nor revealed postoperative reevaluation of the preoperative CT scan a clear suspicion (Figure S1). In another case lung cancer was suspected, but histology revealed a benign histology.

The median size of the investigated nodules in the preoperative chest CT scan was 5.6 mm. In this case a combined positron emission tomography (PET)-CT would not be helpful to further characterize the nodule (22). Due to the high risk of preoperative biopsies surgical resection is

the only path that leads to a reliable diagnosis and outcome in patients with lung cancer resected if a combination with LVRS is considered feasible (20,23,24).

Beyond malignancy, the incidence of tuberculosis is higher in patients with emphysema than in the normal population (25). We found in our patient cohort eight patients with tuberculoma and in one case culture was positive. Infection with mycobacterium can be a contraindication for lung transplantation or it might necessitate antibiotic treatment.

Limitations of our study include the retrospective single center design. The analysis was not performed in an intention to treat group of emphysema patients evaluated for lung volume reduction, but in a patient cohort already selected for LVRS. Since intrapulmonary nodule preclude BLVR in the affected lobe the incidence of intrapulmonary findings might be overestimated compared to the overall emphysema population.

In summary the probability of lung cancer in patients who are LVRS candidates is increased due to the smoking history as shared risk factor for emphysema and lung cancer development. Our data support surgical resection of pulmonary nodules in emphysema patients qualifying for LVRS as a feasible way to confirm or disprove the suspicion for lung cancer.

Limitations of the study

This retrospective study is limited to a single European center with mainly Caucasian patients. Additionally, other factors and cofounders influencing the outcome cannot be ruled out. Further investigations would be necessary to uncover an indirect influence.

Conclusions

In this study, we were able to demonstrate that the usual criteria for malignancy in the CT scan do not have to be evidential for the dignity of a nodule. The probability of finding malignancy in patients screened for lung volume reduction is very high and no nodule should be ignored. A nodule located in the target lobe cannot be further observed in an atelectatic lung of a BLVR patient. A surgical lung volume reduction is therefore the treatment of choice to combine lung volume reduction and histological clarification of a nodule located in the target zone of an emphysematous lung.

Acknowledgments

Funding: This work was supported by the Open Access Publication Fund of the University of Duisburg-Essen.

Footnote

Reporting Checklist: The authors have completed the STROBE reporting checklist. Available at <https://jtd.amegroups.com/article/view/10.21037/jtd-22-915/rc>

Data Sharing Statement: Available at <https://jtd.amegroups.com/article/view/10.21037/jtd-22-915/dss>

Conflicts of Interest: All authors have completed the ICMJE uniform disclosure form (available at <https://jtd.amegroups.com/article/view/10.21037/jtd-22-915/coif>). The authors have no conflicts of interest to declare.

Ethical Statement: The authors are accountable for all aspects of the work in ensuring that questions related to the accuracy or integrity of any part of the work are appropriately investigated and resolved. The study was conducted in accordance with the Declaration of Helsinki (as revised in 2013). The study was approved by Institutional Ethics Committee of University Hospital Essen (No. 19-8993-BO) and individual consent for this retrospective analysis was waived.

Open Access Statement: This is an Open Access article distributed in accordance with the Creative Commons Attribution-NonCommercial-NoDerivs 4.0 International License (CC BY-NC-ND 4.0), which permits the non-commercial replication and distribution of the article with the strict proviso that no changes or edits are made and the original work is properly cited (including links to both the formal publication through the relevant DOI and the license). See: <https://creativecommons.org/licenses/by-nc-nd/4.0/>.

References

1. Fishman A, Martinez F, Naunheim K, et al. A randomized trial comparing lung-volume-reduction surgery with medical therapy for severe emphysema. *N Engl J Med* 2003;348:2059-73.
2. National Emphysema Treatment Trial Research Group; Fishman A, Fessler H, et al. Patients at high risk of death

- after lung-volume-reduction surgery. *N Engl J Med* 2001;345:1075-83.
3. Ahmad S, Taneja A, Kurman J, et al. National trends in lung volume reduction surgery in the United States: 2000 to 2010. *Chest* 2014;146:e228-9.
 4. Shah PL, Herth FJ, van Geffen WH, et al. Lung volume reduction for emphysema. *Lancet Respir Med* 2017;5:147-56.
 5. Stanifer BP, Ginsburg ME. Lung volume reduction surgery in the post-National Emphysema Treatment Trial era. *J Thorac Dis* 2018;10:S2744-7.
 6. McWilliams A, Tammemagi MC, Mayo JR, et al. Probability of cancer in pulmonary nodules detected on first screening CT. *N Engl J Med* 2013;369:910-9.
 7. Waddell TK. Treatment of patients with lung cancer and severe emphysema: lessons from lung volume reduction surgery. *Surg Oncol* 2002;11:201-6.
 8. Choong CK, Mahesh B, Patterson GA, et al. Concomitant lung cancer resection and lung volume reduction surgery. *Thorac Surg Clin* 2009;19:209-16.
 9. Choong CK, Meyers BF, Battafarano RJ, et al. Lung cancer resection combined with lung volume reduction in patients with severe emphysema. *J Thorac Cardiovasc Surg* 2004;127:1323-31.
 10. Darwiche K, Aigner C. Clinical management of lung volume reduction in end stage emphysema patients. *J Thorac Dis* 2018;10:S2732-7.
 11. Travis WD, Colby TV, Corrin B, et al. Histological Typing of Lung and Pleural Tumours (International Histological Classification of Tumours). New York: Springer-Verlag, 1999.
 12. Pellegrino R, Viegi G, Brusasco V, et al. Interpretative strategies for lung function tests. *Eur Respir J* 2005;26:948-68.
 13. Miller MR, Hankinson J, Brusasco V, et al. Standardisation of spirometry. *Eur Respir J* 2005;26:319-38.
 14. Bloch KE, Georgescu CL, Russi EW, et al. Gain and subsequent loss of lung function after lung volume reduction surgery in cases of severe emphysema with different morphologic patterns. *J Thorac Cardiovasc Surg* 2002;123:845-54.
 15. Slama A, Taube C, Kamler M, et al. Lung volume reduction followed by lung transplantation-considerations on selection criteria and outcome. *J Thorac Dis* 2018;10:S3366-75.
 16. Weder W, Ceulemans LJ, Opitz I, et al. Lung Volume Reduction Surgery in Patients with Homogeneous Emphysema. *Thorac Surg Clin* 2021;31:203-9.
 17. Caviezel C, Aruldas C, Franzen D, et al. Lung volume reduction surgery in selected patients with emphysema and pulmonary hypertension. *Eur J Cardiothorac Surg* 2018;54:565-71.
 18. Caviezel C, Schaffter N, Schneiter D, et al. Outcome After Lung Volume Reduction Surgery in Patients With Severely Impaired Diffusion Capacity. *Ann Thorac Surg* 2018;105:379-85.
 19. Tutic M, Lardinois D, Imfeld S, et al. Lung-volume reduction surgery as an alternative or bridging procedure to lung transplantation. *Ann Thorac Surg* 2006;82:208-13; discussion 213.
 20. Hazelrigg SR, Boley TM, Weber D, et al. Incidence of lung nodules found in patients undergoing lung volume reduction. *Ann Thorac Surg* 1997;64:303-6.
 21. McKenna RJ Jr, Fischel RJ, Brenner M, et al. Combined operations for lung volume reduction surgery and lung cancer. *Chest* 1996;110:885-8.
 22. Kernstine KH, Grannis FW Jr, Rotter AJ. Is there a role for PET in the evaluation of subcentimeter pulmonary nodules? *Semin Thorac Cardiovasc Surg* 2005;17:110-4.
 23. Allen GM, DeRose JJ Jr. Pulmonary nodule resection during lung volume reduction surgery. *AORN J* 1997;66:808-10, 812, 814 passim.
 24. Rozenshtein A, White CS, Austin JH, et al. Incidental lung carcinoma detected at CT in patients selected for lung volume reduction surgery to treat severe pulmonary emphysema. *Radiology* 1998;207:487-90.
 25. Byrne AL, Marais BJ, Mitnick CD, et al. Tuberculosis and chronic respiratory disease: a systematic review. *Int J Infect Dis* 2015;32:138-46.

Cite this article as: Plönes T, Slama A, Seebacher G, Viehof J, Okumus Ö, Theegarten D, Darwiche K, Taube C, Aigner C. The nodule in the emphysematous lung: an appeal for surgery in a lung volume reduction concept. *J Thorac Dis* 2023;15(6):3166-3171. doi: 10.21037/jtd-22-915