



Presumed bilateral diffuse uveal melanocytic proliferation – A case report and review of literature

Shweta Parakh^a, Shrey Maheshwari^a, Shrutanjoy Das^a, Vinod Kumar^b, Rupesh Agrawal^{c,d}, Vishali Gupta^e, Prithvi Mruthyunjaya^f, Saurabh Luthra^{a,*}

^a Drishti Eye Institute, Dehradun, Uttarakhand, India

^b Dr.R.P Centre for Ophthalmic Sciences, AIIMS, New Delhi, India

^c National Healthcare Group Eye Institute, Tan Tock Seng Hospital, Singapore, Singapore

^d Lee Kong Chian School of Medicine, Nanyang Technological University, Singapore, Singapore

^e Advanced Eye Centre, Postgraduate Institute of Medical Education and Research, Chandigarh, India

^f Byers Eye Institute at Stanford University, Palo Alto, CA, USA

ARTICLE INFO

Keywords:

Bilateral diffuse uveal melanocytic proliferation
Sunitinib
Plasmapheresis
Renal cell carcinoma
Neovascular glaucoma

ABSTRACT

Purpose: To describe a case of presumed bilateral diffuse uveal melanocytic proliferation (BDUMP) associated with renal cell carcinoma (RCC) and provide an updated review of literature.

Observations: A 58-year-old man, with a history of radical nephrectomy for RCC 8 years ago, presented with gradual diminution of vision. Based on multimodal imaging and detailed systemic evaluation, a diagnosis of presumed BDUMP and metastatic RCC was made. He was started on sunitinib malate as palliative chemotherapy. However, he refused plasmapheresis for BDUMP. The patient rapidly developed bilateral exudative retinal detachment. Subsequently, he progressed to bilateral neovascular glaucoma secondary to closed funnel retinal detachment. Eventually, he was lost to follow up after 13 months.

Conclusions & Importance: BDUMP portends an underlying advanced systemic malignancy. Studies have not conclusively proven any definite treatment for BDUMP and survival is generally poor. Ocular side effects of palliative targeted chemotherapy for the primary malignancy, such as sunitinib, should be borne in mind.

1. Introduction

Bilateral diffuse uveal melanocytic proliferation (BDUMP), a rare paraneoplastic syndrome, which can result in profound vision loss, was first described by Machemer in 1966 in a patient with primary pancreatic carcinoma.^{1–3} However, it was not until 1982 that Barr et al. coined the term BDUMP.⁴

BDUMP is caused by a diffuse proliferation of benign uveal melanocytes, mainly in the choroid, and is distinct from the primary non-ocular tumor histopathologically.⁵ Treatment options include those targeted at the primary malignancy or metastases⁵ and elimination of the supposed causative agent-cultured melanocyte elongation and proliferation (CMEP) factor⁶ – via plasmapheresis.

We herein report a case of presumed BDUMP associated with a history of renal cell carcinoma (RCC). The patient was started on oral

receptor tyrosine kinase (RTK) inhibitor sunitinib as palliative chemotherapy. He refused to undergo plasmapheresis therapy for presumed BDUMP and therefore was administered oral corticosteroids, but worsened progressively.

2. Case

A 58-year-old man came with complaints of gradual diminution of vision in the right eye for 2 weeks and left eye for 3 months. He was diagnosed elsewhere as acute central serous chorioretinopathy (CSCR) in the right eye and chronic CSCR in the left eye, a week before he presented to us. He had a history of renal cell carcinoma, for which he had undergone left laparoscopic radical nephrectomy 8 years ago.

At presentation, best corrected visual acuity (BCVA) was 6/24 and 6/36 in the right eye and left eye respectively. Anterior segment

* Corresponding author. Drishti Eye Institute, 16, Subhash Road, Astley Hall, Dehradun, 248001, Uttarakhand, India.

E-mail addresses: dr.shweta.parakh@gmail.com (S. Parakh), shrey.2011@gmail.com (S. Maheshwari), shrutanjoydas@gmail.com (S. Das), drvinod_agg@yahoo.com (V. Kumar), rupeshstsh@gmail.com (R. Agrawal), vishalisara@yahoo.co.in (V. Gupta), prithvi9@stanford.edu (P. Mruthyunjaya), drsaurabhluthra@gmail.com (S. Luthra).

<https://doi.org/10.1016/j.ajoc.2022.101582>

Received 25 January 2022; Received in revised form 28 April 2022; Accepted 29 April 2022

Available online 13 May 2022

2451-9936/© 2022 The Authors. Published by Elsevier Inc. This is an open access article under the CC BY-NC-ND license (<http://creativecommons.org/licenses/by-nc-nd/4.0/>).

examination was unremarkable. Fundus examination showed a dull foveal reflex and diffuse multiple faint yellow subretinal lesions bilaterally (Fig. 1a and b). Fundus fluorescein angiography (FFA) (Topcon Corporation, Tokyo, Japan) showed multifocal areas of early hyperfluorescence at the posterior pole (Fig. 1c and d). Short-wave fundus autofluorescence (SW-FAF) (Heidelberg Retina Angiograph, Heidelberg Engineering, Heidelberg, Germany) showed a typical giraffe pattern with alternate areas of hyperautofluorescence due to accumulation of lipofuscin and hypoautofluorescence due to retinal pigment epithelium (RPE) atrophy (Fig. 1e and f). B-scan ultrasound (Nidek Co. Ltd, Aichi, Japan) revealed a localized exudative retinal detachment without any mass lesion (Fig. 1g and h). Spectral domain optical coherence tomography (SD-OCT) (RTVue XR Avanti, Optovue Inc., Fremont, CA, USA) revealed bilateral subretinal fluid (SRF) at the macula with alternate areas of RPE thickening and RPE loss in addition to preserved choriocapillaris architecture (Fig. 1i and j). Ultrasound of the abdomen showed 29 × 36 mm well defined hyperechoic lesion in right lobe of liver with a large 95 × 100 × 118 mm lobulated heterogenous mass lesion in left retroperitoneum with multiple calcifications within it. Internal vascularity was seen. Pelvic ascites was present. Positron Emission Tomography and Computed Tomography (PET-CT) showed multiple fluorodeoxyglucose (FDG) avid lesions in right renal fossa, left pelvic cavity, along the liver surface, lung metastases and mediastinal lymph nodes (Fig. 1k and l).

A diagnosis of presumed BDUMP secondary to metastatic renal cell carcinoma was made. The patient was started on palliative oral chemotherapy in the form of oral RTK inhibitor, sunitinib malate (SU11248; SUTENT; Pfizer Inc, New York, NY, USA) 50 mg once a day for 2 weeks, followed by 1 week off. He refused to undergo plasmapheresis therapy for BDUMP. He was then given a course of oral prednisolone in tapering doses for two months. Two weeks post initiation of sunitinib, SRF had increased bilaterally. A month later, the patient presented with bilateral exudative retinal detachment with BCVA of 6/60 and 1/60 in the right eye and left eye respectively (Fig. 2a–h). He was advised bilateral pars plana vitrectomy and silicone oil tamponade but was not willing for the same. Over the next month, he rapidly progressed to bilateral closed funnel retinal detachment (Fig. 2i and j). A month later, he deteriorated further to bilateral neovascular glaucoma with light perception vision.

Magnetic resonance imaging (MRI) of the brain and orbits showed nonspecific hyperintense foci in subcortical white matter of frontal lobes with bilateral total retinal detachment on T2 weighted imaging. PET-CT scan at this point of time revealed significant increase in size and FDG avidity of lesions noted previously. He was started on second-line palliative chemotherapy in the form of oral everolimus, a mammalian target of rapamycin (mTOR) protein kinase inhibitor. The patient still refused radiation therapy or any other therapeutic intervention. At the final follow-up visit at 13 months, he maintained status quo (Fig. 2k and l). Eventually he was lost to follow-up.

3. Discussion

Bilateral diffuse uveal melanocytic proliferation (BDUMP) is a rare paraneoplastic ocular syndrome occurring in patients with systemic, often occult and advanced carcinoma. It is an ominous sign and a hallmark of poor prognosis. The estimated incidence of ocular paraneoplastic syndromes and neurologic paraneoplastic syndromes is <0.01% of cancer patients.^{7,8}

The five cardinal signs of BDUMP as described by Gass et al., in 1990 include: (1) multifocal, faintly visible, round or oval, red, subretinal patches; (2) associated striking pattern of hyperfluorescence during the early phases of angiography; (3) development of multiple, slightly elevated, pigmented and non-pigmented uveal melanocytic tumors and evidence of diffuse thickening of uveal tract; (4) exudative retinal detachment; and (5) rapid progression of cataract.¹ In addition, glaucoma, dilated episcleral vessels, iridocyclitis, shallow anterior chamber,

ciliary body cysts and iridodonesis have been observed.⁹ However, clinical presentation without all the diagnostic features such as exudative retinal detachment or cataract have also been described in earlier stages of BDUMP.¹⁰

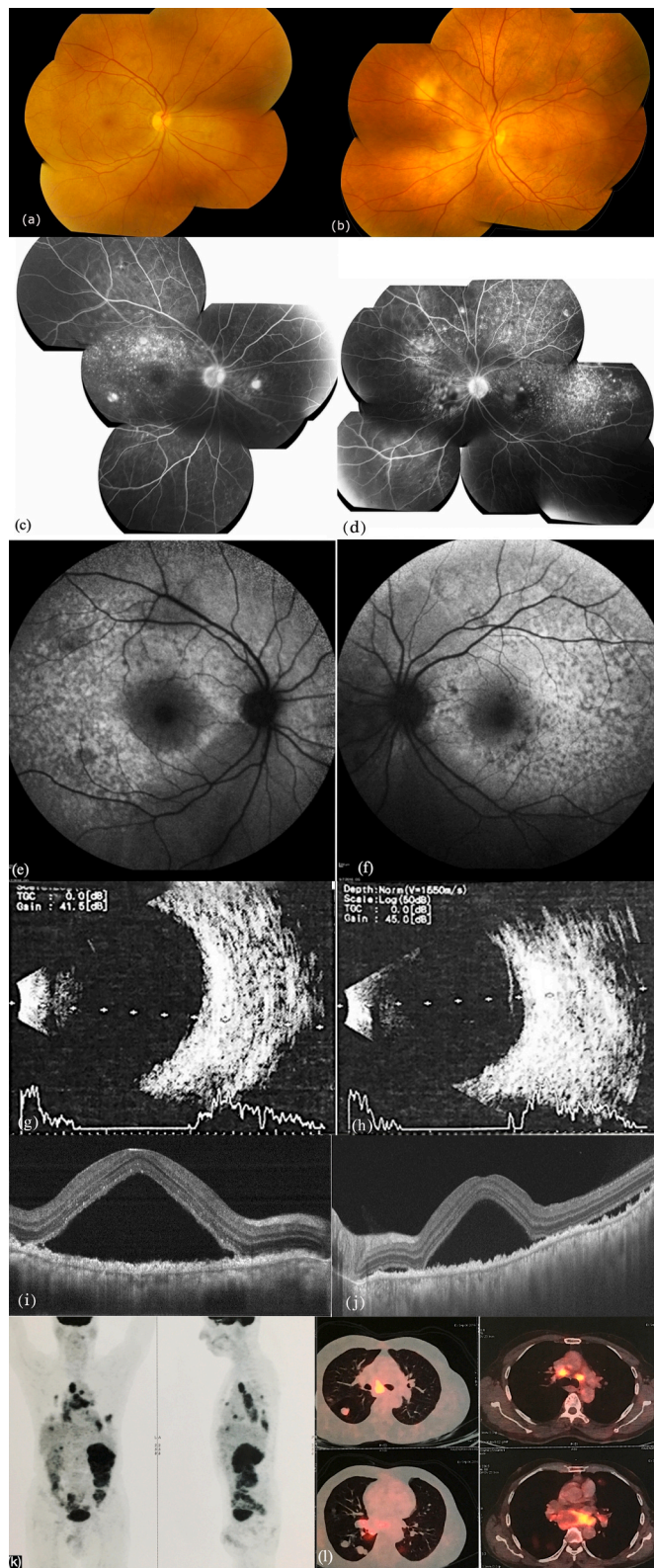
As described previously in literature, mean age at onset of BDUMP is 64 years and the mean duration between onset of ocular symptoms to death is 1 year.¹¹ Giraffe (or leopard-spot) pattern on SW-FAF, OCT findings of RPE aggregation with irregularity, subretinal fluid and preserved choriocapillaris architecture - present in our case - have been described in previous reports of BDUMP.^{12–14} The most common primary malignancy associated with BDUMP in females is urogenital carcinoma (71%), whereas in males, lung carcinoma accounted for 51% of cases.¹⁵ With better life expectancy and improved diagnostic modalities, the reported incidence of this disease has increased to 4.4 per year during 2012–2017.⁵ In 44% cases, BDUMP presented in patients with a previously diagnosed primary tumour whereas in another 44% the primary tumour was diagnosed after or simultaneously with the presentation of BDUMP.⁵

BDUMP is a paraneoplastic syndrome that appears to be caused by ectopic production of growth factors or hormones that act at a site distant from production.¹⁶ Miles et al. have shown the presence of cultured melanocyte elongation and proliferation (CMEP) factor in the IgG enriched plasma fraction that causes uveal melanocytic and RPE proliferation.⁶ This in turn causes disruption of the outer blood-retinal barrier by RPE malfunction.^{16–18} Possible newer etiology for BDUMP associated with various urogenital and lung cancers has been postulated to chronic high levels of hepatocyte growth factor (HGF) which is a ligand for the tyrosine kinase receptor encoded by the met proto-oncogene.¹⁹ High serum levels of HGF have been previously associated with metastasis and decreased survival in cancer patients.²⁰ Tyrosine kinase inhibitors can increase HGF levels.²¹

There are 13 published reports of plasmapheresis treatment for BDUMP. Seven reports demonstrated improvement in vision or SRF with plasmapheresis treatment^{19,22–27}; Five of 7 patients were diagnosed with lung cancer and 5 of 7 were undergoing concomitant chemotherapy. Among the remaining 6 cases, 3 cases showed stability^{23,28} and 3 cases displayed worsening of SRF despite plasmapheresis treatment.^{29–31} In order to explain the varied response to plasmapheresis treatment, Lavine et al. hypothesized that disease heterogeneity is present among patients with BDUMP.³² BDUMP associated with uterine carcinomas may be less amenable to plasmapheresis because CMEP factor is poorly removed due to quicker rebound and is possibly continually secreted by the primary tumor. In contrast, BDUMP associated with lung and ovarian carcinomas respond well to plasmapheresis possibly because CMEP factor is removed more effectively.³² Large molecular weight, intravascular location, and slow production all favour better plasmapheresis elimination of CMEP factor.³³

In general, treatment of BDUMP has until now mainly been ineffective.^{16,34} Various treatment modalities for BDUMP, including ocular radiation,^{4,11,22,35} subretinal fluid drainage³⁶ and corticosteroids^{37–40} have all failed to give consistent results. Vitrectomy and silicone oil tamponade for serous retinal detachment has been attempted with varying outcomes.^{41,42} Patients diagnosed with BDUMP generally have poor survival, mainly due to the underlying systemic malignancy. The median survival of most BDUMP patients is about 15.6 months.⁴³ These patients may even have concurrent multiple systemic malignancies and can present several months to years later with the systemic malignancy, so that prolonged systemic surveillance is mandatory.¹⁸

In our case, in addition to the possible effect of sunitinib, RPE damage due to BDUMP may have aggravated the exudative retinal detachment and finally contributed to the development of neovascular glaucoma. Sunitinib malate is a small molecule multi-targeted RTK inhibitor approved for the treatment of advanced RCC, imatinib - resistant gastrointestinal stromal tumour (GIST) and advanced pancreatic neuroendocrine tumors. It inhibits cellular signalling by targeting receptors for platelet derived growth factor (PDGF) and vascular



(caption on next column)

Fig. 1. Multimodal imaging of bilateral diffuse uveal melanocytic proliferation at initial presentation of the right eye and left eye respectively. (a,b) Color fundus photography showing dull foveal reflex and multiple diffuse faint subretinal yellow lesions. (c,d) Fluorescein angiography showing multifocal hyperfluorescent areas at the posterior pole. (e,f) Short-wave fundus autofluorescence showing the characteristic giraffe pattern. (g,h) B-scan ultrasound showing a localized exudative retinal detachment without any mass lesion. (i,j) Spectral domain optical coherence tomography showing bilateral subretinal fluid (SRF) at the macula with alternate areas of retinal pigment epithelium (RPE) aggregation and RPE loss with preserved choriocapillaris architecture. (k, l) Positron Emission Tomography and Computed Tomography (PET-CT) showing multiple fluorodeoxyglucose (FDG) avid lesions in right renal fossa, left pelvic cavity, along the liver surface, lung metastases and mediastinal lymph nodes. (For interpretation of the references to colour in this figure legend, the reader is referred to the Web version of this article.)

endothelial growth factor (VEGF), both of which play a key role in tumour angiogenesis and tumour cell proliferation.⁴⁴ Dib et al. in their study found that sunitinib at the concentration of 12.5 mg/ml caused no toxicity in *in vivo* and *in vitro* models, but the 25 mg/ml concentration caused retinal changes, suggesting toxicity in the *in vivo* rabbit model.⁴⁵ Santana-Garrido et al. in their *in vivo* study in rats demonstrated that oral administration of sunitinib for 3 weeks produces NADPH oxidase-derived retinotoxic effects associated with oxidative ocular damage.⁴⁶ They proposed that this might be linked to hypertensive side effects but could also be secondary to direct adverse effects of sunitinib. Wegner and Khoramnia first reported a case of reversible neurosensory retinal detachment and retinal edema due to sunitinib in a case of metastatic RCC.⁴⁷ Proposed pathogenetic mechanisms of subretinal exudation include changes in choroidal vascular permeability, choroidal perfusion or microvascular events.^{48–50} In a recent review Fraunfelder et al. reported the median time to onset of retinal detachment for sunitinib to be 69 days. They speculated that daily oral anti-VEGF drug has more uveal drug exposure than single intravitreal anti-VEGF injection.⁵⁰

To the best of our knowledge, our case report is the first case of presumed BDUMP progressing to total closed funnel retinal detachment with neovascular glaucoma, possibly aggravated by sunitinib. Limitations of our study include the absence of molecular or genetic analysis of ocular fluid or serum to demonstrate causative factors of BDUMP such as CMEP or HGF and the correlation of sunitinib therapy with their titres. In addition, further studies regarding the role of RTK inhibitors are needed to establish a causal association with the progression of exudative retinal detachment.

4. Conclusion

BDUMP is the hallmark of a grave systemic condition, hence highlighting the need for a high index of suspicion and prompt evaluation. It is of paramount importance to delve into systemic details, especially in elderly patients presenting with seemingly innocuous findings such as “central serous chorioretinopathy”. Diagnosis of the occult primary malignancy can often prove to be challenging. No definitive treatment for BDUMP has been formulated yet, and survival is generally poor. Ocular side effects of palliative targeted chemotherapy for the primary malignancy, such as sunitinib, should be borne in mind.

Patient consent

Written informed consent was obtained from the patient for publication of this case report and any accompanying images. A copy of the written consent is available for review by the Editor of this journal.

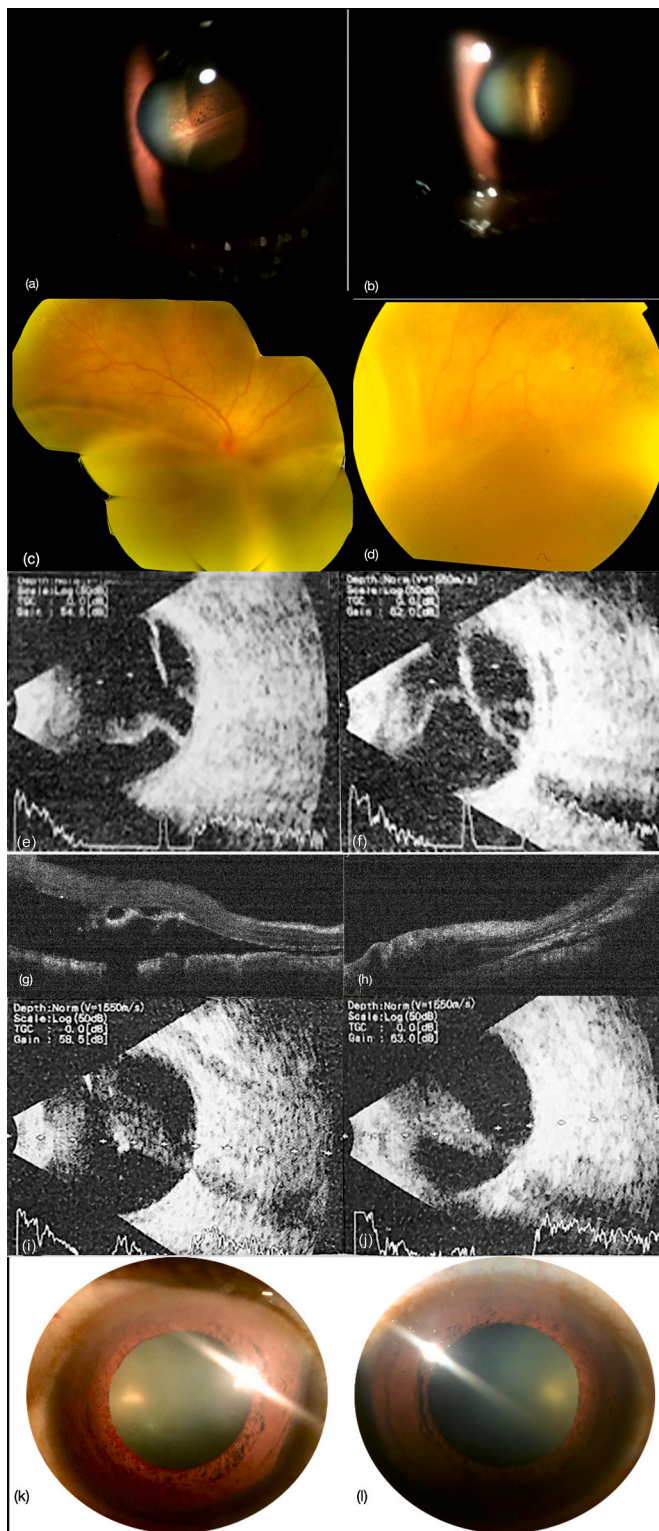


Fig. 2. Multimodal imaging of the right eye and left eye respectively: At 1 month follow-up visit post-sunitinib therapy- (a,b) Anterior segment photograph showing exudative retinal detachment. (c,d) Color fundus photograph showing exudative retinal detachment. (e,f) B-scan ultrasound showing retinal detachment without any mass lesion. (g,h) Optical coherence tomography showing grossly increased subretinal fluid at the macula. At 3 months follow-up - (i,j) B-scan ultrasound showing closed funnel retinal detachment. At the final follow-up at 13 months - (k,l) Anterior segment photograph showing rubeosis iridis. (For interpretation of the references to colour in this figure legend, the reader is referred to the Web version of this article.)

Funding

No funding or grant support was given for this case report.

Declaration of competing interest

The following authors have no financial disclosures: SP, SM, SD, VK, RA, VG, PM, SL.

Authorship

All authors attest that they meet the current ICMJE criteria for Authorship.

Acknowledgements and disclosures

None.

References

- Gass JD, Gieser RG, Wilkinson CP, Beahm DE, Pautler SE. Bilateral diffuse uveal melanocytic proliferation in patients with occult carcinoma. *Arch Ophthalmol.* 1990; 108(4):527–533.
- Shields JA, Shields CL. *Differential Diagnosis of Posterior Uveal Melanoma*. Intraocular Tumors: An Atlas and Textbook. WB Saunders; 1992.
- Machemer R. On the pathogenesis of the flat malignant melanoma (in German). *KlinMonblAugenheilkd.* 1966;148:641–652.
- Barr CC, Zimmerman LE, Curtin VT, Font RL. Bilateral diffuse melanocytic uveal tumors associated with systemic malignant neoplasms: a recently recognized syndrome. *Arch Ophthalmol.* 1982;100:249–255.
- Klemp K, Kiilgaard JF, Heegaard S, Norgaard T, Andersen MK, Ju Prause. Bilateral diffuse uveal melanocytic proliferation: case report and literature review. *Acta Ophthalmol.* 2017;95(5):439–445.
- Miles SL, Niles RM, Pittock S, et al. A factor found in the IgG fraction of serum of patients with paraneoplastic bilateral diffuse uveal melanocytic proliferation causes proliferation of cultured human melanocytes. *Retina.* 2012;32(9):1959–1966.
- Darnell RB, Posner JB. Paraneoplastic syndromes involving the nervous system. *N Engl J Med.* 2003;349(16):1543–1554.
- De Salvo G, Prakash P, Rennie CA, Lotery AJ. Long-term survival in a case of bilateral diffuse uveal melanocytic proliferation. *Eye (Lond).* 2011;25(10): 1385–1386.
- Joseph A, Rahimy E, Sarraf D. Bilateral diffuse uveal melanocytic proliferation with multiple iris cysts. *JAMA Ophthalmol.* 2014;132(6):756–760.
- Pekianaki M, Agrawal R, Desai P, Pavesio C, Sagoo MS. Bilateral Diffuse Uveal Melanocytic Proliferation (BDUMP) associated with B-cell lymphoma: report of a rare case. *BMC Cancer.* 2015;15:23.
- Duong H-VQ, McLean IW, Beahm DE. Bilateral diffuse melanocytic proliferation associated with ovarian carcinoma and metastatic malignant amelanotic melanoma. *Am J Ophthalmol.* 2006;142(4):693–695.
- Yannuzzi LA. *The Retinal Atlas*. Philadelphia: Elsevier; 2010:689–690.
- Ryan SJ. *Retina*. Amsterdam: Elsevier; 2013:1625.
- Shalchi Z, Shunmugam M, Mahroo O, et al. Spectral domain optical coherence tomography findings in a case series of patients with bilateral diffuse uveal melanocytic proliferation. *Ocul Immunol Inflamm.* 2014;22(6):490–493.
- Ryll DL, Campbell RJ, Robertson DM, Brubaker SJ. Pseudometastatic lesions of the choroid. *Ophthalmology.* 1980;87(11):1181–1186.
- Rahimy E, Sarraf D. Paraneoplastic and non-paraneoplastic retinopathy and optic neuropathy: evaluation and management. *Surv Ophthalmol.* 2013;58(5):430–458.
- Mittal R, Cherepanoff S, Thornton S, Kalirai H, Damato B, Coupland SE. Bilateral diffuse uveal melanocytic proliferation: molecular genetic analysis of a case and review of the literature. *Ocul Oncol Pathol.* 2015;2(2):94–99.
- Rahimy E, Coffee RE, McCannel TA. Bilateral diffuse uveal melanocytic proliferation as a precursor to multiple systemic malignancies. *Semin Ophthalmol.* 2015;30(206): 209.
- Niffenegger JH, Soltero A, Niffenegger JS, Yang S, Adamus G. Prevalence of hepatocyte growth factor and autoantibodies to α HGF as a new etiology for bilateral diffuse uveal melanocytic proliferation masquerading as neovascular age related macular degeneration. *J Clin Exp Ophthalmol.* 2018;9.
- Matsumoto K, Umitsu M, De Silva DM, Roy A, Bottaro DP. Hepatocyte growth factor/MET in cancer progression and biomarker discovery. *Cancer Sci.* 2017;108 (3):296–307.
- Organ SL, Tsao M-S. An overview of the c-MET signaling pathway. *Ther Adv Med Oncol.* 2011;3(1 Suppl):S7–S19.
- Mets RB, Golchet P, Adamus G, et al. Bilateral diffuse uveal melanocytic proliferation with a positive ophthalmoscopic and visual response to plasmapheresis. *Arch Ophthalmol.* 2011;129(9):1235–1238.
- Jaben EA, Pulido JS, Pittock S, Markovic S, Winters JL. The potential role of plasma exchange as a treatment for bilateral diffuse uveal melanocytic proliferation: a report of two cases. *J Clin Apher.* 2011;26(6):356–361.

24. Pulido JS, Flotte TJ, Raja H, et al. Dermal and conjunctival melanocytic proliferations in diffuse uveal melanocytic proliferation. *Eye (Lond)*. 2013;27(9):1058–1062.
25. Schelvergem KV, Wirix M, Nijs I, Leys A. Bilateral diffuse uveal melanocytic proliferation with good clinical response to plasmapheresis and treatment of the primary tumor. *Retin Cases Brief Rep*. 2015;9(2):106–108.
26. Rafei-Shamsabadi D, Schneider J, Trefzer L, Technau-Hafsi K, Meiss F, Ness T. Case report: blurred vision and eruptive nevi - bilateral Diffuse Uveal Melanocytic Proliferation with mucocutaneous involvement in a lung cancer patient. *Front Oncol*. 2021;11:658407.
27. Thompson AC, Chen X, Mruthyunjaya P. A case of progressive dimming vision. *JAMA Ophthalmol*. 2018;136(4):434–435.
28. Alasil T, Coady PA, Koudsi S, Mathur M, Materin MA. Bilateral diffuse uveal melanocytic proliferation: a case report. *Retin Cases Brief Rep*. 2017;11(1):71–74.
29. Alrashidi S, Aziz AA, Krema H. Bilateral diffuse uveal melanocytic proliferation: a management dilemma. *BMJ Case Rep*. 2014;2014. <https://doi.org/10.1136/bcr-2014-204387>. bcr2014204387. Published 2014 May 22.
30. Navajas EV, Simpson ER, Krema H, et al. Cancer-associated nummular loss of RPE: expanding the clinical spectrum of bilateral diffuse uveal melanocytic proliferation. *Ophthalmic Surg Laser Imag*. 2011;42:e103–e106.
31. Lentzsch AM, Siggel R, Spital C, Holtick U, Liakopoulos S. Long-time follow-up of asymmetric bilateral diffuse uveal melanocytic proliferation (BDUMP) in a patient with metastasized urothelial carcinoma [published online ahead of print, 2021 Jan 18]. *Retin Cases Brief Rep*. 2021. <https://doi.org/10.1097/ICB.0000000000001129>.
32. Lavine JA, Ramos MS, Wolk AM, et al. Heterogeneity of cultured melanocyte elongation and proliferation factor in bilateral diffuse uveal melanocytic proliferation. *Exp Eye Res*. 2019;184:30–37.
33. Williams ME, Balogun RA. Principles of separation: indications and therapeutic targets for plasma exchange. *Clin J Am Soc Nephrol*. 2014;9(1):181–190.
34. Lin P, Mruthyunjaya P. Retinal manifestations of oncologic and hematologic conditions. *Int Ophthalmol Clin*. 2012;52(1):67–91.
35. Borruat F-X, Othenin-Girard P, Uffer S, Othenin-Girard B, Regli F, Hurlimann J. Natural history of diffuse uveal melanocytic proliferation. *Ophthalmology*. 1992;99(11):1698–1704.
36. Ritland JS, Eide N, Tausjø J. Bilateral diffuse uveal melanocytic proliferation and uterine cancer. A case report. *Acta Ophthalmol Scand*. 2000;78(3):366–368.
37. Mora P, Gonzales S, Crafa P, Carta A, Guex-Crosier Y, Zografos L. Peculiar findings in a case of bilateral uveal pigmented lesions. *Ocul Immunol Inflamm*. 2010;18(5):379–382.
38. Besirli CG, Comer GM. High-resolution OCT imaging of RPE degeneration in bilateral diffuse uveal melanocytic proliferation. *Ophthalmic Surg Laser Imag*. 2010;41(6):S96–S100.
39. Saito W, Kase S, Yoshida K, et al. Bilateral diffuse uveal melanocytic proliferation in a patient with cancer-associated retinopathy. *Am J Ophthalmol*. 2005;140(5):942–945.
40. Rohrbach JM, Roggendorf W, Thanos S, Steuhl KP, Thiel HJ. Simultaneous bilateral diffuse melanocytic uveal hyperplasia. *Am J Ophthalmol*. 1990;110(1):49–56.
41. Tong N, Wang L, Wang N, Zhou Z. Bilateral diffuse uveal melanocytic proliferation secondary to rectal adenocarcinoma: a case report and literature review. *Front Med*. 2021;8:691686. Published 2021 Jul 20.
42. Gass JD, Glatzer RJ. Acquired pigmentation simulating Peutz-Jeghers syndrome: initial manifestation of diffuse uveal melanocytic proliferation. *Br J Ophthalmol*. 1991;75(11):693–695.
43. O'Neal KD, Butnor KJ, Perkinson KR, Proia AD. Bilateral diffuse uveal melanocytic proliferation associated with pancreatic carcinoma: a case report and literature review of this paraneoplastic syndrome. *Surv Ophthalmol*. 2003;48(6):613–625.
44. Goodman VL, Rock EP, Dagher R, et al. Approval summary: sunitinib for the treatment of imatinib refractory or intolerant gastrointestinal stromal tumors and advanced renal cell carcinoma. *Clin Cancer Res*. 2007;13(5):1367–1373.
45. Dib E, Maia M, Lima Ade S, et al. In vivo, in vitro toxicity and in vitro angiogenic inhibition of sunitinib malate. *Curr Eye Res*. 2012;37(7):567–574. <https://doi.org/10.3109/02713683.2011.635916>.
46. Santana-Garrido Á, Reyes-Goya C, André H, Aramburu Ó, Mate A, Vázquez CM. Sunitinib-induced oxidative imbalance and retinotoxic effects in rats. *Life Sci*. 2020;257:118072.
47. Wegner A, Khoramnia R. Neurosensory retinal detachment due to sunitinib treatment. *Eye*. 2011;25(11):1517–1518.
48. Wang M, Munch IC, Hasler PW, Prunte C, Larsen M. Central serous chorioretinopathy. *Acta Ophthalmol*. 2008;86(2):126–145.
49. Wolfensberger TJ, Tufail A. Systemic disorders associated with detachment of the neurosensory retina and retinal pigment epithelium. *Curr Opin Ophthalmol*. 2000;11(6):455–461.
50. Fraunfelder FT, Fraunfelder FW. Oral anti-vascular endothelial growth factor drugs and ocular adverse events. *J OculPharmacolTher*. 2018;34(6):432–435. <https://doi.org/10.1089/jop.2018.0019>.