

# Arthroscopic-Assisted Coracoclavicular Stabilization With Anchorless Transosseous Double-Row Acromioclavicular Ligament Complex Repair: The Acute Acromioclavicular Joint Dislocation



Surasak Srimongkolpitak, M.D., Adinun Apivatgaroon, M.D., Bancha Chernchujit, M.D., and Surapon Atiprayoon, M.D.

**Abstract:** The current concept procedures in the acute acromioclavicular joint dislocation should be divided into 2 types of structure restoration: those that provide coracoclavicular stabilization, which affects the primary healing of the coracoclavicular ligaments by vertically stabilizing the clavicle and coracoid in their anatomical positions, and those that attempt to repair the superior acromioclavicular ligament complex, which controls both horizontal and rotational stabilization. The acute acromioclavicular joint dislocation clinical outcome will be achieved if you perform both procedures. It's difficult to stabilize the acromioclavicular joint in both vertical and horizontal planes, and most current techniques aren't always effective. In this Technical Note, we discuss an arthroscopic-assisted technique that reconstructs the coracoclavicular and acromioclavicular ligaments under image intensifier guidance to achieve bidirectional (vertical and horizontal) and rotational stability.

There is still no consensus on the optimal method for restoring the acromioclavicular (AC) ligament complex. A variety of surgical techniques have been published, the standard of operative management is still debatable, and it remains a difficult procedure. With the use of the arthroscopic-assisted technique, the failure rate and postoperative complications were slightly reduced, and arthroscopic will become the next generation of AC joint surgery.<sup>1</sup> Compared with open surgeries, arthroscopy-assisted AC joint reconstruction

has better functional outcomes and patient satisfaction because the 49% of patients with concomitant intra-articular lesions were treated and the incision was smaller.<sup>2</sup>

A discussed issue of horizontal instability in acute AC joint dislocation was found to relate to a greater chance of postoperative AC joint stabilization failure. The acromioclavicular ligament complex (ACLC), which comprises the AC capsule and ligaments, has the attention of many surgeons. An anatomic reconstruction of the acute AC joint dislocation can be done by referring to the synergistic contribution of the coracoclavicular (CC) and AC capsular structures to ACJ stability.<sup>3,4</sup>

The CC and AC ligaments play a role in creating AC joint stability and preventing vertical and horizontal instability according to a cadaveric biomechanics study that analyzed superior migration and posterior translation of the distal clavicle. The AC ligament is necessary for both horizontal and vertical stability of the AC joint.<sup>5</sup> The combined restoration of the AC capsule and CC ligaments nearly restored native AC joint stability, as determined by biomechanics following the ACLC procedure, in which the AC suture augmentations were able to significantly increase both average posterior translation resistance and torque resistance-like native AC joint stability.<sup>6-8</sup> Many techniques focus on vertical

From the Department of Orthopedics, Faculty of Medicine, Queen Savang Vadhana Memorial Hospital, Sriracha, Chonburi (S.S., S.A.); and Department of Orthopedics, Faculty of Medicine, Thammasat University, Pathum Thani (A.A., B.C.), Thailand.

The authors report that they have no conflicts of interest in the authorship and publication of this article. Full ICMJE author disclosure forms are available for this article online, as [supplementary material](#).

Received April 5, 2022; accepted May 20, 2022.

Address correspondence to Surasak Srimongkolpitak, M.D., Department of Orthopedics, Faculty of Medicine, Queen Savang Vadhana Memorial Hospital, 209 Jermjormpol Road, Si Racha District, Chon Buri Province 20110, Sriracha, Chonburi, Thailand. E-mail: [mikemiky88@gmail.com](mailto:mikemiky88@gmail.com)

© 2022 THE AUTHORS. Published by Elsevier Inc. on behalf of the Arthroscopy Association of North America. This is an open access article under the CC BY-NC-ND license (<http://creativecommons.org/licenses/by-nc-nd/4.0/>).

2212-6287/22463

<https://doi.org/10.1016/j.eats.2022.05.012>

instability by isolating the CC ligamentous complex and performing solitary stabilization and, following that, we found that the radiographic and functional outcomes were also poor. The AC ligament and the superior element of the AC joint, which are reinforced by deltotrapezial fascia fibers, are crucial. After CC stabilization and ACLC augmentation, which restored both planes, the horizontal and vertical stability structures were also immediately provided. The postoperative functional outcomes have improved, and the radiographic diagnostic of the posterior translation AC joint is absent.<sup>9</sup>

The following indications for surgery are included in acute AC joint dislocation (less than 3 weeks): Rockwood classification grade IIIB, IV, and V. Preoperative radiographic evaluation includes an anteroposterior view and a bilateral Zenca's view to assess vertical instability. As previously published, horizontal stability is measured using Alexander views.<sup>10</sup>

## Surgical Technique (With Video Illustration)

### Patient Positions

The surgery is performed in a 70° tilt in a beach-chair position with the affected arm supported by a Mayo standing support. The patient's head is securely fixed on a head guard support, and 2 pillows are placed behind the popliteal fossa to prevent the patient from sliding down (Fig 1).

### Portal Placement

Following standard preparation and draping, the bony prominent anatomic shoulder landmarks are marked. A 5-cm horizontal incision is made medial to the prominent distal clavicle from AC joint dislocation and 3 cm laterally to the prominent distal clavicle. The posterolateral portal, which is placed just posterior diagonal to the prominent posterolateral corner of the acromial bone, is used for diagnostic arthroscopy and as the main viewing portal. A main anterior working portal is made 2 cm lateral to the coracoid process, recognizing the base of the coracoid process (Fig 2).

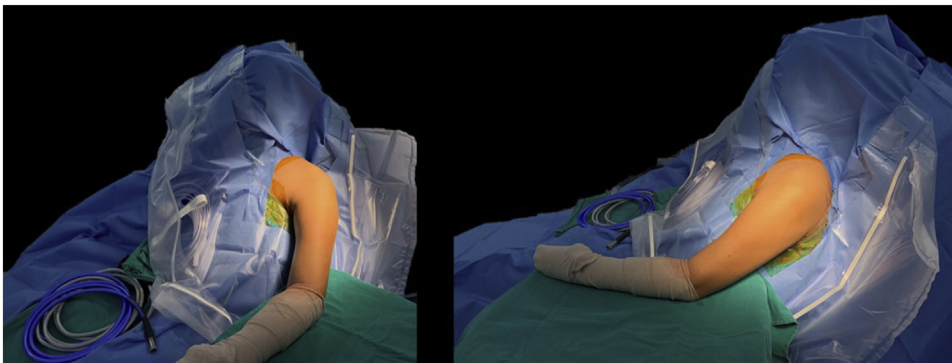
### Arthroscopic-Assisted for Preparing the Base of the Coracoid Process

The posterolateral portal (marked 2 cm on a line extending from the posterolateral corner of the clavicle to the posterolateral corner of the acromion) is a starting portal for arthroscopic assessment of the shoulder when using a 30° arthroscope with a main viewing portal. The posterolateral portal is easy to access in the medial of the rotator interval, where the coracoid process exists, and not really using the 70°, which causes all kinds of anatomy distortion. While using the assisted arthroscopic approach, the glenohumeral joint lesions are simultaneously evaluated and treated. Many times, we found intra-articular pathology in high-grade AC joint dislocations that would have been missed if the traditional open reduction approach had been used.

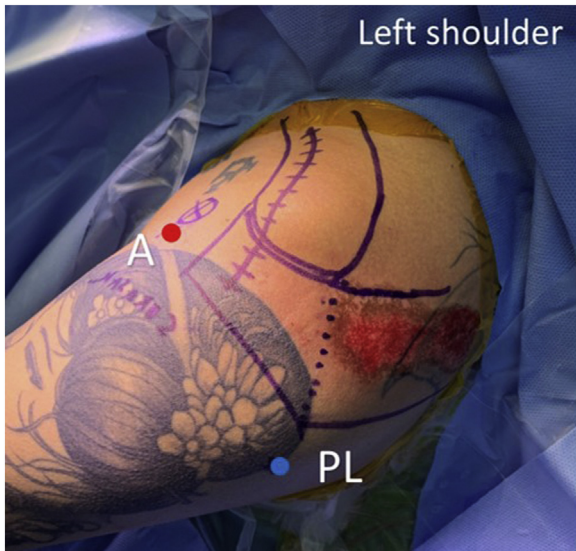
An anterior portal is created under direct vision or outside-in technique at center of the rotator interval. The rotator interval is completely released by radiofrequency electrocautery (RFE). The coracoid process was palpated prominently by the RFE between the medial and rotator intervals. The tip of RFE was directly palpated at 2 o'clock to the left side of the coracoid process, and we could touch the base of coracoid, which was where the horizontal plane was positioned. The major neurovascular structures such as the musculocutaneous nerve and brachial plexus are exposed by RFE and meticulously dissected greater than 1 cm medial to the base of the coracoid process. The arthroscope is removed and the switching rod is put in its place. (Fig 3).

### Distal Clavicle Bone and AC Joint Preparation

A 5-cm horizontal skin incision is made close to the anterior border of the clavicle and extended to the AC joint, with the acromion being incised 3 cm. The deltotrapezial raphe is identified and incised until it reaches the medial border of the distal clavicle part. The anterior and posterior border of the distal clavicle part are exposed (Fig 4). The AC joint and acromion are carefully dissected, and the deltotrapezial fascia and ACLC layers are separated. The ACLC is similar to



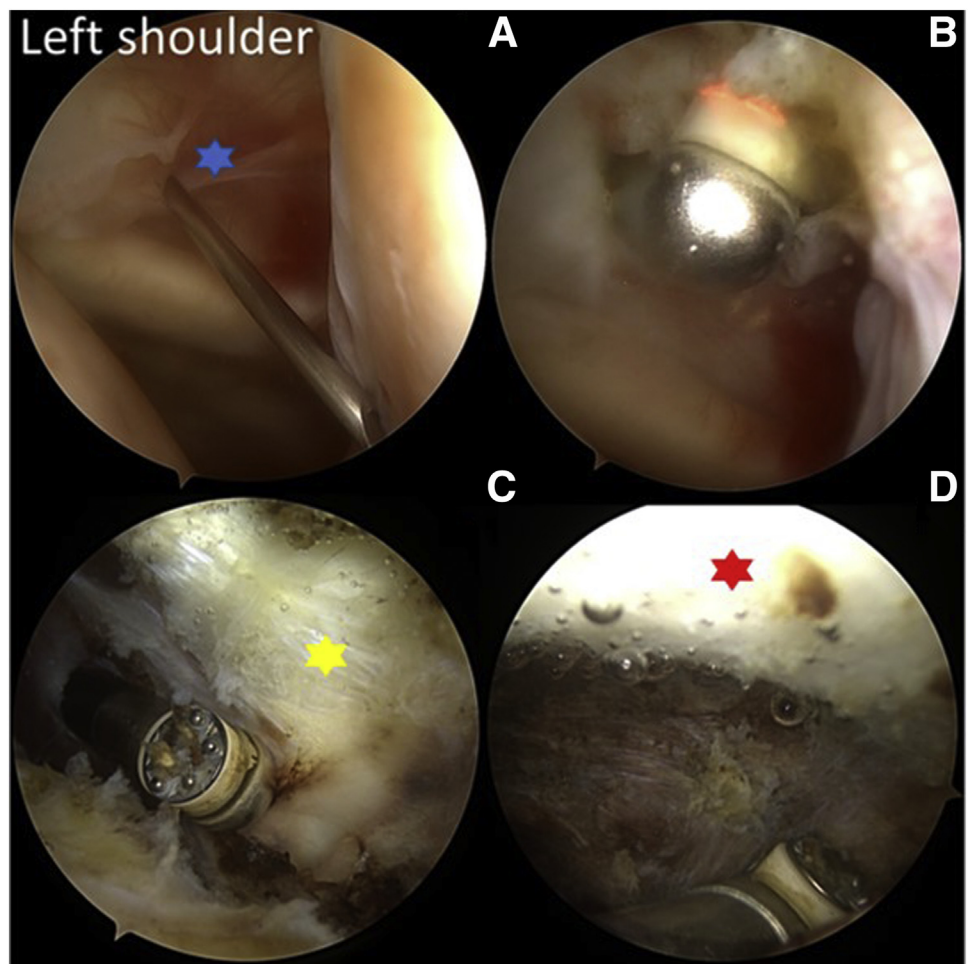
**Fig 1.** The beach-chair position with an assistant to hold the arm in desired position at the left shoulder.



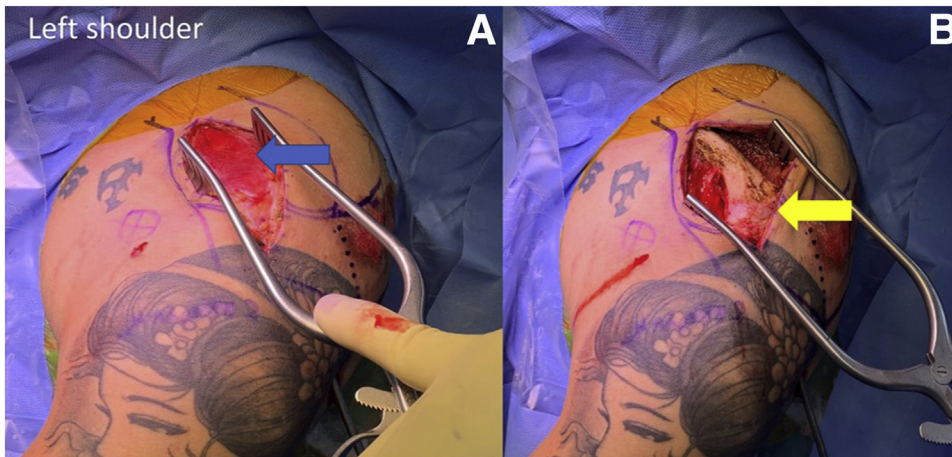
**Fig 2.** The planning portal placement (A, anterior portal [working portal]; PL, posterolateral portal [viewing portal]) at the left shoulder.

rotator cuff tear tissue, which is thick and always detached from the distal clavicle (Fig 5). The anterior border of the acromion bone should be recognized because it helps as a reference line for reducing an AC joint in the horizontal plane.

The posterolateral viewing portal is reinserted to the base of coracoid. Under arthroscopic assistance, a right-angle clamp with loop PDS (polydioxanone; Johnson & Johnson Medical N.V., Belgium) is inserted from the anterior border of the clavicle via the anterior deltoid muscle to touch the medial aspect of the coracoid bone. Always keep the clamp touching the upper part of the coracoid process to avoid injuring the neurovascular bundle at the medial of the coracoid base. A shuttling suture is grasped from the lateral aspect of the coracoid bone to take up the PDS (polydioxanone; Johnson & Johnson) and complete its loop around the coracoid. The ends of the right-angle clamp are clipped to allow subsequent shuttling of 2 FiberTape sutures (Arthrex, Naples, FL) and PDS. The 2 FiberTape sutures (Arthrex)



**Fig 3.** Demonstrated is the arthroscopic-assisted procedure in acromioclavicular joint dislocations at the left shoulder. (A) The anterior working portal was made at rotator interval by using needle insertion (blue star). (B) The rotator interval was released by radiofrequency electrocautery. (C) The coracoid process was exposed after releasing the rotator interval (yellow star) and (D) identified the base of coracoid process (red star).



**Fig 4.** Incisional planning at the left shoulder (A) exposed the deltotrapezial fascia raphe (blue arrow) and (B) the deltotrapezial fascia raphe was split and exposed the distal clavicle part and acromioclavicular joint (yellow arrow)

are confirmed to be placed under the coracoid process without soft-tissue interposition (Fig 6).

### Two Transosseous Tunnels Preparation

The bone reduction clamp is used to bring the distal clavicle to a superior position. On the distal clavicle, the ACLC native is marked. The first tunnel is drilled 4 mm from the articular part of the distal clavicle to the anterior using a 2.5-mm drill bit. The second tunnel is drilled from the 10-mm articular part of the distal clavicle to the anterior part of the clavicle by a 2.5-mm drill bit from the posterior to the anterior direction. The space between the tunnels, however, should be greater than 5 mm to avoid fracture. After finishing the CC stabilization, the 18-G needle with PDS is placed into the tunnel to prepare shuttle the 3 suture limbs by lateral tunnel using the single-loop PDS and medial tunnel using the double-loop PDS (Fig 7).

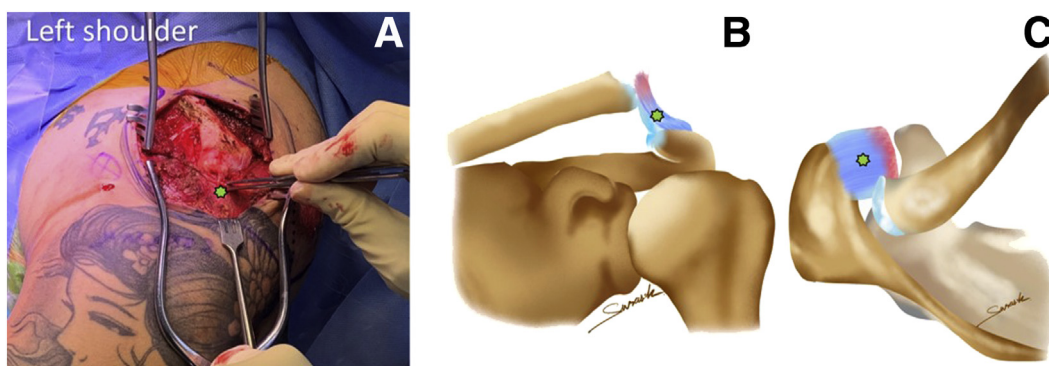
### Vertical and Horizontal Reduction of the AC Joint

An impactor instrumentation at the distal clavicle part creates an anteroinferior force (medial to the

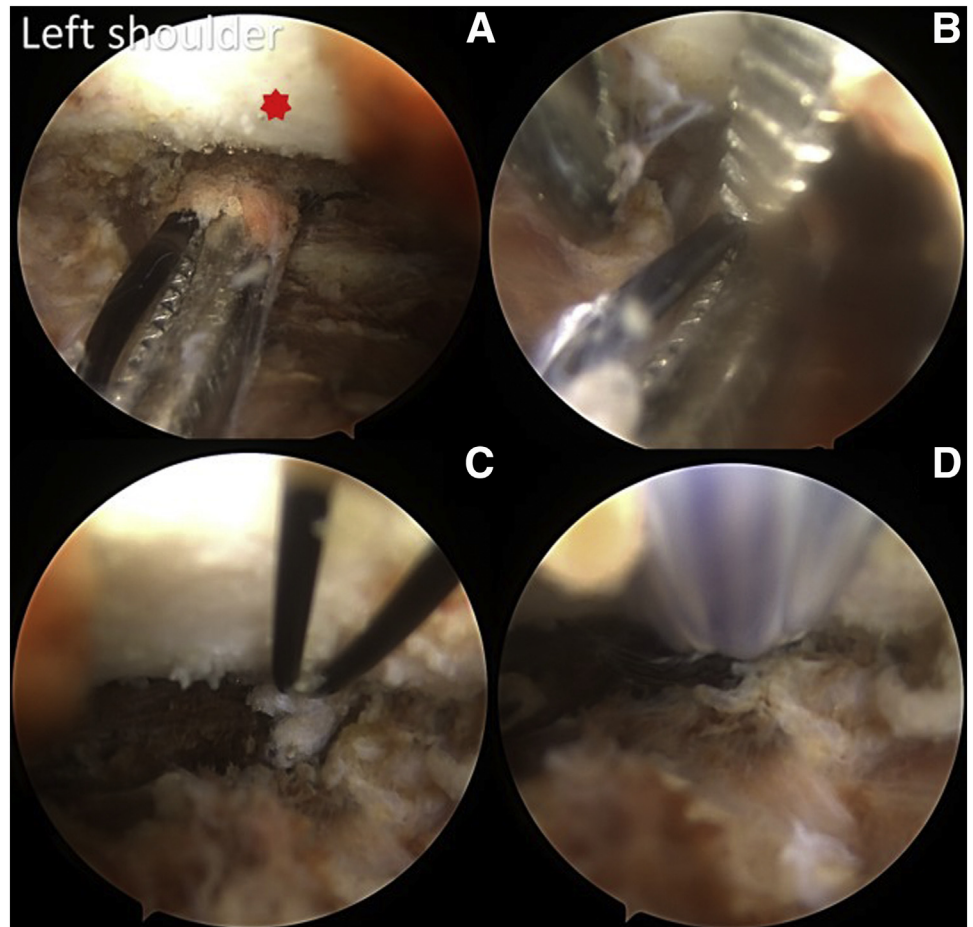
transosseous tunnel for preventing fracture). The superior edge of the distal clavicle is over-reduced by approximately 2 mm to provide vertical stabilization. Flushing between the anterior border of the acromion and the anterior border of the distal clavicle part is used to check the horizontal stabilization. By both the anterior and posterior parts of the distal clavicle aspect, the 2 No. 1.8 K-wires are parallelly inserted through the lateral border of the acromion to the far cortex of the distal clavicle. The image intensifier confirms the proper positioning of the 2 K-wires and the ACJ over-reduction (Fig 8).

### Two Clavicular Tunnels Preparation (Trapezoid and Conoid Tunnels)

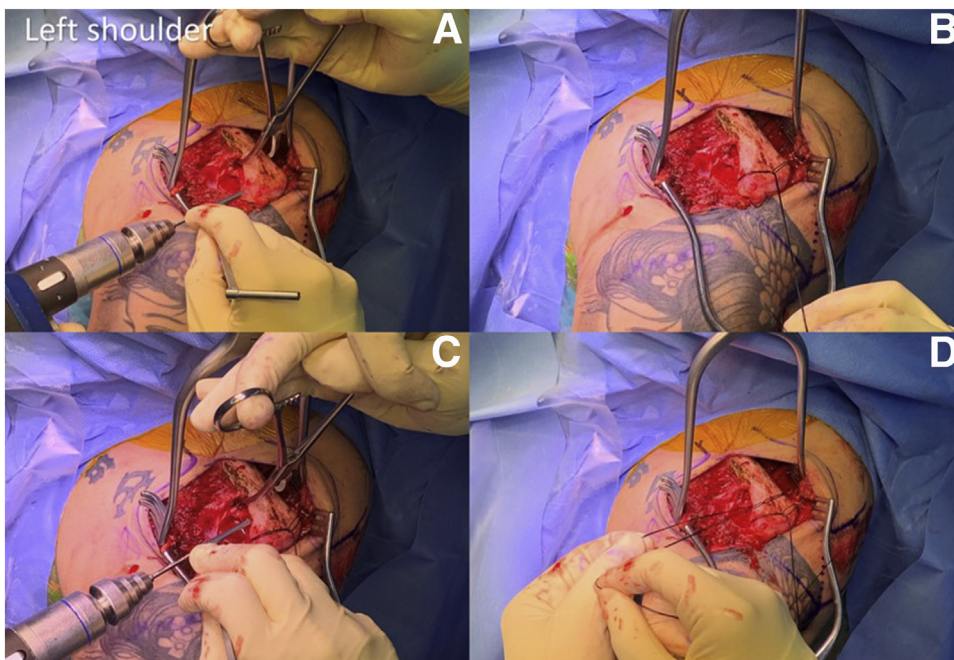
The native anatomical trapezoid and conoid ligaments are marked the clavicular tunnels. At 24 mm and 44 mm from the AC joint, respectively, the optimum positions of the CC ligament insertions and subsequent drill sites for the trapezoid and conoid tunnels are marked. The trapezoid tunnel's 3.5-mm drill hole is 2.5 cm away from the distal clavicle's medial side and



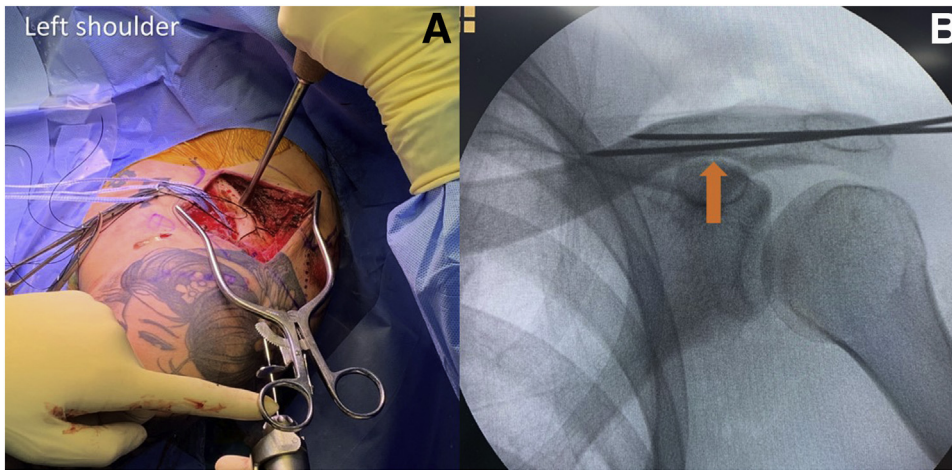
**Fig 5.** The anatomy of the acromioclavicular ligament complex (ACLC) at the left shoulder (A) the ACLC was dissected and obviously showed both of the acromioclavicular (AC) ligament and AC capsule (green star). (B) The ACLC in the coronal view (green star) and (C) The ACLC in the axial view (green star).



**Fig 6.** The loop suture of the base of the coracoid process by arthroscopic assisted (the posterolateral viewing portal) at the left shoulder. (A) The right-angle clamp with polydioxanone (PDS) inserted medially to the base of the coracoid process (red star). (B) The clamp perched the PDS from the right-angle clamp. (C) The PDS loop underneath the base of the coracoid process and (D) the 2 FiberTape sutures (FiberTape; Arthrex) were shuttled with the PDS (Johnson & Johnson). PL, posterolatera.



**Fig 7.** Two transosseous tunnels preparation at the left shoulder. (A) A 2.5-mm drill bit was used to drill the lateral tunnel from the front to the back. (B) The single polydioxanone loop inserted at lateral tunnel. (C) The medial tunnel was drilled with a 2.5-mm drill bit from front to back, with at least 5 mm from the lateral tunnel, and (D) the double polydioxanone loop inserted at medial tunnel.



**Fig 8.** The anatomical K-wire fixation of the ACJ at the left shoulder. (A) The impactor instrument reduced the AC joint and the two No. 1.6 K-wires fixed the anatomical AC joint and (B) checked that the two K-wire positions with CC distance should be less than 3 mm (orange arrow).

0.5 cm anterior to the clavicle's midline. The conoid tunnel's 3.5 mm-drill hole is 4.5 cm in length and 0.5 cm posterior to the clavicle's midline, far from medially the distal clavicle. The 2 clavicular tunnels were drilled perpendicular to the clavicle shaft from the superior of the near cortex to the far cortex of the distal clavicle. A PDS loop with the No. 18 needle is passed through the drill holes (conoid and trapezoid tunnels). The clamp grasps the loop of PDS underneath the clavicle and then is pulled to the anterior border of the clavicle. The 2 FiberTape sutures (medial to coracoid process limbs) are then inserted to the loop of medial tunnel (conoid tunnel) of the PDS and shuttled over the clavicular tunnel. The lateral tunnel (trapezoid tunnel) is repeated the same medial tunnel (conoid tunnel) step-by-step (Fig 9).

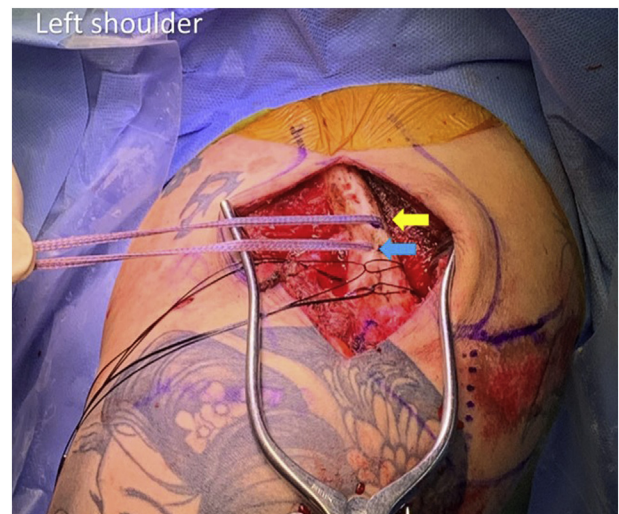
#### The Suture Knot Fixation With Suture Button

The FiberTape is passed through the 12-mm suture button (Arthrex), which is used as a cortical augmentation device to prevent a bone tunnel cut-through. Each of FiberTape sutures is inserted into the 12-mm suture button (Arthrex) and planed to suture knot was crossed each other's on the suture button. The suture button underneath should be checked for any knot spirals from the FiberTape sutures, as the suture button will toggle when the knot is tied, causing the CC stabilization to loosen. Before tying the knot, one assistant should over-reduce the AC joint with a medial impactor instrument to drill holes, and another assistant should pull up the scapular traction with a pair of FiberTape looped underneath the base of the coracoid process (Fig 10). While tying the knot on the suture button, both reduction forces were maintained. The other knot is tied by applying force, which is done in a step-by-step fashion. The image intensifier checks the reduction by comparing the previous CC distance, which should be less than 5 mm (Fig 11).

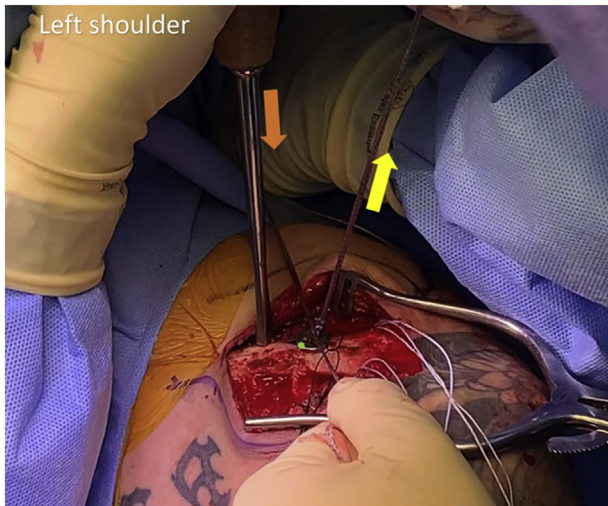
#### ACLC Repair With Anchorless Transosseous Double-Row Repair Technique

Three FiberWire 2-0 sutures (Arthrex) are shuttled with PDS at the lateral horizontal tunnel from the anterior to posterior direction (Fig 12). Each pair of suture limbs is retrograde sutured to the ACLC by 1 cm. We tied 3 knots for the lateral row of the suture bridge after suturing each pair of sutures in the anterior, superior, and posterior parts of the ACLC (Fig 13).

To create the medial row, 3 suture limbs are prepared for each suture limb. At the medial horizontal tunnel, the anterior section of the 3 suture limbs is shuttled with double-loop PDS from the anterior to the posterior. The posterior part of the 3 suture limbs is shuttled with double-loop PDS from the posterior to the anterior at the same tunnel (Fig 14). The medial row was created by tying 3 knots over the clavicle (Fig 15).



**Fig 9.** The conoid and trapezoid clavicular tunnels with shuttling the FiberTape sutures at the left shoulder.



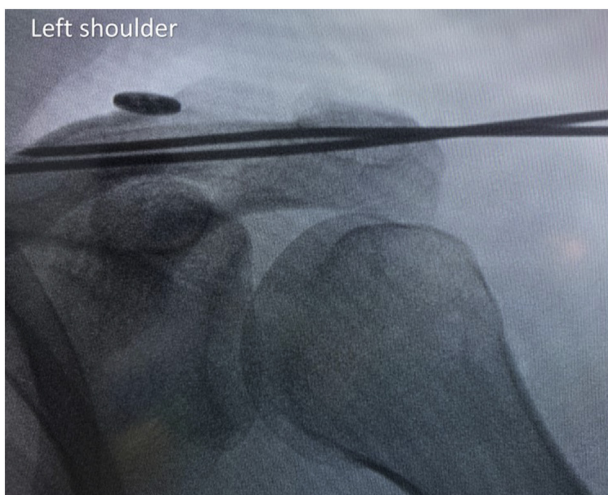
**Fig 10.** The suture knot-tying on the suture button (green star), the impactor instrument forced downward for maintaining the CC distance (orange arrow) and the other FiberTape was pulled up for reacting force with the impactor instrument (yellow arrow) at the left shoulder.

### Deltotrapezial Fascia Plication

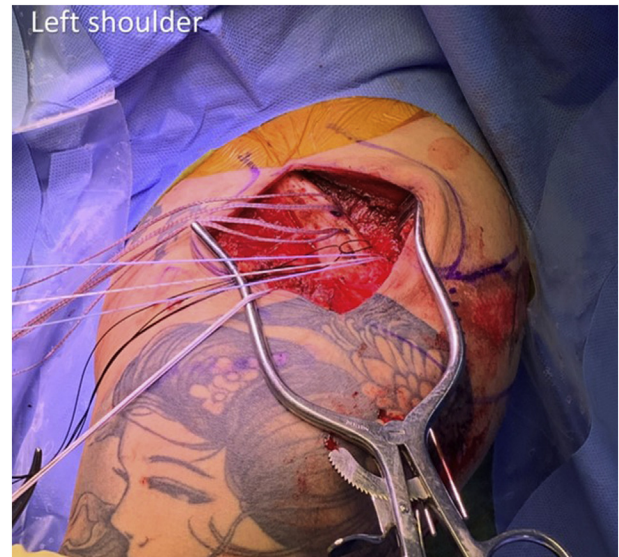
Along the incision, the deltotrapezial fascia was separated from the subcutaneous tissue. We recommend suturing the deltotrapezial fascia plication to stabilize the AC joint's dynamic stabilizer. With the figure-of-eight suture technique, 1-0 VICRYL is sutured approximately 2 cm anterior and posterior border of the deltotrapezial fascia. The deltotrapezial fascia is tightened to create more dynamic stability (Fig 16).

### Postoperative Rehabilitation

The arm sling is used to maintain the shoulder immobilized for 8 weeks. Because the pin migration and loosening problems are avoided, patients cannot do



**Fig 11.** Fluoroscopy is used to check the position of the suture button, and CC distance should be less than 5 mm.

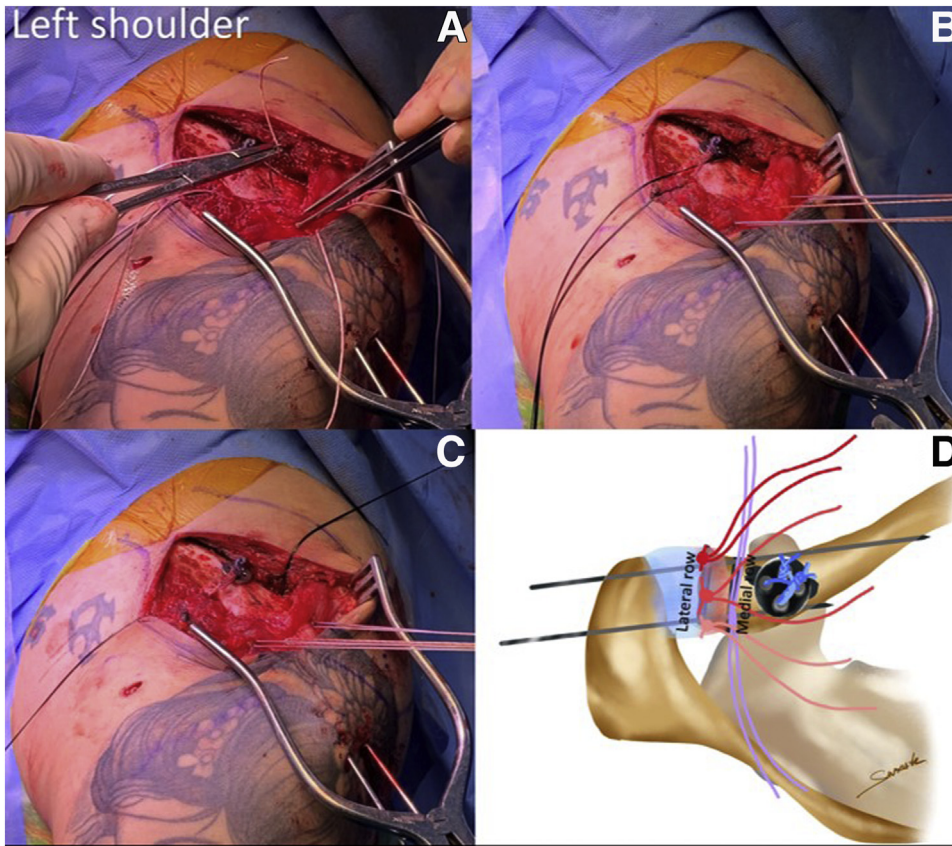


**Fig 12.** The 3 FiberWire sutures shuttling into the lateral horizontal tunnel of the distal clavicle at the left shoulder.

activities that affect the AC joint for the first 12 weeks. During the first 12 weeks, the heavy weights items made it impossible to lift. The 2 K-wires are removed at 8 weeks. Physiotherapy begins with passive and active-assisted range of motion exercises, with flexion and abduction restricted to 60° for the first 8 weeks and gradually increased to 90° after that.

### Discussion

The arthroscopically assisted CC stabilization and AC ligament complex repair with a combination 2 synergistic contribution is a new arthroscopy technique. This technique is designed to restore vertical, horizontal, and rotational instability, which currently, approximately 70 procedures published can guarantee to restore partially function and appearance of the shoulder, but not all directional of the AC joint, which is essential for success in function outcomes. For stabilization, a variety of implants have been used, but we found that CC stabilization with strong suture materials and augmented AC joint and ACLC had the lowest failure rate. The ACLC repair and CC stabilization provided bidirectional stability (vertical and horizontal planes) as well as rotational stability. Furthermore, the arthroscopic-assisted approach is a less-invasive and precise method of identifying related intra-articular pathology. A direct arthroscopic view of the base of the coracoid process confirmed that there was no soft-tissue interposition causing loosening suture tying and unsecured suture fixation. The K-wire temporary fixation with the image intensifier was used to fix the overreduction CC distance and maintain horizontal stability and vertical stability while allowing the ACLC to heal.

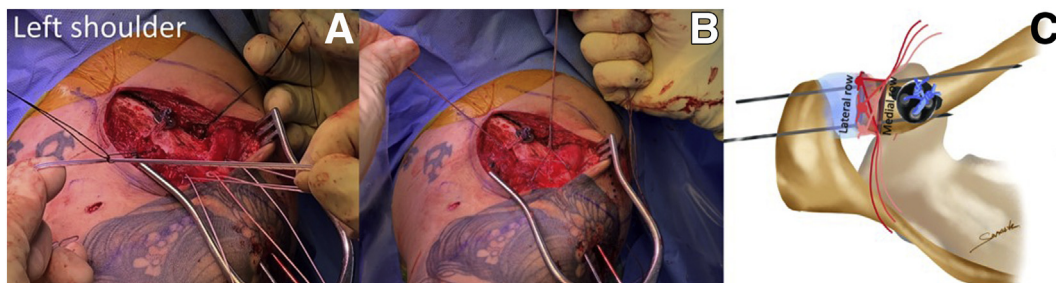

**Fig 13.** The lateral row suture of the left acromioclavicular ligament complex (ACLCL). (A) The 6 suture limbs were sutured from underneath to over the ACLCL. (B) The 6 suture limbs were sutured to cover the anterior, superior, and posterior of the ACLCL part. (C) Three knots were made on the lateral row and (D) after finished the lateral row knotting.

The ACLCL tear in AC joint dislocation had characteristics that were similar to the rotator cuff tissue tear from the greater tuberosity footprint. According to the results of biomechanical research, the suture bridge approach can improve pressurized contact area and mean pressure between the tendon and the footprint and may improve optimize the healing biology at a repaired rotator cuff insertion.<sup>11</sup> From the cadaveric study, the distance from lateral clavicle to end of capsuloligamentous insertion was 9.7 mm. The distance from lateral clavicle to medial intra-articular capsular

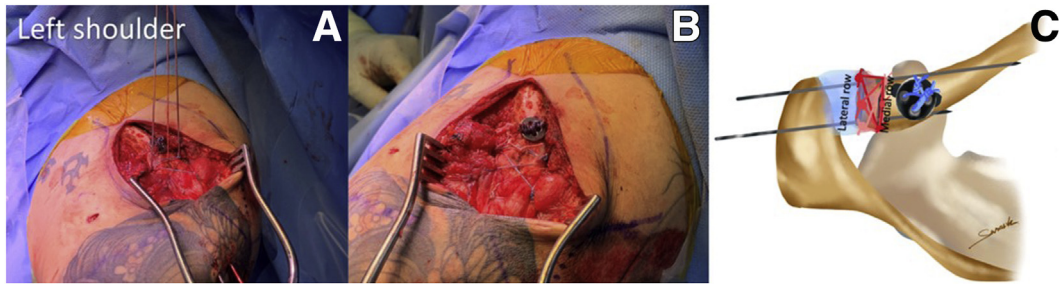insertion was 3.9 mm. The mean distances from the end of the lateral clavicle to the beginning of the trapezoid ligaments were 14.7 mm.<sup>12,13</sup> The posterolateral ligament's attachment site (posterolateral quadrant) has a wide footprint, which has been determined to provide the most stability to the AC joint. The use of an anchoring suture can increase the risk of iatrogenic fractures and bone pullout.<sup>14</sup>

According to the biomechanics study, there was a significant loss of posterior translation stability and rotational torque stability of the AC joint after



**Fig 14.** The medial row suture shuttling of the medial horizontal clavicular tunnel at the left shoulder. (A) The 3 different suture limbs shuttled from anteriorly to posteriorly with double loop polydioxanone (PDS) and the other 3 suture limbs also shuttled from posteriorly to anteriorly with double loop PDS. (B) All 6 suture limbs shuttling procedure was done and (C) after finished the 6 suture limbs shuttling procedure.





**Fig 15.** The medial row procedure at the left shoulder. (A) All 6 suture limb were paired with tying the knot on the distal clavicle. (B) The acromioclavicular ligament complex (ACLCL) was completely attached to the native ACLCL and (C) the graphic picture after finished the anchorless transosseous double-row repair.

completely cutting the AC capsule and ligament. However, reconstruction of the AC capsule significantly improved the stability against posterior translational and rotational torque.<sup>15</sup> The superior section of the ACLCL can be easily repaired or restored, resulting in posterior translational and rotational stability. However, repair of the entire superior ACLCL is recommended to repair the combination, ie, 3 regions (anterior with posterior, anterosuperior, and posterosuperior parts).<sup>7</sup> The scapulothoracic motion is related to the AC joint through the 3-dimensional shoulder function. The physiologic motion of the scapulothoracic and glenohumeral joints is abnormal if the AC capsule is completely resected.<sup>3</sup>

To reduce the AC joint and allow for CC and AC ligament healing, K-wires, Steinmann pins, or cerclage wires are used to repair it. The temporary K-wire fixation has several advantages in terms of allowing the AC ligament and capsule to recover while also protecting the repair site.<sup>16</sup> According to Leidel et al.,<sup>17</sup> K-wire migration was 4% and recurrent AC joint dislocation was 11% following the operation. After acromioclavicular stabilization, functional outcomes (constant score) related to a CC distance of less than 5 mm.<sup>18</sup>

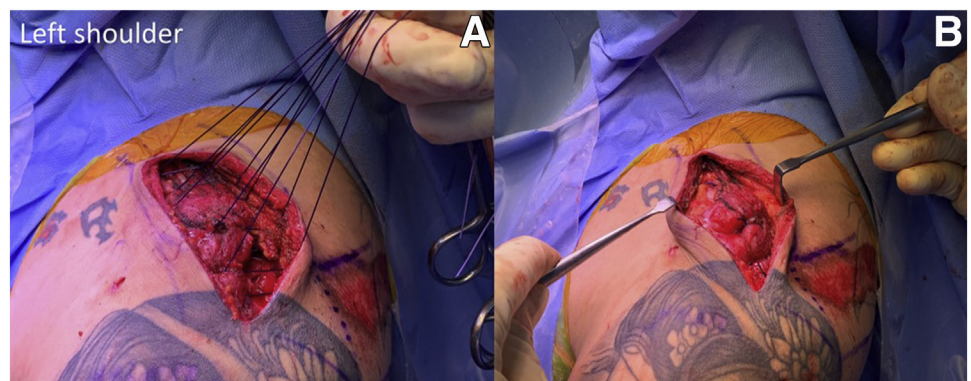
According to the timing of the AC ligament healing potential, a ligamentous state of healing occurs

approximately 12 weeks after the AC complex has been repaired by the intrinsic ligamentous healing process.<sup>19</sup> Overuse activity and aggressive rehabilitation programs should be avoided until the ACLCL, and CC ligament healing stability has been achieved. Based on one study, the AC complex healing process began 3 weeks after the acute AC joint dislocation. As a result, the AC joint procedure should be completed in less than 10 days because it is easier to identify the ACLCL structure and perform anatomical repair.<sup>20</sup>

Without AC joint augmentation or restoration, arthroscopy assisted CC stabilization can reveal unsatisfactory AC joint alignment in 34% of patients in the coronal plane and posterior instability in 42.9 percent of patients in the horizontal plane.<sup>21,22</sup> After anatomic CC reconstruction, the distance between bone tunnels affected the clavicle fracture, if the clavicular tunnels are spaced with a diameter less than 5 mm.<sup>23</sup>

The use of a CC PDS sling beneath the coracoid process prevented the coracoid process from being cut out by the TightRope approach and resulted in a significantly lower strain at a vertical displacement. As a result, we recommended that in the CC sling reconstruction technique, over-reduction is critical in preventing vertical displacement.<sup>24,25</sup>

We suggest that deltotracheal fascia plication be used in high-grade AC joint dislocations because it causes



**Fig 16.** The deltotracheal fascia plication at the left shoulder. (A) The whole layer of the deltotracheal fascia was suture with 1-0 VICRYL and (B) finished the deltotracheal fascia plication and looked like a bump appearance.

**Table 1.** Pearls and Tips

Surgical Step	Pearls and Tips	Pitfalls
1. Arthroscopic-assisted for preparing base of the coracoid process	The posterolateral portal is important for better visibility of the base of coracoid.	The anatomy of the glenohumeral joint structure is unfamiliar in terms of perspective and visualization.
2. The distal clavicle bone and AC joint and ACLC preparation	Simply to repair to the native ACLC anatomy and ensure that both horizontal and vertical stability can be corrected. Confirm that no soft tissue was inserted under the suture button, which might loosen the structural stabilization later.	Separate the layers of the deltotrapezial fascia and ACLC with carefully, and avoid dissecting into the AC joint, as you will have already cut the ACLC, making repair difficult.
3. Two transosseous tunnels preparation	The smaller drill size is important to avoid distal clavicle fracture, hence the 2.5-mm drilling size is used in the lateral and medial horizontal tunnels. The suture material of the monofilament (PDS) is used to protect the K-wire from penetrating through the suture.	To avoid distal clavicle fracture, the space between tunnels should be more than 5 mm.
4. Vertical and horizontal reduction of the AC joint	The elbow supporting and impactor instrument downward force are used as 2 reaction forces in the vertical reduction. The anterior border of the distal clavicle is flush with the anterior border of the acromial in the horizontal stability reference.	To avoid a distal clavicle fracture, the impactor instrument should be placed medially to the tunnel.
5. Two clavicular tunnels preparation (trapezoid and conoid tunnels)	Because the trapezoid and conoid tunnels will be more anatomically correct and decrease the acute angle of the tunnel, causing the clavicular tunnel to widen, the reduction AC joint should be performed first.	To avoid an acute angle between the suture and the clavicular tunnel, the conoid and trapezoid tunnels should be perpendicular to the distal clavicle.
6. The suture knot fixation with suture button	The coracoid process was longitudinally pulled up by scapular traction to reduce the CC distance during knot tying over the suture button.	To avoid knot irritation and tied prominently, fewer than 6 knots should be used.
7. AC ligament complex repair with anchorless transosseous double-row repair technique	Increased the area of the ACLC healing on the distal clavicle. The contact area pressure increased the rate of healing the ACLC.	The 6 suture limbs could be inserted overtightened into the medial tunnel, and the double loop PDS was shuttled through each suture limb one by one to make it easier to pass the suture limb.
8. Deltotrapezial fascia plication	Restored the dynamic stabilizer of the AC joint. The entire deltotrapezial fascia layer is sutured and plicated into a bump appearance.	The skin may be penetrated while dissecting the layer of subcutaneous layer and deltotrapezial fascia layer, especially the anterior skin, which is thin.

AC, acromioclavicular; ACLC, acromioclavicular ligament complex; CC, coracoclavicular; PDS, polydioxanone.

**Table 2.** Advantages, Limitations, and Disadvantages**Advantages**

The bidirectional and rotational stability of the AC joint was anatomically restored.

The associated intraarticular pathology was detected and treated using an arthroscopic assisted technique.

The synthetic material suture provided the strongest reliability and stability of the AC joint stabilization, the use of autografts was unnecessary, and donor site morbidity was avoided.

It is not necessary to return to remove the hardware.

The coracoid drilling holes were not present which caused the coracoid process fracture.

**Limitations and disadvantages**

The use of multiple knots above the clavicle may increase the risk of infection.

K-wire fixation is complicated by early degenerative changes and migration.

Because many holes have been drilled in the clavicular bone, a fracture could occur through the holes.

The passing suture should avoid the musculocutaneous nerve, which is in the 1 cm- medial coracoid process.

AC, acromioclavicular.

severe deltotrapezial fascia disruption or necessarily requires surgery. The dynamic stability of one part of the AC joint can be provided by the deltotrapezial fascia. In 15% of patients with high-grade AC joint dislocation, associated intra-articular lesions benefit from arthroscopic assistance.<sup>26</sup>

**Conclusions**

The AC joint would be able to achieve bidirectional and rotational stability using our technique. This surgery is used to restore normal anatomy, function, strength, range of motion, and the appearance of the shoulder in acute AC joint dislocations. This specific configuration technique improves other surgical techniques in regard of AC capsule and ligament healing, which is typically associated with horizontal and rotational stability. The failure of the AC joint stability was reduced by all the AC and CC stabilization (Tables 1 and 2).

## References

- Duquin TR. All-arthroscopic Weaver-Dunn-Chuinard procedure with double-button fixation for chronic acromioclavicular joint dislocation. *Yearbook Hand Upper Limb Surg* 2010;2010:180-181.
- Boileau P, Gstaald O, Wilson A, Trojani C, Bronsard N. All-arthroscopic reconstruction of severe chronic acromioclavicular joint dislocations. *Arthroscopy* 2019;35:1324-1335.
- Dyrna FGE, Imhoff FB, Voss A, et al. The integrity of the acromioclavicular capsule ensures physiological centering of the acromioclavicular joint under rotational loading. *Am J Sports Med* 2018;46:1432-1440.
- Hislop P, Sakata K, Ackland DC, Gotmaker R, Evans MC. Acromioclavicular joint stabilization: A biomechanical study of bidirectional stability and strength. *Orthop J Sports Med* 2019;7, 232596711983675.
- Kurata S, Inoue K, Hasegawa H, et al. The role of the acromioclavicular ligament in acromioclavicular joint stability: A cadaveric biomechanical study. *Orthop J Sports Med* 2021;9, 232596712098294.
- Dyrna F, Imhoff FB, Haller B, et al. Primary stability of an acromioclavicular joint repair is affected by the type of additional reconstruction of the acromioclavicular capsule. *The. Am J Sports Med* 2018;46:3471-3479.
- Morikawa D, Dyrna F, Cote MP, et al. Repair of the entire superior acromioclavicular ligament complex best restores posterior translation and rotational stability. *Knee Surg Sports Traumatol Arthrosc* 2018;27:3764-3770.
- Garofalo R, Castagna A. Editorial Commentary: Acute repair of the acromioclavicular joint capsule and ligaments and deltoid fascia could allow biological healing of high-grade acromioclavicular separation—coracoclavicular ligament graft augmentation could be indicated if time to surgery is greater than 3 weeks. *Arthroscopy* 2021;37:1096-1098.
- Beitzel K, Mazzocca AD. Open anatomic reconstruction of chronic acromioclavicular instability. *Oper Orthop Traumatol* 2014;26:237-244.
- Zumstein MA, Schiessl P, Ambuehl B, et al. New quantitative radiographic parameters for vertical and horizontal instability in acromioclavicular joint dislocations. *Knee Surg Sports Traumatol Arthrosc* 2017;26:125-135.
- Park MC, ElAttrache NS, Tibone JE, Ahmad CS, Jun B-J, Lee TQ. Part I: Footprint contact characteristics for a transosseous-equivalent rotator cuff repair technique compared with a double-row repair technique. *J Shoulder Elbow Surg* 2007;16:461-468.
- Stine IA, Vangsness CT. Analysis of the capsule and ligament insertions about the acromioclavicular joint: A cadaveric study. *Arthroscopy* 2009;25:968-974.
- Boehm TD, Kirschner S, Fischer A, Gohlke F. The relation of the coracoclavicular ligament insertion to the acromioclavicular joint: A cadaver study of relevance to lateral clavicle resection. *Acta Orthop Scand* 2003;74:718-721.
- Nolte Philip-C, Ruzbarsky JJ, Midtgaard KS, et al. Quantitative and qualitative surgical anatomy of the acromioclavicular joint capsule and ligament: A cadaveric study. *Am J Sports Med* 2021;49:1183-1191.
- Debski RE, Parsons IM, Woo SL-Y, Fu FH. Effect of capsular injury on acromioclavicular joint mechanics. *J Bone Joint Surg Am* 2001;83:1344-1351.
- Mazzocca AD, Arciero RA, Bicos J. Evaluation and treatment of acromioclavicular joint injuries. *Am J Sports Med* 2007;35:316-329.
- Leidel BA, Braunstein V, Kirchhoff C, Pilotto S, Mutschler W, Biberthaler P. Consistency of long-term outcome of acute Rockwood Grade III acromioclavicular joint separations after K-wire transfixation. *J Trauma* 2009;66:1666-1671.
- Greiner S, Braunsdorf J, Perka C, Herrmann S, Scheffler S. Mid to long-term results of open acromioclavicular-joint reconstruction using polydioxansulfate cerclage augmentation. *Arch Orthop Trauma Surg* 2008;129:735-740.
- Tuecking LR, Erdle B, Bernstein A, et al. Ligamentous healing potential of the acromioclavicular ligament following acute anatomical reconstruction [published online May 20, 2021]. *Arch Orthop Trauma Surg*. <https://doi.org/10.1007/s00402-021-03936-7>
- Maier D, Tuecking L-R, Bernstein A, et al. The acromioclavicular ligament shows an early and dynamic healing response following acute traumatic rupture. *BMC Musculoskelet Disord* 2020;21:593.
- Hann C, Kraus N, Minkus M, Maziak N, Scheibel M. Combined arthroscopically assisted coraco- and acromioclavicular stabilization of acute high-grade acromioclavicular joint separations. *Knee Surg Sports Traumatol Arthrosc* 2017;26:212-220.
- Salzmann GM, Walz L, Buchmann S, Glabgly P, Venjakob A, Imhoff AB. Arthroscopically assisted 2-bundle anatomical reduction of acute acromioclavicular joint separations. *Am J Sports Med* 2010;38:1179-1187.
- Spiegel U, Smith S, Euler SA, Dornan G, Millett PJ, Wijdicks CA. Biomechanical consequences of coracoclavicular reconstruction techniques on clavicle strength. *Orthop J Sports Med* 2014;2. 2325967114S0006 (7\_supp2).
- Martetschlager F, Buchholz A, Sandmann G, et al. Acromioclavicular and coracoclavicular PDS augmentation for complete AC joint dislocation showed insufficient properties in a cadaver model. *Knee Surg Sports Traumatol Arthrosc* 2012;21:438-444.
- Weiser L, Nüchtern JV, Sellenschloh K, et al. Acromioclavicular joint dislocations: Coracoclavicular reconstruction with and without additional direct acromioclavicular repair. *Knee Surg Sports Traumatol Arthrosc* 2015;25:2025-2031.
- Pauly S, Gerhardt C, Haas NP, Scheibel M. Prevalence of concomitant intraarticular lesions in patients treated operatively for high-grade acromioclavicular joint separations. *Knee Surg Sports Traumatol Arthrosc* 2008;17:513-517.