



Case report

Infections preceding the development of Dercum disease

Karen Beltran, investigation*, Rita Wadea, investigation, Karen L. Herbst, investigation

College of Medicine, University of Arizona, 1625 N Campbell Ave, Tucson, Arizona, 85724, United States

ARTICLE INFO

Article history:

Received 20 November 2019

Received in revised form 10 December 2019

Accepted 10 December 2019

Keywords:

Histoplasmosis

Toxoplasmosis

Lyme disease

Coccidioidomycosis

Dercum disease

ABSTRACT

Dercum Disease (DD) is a rare inflammatory disease of painful subcutaneous fat masses with known alterations in lymphatic vessels. DD masses vary from pearl to walnut-size or larger and occur anywhere in body fat. Signs and symptoms of DD are similar to fibromyalgia. While the etiology of DD is unknown, metabolic, autoimmune, or autosomal genetic transmission has been proposed. This series presents 7 cases where DD followed an infection either histoplasmosis, coccidioidomycosis or Lyme disease. Known changes in fat by infectious agents are reviewed. Early diagnosis and treatment of infections may prevent further damage to fat.

© 2019 The Authors. Published by Elsevier Ltd. This is an open access article under the CC BY-NC-ND license (<http://creativecommons.org/licenses/by-nc-nd/4.0/>).

Introduction

Dercum disease (adiposis dolorosa) is a syndrome of painful fatty growths with altered lymphatics [1,2], lipomas and/or angiolipomas [3] more common in women. The etiology is not known, but DD has been associated with infection since the 1800s including influenza [4], herpes zoster [5], erysipelas [6], typhus [5], measles [7], and malaria [8]. The lymphatic dysregulation in Dercum disease has been shown in a previous study with associated abnormal adipose tissue deposition [1], nonetheless there has not been a thorough analysis of how different infectious etiologies correlate with clinical manifestation prior to diagnosis. This paper presents seven cases of women with DD associated with infections including age at time of consent, approved by the University of Arizona Institutional Review Board.

Cases

Representative case

Case 4 Lyme Disease: A female age 37y presented for care due to painful lipomas. When infected at age 36y, the subject complained of neck stiffness, headaches, vertigo and fatigue lasting 3.5 weeks (see also Table 1). She initially noticed the development of a lipoma in her right groin and soon after noticed lipomas all over her body. As her lipomas were developing, she noticed burning and tingling in her arms, dilated veins in her legs, and easy bruising. She was

mistakenly diagnosed with adrenal failure and was prescribed hydrocortisone for 3 weeks, followed by increasing number of lipomas. Her past medical history was significant only for three non-painful lipomas removed age 27y. On physical exam she had multiple lipomas around the antecubital and brachial areas of the elbow, anterolateral ribs, abdomen, buttocks, and thigh ranging from the size of a pearl to a marble or walnut, and a large mass in the right groin measuring approximately 6×2 cm. No edema was noted. Histology of the fat from the upper abdomen was consistent with lipoma (Fig. 1A); the initial groin lipoma was full of connective tissue (Fig. 1B). Urine PCR was positive for *Borrelia burgdorferi* and *Bartonella henselae*. The patient was diagnosed with Dercum disease with active Lyme infection.

Past medical history, presenting symptoms of DD, and physical exam for case 4 and six other cases are presented in Table 1, and presenting symptoms of infection, laboratories and imaging used for diagnosis of the infections are presented in Table 2.

Summary of Cases: On a questionnaire, all participants stated they had an infection before diagnosis of DD raising the possibility of infection as a trigger of painful fatty masses in DD (Tables 1 and 2).

Discussion

The lymphatic system is an immune organ and can be affected by infection. Valley fever or coccidioidomycosis disseminates in the lymphatic system through macrophages causing impaired lymphatic drainage and inflammation of lymph nodes and lymphatic vessels [9].

toxoplasmosis causes bilateral, symmetrical, non-tender cervical adenopathy, highlighting involvement of the lymphatic system. Chronic toxoplasmosis infection modulates tissue lipoprotein

* Corresponding author.

E-mail address: kabeltran@email.arizona.edu (K. Beltran).

Table 1
History and exam findings of seven women with DD after infection.

Case	Age	Infection	Past Medical History	DD Symptoms	Exam Findings
1	58	Cocci	Asthma Hypothyroid Lipomas age 19 resected age 40	Progressive weakness Pins and needles peripheral limbs	Multiple fibrotic fat pads Multiple tender lipomas arms, abdomen, legs Edematous fat upper arms, medial knees, leg
2	24	Histo	Hypothyroid Migraines POTS MCAS Lipomas	Painful lipomas thighs Arm and leg swelling	Heavy fat pads arms, shoulders Diffuse lipomas subcutaneous fat
3	37	Borreliosis	Lipomas	Age 36y painful groin lipoma, then whole body lipomas Burning and tingling in arms Abdominal cramps Swelling Whole-body pain ~150 lipomas	Lipomas occiput, neck, supraclavicular, arms, ribs, abdomen, buttocks, and thighs Thick fat lower leg to ankle Lipomas anterior trunk, below breasts, proximal arms and legs
4	42	Borreliosis	Bilateral abdominal hernias Lipomas	Lipomas on arms and legs	Multiple fat pads Lipomas throughout subcutaneous fat
5	49	Borreliosis	Prediabetes NAFLD Adrenal adenoma		
6	48	Borreliosis	Fibromyalgia NAFLD	Painful lipomas shoulder, arm, hip, thigh with fibrotic tissue	Thick Diffuse pea-sized lipomas all subcutaneous fat
7	42	Borreliosis	MCAS Hypothyroid Angiolipoma	Multiple lipomas over rib cage, abdomen after heat	Swelling Fat pads upper arm, abdomen Lipomas cubital, lower arm, lateral abdomen, buttocks, thighs, knees, legs Edema

Abbreviations: Cocci= Coccidioidomycosis; Histo= Histoplasmosis; POTS = postural orthostatic tachycardia syndrome; MCAS = mast cell activation syndrome; NAFLD = non-alcoholic fatty liver disease.

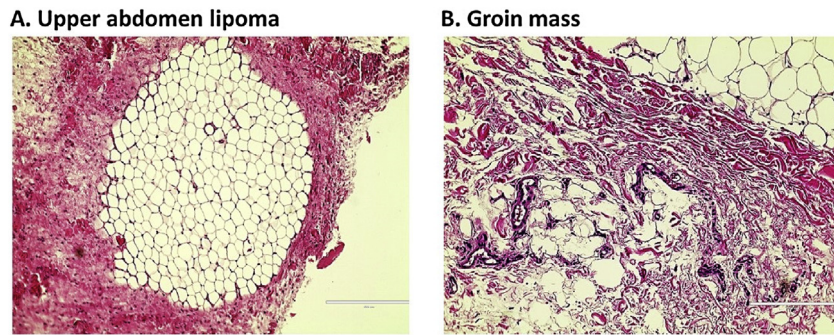


Fig. 1. Histology of fat tissue from Case 4 with Dercum disease infected with *Bartonella henselae* and *Borrelia burgdorferi*. **Fig. 1A:** Lipoma surrounded by pink connective tissue (H&E; 20X); **Fig. 1B:** Initial groin mass full of connective tissue (red colored tissue) and adipose tissue.

Table 2
Case series overview with symptoms, labs, ages and additional infections.

Case	Age Infected	Symptoms of Infection Before DD								Infection Labs and Imaging	Age Onset Dercum Disease	Time between infection and onset of DD	Additional Infections -found at time of testing*
		Fever/ Chills	Sweating	Fatigue	SOB	Arthralgia	Brain Fog	Headache	Myalgia				
1	40	Coccidioidomycosis								+Chest X-ray	57	17 years	None
		X	X	X	X								
2	10	Histoplasmosis								Chest CT calcified granulomas; Histoplasma antibody complement titer 1:32 (<1:8)	23	13 years	None
		X	X	X	X			X	X				
3	36	Borrelia burgdorferi (Lyme disease)								Urine PCR+ <i>Borrelia</i> and <i>Bartonella</i>	37	<1 year	<i>Bartonella henselae</i>
				X		X	X	X	X				
4	39	X	X	X	X	X	X	X	X	Borrelia serum + IgM; IgM index 1.5 (<0.90); +IgM blot	39	<1 year	<i>Toxoplasma</i> <i>Parvovirus</i> <i>Mycoplasma</i>
5	Teens	X	X	X	X	X	X	X	X	Western blot IgM + bands 39, 41; Urine PCR+ <i>Borrelia</i>	48	<1 year	<i>Chlamydia</i>
6	39		X	X	X	X	X	X	X	Western blot IgM + bands 23-25, 31, 34, 39, 41, 83-93	46	5 years	<i>Babesia</i>
7	39	X	X	X	X	X	X	X	X	Western blot IgG + bands 23-25, 31, 34, 39, 41, 83-93; Urine PCR+ <i>Borrelia burgdorferi</i> plasmid	39	<1 year	<i>Babesia</i> <i>Bartonella henselae</i> , <i>Rickettsia</i>

Abbreviations: CT = computed tomography; PCR = polymerase chain reaction; SAT = subcutaneous adipose tissue. *Species of some secondary infections unknown.

lipase activity favoring triglyceride partitioning from muscle towards fat, which may in part account for the occurrence of fatty masses [10]. Lyme disease caused by *Borrelia burgdorferi* causes lymphatic vessel dilatation [10] and has been associated with a septal and nodular panniculitis. Painful masses in DD are different from reported skin and tissue changes locally around tick bites in Lyme disease, and therefore may represent a primary effect on flow through tissue resulting in lymph stasis and fat growth [11].

The cases reported here had infections from less than one year to years before the development of DD. Since the lymphatic system can be altered in structure and function in DD [1,2], we hypothesize that an inflammatory process alters lymphatic function leading to edema, inflammation, fibrosis and development of painful masses consistent with DD. Several mediators of inflammation including IFN- α , IL-1 β , histamine and VEGF-C/VEGFR-3 have been shown to increase the permeability of lymphatics and facilitate vascular expansion to combat an immune response [12]. Further studies on VEGF-C function have demonstrated in a chronic inflammatory state its overexpression resulted in adipocyte hypertrophy, weight gain and insulin resistance in mice [13]. Inflammatory processes could result from trauma or other causes and not just infection as in a case reported as trauma induced DD [14].

Three cases presented here had lipomas earlier in life. Lipomas with altered lymphatic drainage may predispose to the development of an immune response and further exacerbation of fatty masses in the presence of infection. The co-infections in many of our cases may also have contributed to inflammation and growth of fat tissue.

This case series calls attention to the presence of lipomas occurring after infections including Lyme disease, histoplasmosis and coccidioidomycosis. Studies examining larger populations with infections are needed, and evaluation of adipose tissue and the lymphatic system in animal models of infections may provide evidence further connecting infection and changes in fat tissue consistent with lipomas.

Funding

This data has not been presented at any meeting.

This research did not receive any specific grant from funding agencies in the public, commercial, or not-for-profit sectors.

Declaration of Competing Interest

The authors state no conflict of interest.

References

- [1] Rasmussen JC, Herbst KL, Aldrich MB, et al. An abnormal lymphatic phenotype is associated with subcutaneous adipose tissue deposits in Dercum's disease. *Obesity* 2014;9:20836.
- [2] Tins BJ, Matthews C, Haddaway M, et al. Adiposis dolorosa (Dercum's disease): MRI and ultrasound appearances. *Clin Radiol* 2013;25: 00199-2.
- [3] Herbst KL, Asare-Bediako S. Adiposis dolorosa is more than painful fat. *Endocrinologist* 2007;17:326-44.
- [4] Bergeron PN. A case of adiposis dolorosa with involvement of the large nerve trunks. *J. Nerve* 1918; 36:159.
- [5] Price GE. Adiposis Dolorosa: a clinical and pathological study, with the report of two cases with necropsy. *Am J* 1909;137:705-14.
- [6] Eshner AA. A case of adiposis dolorosa. *JAMA* 1898;XXXI:1156-60.
- [7] Alger EM. Clinical memoranda: a case of adiposis dolorosa. *Medical News* 1901;78(1882-1905)91 (2 pages).
- [8] Frankenheimer JB. Adiposis dolorosa. *JAMA* 1908;L:1012-3.
- [9] Fernandez NJ, Henderson DW, Spotswood T, Christmas R. Multi-systemic disease in a dog. *Can Vet J* 2008;49:715-22.
- [10] Muller KE. Damage of collagen and elastic fibres by borrelia burgdorferi - known and new clinical and histopathological aspects. *Open Neurol J* 2012;6: 179-86, doi: <http://dx.doi.org/10.2174/1874205X01206010179> eCollection 2012.
- [11] Schneider M, Conway EM, Carmeliet P. Lymph makes you fat. *Nat Genet* 2005;37:1023-4.
- [12] Schwager S, Detmar M. Inflammation and lymphatic function. *Front Immunol* 2019;10(308), doi:<http://dx.doi.org/10.3389/fimmu.2019.00308> eCollection 2019.
- [13] Karaman S, Hollmen M, Yoon SY, et al. Transgenic overexpression of VEGF-C induces weight gain and insulin resistance in mice. *Sci Rep* 2016;6(31566), doi: <http://dx.doi.org/10.1038/srep31566>.
- [14] Hao D, Olugbodi A, Udechukwu N, Donato AA. Trauma-induced adiposis dolorosa (Dercum's disease). *BMJ Case Rep* 2018;2018., doi:<http://dx.doi.org/10.1136/bcr-2017-bcr-2017-223869>.