

REVIEW

Clinical application of multimodality imaging in radiotherapy treatment planning for rectal cancer

Yan Yang Wang, Hong Zhe

Department of Radiation Oncology, General Hospital of Ningxia Medical University, Yinchuan, China

Corresponding address: Yan Yang Wang, Department of Radiation Oncology, General Hospital of Ningxia Medical University, No. 804 Shengli Street, Yinchuan, Ningxia, China.

Email: fdwyy1981@hotmail.com

Date accepted for publication 24 September 2013

Abstract

Radiotherapy plays an important role in the treatment of rectal cancer. Three-dimensional conformal radiotherapy and intensity-modulated radiotherapy are mainstay techniques of radiotherapy for rectal cancer. However, the success of these techniques is heavily reliant on accurate target delineation and treatment planning. Computed tomography simulation is a cornerstone of rectal cancer radiotherapy, but there are limitations, such as poor soft-tissue contrast between pelvic structures and partial volume effects. Magnetic resonance imaging and positron emission tomography (PET) can overcome these limitations and provide additional information for rectal cancer treatment planning. PET can also reduce the interobserver variation in the definition of rectal tumor volume. However, there is a long way to go before these image modalities are routinely used in the clinical setting. This review summarizes the most promising studies on clinical applications of multimodality imaging in target delineation and treatment planning for rectal cancer radiotherapy.

Keywords: *Rectal cancer; radiotherapy treatment planning; computed tomography; magnetic resonance imaging; positron emission tomography/computed tomography.*

Introduction

Colorectal cancer is a common malignancy and remains a formidable health burden worldwide^[1]. Rectal cancer comprises approximately 33% of these cases^[2]. Preoperative radiotherapy, often combined with chemotherapy, followed by a total mesorectal excision (TME), has become the standard of care for patients with locally advanced rectal cancer^[3–5]. The success of radiotherapy is critically dependent on delivering an adequate radiation dose to tumor volumes while maximally sparing normal tissues and organs at risk^[6]. However, these strategies are heavily reliant on accurate target delineation^[7]. This review focuses on the clinical application of multimodality imaging in target delineation and treatment planning for rectal cancer radiotherapy, especially for preoperative radiotherapy.

Computed tomography

Historically, simulation and planning of radiotherapy for rectal cancer was based on orthogonal films. Rectal

contrast and bony landmarks were used to delineate the treatment volumes, supplemented by clinical examination to aid definition of the inferior extent of the tumor. The availability of computed tomography (CT) and sophisticated treatment planning software has improved target definition, reduced geographic miss, and enabled the design of precision three-dimensional conformal radiotherapy (3DCRT) (Fig. 1). Studies have shown that CT planning has advantages over orthogonal films in terms of definition of anterior and superior tumor borders and reduced toxicity in comparison with historical controls^[8,9]. However, visualization of pelvic structures using CT is limited by poor soft-tissue contrast between pelvic structures of similar Hounsfield units^[10]. When contouring target volumes for rectal cancer, it is important to set an image gray scale that maximizes the contrast between soft-tissue infiltration and normal fat. It is also important to adequately visualize air in the bowel (particularly the large intestine) to properly identify normal tissue. The routine window for abdominal CT scans is not optimal for this targeting. It is better to select a window and level that emphasize densities

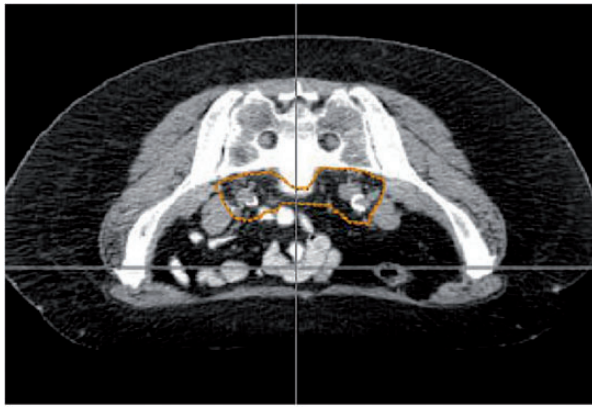


Figure 1 Outline of the clinical target volume (CTV) on the simulation CT scan of a patient with rectal cancer in the prone position. The CTV encompasses the possible regions into which the microscopic disease may extend, or regions with a high risk of involvement based on clinical experience (invisible tumor)^[31].

within the mesorectum, and which adequately display the contrast between air in the large bowel and the surrounding fat. Myerson and Drzymala^[11] recommend a level of about -60 Hounsfield units and a somewhat larger than routine window (~ 250 Hounsfield units) of approximately 600 Hounsfield units to help better identify both loops of bowel and perirectal soft-tissue densities.

According to previous research^[11] and our clinical experience, we generally distend the rectum with 50 ml of air at the time of simulation, so that the imaged boost target volume will incorporate an upper bound on the extent of rectal movement. This maneuver will not be feasible in patients who have substantial tumor-associated pain. However, such patients invariably have very advanced cancers, which are fixed anyway. Knowledge of bowel location and dose–volume histogram information is important in planning boost portals and interpreting treatment plans and outcome. Therefore, patients should be simulated with small bowel contrast. Intravenous contrast is not usually necessary. Major vessels can readily be identified by following sequential 3 -mm cuts.

Magnetic resonance imaging

During the past 2 decades, magnetic resonance imaging (MRI) has emerged as the most accurate staging modality for locally advanced rectal cancer. Dual phased-array, thin-section MRI has been shown to be the gold standard for rectal cancer staging, with sensitivities of 71 – 91% and specificities of 78 – 100% in detecting depth of penetration and lymph node metastasis^[12–15]. MRI addresses many of the limitations of CT, such as definition of depth of invasion through the rectal wall into local structures, and extension into presacral space and mesorectal

circumference, which are high-risk areas for recurrence (Fig. 2). MRI-defined tumor volumes for radiotherapy planning of rectal cancer could result in smaller, shorter, more accurate tumor contours, lying further from the anal sphincter^[16,17]. This would facilitate dose sparing to the normal tissues and escalation to the target.

O'Neill et al.^[18] reviewed imaging and planning data for 10 patients with locally advanced low rectal cancer. Tumor volume and location were compared for sagittal pretreatment MRI and planning CT. CT consistently overestimated all tumor radiologic parameters. Estimates of tumor volume, tumor length, and height of proximal tumor from the anal verge were larger on planning CT than on MRI. Tumor volumes defined on MRI are smaller, shorter, and more distal from the anal sphincter than CT-based volumes. Tan et al.^[19] compared the volumetric and spatial relationships of gross tumor volume (GTV) derived from CT (CT-GTV) and GTV derived from MRI (MR-GTV) to determine the utility of multimodality imaging for radiotherapy treatment planning in rectal cancer. Fifteen patients with T3-stage rectal cancer were accrued in this study. All patients underwent a diagnostic MRI and CT and MRI simulation. Data sets were coregistered. Tumor volumes were analyzed for 3 anatomical subregions (sigmoid, rectal, and anal). The mean CT-GTV/MR-GTV ratio was 1.2 . The tumor volume ratios for the rectal subregion were well correlated. CT-GTV provided adequate spatial coverage of tumor in reference to MR-GTV with an average mean discrepancy of 0.12 . CT-GTV coverage was inadequate for tumors with MRI evidence of anal and sigmoid invasion. The investigators concluded that conventional simulation CT imaging provided a reasonable estimate of the GTV. Multimodality imaging with staging MRI can assist target volume definition where there is involvement of the sigmoid and anorectal region, and avoid geographic misses. In the study conducted by Seierstad et al.^[20], rectal tumor volumes assessed by MRI prior to and after 2 cycles of chemotherapy given in a neoadjuvant setting were used as input for a novel simultaneous integrated boost (SIB) strategy in preoperative radiotherapy for locally advanced rectal cancer. MRI was performed prior to and after neoadjuvant chemotherapy. Sagittal and axial T_2 -weighted MRI of the pelvis was acquired using a fast spin-echo sequence (repetition time range, 4000 – 6000 ms; echo time, 85 ms; echo-train length, 12 ; number of excitations, 4 ; matrix size, 512×512 ; slice thickness, 5 mm; slice gap, 0 mm). In all tumor-containing axial T_2 -weighted MRI, GTV was manually delineated by an experienced MR radiologist. Planning CT images were rigidly coregistered with pre- and post-chemotherapy MRI using the coregistration option “Mutual information” in the treatment planning system. From the image registration, the MR-delineated GTV were automatically transferred to the CT planning basis. The investigators pointed out that MRI facilitated the delineation of boost volume for rectal cancer.

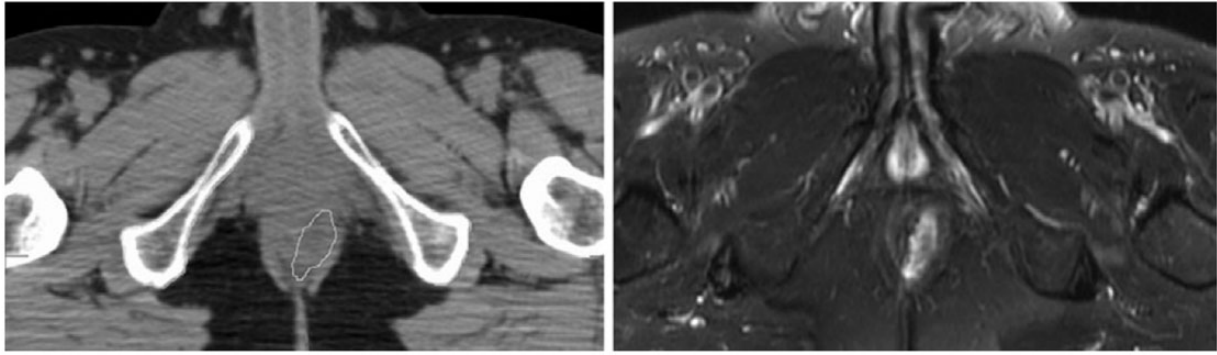


Figure 2 Outline of the gross tumor volume (GTV) on the simulation CT scan of a patient with rectal cancer in the supine position (left). The GTV is clearly shown on T₂-weighted MRI (right). It was not evident on CT and was not clinically detected. The GTV is the macroscopic volume of the tumor. The GTV defines the tumor volume determined by clinical examination and imaging modalities (visible, palpable)^[19].

Compared with CT, MRI defines the target volume of rectal cancer more simply and accurately. Adding the invasion part on MRI to the target volume can decrease the local recurrence induced by missing the target. In addition, MRI can be used in determining the target volume for rectal cancer brachytherapy^[21]. However, MRI also has its disadvantages, including lack of electron density information and potential image distortion. Tissue electron densities are required for accurate dose calculations and to account for tissue inhomogeneities within the treatment volume. Unlike CT data, whereby electron density can be automatically calibrated from Hounsfield units, MRI signal intensity has no such correlation. Therefore, CT images are also required for radiotherapy dose planning. Image coregistration has become an integrated tool in radiotherapy planning, and facilitates the use of multimodal imaging approaches for optimal target delineation^[10]. Dean et al.^[22] evaluated the CT–MRI coregistration accuracy of 4 commercial rigid-body techniques for external-beam radiotherapy treatment planning for rectal patients. Seventeen patients with biopsy-proven rectal cancer were scanned with CT and MRI in the prone position without the use of fiducial markers. Two automated and 2 manual techniques on 2 separate treatment planning systems were compared with a reference coregistration. Accuracy and reproducibility were analyzed using a measure of target registration error (TRE) that was based on the average distance of the misregistration between vertices of the clinically relevant GTV as delineated on the CT image. An automated technique achieved the greatest accuracy, with a TRE of 2.3 mm. Both automated techniques demonstrated perfect reproducibility and were significantly faster than their manual counterparts. There was a significant difference in TRE between registrations performed on the 2 planning systems, but there were no significant differences between the manual and automated techniques. The automated registration technique offered a fast and

accurate solution, with associated uncertainties within acceptable treatment planning limits.

More recently, diffusion-weighted MRI (DWI) has been documented as a potential tool for evaluation of tumors in the body^[23]. DWI is used to measure the Brownian motion of water molecules in tissue, which has been shown to be inversely proportional to cellular density^[24], presumably because increased cellular density limits water diffusion in the interstitial space. The apparent diffusion coefficient (ADC), a quantitative parameter measured on DWI, has been shown to be useful for evaluating solid tumors in the abdomen and pelvis^[25,26]. DWI evaluates the diffusion capacity of water molecules and obtains information about microscopic structures such as cell density or necrotic cell clusters, and therefore indirectly assesses tumor aggressiveness^[27]. Rao et al.^[28] found that the addition of DWI to conventional T₂-weighted imaging provides better detection of rectal cancer. In another study, Gu et al.^[29] made a comparison between MRI and positron emission tomography (PET) combine with CT (PET/CT) for rectal cancer. They found the significant negative correlations between ADC and standardized uptake value (SUV) to suggest an association between tumor cellularity and metabolic activity in primary rectal adenocarcinoma. Van Brussel et al.^[30] investigated the potential role of DWI in the delineation of the target. They used DWI in intensity-modulated radiotherapy (IMRT) dose painting for 5 rectal cancer patients. The boost volume was defined as a focal area of high signal detected in the rectum in high *b* value images (1000 s/mm²). Photon IMRT and an SIB were used to treat the whole pelvis with 45 Gy, and the region with the maximum diffusion restriction (on DWI with the highest *b* value) with 52.5 Gy in 25 treatments. Dose–volume constraints for small bowel were met in all 5 patients with a combination of 6, 7, or 8 beams. As a functional imaging modality, DWI can detect rectal cancer more accurately and

provide tumor metabolic information, which facilitated the dose painting of IMRT. DWI promises to become an important branch of bioinformation-guided radiotherapy research.

MRI can affect the determination of both GTV and clinical target volume (CTV). The Radiation Therapy Oncology Group (RTOG) recommended that rectal cancer CTV should include at least the internal iliac, presacral, and perirectal nodal regions^[31]. Although the contrast agent has not obtained approval by the US Food and Drug Administration, some studies have suggested that lymphotropic nanoparticle MRI (LNMRI) can improve the ability to characterize lymph nodes as benign or malignant beyond size criteria alone^[32,33]. As a novel imaging technique, LNMRI is mostly used in lymph node diagnosis of genitourinary tumor^[34,35]. Just as for prostate cancer, LNMRI may also affect the CTV for rectal cancer radiotherapy.

Application of MRI in radiotherapy treatment planning for rectal cancer is an emerging research area. We are unable to provide recommendations regarding the optimum protocols for the use of MRI in radiotherapy planning given the relatively lower experience and published patients numbers utilising this technique compared to that available for CT.

Positron emission tomography

PET has been recognized as an important imaging modality for the diagnosis and staging of many malignant diseases because of its ability to provide metabolic activity information on malignant tumors. For colorectal cancer, PET/CT has an accuracy between 83% and 93% for initial staging, 96% sensitivity and 97% specificity

for local recurrence, and 95% sensitivity and 98% specificity for detecting distant metastases^[36,37]. PET/CT is increasingly being applied in oncology to assist with initial staging of tumors as well as monitoring response to therapy in several disease sites. This has translated into increased incorporation of combined-modality PET/CT into radiation oncology for treatment planning^[38] (Fig. 3).

Buijsen et al.^[39] compared CT-, MRI-, and PET/CT-based tumor length measurements in rectal cancer with pathology. Twenty-six patients with rectal cancer underwent both MRI and PET/CT imaging followed by short-course radiotherapy (5×5 Gy) and surgery within 3 days after radiotherapy. Tumor length was measured manually and independently by 2 observers on CT, MRI, and PET/CT. PET/CT-based tumor length measurements were also generated automatically using the signal-to-background-ratio (SBR) method. The SBR method was used to find for each patient a percentage threshold of the maximal SUV within a user-defined volume of interest around the tumor. All measurements were correlated with the tumor length on the pathologic specimen. CT-based measurements did not show a valuable correlation with pathology. MR-based measurements correlated only weakly, but still significantly. Manual PET/CT measurements reached a good correlation with pathology, but less strong than automatic PET/CT-based measurements, which provided the best correlation. This study demonstrated that automatically generated PET/CT-based contours show the best correlation with the surgical specimen, and thus provide a useful and powerful tool to accurately determine the largest tumor dimension in rectal cancer. Bassi et al.^[40] compared CT with PET/CT scans with respect to rectal tumor volumes for 25

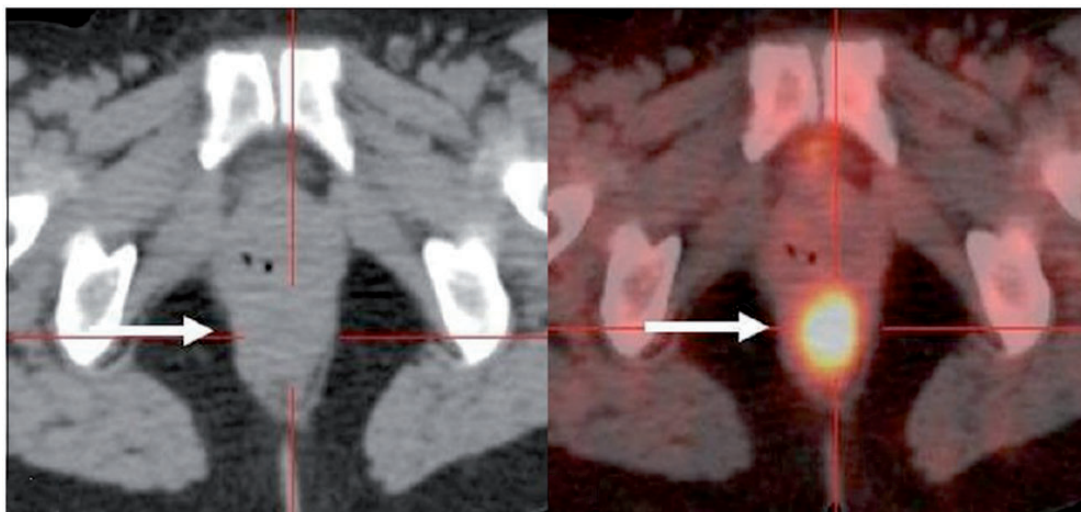


Figure 3 Axial unenhanced CT scan (left) shows ill-defined soft-tissue thickening in the perianal region (arrow) without definite evidence of a nodule/mass. Fusion PET/CT image (right) shows an intense focus of hypermetabolism corresponding to the soft-tissue thickening, suggesting rectal cancer, which can help the radiation oncologist to define the GTV^[48].

patients with rectal cancer who were candidates for preoperative radiotherapy. The GTV and CTV were delineated on the basis of CT and PET/CT. In 24% of the patients, PET/CT affected tumor staging or the treatment purpose; in 12%, PET/CT showed an uptake in the regional lymph nodes, and in one case also in the liver. The PET/CT GTVs were statistically significantly larger than the CT GTVs, the mean difference being 25%. Brændengen et al.^[441] compared delineation of GTV using PET/CT and MRI for a group of patients with rectal cancer. Seventy-seven consecutive patients were prospectively screened for inclusion in the study. Standard GTV was delineated using information from clinical examination, CT, and MRI (GTV-MRI). Thereafter, a GTV-PET was defined in the PET/CT, and the target volume delineations were compared for total volume, overlap, and mismatch. The median volume of GTV-MRI was larger than that of GTV-PET: 111 ml versus 87 ml ($P < 0.001$). In many cases, the GTV-MRI contained the GTV defined on the PET/CT images as subvolumes, but when a GTV total was calculated after the addition of GTV-PET to GTV-MRI the volume increased, with a median of 11%.

Another advantage of PET scanning is the ability to use the quantitative information of the tracer uptake within the tumor to automatically create a contour around the tumor. This contouring process significantly reduces the interobserver variability in the interpretation of images, as it eliminates the human factor, increases consistency, and diminishes interobserver variability^[42,43]. Krengli et al.^[44] analyzed the interobserver variation for target volume delineation in preoperative radiotherapy of rectal cancer, and concluded that PET/CT may allow a reduced interobserver variation in GTV delineation in comparison with CT. Buijsen et al.^[45] analyzed the effect of the use of PET/CT on the interobserver variation in GTV definition in rectal cancer. Forty-two patients diagnosed with rectal cancer underwent PET/CT for radiotherapy planning. An automatic contour was created on the PET scan using the source-to-background ratio. The GTV was delineated by 5 observers in 3 rounds: using CT and MRI, using CT, MRI, and PET, and using CT, MRI, and PET auto-contour. GTV volumes were compared and concordance indices (CI) were calculated. GTV volumes based on PET were found to be significantly smaller. CIs increased significantly using PET, and the best interobserver agreement was observed using PET auto-contours.

PET seems to be promising in target determination, but there are several methodological issues that need to be addressed, including the method for tumor volume segmentation and the selection of optimal tracer for rectal cancer. In the study by Day et al.^[46], 3 segmentation methods were evaluated and compared for patients with rectal and anal cancer: percentage of the maximum SUV ($SUV_{\%max}$), fixed SUV cutoff of 2.5 ($SUV_{2.5}$), and mathematical technique based on a

confidence-connected region-growing (CCRG) method. The CCRG method is based on a region-growing method using the pixel intensity data of the tumor region in an iterative statistical manner to detect the edge of the tumor mass. PET/CT imaging studies for 18 patients who received radiotherapy were used to evaluate the segmentation methods. A PET-avid (PET_{avid}) region was manually segmented for each patient, and the volume was then used to compare the calculated volumes along with the absolute mean difference and range for all methods. For the $SUV_{\%max}$ method, the volumes were always smaller than the PET_{avid} volume by a mean of 56%. The volumes from the $SUV_{2.5}$ method were either smaller or larger than the PET_{avid} volume by a mean of 37%. The CCRG approach provided the best results, with a mean difference of 9%. This study showed that the CCRG technique can be used in the segmentation of tumor volumes on PET images for patients with rectal cancer. Roels et al.^[47] investigated the use of PET/CT with fluorodeoxyglucose (FDG), fluorothymidine (FLT), and fluoromisonidazole (FMISO) for radiotherapy target definition and evolution in rectal cancer. PET/CT was performed before and during preoperative chemoradiotherapy in 15 patients with resectable rectal cancer. PET images were used for treatment target delineation, and CT images on the different time points were nonrigidly registered. Mismatch analyses were carried out to quantify the overlap between FDG and FLT or FMISO tumor volumes (TV) and between PET TVs over time. Ninety sequential PET/CT images were analyzed. On each time point, the mean FDG-PET TV was significantly larger than the FMISO-PET TV but not significantly larger than the mean FLT-PET TV. There was a mean 65% mismatch between the FMISO and FDG TVs obtained before and during CRT. FLT TVs corresponded better with the FDG TVs (25% mismatch before and 56% during chemoradiotherapy). During chemoradiotherapy, on average 61% of the mean FDG TV (7 ml) overlapped with the baseline mean TV (15.5 ml). For FLT, the TV overlap was 49%, and for FMISO only 20% of the TV during chemoradiotherapy remained inside the contour at baseline. It was concluded that FDG, FLT, and FMISO-PET reflect different functional characteristics that change during chemoradiotherapy in rectal cancer. FLT and FDG show good spatial correspondence, while FMISO seems less reliable owing to the nonspecific FMISO uptake in normoxic tissue and tracer diffusion through the bowel wall. FDG and FLT-PET/CT imaging seem most appropriate for integration in preoperative radiotherapy for rectal cancer.

PET/CT affects rectal cancer staging, and increase target definition and contouring consensus. After thorough methodological research and combined use with MRI, PET/CT may come to play an essential role in target definition for rectal cancer.

Conclusions

3DCRT and IMRT are the mainstay techniques for rectal cancer treatment. CT simulation is a cornerstone of these modern techniques, but has limitations, such as poor soft-tissue contrast between pelvic structures and partial volume effects. MRI and PET can overcome these limitations and provide additional information for the planning of rectal cancer treatment. In addition, PET can affect rectal cancer staging, and increase target definition and contouring consensus. However, there is long way to go before these imaging modalities are routinely used in clinical settings. Several questions, such as the registration method for MRI and CT, the value of DWI in rectal cancer radiotherapy treatment planning, the tumor volume segmentation method of PET imaging, and the optimal tracer for rectal cancer PET imaging, need to be answered by further research.

Acknowledgements

This work was supported by Ningxia Science & Technology Supporting Program (2012).

Conflict of interest

The authors have no conflicts of interest to declare.

References

- [1] Kosinski L, Habr-Gama A, Ludwig K, Perez R. Shifting concepts in rectal cancer management: a review of contemporary primary rectal cancer treatment strategies. *CA Cancer J Clin* 2012; 62: 173–202.
- [2] Glimelius B, Grönberg H, Järhult J, Wallgren A, Cavallin-Ståhl E. A systematic overview of radiation therapy effects in rectal cancer. *Acta Oncol* 2003; 42: 476–492.
- [3] Sauer R, Fietkau R, Wittekind C, et al. German Rectal Cancer Group. Adjuvant vs. neoadjuvant radiochemotherapy for locally advanced rectal cancer: the German trial CAO/ARO/AIO-94. *Colorectal Dis* 2003; 5: 406–415.
- [4] Kapiteijn E, Marijnen CA, Nagtegaal ID, et al. Dutch Colorectal Cancer Group. Preoperative radiotherapy combined with total mesorectal excision for resectable rectal cancer. *N Engl J Med* 2001; 345: 638–646.
- [5] Sebag-Montefiore D, Steele R, Quirke P, Grieve R, Khanna S, Monson J. Routine short course pre-op radiotherapy or selective post-op chemoradiotherapy for resectable rectal cancer? Preliminary results of the MRC CR07 randomised trial. *J Clin Oncol* 2006; 24: 3511.
- [6] Valentini V, Beets-Tan R, Borras JM, et al. Evidence and research in rectal cancer. *Radiother Oncol* 2008; 87: 449–474.
- [7] Gwynne S, Mukherjee S, Webster R, Spezi E, Staffurth J, Coles B, Adams R. Imaging for target volume delineation in rectal cancer radiotherapy—a systematic review. *Clin Oncol (R Coll Radiol)* 2012; 24: 52–63.
- [8] Cella L, Ciscognetti N, Martin G, et al. Preoperative radiation treatment for rectal cancer: comparison of target coverage and small bowel NTCP in conventional vs. 3D-conformal planning. *Med Dosim* 2009; 34: 75–81.
- [9] Borger JH, van den Boggaard J, de Haas DF, et al. Evaluation of three different CT simulation and planning procedures for the preoperative irradiation of operable rectal cancer. *Radiother Oncol* 2008; 87: 350–356.
- [10] Khoo VS, Joon DL. New developments in MRI for target volume delineation in radiotherapy. *Br J Radiol* 2006; 79: S2–S15.
- [11] Myerson R, Drzymala R. Technical aspects of image-based treatment planning of rectal carcinoma. *Semin Radiat Oncol* 2003; 13: 433–440.
- [12] Blomqvist L, Rubio C, Holm T, Machado M, Hindmarsh T. Rectal adenocarcinoma: assessment of tumour involvement of the lateral resection margin by MRI of resected specimen. *Br J Radiol* 1999; 72: 18–23.
- [13] Brown G, Richards CJ, Newcombe RG, et al. Rectal carcinoma: thin section MR imaging for staging in 28 patients. *Radiology* 1999; 211: 215–222.
- [14] Brown G, Radcliffe AG, Newcombe RG, Dallimore NS, Bourne MW, Williams GT. Preoperative assessment of prognostic factors in rectal cancer using high-resolution magnetic resonance imaging. *Br J Surg* 2003; 90: 355–364.
- [15] MERCURY Study Group. Diagnostic accuracy of preoperative magnetic resonance imaging in predicting curative resection of rectal cancer: prospective observational study. *BMJ* 2006; 333: 779.
- [16] Beets-Tan RG, Beets GL, Vliegen RF, et al. Accuracy of magnetic resonance imaging in prediction of tumour-free resection margin in rectal cancer surgery. *Lancet* 2001; 357: 497–504.
- [17] Kulkarni T, Gollins S, Maw A, Hobson P, Byrne R, Widdowson D. Magnetic resonance imaging in rectal cancer downstaged using neoadjuvant chemoradiation: accuracy of prediction of tumour stage and circumferential resection margin status. *Colorectal Dis* 2008; 10: 479–489.
- [18] O'Neill BD, Salerno G, Thomas K, Tait DM, Brown G. MR vs CT imaging: low rectal cancer tumour delineation for three-dimensional conformal radiotherapy. *Br J Radiol* 2009; 82: 509–513.
- [19] Tan J, Lim Joon D, Fitt G, et al. The utility of multimodality imaging with CT and MRI in defining rectal tumour volumes for radiotherapy treatment planning: a pilot study. *J Med Imaging Radiat Oncol* 2010; 54: 562–568.
- [20] Seierstad T, Hole KH, Saelen E, Ree AH, Flatmark K, Malinen E. MR-guided simultaneous integrated boost in preoperative radiotherapy of locally advanced rectal cancer following neoadjuvant chemotherapy. *Radiother Oncol* 2009; 93: 279–284.
- [21] Smith JA, Wild AT, Singhi A, et al. Clinicopathologic comparison of high-dose-rate endorectal brachytherapy versus conventional chemoradiotherapy in the neoadjuvant setting for resectable stages II and III low rectal cancer. *Int J Surg Oncol* 2012; 2012: 406568.
- [22] Dean CJ, Sykes JR, Cooper RA, et al. An evaluation of four CT-MRI co-registration techniques for radiotherapy treatment planning of prone rectal cancer patients. *Br J Radiol* 2012; 85: 61–68.
- [23] Lambrecht M, Deroose C, Roels S, et al. The use of FDG-PET/CT and diffusion-weighted magnetic resonance imaging for response prediction before, during and after preoperative chemoradiotherapy for rectal cancer. *Acta Oncol* 2010; 49: 956–963.
- [24] Guo AC, Cummings TJ, Dash RC, Provenzale JM. Lymphomas and high-grade astrocytomas: comparison of water diffusibility and histologic characteristics. *Radiology* 2002; 224: 177–183.
- [25] Taouli B, Vilgrain V, Dumont E, Daire JL, Fan B, Menu Y. Evaluation of liver diffusion isotropy and characterization of focal hepatic lesions with two single-shot echo-planar MR imaging sequences: prospective study in 66 patients. *Radiology* 2003; 226: 71–78.
- [26] Zhang J, Tehrani YM, Wang L, Ishill NM, Schwartz LH, Hricak H. Renal masses: characterization with diffusion-weighted MR imaging—a preliminary experience. *Radiology* 2008; 247: 458–464.
- [27] Kanauchi N, Oizumi H, Honma T, et al. Role of diffusion-weighted magnetic resonance imaging for predicting of tumor

- invasiveness for clinical stage IA non-small cell lung cancer. *Eur J Cardiothorac Surg* 2009; 35: 706–710.
- [28] Rao SX, Zeng MS, Chen CZ, et al. The value of diffusion-weighted imaging in combination with T2-weighted imaging for rectal cancer detection. *Eur J Radiol* 2008; 65: 299–303.
- [29] Gu J, Khong PL, Wang S, Chan Q, Law W, Zhang J. Quantitative assessment of diffusion-weighted MR imaging in patients with primary rectal cancer: correlation with FDG-PET/CT. *Mol Imaging Biol* 2011; 13: 1020–1028.
- [30] Van Brussel S, Deckers F, Van Laere S. IMRT for rectal cancer patients based on diffusion weighted MRI (DWMRI). *Int J Radiat Oncol Biol Phys* 2008; 72: S251.
- [31] Myerson RJ, Garofalo MC, El Naqa I, et al. Elective clinical target volumes for conformal therapy in anorectal cancer: a Radiation Therapy Oncology Group consensus panel contouring atlas. *Int J Radiat Oncol Biol Phys* 2009; 74: 824–830.
- [32] Pandharipande PV, Mora JT, Uppot RN, et al. Lymphotropic nanoparticle-enhanced MRI for independent prediction of lymph node malignancy: a logistic regression model. *Am J Roentgenol* 2009; 193: W230–W237.
- [33] Froehlich JM, Triantafyllou M, Fleischmann A, Vermathen P, Thalmann GN, Thoeny HC. Does quantification of USPIO uptake-related signal loss allow differentiation of benign and malignant normal-sized pelvic lymph nodes? *Contrast Media Mol Imaging* 2012; 7: 346–355.
- [34] John SS, Zietman AL, Shipley WU, Harisinghani MG. Newer imaging modalities to assist with target localization in the radiation treatment of prostate cancer and possible lymph node metastases. *Int J Radiat Oncol Biol Phys* 2008; 71: S43–S47.
- [35] Myrehaug S, Chan G, Craig T, et al. A treatment planning and acute toxicity comparison of two pelvic nodal volume delineation techniques and delivery comparison of intensity-modulated radiotherapy versus volumetric modulated arc therapy for hypofractionated high-risk prostate cancer radiotherapy. *Int J Radiat Oncol Biol Phys* 2012; 82: e657–e662.
- [36] Sachelarie I, Kerr K, Ghesani M, Blum RH. Integrated PET-CT: Evidence-based review of oncology indications. *Oncology* 2005; 19: 481–490.
- [37] Delbeke D, Martin WH. PET and PET-CT for evaluation of colorectal carcinoma. *Semin Nucl Med* 2004; 34: 209–223.
- [38] Paulino AC, Johnstone PAS. FDG-PET in radiotherapy treatment planning: Pandora's box? *Int J Radiat Oncol Biol Phys* 2004; 59: 4–5.
- [39] Buijsen J, van den Bogaard J, Janssen MH, et al. FDG-PET provides the best correlation with the tumor specimen compared to MRI and CT in rectal cancer. *Radiother Oncol* 2011; 98: 270–276.
- [40] Bassi MC, Turri L, Sacchetti G, et al. FDG-PET/CT imaging for staging and target volume delineation in preoperative conformal radiotherapy of rectal cancer. *Int J Radiat Oncol Biol Phys* 2008; 70: 1423–1426.
- [41] Brændengen M, Hansson K, Radu C, Siegbahn A, Jacobsson H, Glimelius B. Delineation of gross tumor volume (GTV) for radiation treatment planning of locally advanced rectal cancer using information from MRI or FDG-PET/CT: a prospective study. *Int J Radiat Oncol Biol Phys* 2011; 81: e439–e445.
- [42] Chiti A, Kirienko M, Gregoire V. Clinical use of PET-CT data for radiotherapy planning: what are we looking for? *Radiother Oncol* 2010; 96: 277–279.
- [43] Patel DA, Chang ST, Goodman KA, et al. Impact of integrated PET/CT on variability of target volume delineation in rectal cancer. *Technol Cancer Res Treat* 2007; 6: 31–36.
- [44] Krenfli M, Cannillo B, Turri L, et al. Target volume delineation for preoperative radiotherapy of rectal cancer: interobserver variability and potential impact of FDG-PET/CT imaging. *Technol Cancer Res Treat* 2010; 9: 393–398.
- [45] Buijsen J, van den Bogaard J, van der Weide H, et al. FDG-PET-CT reduces the interobserver variability in rectal tumor delineation. *Radiother Oncol* 2012; 102: 371–376.
- [46] Day E, Betler J, Parda D, et al. A region growing method for tumor volume segmentation on PET images for rectal and anal cancer patients. *Med Phys* 2009; 36: 4349–4358.
- [47] Roels S, Slagmolen P, Nuyts J, et al. Biological image-guided radiotherapy in rectal cancer: is there a role for FMISO or FLT, next to FDG? *Acta Oncol* 2008; 47: 1237–1248.
- [48] Purandare NC, Dua SG, Arora A, Shah S, Rangarajan V. Colorectal cancer—patterns of locoregional recurrence and distant metastases as demonstrated by FDG PET/CT. *Indian J Radiol Imaging* 2010; 20: 284–288.