

Received: 2016.12.05  
Accepted: 2017.02.20  
Published: 2017.04.24

ISSN 1941-5923  
© Am J Case Rep, 2017; 18: 444-447  
DOI: 10.12659/AJCR.902708

## Regional Anesthesia Did Not Delay Diagnosis of Compartment Syndrome: A Case Report of Anterior Compartment Syndrome in the Thigh Not Masked by an Adductor Canal Catheter

Authors' Contribution:  
Study Design A  
Data Collection B  
Statistical Analysis C  
Data Interpretation D  
Manuscript Preparation E  
Literature Search F  
Funds Collection G

EF 1 **Arissa Torrie**  
EF 2 **Jyoti Sharma**  
EF 3 **Mark Mason**  
EF 4 **Hillenn Cruz Eng**

1 Department of Internal Medicine, Penn State Health, Hershey, PA, U.S.A.  
2 Department of Orthopedic Surgery, Massachusetts General Hospital, Boston, MA, U.S.A.  
3 Department of Orthopedic Surgery, Penn State Health, Hershey, PA, U.S.A.  
4 Department of Anesthesiology and Perioperative Medicine, Penn State Health, Hershey, PA, U.S.A.

**Corresponding Author:** Hillenn Cruz Eng, e-mail: [hcruzeng@hmc.psu.edu](mailto:hcruzeng@hmc.psu.edu)  
**Conflict of interest:** None declared

**Patient:** Male, 56  
**Final Diagnosis:** Anterior compartment syndrome of the thigh  
**Symptoms:** Unrelenting pain on the anterior aspect of the right thigh  
**Medication:** Morphine • Lyrica • Flexeril • Percocet 5/325 • Hydromorphone • Synthroid • Metformin  
**Clinical Procedure:** Adductor canal catheter placement, emergent fasciotomy  
**Specialty:** Anesthesiology





**Objective:** Unusual clinical course  
**Background:** Acute compartment syndrome (ACS) of the thigh after elective primary total knee arthroplasty is rare. If not recognized and treated promptly, devastating consequences may result. Certain regional anesthesia techniques are thought to mask the symptoms of acute compartment syndrome, but there are no cases reported of adductor canal catheters masking the symptoms of thigh compartment syndrome. We report a case where symptoms and diagnosis of acute anterior thigh compartment syndrome were not masked by a functioning adductor canal catheter.

**Case Report:** A 56-year-old male developed anterior thigh compartment syndrome after an elective primary total knee arthroplasty. Surgery was performed under spinal anesthesia with periarticular local infiltration analgesia. Postoperatively, an adductor canal catheter was placed, atraumatically, under ultrasound guidance in the recovery room with a plan to begin a continuous infusion of 0.2% ropivacaine 10 hours after the periarticular injection. Six hours after surgery, the patient complained of tightness and 10/10 pain in his right thigh, which was initially managed with parenteral opioids with moderate success. Continuous infusion through the adductor canal catheter was started and pain improved to 6/10 aching pain. Nonetheless, two hours after starting the continuous infusion, the patient reported tightness, swelling, and 10/10 pressure-like pain that was not relieved by the peripheral catheter infusion or PRN boluses of additional opioids. Due to the patient's symptomatology compartment pressures were measured. The anterior compartment pressure was 47 mm Hg and emergent anterior compartment fasciotomy was performed.

**Conclusions:** In this case, a functioning adductor canal catheter did not mask symptoms of, or delay diagnosis of, acute compartment syndrome in the thigh.

**MeSH Keywords:** Anterior Compartment Syndrome • Arthroplasty, Replacement, Knee • Nerve Block

Full-text PDF: <http://www.amjcaserep.com/abstract/index/idArt/902708>

 1783   1  24



## Background

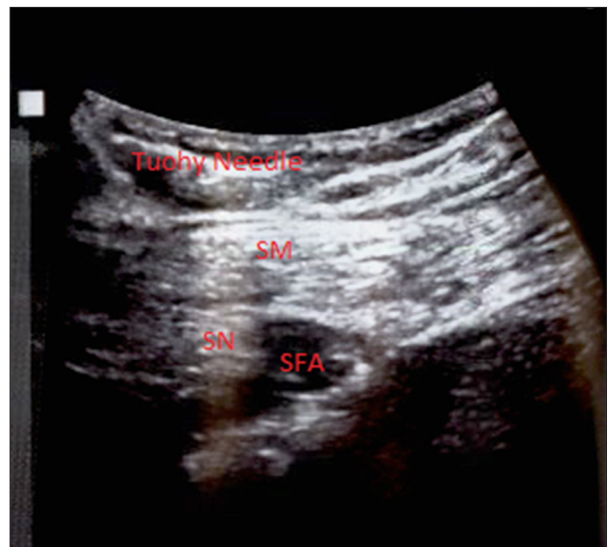Acute anterior compartment syndrome (ACS) of the thigh after elective total knee arthroplasty (TKA) is an uncommon occurrence; however, catastrophic consequences may occur if there is a delay in either diagnosis or treatment [1,2]. Morbidity includes loss of function from muscle damage or excessive scar tissue formation, periprosthetic joint infection related to prolonged open wounds after fasciotomies, and even loss of limb [2]. It is well documented that prompt recognition and immediate surgical decompression are important for good clinical outcomes [1]. It has been suggested that the use of epidural analgesia or peripheral nerve blocks can mask the pain associated with impending ACS resulting in delayed diagnosis [3–5]. However, not all regional techniques are equivalent. To our knowledge, there have been no reported cases of anterior compartment syndrome of the thigh after total knee arthroplasty in which an adductor canal catheter either caused or delayed the diagnosis of the compartment syndrome.

Pain management after TKA has traditionally included parenteral opioids and neuraxial and regional techniques [6]. The use of adductor canal blocks (ACB) for pain management after TKA has increased compared to femoral nerve blocks (FNB) or epidurals [7–9]. As with any new technique, it is important to examine and report adverse outcomes that might be associated with a given technique. In this case report, the patient developed an acute anterior compartment syndrome after a total knee arthroplasty, but the symptoms of compartment syndrome were not masked by the functioning adductor canal catheter.

## Case Report

A 56-year-old Caucasian male with right knee degenerative osteoarthritis presented for elective TKA. He had failed conservative treatment with anti-inflammatory medications and cortisone injections. The patient's past medical history was pertinent for obesity (BMI 45), hypertension, diabetes mellitus type 2, hypothyroidism, non-invasive melanoma, and chronic pain due to chronic left chest wall pain from previous thoracic outlet syndrome surgery, no previous trauma to the affected limb reported. At the time of surgery, the patient was taking extended release morphine 100 mg three times a day (TID), Lyrica 150 mg twice a day (BID), Flexeril 10 mg TID, Percocet 5/325 mg four times a day (QID), and hydromorphone 8 mg QID. Written consent from the patient was obtained to report this case.

The anesthetic plan included spinal anesthesia and postoperative placement of an adductor canal catheter per department protocol. Spinal anesthesia was performed in the operating room with no complications. Local infiltration analgesia



**Figure 1.** Ultrasound image demonstrating placement for the adductor canal catheter, which was placed by the anesthesiologist post-operatively in the recovery room. The Tuohy needle is traversing the sartorius muscle (SM). The superficial femoral artery (SFA) is intact and the saphenous nerve (SF) lies adjacent to the artery.

(LIA) (80 mL ropivacaine 0.5%, 0.3 mL epinephrine (1 mg/mL), 1 mL ketorolac (30 mg/mL), 0.5 mL morphine (10 mg/mL), 38 mL NS) was administered intra and periarticularly by the surgeon during the procedure. No intraoperative surgical complications were noted. Tourniquet time and pressure were 99 minutes and 350 mm Hg, respectively (SBP 102–138 mm Hg, DBP 65–92 mm Hg, mean BP 85 mm Hg). No drains were left in the surgical site. Postoperatively, an adductor canal catheter was placed under ultrasound guidance in the recovery room with a single, atraumatic attempt (Figure 1).

To assess pain, the numeric pain rating scale (NRS) was used. Six hours after surgery, the patient reported 10/10 aching pain along with tightness in his right thigh. He had moderate pain relief 8/10 with scheduled dihydromorphone 8 mg PO every eight hours, 100 mg PO morphine SR and rescue 4 mg IV morphine every one hour. Ten hours after time of LIA injection, a continuous infusion of 0.2% ropivacaine at 8 cc/hour was started. The pain initially improved to 6/10. However, two hours after starting the infusion through the adductor canal catheter, the patient was reevaluated by our Acute Pain Service due to ongoing complaints of unrelenting 10/10 right thigh tightness, swelling, and pressure-like pain. A total volume of 32 cc of ropivacaine 0.2% was infused by the nerve catheter pump.

The pain was localized primarily to the proximal thigh and less so around the actual knee. The right dorsalis pedis pulse was faint and the right thigh and knee was firm to palpation. Given the worsening pain and swelling of the thigh on clinical

examination, compartment pressures of the thigh were measured to assess for acute compartment syndrome. The documented pressures were as follows: anterior compartment 47 mm Hg, adductor compartment 4 mm Hg, and posterior compartment 17 mm Hg. The patient's blood pressure at the time was 118/68 mm Hg with a mean arterial pressure 85 mm Hg. The diagnosis of anterior thigh compartment syndrome was confirmed and the patient was taken back to the operating room within 90 minutes of diagnosis. The adductor canal catheter was removed intraoperative since it was adjacent to the surgical field. When the median parapatellar arthrotomy was reopened a moderate amount of hematoma was observed, but described as not excessive relative to having a TKA performed hours earlier. The fascia was then released proximally to release the anterior compartment of the thigh.

After release of the anterior fascia, the pressure in the thigh decreased substantially. No necrotic muscle was noted and no arterial bleeding was seen. The thigh was copiously irrigated and after careful examination numerous small venous bleeding sites were cauterized. No evidence of muscle damage or bleeding related to the placement of the adductor canal catheter was detected. The only significant hematoma was located within the knee capsule. The arthrotomy was closed over a drain and the incision was closed primarily with no tension observed. The patient was transferred to the PACU in stable condition.

Six hours post-fasciotomy, the patient reported 10/10 pain localized to the proximal. The compartment pressure in the anterior thigh was re-measured and reported initially to be 24 mm Hg, immediate repeat measure was 18 mm Hg. The patient was observed and treated with additional parenteral pain medication, elevation, and ice. The patient's pain slowly improved and he resumed the standard postoperative pathway for TKA patients. The patient was able to participate in physical therapy one day post-fasciotomy and was discharged on hospital day 6. At the three-month follow-up visit, the patient was ambulating unassisted with no reported knee or thigh pain. He had no apparent long-term sequelae from the post-TKA acute thigh compartment syndrome.

## Discussion

Postoperative analgesia, along with a low index of suspicion for ACS, such as after a TKA, can lead to a late recognition of ACS [10]. Prompt diagnosis of ACS is critical in order to avoid irreversible tissue damage leading to muscle necrosis, neurologic deficits, myoglobinuria, limb loss, renal failure, and mortality [1]. Even with prompt recognition and compartment release, additional incisions in the immediate postoperative period and prolonged open wounds can lead to negative sequel [2].

Compartment releases in the setting of a TKA increase infection rates, which can be devastating for patients [11]. Infections render poor outcomes typically requiring additional surgery(s) and prolonged recovery, while increasing medical costs [12]. Stiffness and permanent limb dysfunction can also become an issue with multiple surgeries and multiple incisions [11,12].

Procedures that are at relatively low risk for ACS, such as primary total knee arthroplasty, may pose a risk for late diagnosis of ACS [10]. Our patient was on a chronic opioid pain regimen for long standing pain. His clinical scenario postoperatively could have easily been mistaken for drug seeking behavior or misunderstood given his background of chronic opioid medication use. It is important that medical staff be vigilant in the early postoperative period assessing for ACS. For the narcotic tolerant patient, regional anesthetic techniques are thought to be helpful in the management of acute pain [13]. It is unknown if similar results would have occurred in a narcotic naïve patient.

It is essential when using a regional block that the intensity of the block be appropriate to the anticipated intensity of the post-surgical pain [14]. Continuous epidural analgesia has been documented several times in the literature to mask the pain of ACS [3–5]. However, less is known about adductor canal catheters as it is a rather new analgesic modality. To our knowledge, there are no reports of a delay in diagnosis of ACS being associated with the presence of an adductor canal catheter. In this case, the adductor canal catheter did not mask the symptoms of ACS.

It is unclear what caused the compartment syndrome in this case. Multiple attempts to place regional anesthesia may contribute to ACS development from repeated trauma. In addition, when placing an ACB the proximity of the saphenous nerve to the femoral artery, there is an inherent risk of vascular puncture when advancing the needle tip toward the nerve [15]. However, our patient had one documented attempt at placement of his nerve catheter, and no signs of intramuscular trauma or intramuscular bleeding were noted at the time of compartment release. Increased fluid volume delivered by an indwelling catheter might also cause compartment syndrome. However, in a large volume compartment, such as the thigh, 32 cc of volume infused over four hours would typically not be enough to cause a compartment syndrome.

A tourniquet use can produce an ischemia-reperfusion injury increasing the risk of ACS [16]. Recommendations for tourniquet use vary. Worland recommends a tourniquet time of less than three hours and at a pressure limited to 100 mm Hg above systolic pressure [17]. Klenerman [18] recommends a tourniquet pressure of the thigh to be double that of the systolic pressure in the arm. In this case, the tourniquet time

was well below the three hour limit at 99 minutes. To maintain a dry field in this patient, a tourniquet pressure of 350 mm Hg was necessary. Tourniquet pressures of 350 mm HG in the thigh, when maintained for less than two hours, have not been associated with compartment syndrome [19]. However, since many authors now recommend lower tourniquet pressures, it is possible that the increase tourniquet pressure contributed to the ACS.

Regional anesthetic techniques, such as adductor canal catheters with continuous infusion of local anesthetics are becoming more popular in total knee arthroplasty, and have advantages in this setting. [20,21]. There are a few reported cases of atraumatic anterior compartment syndrome of the thigh [22–24], and although our case also reports anterior thigh compartment syndrome; it has not been described with the presence of a peripheral nerve catheter and a continuous infusion of local

anesthetics. Clinicians must remain vigilant to avoid delayed diagnosis, and the devastating consequences which can follow.

## Conclusions

This case demonstrates that an adductor canal catheter did not mask symptoms of ACS and prompt diagnosis was not delayed by the presence of a functioning peripheral nerve catheter. Use of ACB may be considered as part of a multimodal pain regimen for lower extremity surgeries at risk of ACS.

## Acknowledgements

The authors would like to acknowledge Jessica Boden, MD, for her contribution in the development of this case report.

## References:

1. Haggis P, Yates P, Blakeway C et al: Compartment syndrome following total knee arthroplasty. *J Bone Joint Surg Br*, 2006; 88(3): 331–34
2. Vegari DN, Rangavajjala AV, Diiorio TM, Parvizi J: Fasciotomy following total knee arthroplasty: Beware of terrible outcome. *J Arthroplasty*, 2014; 29(2): 335–39
3. Morrow BC, Mawhinney IN, Elliott JR: Tibial compartment syndrome complicating closed femoral nailing: Diagnosis delayed by an epidural analgesic technique – case report. *J Trauma*, 1994; 37(5): 867–68
4. Strecker WB, Wood MB, Bieber EJ: Compartment syndrome masked by epidural anesthesia for postoperative pain: Report of a case. *J Bone Joint Surg Am*, 1986; 68(9): 1447–4.
5. WM, Chiu KY: Silent compartment syndrome complicating total knee arthroplasty: Continuous epidural anesthesia masked the pain. *J Arthroplasty*, 2000; 15: 241–43
6. Silvasti M, Pitkänen M: Patient-controlled epidural analgesia versus continuous epidural analgesia after total knee arthroplasty. *Acta Anaesthesiol Scand*, 2001; 45(4): 471–76
7. Jenstrup M.T, Jaeger P, Lund J et al: Effects of adductor-canal blockade on pain and ambulation after total knee arthroplasty: A randomized study. *Acta Anaesthesiol Scand*, 2012; 56(3): 357–64
8. Karnawat R. Monika G, Suthar OP: Adductor canal block for post-operative pain relief in knee surgeries: A review article. *J Anesth Clin Res*, 2015; 6(10): 1–4
9. Grevstad U, Mathiesen O, Valentiner LS: Effect of adductor canal block versus femoral nerve block on quadriceps strength, mobilization, and pain after total knee arthroplasty: A randomized, blinded study. *Reg Anesth Pain Med*, 2015; 40(1): 3–10
10. Boonstra RH, Haverkamp D, Campo MM, van der Vis HM: Acute compartment syndrome of the thigh following total knee arthroplasty. *Knee*, 2012; 19(2): 151–53
11. Dover M, Memon AR, Marafi H et al: Factors associated with persistent sequelae after fasciotomy for acute compartment syndrome. *J Ortho Surg*, 2012; 20(3): 312–15
12. Fitzgerald AM, Gaston P, Wilson Y et al: Long-term sequelae of fasciotomy wounds. *Br J Plast Surg*, 2000; 53(8): 690–93
13. Wenzel JT, Schwenk ES, Baratta JL: Managing opioid-tolerant patients in the perioperative surgical home. *Anesthesiol Clin*, 2016; 34(2): 287–301
14. Mar GJ, Barrington MJ, McGuirk BR: Acute compartment syndrome of the lower limb and the effect of postoperative analgesia on diagnosis. *Br J Anesth*, 2009; 102(1): 3–11
15. Burckett-St Laurent D, Peng P et al: The nerves of the adductor canal and the innervation of the knee: An anatomic study. *Reg Anesth Pain Med*, 2016; 41(3): 321–27
16. Olivecrona C, Lapidus LJ, Benson L, Blomfeldt R: Tourniquet time affects postoperative complications after knee arthroplasty. *Int Orthop*, 2013; 37(5): 827–32
17. Worland RL, Arredondo J, Angles F et al: Thigh pain following tourniquet application in simultaneous bilateral total knee replacement arthroplasty. *J Arthroplasty*, 1997; 12(8): 848–52
18. Klenerman L, Biswas M, Hulands GH, Rhodes AM: Systemic and local effects of the application of a tourniquet. *J Bone Joint Surg Br*, 1980; 62(3): 385–88
19. Wheelless CR: TKR: Patient Positioning, Prepping and Draping. In: *Wheelless' Textbook of Orthopaedics*, 2016. Retrieved from [http://www.wheellessonline.com/ortho/extremity\\_tourniquets](http://www.wheellessonline.com/ortho/extremity_tourniquets)
20. Hanson NA, Allen CJ, Hostetter LS: Continuous ultrasound-guided adductor canal block for total knee arthroplasty: A randomized, double-blind trial. *Anesth Analg*, 2014; 118(6): 1370–77
21. Hanson NA, Lee PH, Yuan SC: Continuous ambulatory adductor canal catheters for patients undergoing knee arthroplasty surgery. *J Clin Anesth*, 2016; 35: 190–94
22. Gutfraynd A, Philpott S: A case of acute atraumatic compartment syndrome of the thigh. *J Emerg Med*, 2016; 51(3): 45–47
23. McDonald L, Mitchell R, Deaton T: Bilateral compartment syndrome of the anterior thigh following functional fitness exercises. *Mil Med*, 2012; 177: 993–96
24. Dahab R, Barret C, Pillar R, De Matas M: Anterior thigh compartment syndrome after prone positioning for lumbosacral fixation. *Eur Spine J*, 2012; 32: 554–56