

Arthroscopic Management of Osteochondral Lesion of Plantar Medial Talar Head



Tun Hing Lui, M.B.B.S. (H.K.), F.R.C.S. (Edin.), F.H.K.A.M., F.H.K.C.O.S., and Chun Lok Chow, M.B.Ch.B., M.R.C.S.Ed.

Abstract: Osteochondral lesions of the talar head can be classified into 4 types: type 1 is located at the anterior part of the talar head, type 2 is at the plantar side of the talar head, type 3 is at the plantar lateral side of the talar head, and type 4 is at the plantar medial aspect of the talar head. The purpose of this Technical Note is to describe the details of arthroscopic management of an osteochondral lesion of the plantar medial talar head. It includes arthroscopic synovectomy of the medial recess of the anterior subtalar joint, debridement, and microfracture of the osteochondral lesion.

The osteochondral lesion of the talar head is a rare condition.¹⁻⁷ The etiology of an osteochondral lesion of the talar head remains controversial. Trauma might play a role, either acute supination injury or chronically from repetitive injury.^{2,3} However, this may not be the only etiologic factor because no trauma history can be identified in some cases.^{1,2} Osteochondral lesions of the talar head can be classified according to its location in the talar head. A type 1 lesion is located at the anterior part of the talar head.² A type 2 lesion is at the plantar side of the talar head,³ resulting from talocuboid and/or talocalcaneal impaction from a supination injury of the foot and ankle. The lesion is strongly associated with injury of the osseous and ligamentous structures of the transverse tarsal joint complex including the plantar components of the spring ligament, extensor digitorum brevis muscle, anterior process of the calcaneus, and cuboid.³ A type 3 lesion is at plantar lateral side of the

talar head.⁸⁻¹³ It can be caused by impingement by a “too long” anterior process of the calcaneus or nonunion of the anterior calcaneal process.⁸⁻¹³ A type 4 lesion is at the plantar medial aspect of the talar head.

Symptomatic osteochondral lesions require debridement of the lesion with or without drilling or microfracture of the subchondral bone if conservative treatment fails to relieve the symptoms. Causative or concomitant pathology should also be treated. The “too long” anterior process⁸⁻¹² or nonunion of anterior calcaneal process¹³ that is impinging on the type 3 lesion should be resected. The spring ligament may need to be repaired in a type 2 lesion.³ This anatomic classification provides guidance for the choice of an appropriate arthroscopic approach. Talonavicular arthroscopy is used to access the type 1 lesion.^{14,15} A type 2 lesion requires combined anterior subtalar arthroscopy^{16,17} and medial subtalar arthroscopy.^{18,19} In case of an associated torn superomedial spring ligament, the lesion can also be approached via the posterior tibial tendoscopy.²⁰ A type 3 lesion is

From the Department of Orthopaedics and Traumatology, North District Hospital, Sheung Shui, NT, Hong Kong SAR, People's Republic of China.

The authors report that they have no conflicts of interest in the authorship and publication of this article. Full ICMJE author disclosure forms are available for this article online, as [supplementary material](#).

Received August 4, 2018; accepted September 12, 2018.

Address correspondence to Tun Hing Lui, M.B.B.S. (H.K.), F.R.C.S. (Edin.), F.H.K.A.M., F.H.K.C.O.S., Department of Orthopaedics and Traumatology, North District Hospital, 9 Po Kin Rd, Sheung Shui, NT, Hong Kong SAR, People's Republic of China E-mail: luithderek@yahoo.co.uk

© 2018 by the Arthroscopy Association of North America. Published by Elsevier. This is an open access article under the CC BY-NC-ND license (<http://creativecommons.org/licenses/by-nc-nd/4.0/>).

2212-6287/18971

<https://doi.org/10.1016/j.eats.2018.09.001>

Table 1. Indication and Contraindications of Arthroscopic Management of Osteochondral Lesions of the Plantar Medial Talar Head

Indication	Contraindications
A symptomatic osteochondral lesion at the plantar medial side of the talar head that is recalcitrant to conservative treatment	Active infection at the expected portal sites
	Other causes of the medial heel pain, such as posterior tibial tendon deficiency

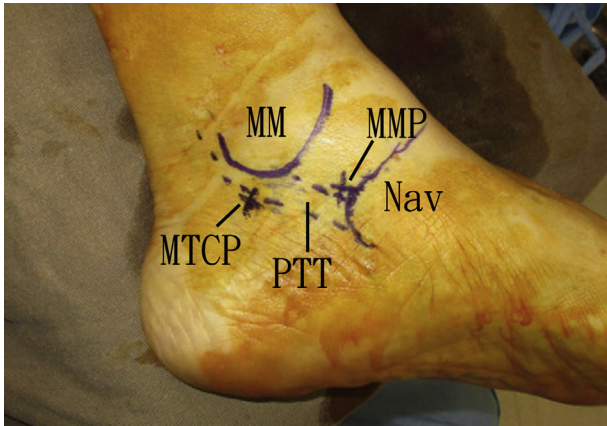


Fig 1. Arthroscopic management of an osteochondral lesion of the plantar medial talar head of the left foot. The patient is in the supine position with legs spread. The medial malleolus (MM), posterior tibial tendon (PTT), and navicular bone (Nav) are outlined. The medial midtarsal portal (MMP) is located at the medial corner of the talonavicular joint, just above the insertion of the posterior tibial tendon. The medial tarsal canal portal (MTCP) is just posterior to the tibialis posterior tendon and just above the level of the sustentaculum tali.

approached via calcaneocuboid arthroscopy or anterior subtalar arthroscopy.¹⁰⁻¹³ A type 4 lesion is approached via medial subtalar arthroscopy.^{18,19} This report describes the technical details of arthroscopic management of the osteochondral lesion of the plantar medial talar head, which includes arthroscopic synovectomy, debridement, and microfracture of the osteochondral lesion. It is indicated for a symptomatic osteochondral lesion at the plantar medial side of the talar head that is recalcitrant to conservative treatment. This procedure is contraindicated if there is active infection at the expected portal sites or if there

are other causes of medial heel pain, such as posterior tibial tendon deficiency (Table 1).

Technique

Preoperative Planning and Patient Positioning

The location of pain and a tender spot at the plantar medial aspect of the talar head is the most important clinical finding. Preoperative radiographs are useful for exclusion of post-traumatic degeneration of the talocalcaneonavicular joint. Preoperative magnetic resonance imaging (MRI) may show the osteochondral lesion. Talocalcaneonavicular joint effusion may be suggestive of talar head impaction.²¹ More importantly, MRI may be needed to exclude other causes of medial heel pain, such as posterior tibial tendon deficiency.

The patient is in the supine position with legs spread. A thigh tourniquet is applied to provide a bloodless operative field. The medial malleolus, tibialis posterior tendon, and navicular are outlined. The medial midtarsal portals and the medial tarsal canal portal are marked. A 2.7-mm 30° arthroscope (Henke-Sass Wolf GmbH, Tuttlingen, Germany) is used for this procedure.

Portal Placement

This procedure is performed via the medial midtarsal portal and the medial tarsal canal portal.^{18,19} The medial midtarsal portal is located at the medial corner of the talonavicular joint, just above the insertion of the tibialis posterior tendon. The medial tarsal canal portal is just posterior to the tibialis posterior tendon and just above the level of the sustentaculum tali. This portal is at the medial end of the tarsal canal (Fig 1).

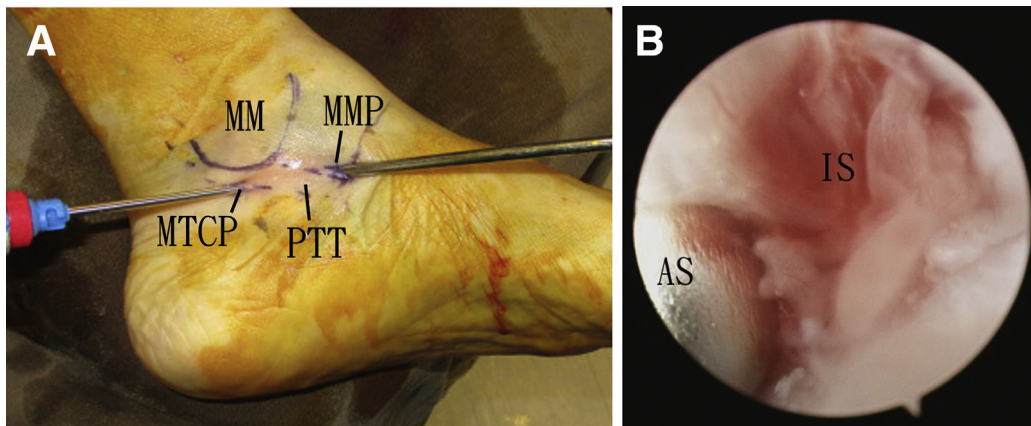


Fig 2. Arthroscopic management of an osteochondral lesion of the plantar medial talar head of the left foot. The patient is in the supine position with legs spread. (A) Medial subtalar arthroscopy is performed with the medial midtarsal portal as the viewing portal and the medial tarsal canal portal as the working portal. (B) The inflamed synovium at the medial recess of the anterior subtalar joint is resected with an arthroscopic shaver. (AS, arthroscopic shaver; IS, inflamed synovium; MM, medial malleolus; MMP, medial midtarsal portal; MTCP, medial tarsal canal portal; PTT, posterior tibial tendon.)

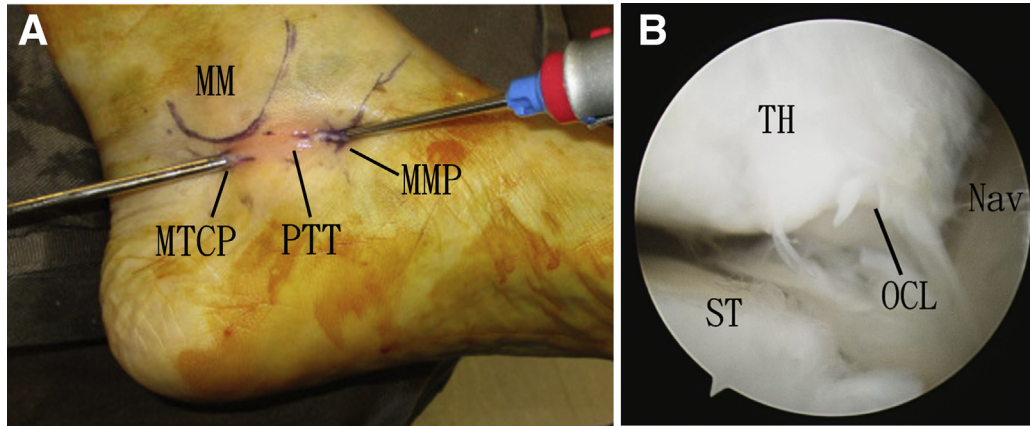


Fig 3. Arthroscopic management of an osteochondral lesion of the plantar medial talar head of the left foot. The patient is in the supine position with legs spread. (A) Medial subtalar arthroscopy is performed with the medial tarsal canal portal as the viewing portal and the medial midtarsal portal as the working portal. (B) The osteochondral lesion is identified at the plantar medial side of the talar head. (MM, medial malleolus; MMP, medial midtarsal portal; MTCP, medial tarsal canal portal; Nav, navicular bone; OCL, osteochondral lesion; PTT, posterior tibial tendon; ST, sustentaculum tali; TH, talar head.)

Arthroscopic Synovectomy of the Medial Recess of the Anterior Subtalar Joint

Medial subtalar arthroscopy is performed with the medial midtarsal portal as the viewing portal. The inflamed synovium at the medial recess of the anterior subtalar joint is resected with an arthroscopic shaver (Dyonics; Smith & Nephew, Andover, MA) via the medial tarsal canal portal (Fig 2). The portals can be

switched as the viewing and working portals to have complete synovectomy of the medial recess. After clearance of the medial recess, the medial joint line of the anterior subtalar joint can be seen.

Arthroscopic Debridement of an Osteochondral Lesion of the Plantar Medial Talar Head

The medial tarsal canal portal is the viewing portal. The medial side of the talocalcaneonavicular joint is examined. The osteochondral lesion is identified at the plantar medial side of the talar head (Fig 3). The hindfoot is everted to expose the most plantar part of the osteochondral lesion. The lesion is debrided with an arthroscopic shaver via the medial midtarsal portal. All fibrillated cartilage and unstable cartilaginous flaps are resected, and the subchondral bone is exposed.

Microfracture of an Osteochondral Lesion of the Plantar Medial Talar Head

The medial tarsal canal portal is the viewing portal. Microfracture of the subchondral bone of the osteochondral lesion is performed with an arthroscopic awl

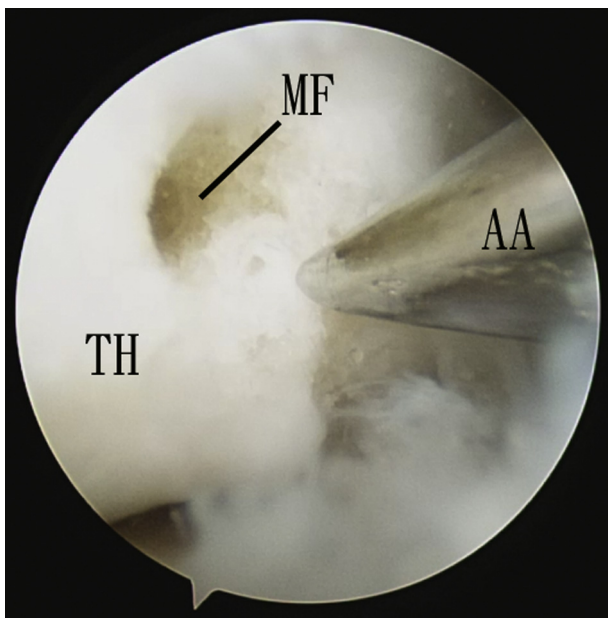


Fig 4. Arthroscopic management of an osteochondral lesion of the plantar medial talar head of the left foot. The patient is in the supine position with legs spread. The medial tarsal canal portal is the viewing portal, and the medial midtarsal portal is the working portal. Microfracture of the lesion is performed with an arthroscopic awl. (AA, arthroscopic awl; MF, microfracture hole; TH, talar head.)

Table 2. Pearls and Pitfalls of Arthroscopic Management of Osteochondral Lesions of the Plantar Medial Talar Head

Pearls	Pitfalls
The medial recess of the anterior subtalar joint is deep to the tibialis posterior. The arthroscope and arthroscopic instrument should go deep to the tendon before they can be slid into the medial recess.	Too posterior placement of the medial tarsal canal portal can injure the tibial neurovascular bundle.
The plantar portion of the osteochondral lesion is exposed by hindfoot eversion.	Failure of debridement of the most plantar part of the osteochondral lesion may result in residual pain.

Table 3. Advantages and Risks of Arthroscopic Management of Osteochondral Lesions of the Plantar Medial Talar Head

Advantages	Risks
Better cosmetic result	Injury to the cartilage of the talar head
Less pain	Injury to the tibialis posterior tendon
Less surgical trauma	Injury to the saphenous nerve Injury to the tibial nerve

(Acufex; Smith & Nephew) via the medial midtarsal portal (Fig 4, Table 2, Video 1).

Discussion

In our experience, the osteochondral lesion can be caused by inversion injury of the hindfoot. The axis of hindfoot inversion/eversion passes through the center of the talar head and bisects the posterior calcaneal facet. During inversion injury, there is distraction injury of the lateral ligamentous structures of the anterior and posterior subtalar joint including the sinus tarsi. However, the osteoarticular structures medial to the axis face the compression injury. Therefore, the medial heel pain owing to an osteochondral lesion of the plantar medial talar head can be accompanied by lateral heel pain owing to sinus tarsi syndrome. Posterior subtalar arthroscopy may also be needed to deal with the sinus tarsi syndrome.

Arthroscopic management of an osteochondral lesion of the plantar medial talar head has the advantages of better cosmetic results, less pain, and less surgical trauma. The potential risks of this technique include injury to the cartilage of the talar head, tibialis posterior tendon, saphenous nerve, and tibial nerve. This technique is technically demanding and should be reserved for experienced foot and ankle arthroscopists (Table 3).

References

- Turati M, Glard Y, Afonso D, Griffet J, Bigoni M. Osteochondral alteration in a child treated with levetiracetam: A rare case of juvenile osteochondritis dissecans of the talar head. *J Pediatr Orthop B* 2017;26:189-192.
- Corominas L, Sanpera I Jr, Masrouha K, Sanpera-Iglesias J. Retrograde percutaneous drilling for osteochondritis dissecans of the head of the talus: Case report and review of the literature. *J Foot Ankle Surg* 2016;55:328-332.
- Gorbachova T, Wang PS, Hu B, Horrow JC. Plantar talar head contusions and osteochondral fractures: Associated findings on ankle MRI and proposed mechanism of injury. *Skeletal Radiol* 2016;45:795-803.
- Dolan AM, Mulcahy DM, Stephens MM. Osteochondritis dissecans of the head of the talus. *Foot Ankle Int* 1997;18:365-368.
- Honle W, Schuh A. Osteochondritis dissecans of the head of the talus: A case report. *Zentralbl Chir* 2007;132:465-467.
- Thacker MM, Dabney KW, Mackenzie WG. Osteochondritis dissecans of the talar head: Natural history and review of literature. *J Pediatr Orthop B* 2012;21:373-376.
- Shepard G. Osteochondritis dissecans of the head of talus: An unusual cause of limping in child. *Foot* 2004;8:51-52.
- Pouliquen JC, Duranthon LD, Glorion CH, Kassis B, Langlais J. The too-long anterior process calcaneus: A report of 39 cases in 25 children and adolescents. *J Pediatr Orthop* 1998;18:333-336.
- el Hayek T, D'Ollone T, Rubio A, Lusakisimo S, Griffet J. A too-long anterior process of the calcaneus: A report of 31 operated cases. *J Pediatr Orthop B* 2009;18:163-166.
- Lui TH. Arthroscopic resection of the calcaneonavicular coalition or the "too long" anterior process of the calcaneus. *Arthroscopy* 2006;22:903.e1-903.e4.
- Bauer T, Golano P, Hardy P. Endoscopic resection of a calcaneonavicular coalition. *Knee Surg Sports Traumatol Arthrosc* 2010;18:669-672.
- Lui TH. Arthroscopic resection of too-long anterior process of the calcaneus. *Arthrosc Tech* 2016;5:e1179-e1183.
- Lui TH. Endoscopic excision of symptomatic nonunion of anterior calcaneal process. *J Foot Ankle Surg* 2011;50:476-479.
- Lui TH, Chan LK. Safety and efficacy of talonavicular arthroscopy in arthroscopic triple arthrodesis. A cadaveric study. *Knee Surg Sports Traumatol Arthrosc* 2010;18:607-611.
- Lui TH. New technique of arthroscopic triple arthrodesis. *Arthroscopy* 2006;22:464.e1-464.e5.
- Lui TH, Chan KB, Chan LK. Portal safety and efficacy of anterior subtalar arthroscopy: A cadaveric study. *Knee Surg Sports Traumatol Arthrosc* 2010;18:233-237.
- Lui TH. Clinical tips: Anterior subtalar (talocalcaneonavicular) arthroscopy. *Foot Ankle Int* 2008;29:94-96.
- Lui TH, Chan LK, Chan KB. Medial subtalar arthroscopy: A cadaveric study of the tarsal canal portal. *Knee Surg Sports Traumatol Arthrosc* 2013;21:1279-1282.
- Lui TH. Medial subtalar arthroscopy. *Foot Ankle Int* 2012;33:1018-1023.
- Lui TH. Endoscopic repair of the superficial deltoid ligament and spring ligament. *Arthrosc Tech* 2016;5:e621-e625.
- Desai KR, Beltran LS, Bencardino JT, Rosenberg ZS, Petchprapa C, Steiner G. The spring ligament recess of the talocalcaneonavicular joint: Depiction on MR images with cadaveric and histologic correlation. *AJR Am J Roentgenol* 2011;196:1145-1150.