






A rare complication after coronary bypass surgery: Incisional pyoderma gangrenosum

 Mehmet Erdem Memetoglu,  Abdulkirim Ozhan,  Mehmet Yilmaz,  Tamer Kehlibar,  Bulend Ketenci

Department of Cardiovascular Surgery, Dr. Siyami Ersek Thoracic and Cardiovascular Surgery Training and Research Hospital, Istanbul, Turkey

ABSTRACT

Pyoderma gangrenosum (PG) is a non-infectious, necrotizing, destructive skin disease which is rarely seen after cardiac surgery. This report presents a PG case after coronary bypass surgery.

Keywords: Coronary artery bypass; pyoderma gangrenosum; wound healing.

Cite this article as: Memetoglu ME, Ozhan A, Yilmaz M, Kehlibar T, Ketenci B. A rare complication after coronary bypass surgery: Incisional pyoderma gangrenosum. *North Clin Istanbul* 2021;8(4):395–397.

Pyoderma gangrenosum (PG) is a destructive, necrotizing, non-infectious, and ulcerating skin disease, which can usually be seen in adults. Immunity disorders, systemic diseases, malignancies, and genetic predisposition are held responsible in the etiology. PG may occur after trauma and surgery. Although it can be seen in all parts of the body, it especially affects the extremities [1]. The lesions are painful ulcers, blisters, pustules or vegetation, and are histologically characterized by neutrophil accumulation. Even though there is no definitive treatment, immune suppressive drugs such as topical and systemic corticosteroids, cyclosporine, and methotrexate are used in the treatment of PG [2].

CASE REPORT

A 75-year-old male patient underwent coronary artery bypass surgery with the diagnosis of coronary artery disease. He had a history of chemotherapy for prostate cancer 10 years ago and no known systemic disease. The post-operative course in the intensive care unit was stable and free of events. On the 2nd post-operative day, pro-

gressive and erythematous puffy ulcerative lesions with serous discharge and irregular borders were detected on the sites of sternotomy and saphenous incisions (Fig. 1). Granulation tissue and chronic inflammatory response were seen on the pathological evaluation of the specimens which were taken from the lesions (Fig. 2).

The patient's body temperature was normal. Laboratory tests revealed that hemoglobin 9.0 g/dL, platelet count 200.000/mm³, and CRP 16 mg/dL. Neither debridement nor surgical intervention was applied to the lesions.

There was no proliferation of the microorganism in the wound and blood cultures. The patient was examined in the dermatology clinic and the diagnosis of the PG was confirmed. Prophylactic antibiotic therapy (cephamezine 3 × 1000 mg) was stopped. Daily wet wound dressings were applied with steroid containing topical ointment (Dermovate®). The clinical improvement on the lesions was noticed on the 5th day of the follow-up and the treatment was continued. On the 20th day of the treatment, the inflammatory appearance such as skin necrosis, erythema, and serous discharge of the wounds recovered (Fig. 3). Informed consent was obtained from the patient.

Received: February 14, 2020 *Accepted:* May 15, 2020 *Online:* August 05, 2021



Correspondence: Abdulkirim OZHAN, MD. Dr. Siyami Ersek Gogus Kalp ve Damar Cerrahisi Egitim ve Arastirma Hastanesi, Kalp Damar Cerrahisi Klinigi, Istanbul, Türkiye.

Tel: +90 545 221 69 96 e-mail: draozhan@gmail.com

© Copyright 2021 by Istanbul Provincial Directorate of Health - Available online at www.northclinist.com

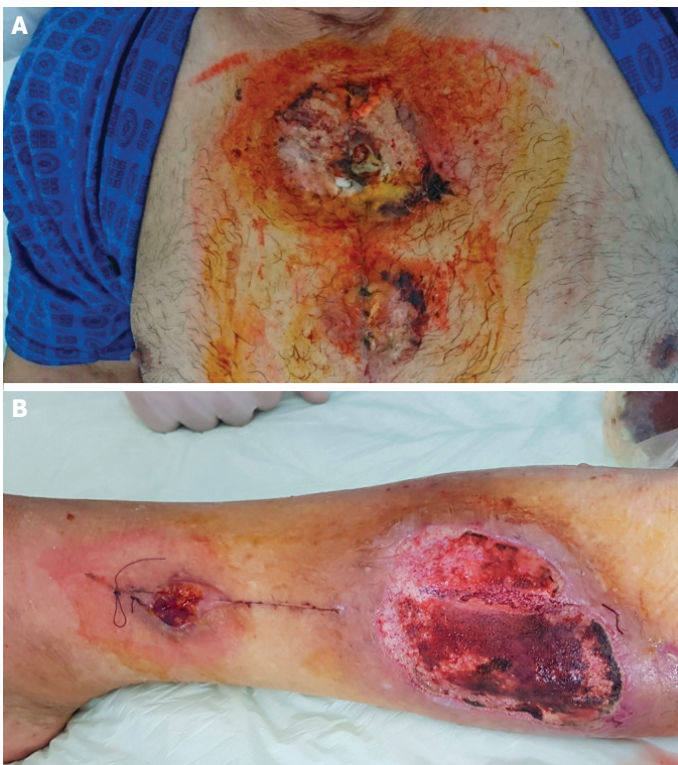


FIGURE 1. Appearance of the wounds on the 2nd post-operative day. **(A)** Sternal incision. **(B)** Saphenous incision.

DISCUSSION

PG is characterized by rapidly progressive and painful necrotic ulcers which involves all layers of the skin, usually on the extremities [3]. There are four subtypes of PG; ulcerative, pustular, bullous, and vegetative. Pustular PG is usually associated with inflammatory bowel disease, while bullous PG often coappears with hematological disorders and is located on the upper extremities and face. Other variants of the PG were also identified, such as malignant pyoderma, vesiculopustular, peristomal, and extracutaneous variants [4]. The lesions in our patient were defined as ulcerative PG in accordance with the appearance of the lesions and the pathological evaluation.

Approximately half of the PG cases are accompanied by a systemic disease. The most common of these diseases are; inflammatory bowel diseases such as ulcerative colitis, hematological malignancies, rheumatic diseases, malignancies, and monoclonal gammopathies [5]. In our case, lesions were observed after coronary artery bypass surgery and the patient had a history of surgery for malignancy.

Approximately one-fifth of patients with PG have positive pathergy test. Abnormal cytokine release such as interleukin (IL)-8, IL-1 β , IL6, tumor necrosis factor- β ,

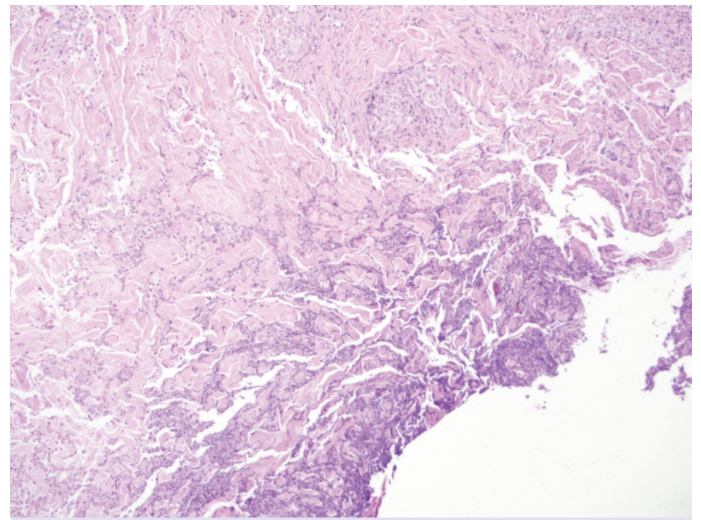


FIGURE 2. Necrosis in the superficial layer, infiltration of the dermis with interstitial lymphocytes, plasmocytes and neutrophils, and intradermal abscess formation (20 \times 10, hematoxylin and eosin staining).

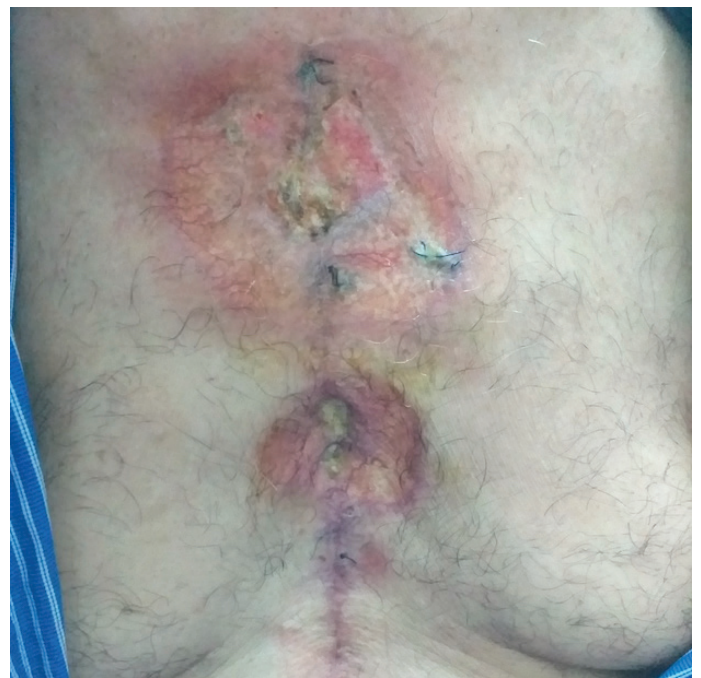

FIGURE 3. Recovery of the sternal wound on the 20th day of the treatment.

granulocyte colony-stimulating factor, matrix metalloproteinase (MMP)-9, MMP-10, and pathergy reaction is thought to be responsible for PG [6].

The lesion begins as a necrotic area and may rapidly progress into an ulcerative lesion. There is usually erythematous and purple appearance around the ulcer [6].

PG treatment should be done according to the location, number, and severity of the lesions and also with consideration of the underlying disease. The reduction in the diameter of the lesion and the absence of new lesions are indicative of response to treatment. Although there is no specific treatment, the initial treatment are corticosteroids. Cyclosporine, thalidomide, and azathioprine can be used as steroid rescue agents in patients with extensive lesions [2].

Although post-operative incisional PG has been reported in the literature mostly after abdominal and thoracic surgery, it may be seen after any invasive procedure including percutaneous interventions [7]. PG has been rarely reported after coronary artery bypass surgery in the literature; but a fatal case of PG which occurred in the sternal and saphenous incisions after coronary artery bypass surgery shows the importance and severity of the disease [8].

Wound debridement should be avoided in case of incisional PG. We think that PG should be considered in the lesions which are rapidly progressive and resistant to antibiotic treatment.

Informed Consent: Written informed consent was obtained from the patient for the publication of the case report and the accompanying images.

Conflict of Interest: No conflict of interest was declared by the authors.

Financial Disclosure: The authors declared that this study has received no financial support.

Authorship Contributions: Concept – BK, MEM, AO; Design – MY, MEM, TK; Supervision – BK, MEM; Fundings – BK, AO; Materials – MEM, AO; Data collection and/or processing – MEM, AO; Analysis and/or interpretation – MEM, TK; Literature review – MY, MEM; Writing – MEM, AO; Critical review – BK, MEM, MY, TK.

REFERENCES

1. Shen J, Zhang W, Jiang X. Pyoderma gangrenosum after cesarean section treated with skin graft: A case report. *Medicine (Baltimore)* 2019;98:e15380.
2. Kleinfelder RE, Hin N, Cubelli S, Snyder A, Kerdel F, Glick B. Multiple facial lesions of recalcitrant pyoderma gangrenosum successfully treated with adalimumab. *J Clin Aesthet Dermatol* 2019;12:28–32.
3. Osaka A, Ide H, Ban S, Takimoto T, Aoki K, Kobori Y, et al. Pyoderma gangrenosum after radical prostatectomy: case report. *Int Cancer Conf J* 2018;7:114–6.
4. Ruocco E, Sangiuliano S, Gravina AG, Miranda A, Nicoletti G. Pyoderma gangrenosum: an updated review. *J Eur Acad Dermatol Venereol* 2009;23:1008–17.
5. Wang JY, French LE, Shear NH, Amiri A, Alavi A. Drug-induced pyoderma gangrenosum: a review. *Am J Clin Dermatol* 2018;19:67–77.
6. Goodarzi H, Sivamani RK, Garcia MS, Wehrli LN, Craven H, Ono Y, et al. Effective strategies for the management of pyoderma gangrenosum. *Adv Wound Care (New Rochelle)* 2012;1:194–9.
7. Gooding JM, Kinney TB, Oglevie SB, Wang-Rodriguez J. Pyoderma gangrenosum twice complicating percutaneous intervention in a single patient. *AJR Am J Roentgenol* 1999;172:1352–4.
8. Bryan CS. Fatal pyoderma gangrenosum with pathergy after coronary artery bypass grafting. *Tex Heart Inst J* 2012;39:894–7.