

CASE REPORT

Heterotaxy syndrome with complex congenital heart disease, facial palsy, and asplenia: A rare newborn finding

Sanjeev Kharel¹  | Dinesh Prasad Koirala² | Suraj Shrestha¹  | Hari Sedai¹ |
Bibek Man Shrestha¹ | Sushan Homagain¹ | Suraj Kandel¹

¹Institute of Medicine, Maharajgunj Medical Campus, Kathmandu, Nepal

²Department of Gastrointestinal and General Surgery, Pediatric Surgery Unit, Tribhuvan University, Teaching Hospital, Kathmandu, Nepal

Correspondence

Dinesh Prasad Koirala, Department of Gastrointestinal and General Surgery, Pediatric Surgery Unit, Tribhuvan University, Teaching Hospital, Kathmandu, Nepal.
Email: dpk61@icloud.com

Funding information

None

Abstract

Heterotaxy syndrome is associated with asplenia/polysplenia and complex congenital heart disease. Facial palsy in heterotaxy is very rare. The management is still challenging with a poor prognosis. Proper counseling to the family about the disease course, treatment modalities, and outcomes is essential.

KEYWORDS

asplenia, complex congenital heart disease, heterotaxy, situs ambiguous

1 | INTRODUCTION

Heterotaxy syndrome (HS) or situs ambiguous refers to an abnormal arrangement of thoracoabdominal organs caused by disruption of left-right axis orientation during early embryonic development, wherein the organs are not a partial or complete mirror image but in different locations.^{1,2} Right-sided isomerism with asplenia, a subtype of HS, is associated with more severe congenital heart disease and thus higher morbidity and mortality despite advances in surgery.³⁻⁵ The incidence of congenital facial nerve palsy is about two in 1000 live births likely resolving by 3–6 months of age.⁶ Herein, we report a rare case of a newborn with features of heterotaxy with facial palsy and complex congenital heart diseases.

2 | CASE PRESENTATION

A term newborn (born at 38+4 weeks of gestation) in his second day of life born to a 27-year female with a normal

vaginal delivery was brought to our emergency department with the complaint of multiple episodes of sudden bilious vomiting following the initiation of breastfeeding along with frothing from the mouth without other complaints. The patient was thus kept nil per oral and IV fluids with the suspicion of a tracheoesophageal fistula at another center.

On arrival in our emergency, he was afebrile with a heart rate of 138 beats/min, respiratory rate 56 times/min, and oxygen saturation of 96% in room air with all other vitals stable including normal passage of urine and stools. On physical examination, the child was active; however, his face was deviated to the left side with a lack of movement of forehead, cheek, and corner of mouth and had a high arch palate, which increased during crying episodes. Icterus was observed up to the trunk and upper limb, and no other gross abnormality on the head-to-toe examination was detected. A holosystolic murmur was heard on cardiovascular examination, and examinations of other systems were normal.

This is an open access article under the terms of the Creative Commons Attribution-NonCommercial-NoDerivs License, which permits use and distribution in any medium, provided the original work is properly cited, the use is non-commercial and no modifications or adaptations are made.

© 2021 The Authors. *Clinical Case Reports* published by John Wiley & Sons Ltd.

The boy had cried immediately after birth with an Apgar score of 8/10 and 9/10 at 1 min and 5 min, respectively, without any need of resuscitation. During the observation, facial deviation to the left side was observed for which the patient was kept for further evaluation and management in the neonatal intensive care unit (NICU). Birth weight and head circumference were normal. The child was breastfed after 1 h of life when the symptoms began. The mother had a history of spontaneous first-trimester abortion. In the recent pregnancy, mother was in normal health during the first trimester, with no history of illicit/teratogenic drug intake, smoking, alcohol, and no fever, rashes, or any other illness in the first trimester. The rest of her pregnancy was also uneventful. All the prenatal and necessary examinations but anomaly scan were performed as per required and was reported to be normal during her ANC checkups.

Blood investigations revealed hyponatremia (127 mEq/L [135–146 mEq/L]), hyperbilirubinemia [Total bilirubin-15.54 mg/dl], increased aminotransferase (AST/SGOT-70 U/L [<37 U/L]) and leukocytosis (WBC-13,900/mm³) with all other parameters within normal range.

X-ray of the chest and abdomen showed an Orogastric (OG) tube on the right side. (Figure 1) Echocardiography was done on the first day of life (DOL) revealed a complex congenital heart disease with ventricular inversion, complete atrioventricular septal defect (unbalanced type, RV dominant), double outlet right ventricle, malposition of great arteries, mild pulmonary stenosis, and possible partial anomalous pulmonary vein connection of left-sided pulmonary veins along with a small patent ductus arteriosus. (Figure 2) Neurosonogram was normal. Ultrasonography of abdomen/pelvis on 4th DOL showed a midline liver with

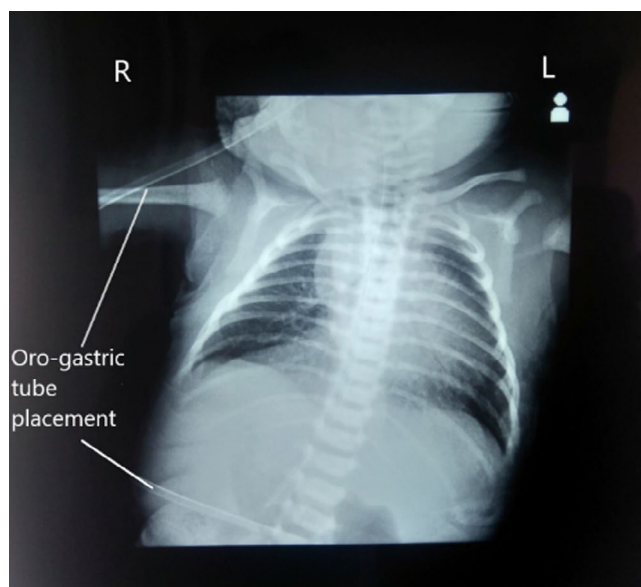


FIGURE 1 Chest and abdomen X-ray PA view showing OG tube in right side

normal echogenicity, right-sided stomach with no spleen and cardiac apex on the left side, and all other organs in normal position. Further gastrograffin follow through confirmed the findings of the right-sided stomach with the left-sided ileocecal junction. (Figure 3) All these findings were suggestive of Heterotaxy syndrome with complex congenital heart disease.

The baby received double phototherapy during the hospital stay for hyperbilirubinemia. The oral feed was increased gradually (5 ml OG feeding 2 hourly) with tapering of intravenous fluid along with antiemetics support. After admission, two spikes of fever (Tmax-102F) were observed owing to *Klebsiella pneumoniae*, resistant to amoxicillin/Ampicillin which subsided with IV Ciprofloxacin/Amikacin. The mother was counseled well about the baby's condition and all the possible best alternatives for the treatment of the baby. The baby had gradually increased oral feed and tolerated well at the time of writing the report. The patient was discharged after 11 days of admission with the consultation with a pediatric surgeon and is on regular follow-up.

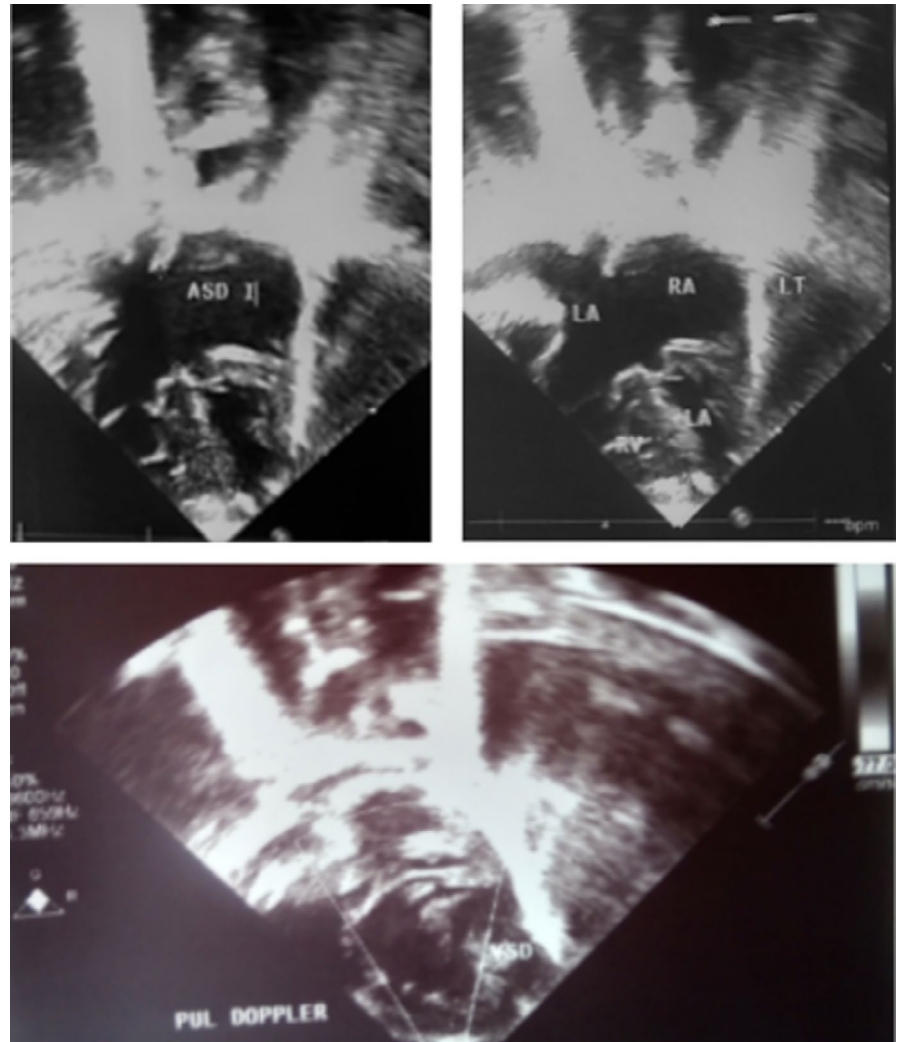
3 | DISCUSSION

Heterotaxy syndrome is a developmental laterality defect and is commonly associated with congenital heart diseases, especially in heterotaxy syndrome.⁷ Complex heart defects like pulmonary atresia, common mixing situations, anomalous pulmonary venous drainage, complete atrioventricular septal defect, and ventriculoarterial discordance especially in infants with right isomerism can be observed in heterotaxy. It is associated with either polysplenia and asplenia, and most of the patients with asplenia are immunocompromised making them vulnerable to high risk of infection or sepsis.^{8–10} Our patient had complex heart disease as mentioned and asplenia which might have complicated his hospital stay.

Apart from cardiac symptoms, gastrointestinal symptoms mainly vomiting are one of the non-cardiac manifestations of heterotaxy owing largely to intestinal malrotation and biliary atresia and rarely the anal atresia and tracheoesophageal fistula.¹¹ Our case was suspected with TEF based on symptomatology. However, intestinal malrotation could be the real culprit behind the non-bilious vomiting. As the majority of congenital facial paralysis are often related to perineal trauma during delivery, the same notion might be true in our case and the relation with heterotaxy can be due to developmental defect or a mere coincidence.^{12,13} But infectious, inflammatory, neoplastic, and traumatic causes should also be considered to make correct diagnosis.¹⁴

Diagnosis of the situs of any abdominal organ can be done by ultrasound.¹⁵ An abdominal scan should be done and might reveal abnormal symmetry of the liver, presence/absence and position of the gallbladder, and spleen abnormalities asplenia, single, or multiple small spleens.^{16,17} Our patient was

FIGURE 2 Parasternal views of Echocardiogram showing complex congenital heart disease with ventricular inversion, complete atrioventricular septal defect (unbalanced type, RV dominant), double outlet right ventricle



found to have situs ambiguous with asplenia through USG scanning and helped to reach a diagnosis of HS. Additionally, advanced imaging techniques like radiography, ultrasonography, CT, magnetic resonance imaging (MRI), and angiocardiography help in the detailed assessment of complex cardiac and extracardiac anomalies. However, availability of institutional equipment, manpower, and patient's choice is factors to be considered while doing CT and MRI. Moreover, the radiation dose should be minimized for children.^{3,18} CT angiogram advised in our case was, however, not performed due to the economical constraints of the family. Though a diagnosis of HS can be made antenatally but has no role in improving the outcomes in these patients.^{19,20} The mother of our case did not undergo an anomaly scan during her pregnancy, and thus, the diagnosis was likely missed.

New emerging medical management and cardiac surgical techniques like Fontan circulation and biventricular repair have shown an encouraging result on the improvement of prognosis in these patients. The outcomes after the surgery irrespective of presence or absence of HS are comparable to those with Fontan Circulation.⁸ A study Done by Agrawal et al²¹ among 75 HS patients with cardiac defects between

January 2011 and September 2018 found in-hospital mortality only 13% and concluded through review of literature that surgical management of this rare condition is related to satisfactory outcomes. The patients with this condition have lengthy clinical courses with an abundance of serious complications, including heart failure, respiratory failure, and sepsis.²² Our patient was managed with supportive care.

The management and treatment of Bell's palsy in children are still controversial with no clear guidelines.²³ In regard to the management of facial palsy in our case due to perinatal trauma (congenital), the family members were well counseled about the favorable prognosis of facial palsy. As, majority of children with facial palsy have a good prognosis with or without treatment (steroids, antivirals) and absence of sequela.²⁴ The severity of congenital heart disease is associated with the prognosis of ambiguous in children.²⁵ Patients with complex cardiac lesions and heterotaxy have a poor prognosis with 1-year mortality >85% in patients with asplenia and >50% in patients with polysplenia.¹⁸

A retrospective review (1997–2014) showed 83% survival among HS patients over a median follow-up of 65 months while 34% had a poor outcome.²⁶ However, with the

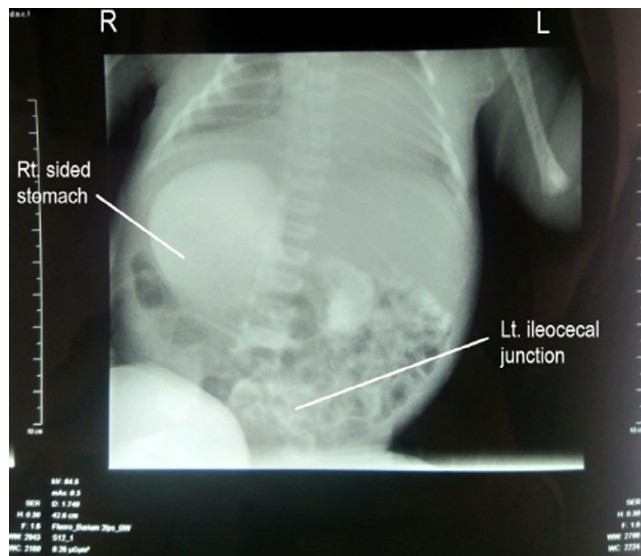


FIGURE 3 Gastrograffin showing right-sided stomach with left-sided ileocecal junction

improvement in the long-term outlook for these patients with modern cardiac surgery, the intra-abdominal anomalies have become increasingly significant and the visceral anomalies may contribute strongly to affect the long-term outcome.²⁷

4 | CONCLUSIONS

Heterotaxy syndrome with complex congenital heart disease remains a challenge. In recent studies, surgery management of this condition has shown a satisfactory outcome. Facial palsy, a very rare presentation in this case, has also a good prognosis. Proper counseling to the parents and the families about the condition, adequate follow-up along with all possible treatment modalities and the disease outcome is crucial.

ACKNOWLEDGEMENTS

We gratefully acknowledge the work of members of our hospital and the patient.

CONFLICT OF INTEREST

None declared.

AUTHOR CONTRIBUTIONS

DK (Dinesh Prasad Koirala): involved in counseling and treatment of the patient. SK (Sanjeev Kharel) and SS (Suraj Shrestha): collected all the required case information, images, slides, reports; reviewed the literature and contributed in both writing and editing the manuscript. HS (Hari Sedai), BMS (Bibek Man Shrestha), SH (Sushant Homagain), SK (Suraj Kandel): involved in editing the manuscript. All authors read and approved the final manuscript.

ETHICAL APPROVAL

Not Applicable.

CONSENT FOR PUBLICATION

Written informed consent was obtained from the infant's parents before the submission of the report for the publication of the case and the images.

DATA AVAILABILITY STATEMENT

The data that support the findings of this study are available from the corresponding author upon reasonable request.

ORCID

Sanjeev Kharel  <https://orcid.org/0000-0001-9591-3168>

Suraj Shrestha  <https://orcid.org/0000-0001-6888-260X>

REFERENCES

- Cartes-Zumelzu F. Fundamentals of diagnostic radiology. William E. Brant, Clyde A. Helms, Lippincott Williams and Wilkins, 1999, £104, p. 1460, ISBN 0683300938. *Eur J Radiol.* 2001;37:210-211. [https://doi.org/10.1016/s0720-048x\(00\)00261-8](https://doi.org/10.1016/s0720-048x(00)00261-8)
- Jacobs JP, Anderson RH, Weinberg PM, et al. The nomenclature, definition and classification of cardiac structures in the setting of heterotaxy. *Cardiol Young.* 2007;17(Suppl 2):1-28.
- Applegate KE, Goske MJ, Pierce G, Murphy D. Situs revisited: imaging of the heterotaxy syndrome. *Radiographics.* 1999;19:837-852. <https://doi.org/10.1148/radiographics.19.4.g99jl31837>
- Gilljam T, McCrindle BW, Smallhorn JF, Williams WG, Freedom RM. Outcomes of left atrial isomerism over a 28-year period at a single institution. *J Am Coll Cardiol.* 2000;36:908-916. [https://doi.org/10.1016/s0735-1097\(00\)00812-3](https://doi.org/10.1016/s0735-1097(00)00812-3)
- Hashmi A, Abu-Sulaiman R, McCrindle BW, Smallhorn JF, Williams WG, Freedom RM. Management and outcomes of right atrial isomerism: a 26-year experience. *J Am Coll Cardiol.* 1998;31:1120-1126. [https://doi.org/10.1016/s0735-1097\(98\)00062-x](https://doi.org/10.1016/s0735-1097(98)00062-x)
- Varanasi VK. Congenital facial paralysis. *Anaplastology.* 2012;01:100e-101. <https://doi.org/10.4172/2161-1173.1000e101>
- Swisher M, Jonas R, Tian X, Lee ES, Lo CW, Leatherbury L. Increased postoperative and respiratory complications in patients with congenital heart disease associated with heterotaxy. *J Thorac Cardiovasc Surg.* 2011;141:637-644. e3. <https://doi.org/10.1016/j.jtcvs.2010.07.082>
- Kim S-J. Heterotaxy syndrome. *Korean Circ J.* 2011;41(5):227-232.
- Sadiq M, Stumper O, De Giovanni JV, et al. Management and outcome of infants and children with right atrial isomerism. *Heart.* 1996;75:314-319. <https://doi.org/10.1136/hrt.75.3.314>
- Agarwal H, Mittal SK, Kulkarni CD, Verma AK, Srivastava SK. Right isomerism with complex cardiac anomalies presenting with dysphagia—a case report. *J Radiol Case Rep.* 2011;5(4):1-9.
- Kothari SS. Non-cardiac issues in patients with heterotaxy syndrome. *Ann Pediatr Cardiol.* 2014;7(3):187-192.
- Al Tawil K, Saleem N, Kadri H, Rifae M, Tawakol H. Traumatic facial nerve palsy in newborns: is it always iatrogenic? *Am J Perinatol.* 2010;27:711-714. <https://doi.org/10.1055/s-0030-1253097>
- Pavlou E, Gkampeta A, Arampatzi M. Facial nerve palsy in childhood. *Brain Dev.* 2011;33:644-650. <https://doi.org/10.1016/j.braindev.2010.11.001>

14. Shargorodsky J, Lin HW, Gopen Q. Facial nerve palsy in the pediatric population. *Clin Pediatr*. 2010;49(5):411-417.
15. Iida A, Emi M, Matsuoaka R, et al. Identification of a gene disrupted by inv(11)(q13.5;q25) in a patient with left-right axis malformation. *Hum Genet*. 2000;106:277-287. <https://doi.org/10.1007/s004390000245>
16. Vetter VL. Book review nadas' pediatric cardiology edited by Donald C. Fyler. 784 pp., illustrated. Philadelphia, Hanley and Belfus. 1992. \$75. (distributed by mosby-year book, St. Louis.) 0-932883-94-X. *N Engl J Med*. 1993;328:1285-1286. <https://doi.org/10.1056/nejm199304293281724>
17. Rose V, Izukawa T, Moes CA. Syndromes of asplenia and polysplenia. A review of cardiac and non-cardiac malformations in 60 cases with special reference to diagnosis and prognosis. *Heart*. 1975;37:840-852. <https://doi.org/10.1136/hrt.37.8.840>
18. Haramati LB, Glickstein JS, Issenberg HJ, Haramati N, Crooke GA. MR imaging and CT of vascular anomalies and connections in patients with congenital heart disease: significance in surgical planning. *Radiographics*. 2002;22(2):337-347; discussion 348-9.
19. Berg C, Geipel A, Smrcek J, et al. Prenatal diagnosis of cardio-splenic syndromes: a 10-year experience. *Ultrasound Obstet Gynecol*. 2003;22:451-459. <https://doi.org/10.1002/uog.904>
20. Berg C, Geipel A, Kamil D, et al. The syndrome of left isomerism. *J Ultrasound Med*. 2005;24:921-931. <https://doi.org/10.7863/jum.2005.24.7.921>
21. Agarwal R, Varghese R, Jesudian V, Moses J. The heterotaxy syndrome: associated congenital heart defects and management. *Indian J Thorac Cardiovasc Surg*. 2021;37:67-81. <https://doi.org/10.1007/s12055-020-00935-y>
22. Yildirim SV, Tokel K, Varan B, Aslamaci S, Ekici E. Clinical investigations over 13 years to establish the nature of the cardiac defects in patients having abnormalities of lateralization. *Cardiol Young*. 2007;17(3):275-282.
23. Youshani AS, Mehta B, Davies K, Beer H, De S. Management of Bell's palsy in children: an audit of current practice, review of the literature and a proposed management algorithm. *Emerg Med J*. 2015;32:274-280. <https://doi.org/10.1136/emered-2013-202385>
24. Ismail AQ, Alake O, Kallappa C. Do oral steroids aid recovery in children with Bell's Palsy? *J Child Neurol*. 2014;29:NP96-NP97. <https://doi.org/10.1177/0883073813504624>
25. Pepes S, Zidere V, Allan LD. Prenatal diagnosis of left atrial isomerism. *Heart*. 2009;95(24):1974-1977.
26. McGovern E, Kelleher E, Potts JE, et al. Predictors of poor outcome among children with heterotaxy syndrome: a retrospective review. *Open Heart*. 2016;3(2):e000328.
27. Frober R. Heterotaxy syndrome: an embryologic study. *Ann Clin Lab Res*. 2016;4:1. <https://doi.org/10.21767/2386-5180.100071>

How to cite this article: Kharel S, Koirala DP, Shrestha S, et al. Heterotaxy syndrome with complex congenital heart disease, facial palsy, and asplenia: A rare newborn finding. *Clin Case Rep*. 2021;9:e04573. <https://doi.org/10.1002/ccr3.4573>