



Elective lung resection after treatment for COVID-19 pneumonia

Takashi Sakai¹ · Yoko Azuma¹ · Kotaro Aoki² · Megumi Wakayama³ · Shion Miyoshi⁴ · Kazuma Kishi⁴ · Kazuhiro Tateda² · Sakae Homma⁵ · Akira Iyoda¹

Received: 6 February 2021 / Accepted: 30 March 2021 / Published online: 3 April 2021
© The Japanese Association for Thoracic Surgery 2021

Abstract

A 65-year-old man with coronavirus disease 2019 (COVID-19) was admitted to our hospital. Computed tomography detected bilateral pneumonia with a lung nodule suspicious for lung cancer. Lobectomy was performed 3 months after the treatment for COVID-19 without any complications. The surgical specimen revealed fibrosis below the pleura with a small collection of lymphocytes and intravascular hemorrhagic thrombosis, and no residual RNA was detected. This is the first report describing a surgical specimen after recovery from COVID-19 pneumonia, and suggests that elective thoracic surgery can be performed safely, depending on the patient's respiratory function, without infectious risk.

Keywords SARS-CoV-2 · COVID-19 · Lung cancer

Introduction

The characteristics of coronavirus disease 2019 (COVID-19) are in the process of being clarified, however, reports of histopathological findings are rare, and there are no reports on lung specimens after recovery from COVID-19. Though guidelines for the indication of surgery during the COVID-19 pandemic have been proposed, reports on the management of elective surgery are quite rare [1]. Herein, we describe a patient who underwent elective surgery for lung carcinoma diagnosed during his treatment for COVID-19 pneumonia and report the histopathological characteristics of the resected specimen.

Case

A 65-year-old man was admitted to our hospital with fever and dyspnea. He was a former smoker and had a history of diabetes mellitus. Computed tomography (CT) scan revealed bilateral ground-glass opacities and a solid 19-mm nodule in the right lower lobe (Fig. 1a, b). Polymerase chain reaction (PCR) test confirmed severe acute respiratory syndrome coronavirus 2 (SARS-CoV-2) infection, and the patient was administered oxygen, inhaled steroids, and favipiravir. Although the lung opacities temporarily worsened 2 weeks after admission (Fig. 1c), the patient's oxygenation and symptoms gradually improved; the PCR test was negative twice 4 weeks after admission.

The lung nodule was suspected to be cancerous, and surgery was planned. The patient's respiratory symptoms disappeared after hospitalization; however, the ground-glass opacities were visible on CT scans taken 6, 12, and 16 weeks (Fig. 1d–f) after hospitalization. A multi-disciplinary team including an infection control and prevention group, a pulmonologist, an anesthesiologist, and a thoracic surgeon decided that surgery 12 weeks after the completion of the treatment was appropriate, considering his respiratory function, infectivity, and cancer progression. The patient's oxygenation and respiratory function recovered at 12 weeks post-admission (Fig. 2). After the patient was confirmed to be negative for SARS-CoV-2 by the PCR test and that D-dimer value has returned to the normal level (Fig. 2),

✉ Akira Iyoda
aiyoda@med.toho-u.ac.jp

¹ Division of Chest Surgery, Department of Surgery, Toho University School of Medicine, 6-11-1, Omorinishi, Ota-ku, Tokyo 143-8541, Japan

² Department of Microbiology and Infectious Diseases, Toho University School of Medicine, Tokyo, Japan

³ Department of Surgical Pathology, Toho University School of Medicine, Tokyo, Japan

⁴ Division of Respiratory Medicine, Department of Internal Medicine, Toho University School of Medicine, Tokyo, Japan

⁵ Department of Advanced and Integrated Interstitial Lung Diseases Research, School of Medicine, Toho University, Tokyo, Japan

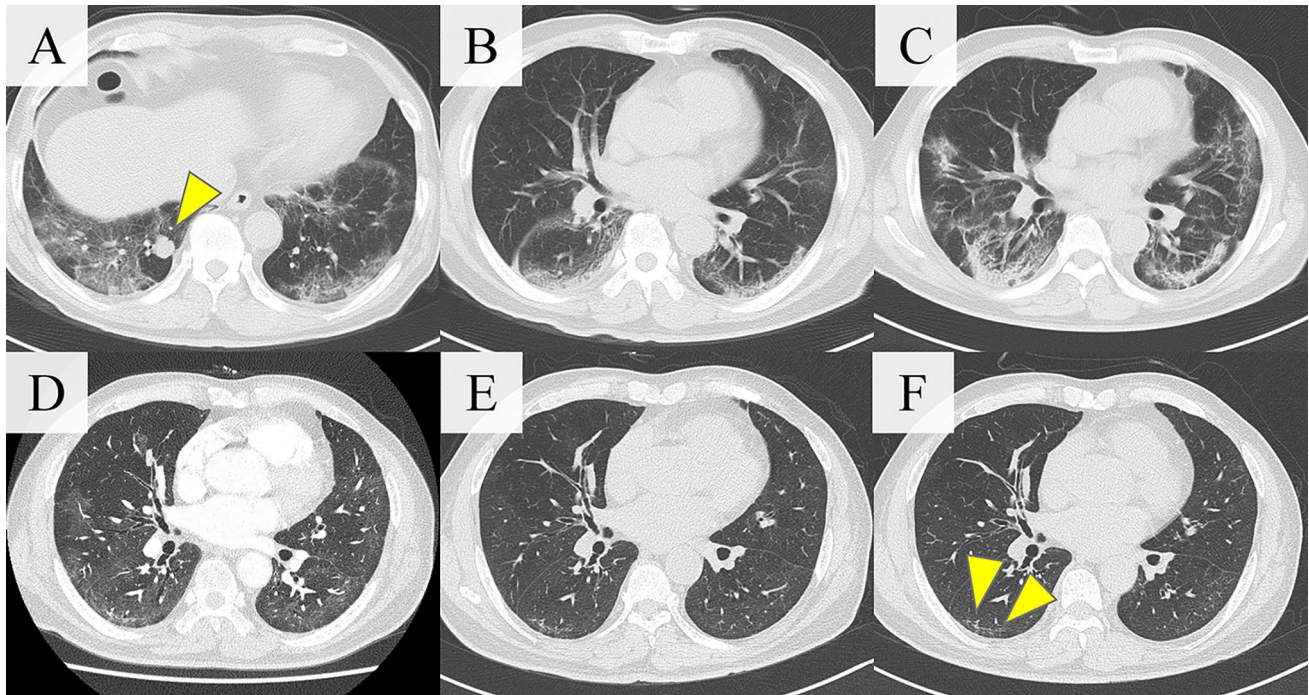
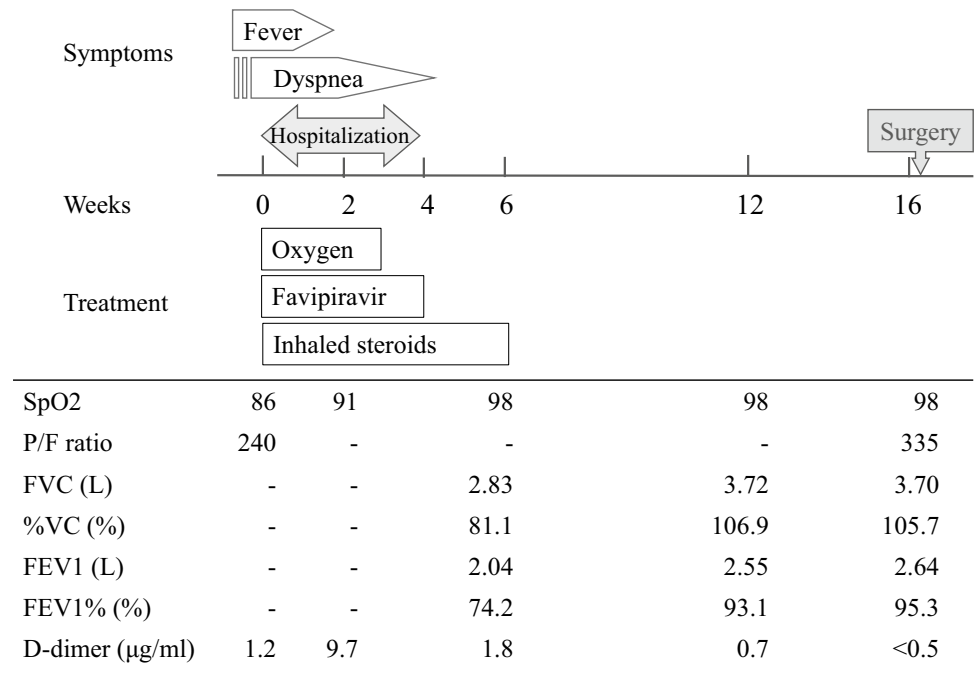


Fig. 1 a, b The computed tomography scan on admission showed patchy consolidation with ground glass opacity in all lung lobes and a solid nodule (arrow). The consolidation worsened 2 weeks (c), and

improved d 6, e 10, and f 16 weeks after admission, however, subpleural curvilinear shadow of the right lower lobe remained 16 weeks after admission (arrows)

Fig. 2 Time table, and inspection and D-dimer value results of the patient. His oxygenation evaluated using the saturation of percutaneous and arterial oxygen improved, and the pulmonary function test improved markedly from 6 to 12 and 16 weeks after admission. The D-dimer value was high during the infection, and returned to the normal level before surgery



he underwent lobectomy 16 weeks after his initial admission. The postoperative course was favorable, and he was discharged 7 days after the surgery.

PCR was performed on each extracted specimen, including the bronchus of the right lower lobe, the area in which

pneumonia was present at the time of surgery, the area in which pneumonia had disappeared during treatment, and the area where there was no pneumonia throughout the treatment period. All specimens were negative for SARS-CoV-2 RNA.

Histologically, fibrosis in the alveolar wall was widely observed below the visceral pleura (Fig. 3a, b) and focally along the alveolar septum (Fig. 3c, d). Infiltration of inflammatory cells including lymphocytes, plasma cells and eosinophils was partially observed (Fig. 3e). These fibrotic and inflammatory findings were almost unobserved in the area where there was no pneumonia throughout the treatment period, however, observed in the area in which pneumonia was present at the time of surgery and the area in which pneumonia had disappeared during treatment.

Intravascular hemorrhagic thrombosis was also observed in the specimen (Fig. 3f). The lung nodule was diagnosed as primary lung adenocarcinoma with its invasive size of 14 mm and predominantly papillary subtype, T1bN0M0 Stage IA2. There was no obvious change due to COVID-19 pneumonia in the tumor.

Discussion

Patients with preoperative SARS-CoV-2 infection have a high mortality and morbidity rate, especially in thoracic surgery [2]. Guidelines recommend that surgery during a pandemic period should be deferred or alternative treatment methods should be considered, depending on the patient's

condition [1]. However, there is no data on the safety, infectivity, and management of elective surgery. Our patient underwent elective lung resection safely without subsequent SARS-CoV-2 spread or complications. These results can be included in a database of elective surgery during the COVID-19 pandemic.

Surgical and histopathological findings have been reported in patients with early-phase COVID-19 pneumonia [3]. Histopathology suggests infiltration of inflammatory cells, alveolar hemorrhage, thickened interstitium, and intravascular hemorrhagic thrombosis in severe cases. In our patient, although CT revealed subpleural curvilinear shadow and the thoracoscopic findings were almost within normal limits, histopathology showed fibrosis below the pleura, infiltration of lymphocytes, and intravascular hemorrhagic thrombosis 16 weeks post-admission. Although, some lung changes may be due to chronic bronchitis or emphysema, these findings suggest that fibrosis, inflammatory infiltration, and thrombosis remain for a long period after treatment for COVID-19 pneumonia. Prolonged inflammation, thrombosis, and fibrosis may cause sequelae, which has been identified as a challenge for patients. There is no relationship between residual opacities and residual virus, as indicated by negative results for SARS-CoV-2 RNA in our surgical specimens, and the timing and procedure of surgery should

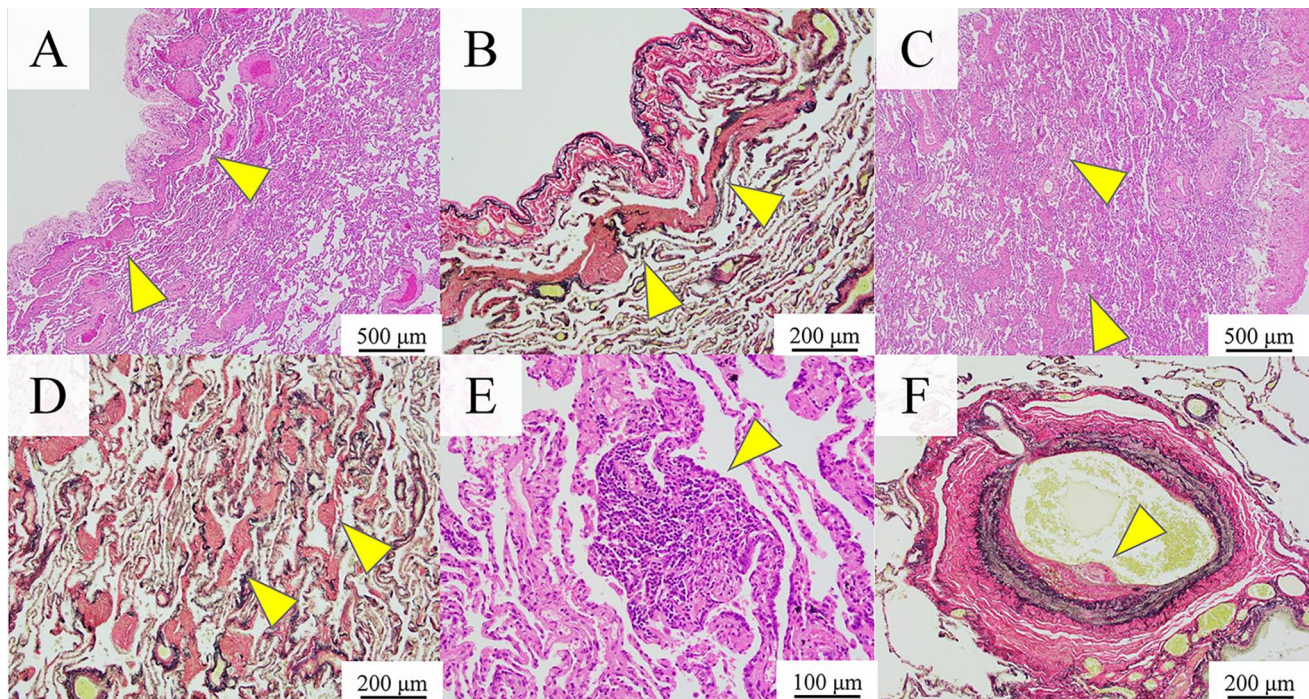


Fig. 3 a–f Histologically, subpleural fibrosis in the alveolar wall (arrows) was widely observed (a: Hematoxylin–Eosin staining, Scale bar=500 μm, b: Elastica van Gieson stain, Scale bar=200 μm) and focally along the alveolar septum (c: Hematoxylin–Eosin staining, Scale bar=500 μm, d Elastica van Gieson stain, Scale bar=200 μm).

e Infiltration of inflammatory cells including neutrophils, lymphocytes, plasma cells and eosinophils was partially observed (Hematoxylin–Eosin staining, Scale bar=100 μm). f Organized hemorrhagic thrombosis were found in peripheral pulmonary vessels (Elastica van Gieson stain, Scale bar=200 μm)

be determined comprehensively based on the cancer stage, range of remaining lung consolidations, respiratory function, and general condition.

Conclusion

The present study suggests that elective surgery is feasible for patients who have recovered from a SARS-CoV-2 infection, depending on the patient's respiratory function and general condition. Organized fibrosis and inflammation may remain for a prolonged period after recovery from COVID-19, whereas radiologic findings improved.

References

1. Antonoff M, Backhus L, Boffa DJ, Broderick SR, Brown LM, Carrott P, et al. COVID-19 guidance for triage of operations for thoracic malignancies: a consensus statement from thoracic surgery outcomes research network. *Ann Thorac Surg.* 2020;110:692–6.
2. Nepogodiev D, Bhangu A, Glasbey JC, Li E, Omar OM, Simoes JF, et al. Mortality and pulmonary complications in patients undergoing surgery with perioperative SARS-CoV-2 infection: an international cohort study. *Lancet.* 2020;396:27–38.
3. Tian S, Hu W, Niu L, Liu H, Xu H, Xiao S. Pulmonary pathology of early-phase 2019 novel coronavirus (COVID-19) pneumonia in two patients with lung cancer. *J Thorac Oncol.* 2020;15:700–4.

Publisher's Note Springer Nature remains neutral with regard to jurisdictional claims in published maps and institutional affiliations.