



Contents lists available at ScienceDirect

JPRAS Open

journal homepage: www.elsevier.com/locate/jpra

Case Report

Salmonella infection of breast implant associated with traveler's diarrhea: A case report

Bradley R. Hall^a, Katherine L. Billue^b, Stacey E. Sanders^b,
Bria R. Meyer^a, Perry J. Johnson^{b,*}^a Department of Surgery, University of Nebraska Medical Center, Omaha, NE 68198-3280, USA^b Department of Surgery, Division of Plastic and Reconstructive Surgery, University of Nebraska Medical Center, Omaha, NE 68198-3280, USA

ARTICLE INFO

Article history:

Received 21 August 2018

Accepted 30 August 2018

Available online 19 September 2018

Keywords:

Traveler's diarrhea

Salmonella

Breast

Infection

Implant

ABSTRACT

We present the first case of traveler's diarrhea resulting in breast implant infection. An otherwise healthy 34-year-old female underwent breast augmentation. Five months later, while vacationing in Cancun, Mexico, she developed abdominal pain and diarrhea that progressed to include fevers and chills. Her symptoms persisted until she returned to the United States, at which point her primary care physician evaluated her on the fourth day of her illness. An abdominal CT scan was unremarkable; however, a complete metabolic panel demonstrated elevated transaminases. Her symptoms soon resolved without treatment. Fourteen days after symptom resolution, the patient developed right breast pain. She was evaluated in the surgical clinic where the breast was tender to palpation, swollen and without erythema. An ultrasound demonstrated a small amount of homogenous fluid surrounding the implant. She was prescribed amoxicillin–clavulanate 875–125 mg BID; however, she presented three days later with worsening pain, swelling and new erythema. She was taken to the operating room, where the abscess was incised, drained and the implant removed. Cultures grew *Salmonella* serogroup C. Patients should be counseled regarding the potential for hematogenous seeding of the breast cavity and implant following severe illness and bacteremia. It may be reasonable to provide patients with breast implants who are

* Corresponding author.

E-mail address: pjohnson@unmc.edu (P.J. Johnson).

traveling to areas at high-risk for traveler's diarrhea or areas with limited medical resources with an antibiotic to take if moderate to severe symptoms of traveler's diarrhea were to develop while away.

© 2018 The Authors. Published by Elsevier Ltd on behalf of British Association of Plastic, Reconstructive and Aesthetic Surgeons.

This is an open access article under the CC BY-NC-ND license.
(<http://creativecommons.org/licenses/by-nc-nd/4.0/>)

Introduction

The number of breast augmentation procedures performed in the United States has increased by 41% since the year 2000 and is now the most common aesthetic surgical procedure performed in the United States.¹ Post-operative infection rates are low and estimated to occur following 1–2% of all cases with lower rates seen in patients undergoing aesthetic breast augmentation.² Most infections occur in the first two months after surgery;² however, infections can occur several months to years later, often in the setting of either systemic bacteremia or an invasive diagnostic or therapeutic procedure.^{3,4} For patients with artificial joints or other synthetic material, the risk of prosthesis infection resulting from hematogenous seeding is well established;⁵ however, few cases have ever been reported for patients with breast implants. Here, we report the first case of a breast implant infection following a case of traveler's diarrhea in a young healthy female.

Case presentation

A 34-year-old otherwise healthy non-obese female with hypomastia and asymmetric breasts elected to undergo bilateral breast augmentation with left-sided crescentic lift (Figure 1). Two grams of intravenous cefazolin were administered prior to making a 5 cm incision in the inframammary fold centered below the areola. A 485 mL smooth silicone implant was chosen for the right breast and a 445 mL smooth silicone implant was chosen for the left. Both the subglandular prepectoral spaces and implants were irrigated with antibiotic solution containing gentamycin, bacitracin and cefazolin prior to insertion using a Keller funnel. Interrupted 3–0 absorbable braided sutures were used to close the deep dermal space and a running 5–0 absorbable monofilament suture was used to close the subcuticular layer. A left-sided crescentic lift was then performed to elevate the left nipple-areolar complex and the skin layers were closed in a similar fashion. Sterile dressings were applied, and the patient was discharged to home after recovering from anesthesia. No post-operative antibiotics were prescribed.

She was seen for follow up one week after surgery and noted to be doing well except for mild muscle spasms of the left breast that resolved with diazepam. Approximately five months later, the patient vacationed in Cancun, Mexico, during which time she developed abdominal pain, fevers, chills and diarrhea. Her symptoms persisted after returning to the United States and her primary care physician evaluated her on the fourth day of her illness. At that time, a complete metabolic panel was significant for elevated transaminases and an abdominal CT was unremarkable. A stool sample was not collected nor was she prescribed antibiotics. Five days later, repeat labs were obtained, which demonstrated an improvement in her transaminase levels and she reported resolution of her symptoms. Fourteen days after her symptoms resolved, she developed right breast pain and swelling (Figure 2). She was seen in our clinic and on exam, her right breast was swollen, tender to palpation and without erythema. No drainage was noted from her incision and the left breast was unremarkable. An ultrasound demonstrated homogenous fluid surrounding the implant (Figures 3 and 4). She was prescribed amoxicillin-clavulanate 875–125 mg BID; however, three days later, she presented with a large abscess in the inferior pole of the right breast with worsening erythema and prominent fluctuance. That day, she was taken to the operating room, where the abscess was incised and drained and the implant removed. During surgery, 200 mL of grossly purulent material was drained. Cultures

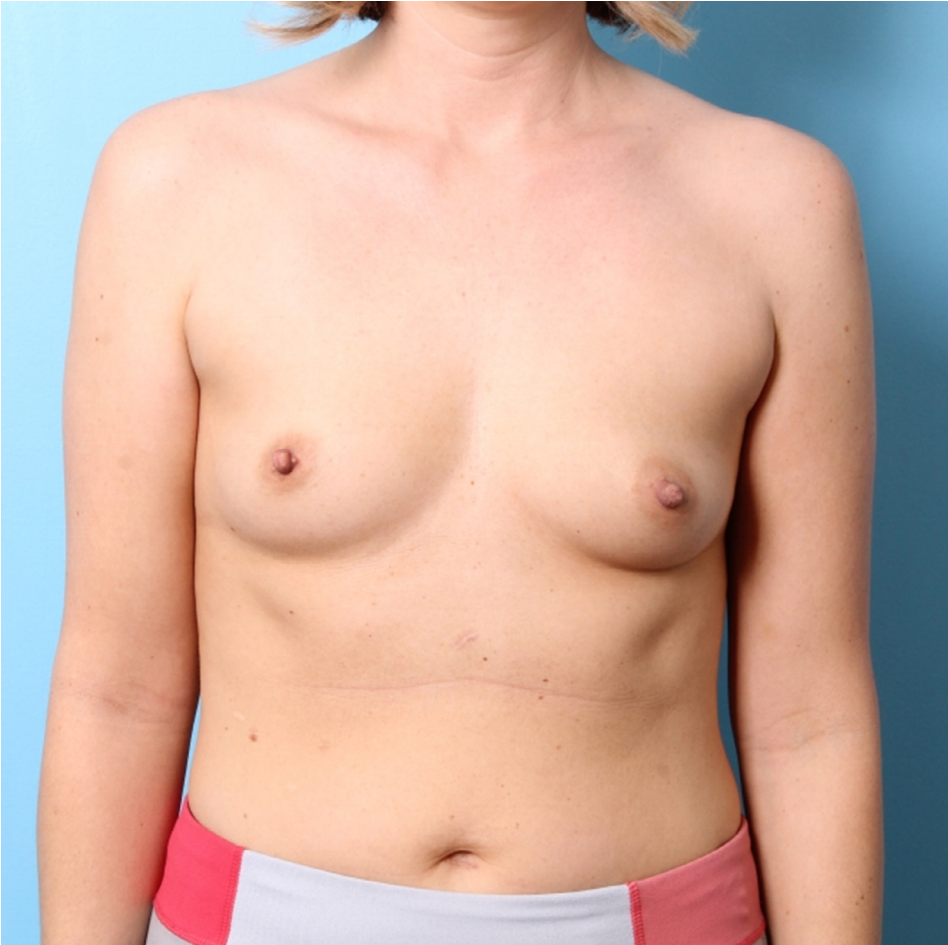


Figure 1. Preoperative image of patient's breasts demonstrating hypomastia and asymmetric areolar location.

were obtained of the fluid that later grew *Salmonella* serogroup C. At that time, her antibiotics were changed to sulfamethoxazole–trimethoprim 800–160 mg BID given the culture sensitivities. Infectious disease was consulted, and it was recommended that she complete a total of 14 days of antibiotic therapy and four additional months pass before another implant be placed.

Discussion

Several serovars of non-typhoidal *Salmonella* exist and 5–12% of cases result in systemic illness. Our patient was infected with *Salmonella* serogroup C, which is both the most common serogroup in the United States and one of the most lethal.⁶ *Salmonella* is a Gram-negative facultative anaerobic bacterium known to cause traveler's diarrhea in addition to *Escherichia coli*, *Campylobacter*, *Shigella*, *Vibrio* and *Giardia*.^{7,8} *Salmonella* infection is typically caused by fecal-oral contamination of food or water. The risk of developing traveler's diarrhea is destination dependent and estimated to be >20% for countries including Mexico, Central America, India, and most of Africa.⁷ Extraintestinal *Salmonella* infections can occur as a result of the bacterium's ability to live within enteric phagocytes that later return to systemic circulation after resolution of the primary enteric insult.⁹



Figure 2. Image taken after having recovered from gastroenteritis at the time when the patient noticed tenderness and swelling of the right breast.

Our patient had minimal risk factors for infection and every precaution was taken to reduce her risk in the perioperative period. Her historical account of having developed diarrhea and abdominal pain during her vacation at a high-risk destination is consistent with a diagnosis of traveler's diarrhea and it is highly likely that her breast implant infection was attributable to her recent illness. Our patient was not evaluated until she came back to the United States, at which point she was febrile with elevated transaminases. Our patient may have been able to avoid systemic illness (and potentially her breast implant infection) if she would have taken antibiotics earlier in the disease course when they were already otherwise indicated.

Recent guidelines published in 2017 state that routine antibiotic prophylaxis for traveler's diarrhea is not indicated except for individuals at high-risk of dehydration-related complications (i.e. severe cardiovascular disease). For patients who do develop traveler's diarrhea, antibiotic therapy is recommended once symptoms interfere with daily activities.⁸ Every year, millions of people develop traveler's diarrhea and, although recent estimates are not available, a small percentage of these people likely have breast implants.¹⁰ This case demonstrates the potential for hematogenous seeding of the

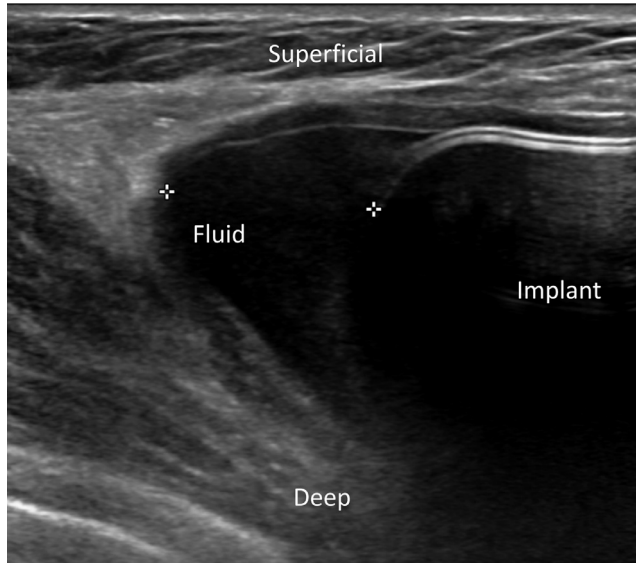


Figure 3. Ultrasound image demonstrating a small collection of homogenous fluid at the inferior and lateral aspect of the breast outside of her implant at the 7 o'clock position.

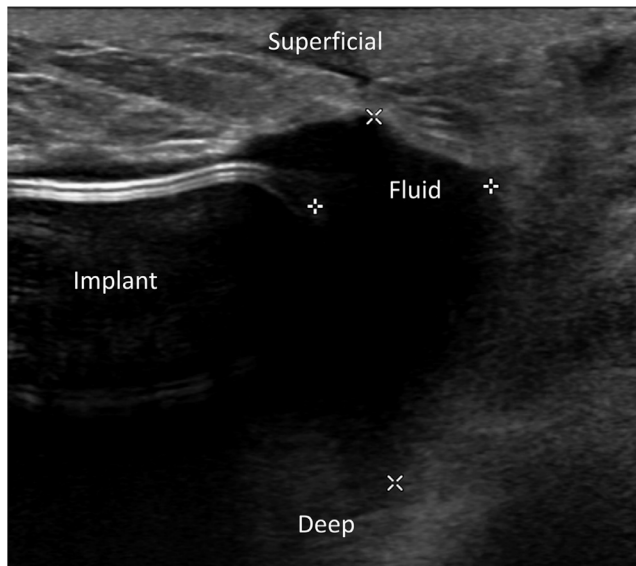


Figure 4. Ultrasound image demonstrating a small collection of homogenous fluid at the superior and lateral pole of the breast outside of her implant at the 11 o'clock position.

breast implant cavity and potential for infection in the setting of severe traveler's diarrhea. This risk is also likely present in the setting of other sources of bacteremia and remains relatively uninvestigated.

Patients who have previously undergone breast augmentation with prosthetic implants should be made aware of the potential for hematogenous seeding of the implant cavity and risk for subsequent infection following an episode of bacteremia. Patients should also be counseled regarding the impor-

tance of medical evaluation prior to the development of severe infectious disease. As evidenced by our case, worsening or severe traveler's diarrhea is an indication for antibiotic therapy and patients with breast implants should not delay antibiotic therapy given its already present indication and potential for hematogenous seeding of distant sites. It may be reasonable to provide patients with breast implants who are traveling to areas at high-risk for traveler's diarrhea or areas with limited medical resources with an antibiotic to take if moderate to severe symptoms of traveler's diarrhea were to develop while away.

Conflicts of interest

The authors declared no potential conflicts of interest with respect to research, authorship and publication of this article.

Funding

The authors received no financial support for the research, authorship and publication of this article.

References

1. American Society of Plastic Surgeons. Cosmetic plastic surgery statistics. <https://www.plasticsurgery.org/documents/News/Statistics/2017/plastic-surgery-statistics-report-2017.pdf>; 2017 [Accessibility verified July 20, 2017].
2. Pittet B, Montandon D, Pittet D. Infection in breast implants. *Lancet Infect Dis*. 2005;5:94–106.
3. Hunger J, Padilla M, Cooper-Vastola S. Late *Clostridium perfringens* breast implant infections after dental treatment. *Ann Plast Surg*. 1996;36:309–312.
4. Bernardi C, Saccomanno F. Late *Klebsiella pneumoniae* infection following breast augmentation: case report. *Aesthetic Plast Surg*. 1998;22:222–224.
5. Aslam S, Reitman C, Darouiche RO. Risk factors for subsequent diagnosis of prosthetic joint infection. *Infect Control Hosp Epidemiol*. 2010;31:298–301.
6. Fuche FJ, Sow O, Simon R, Tennant SM. *Salmonella* serogroup C: current status of vaccines and why they are needed. *Clin Vaccine Immunol*. 2016;23:737–745.
7. Steffen R, Hill DR, DuPont HL. Traveler's diarrhea: a clinical review. *JAMA*. 2015;313:71–80.
8. Singh E, Redfield D. Prophylaxis for travelers' diarrhea. *Curr Gastroenterol Rep*. 2009;11:297–300.
9. Worley MJ, Nieman GS, Geddes K, Heffron F. *Salmonella* typhimurium disseminates within its host by manipulating the motility of infected cells. *Proc Natl Acad Sci USA*. 2006;103:17915–17920.
10. Cook RR, Delongchamp RR, Woodbury M, Perkins LL, Harrison MC. The prevalence of women with breast implants in the United States—1989. *J Clin Epidemiol*. 1995;48:519–525.