

Improving ^{18}F -Fluoro-D-Glucose-Positron Emission Tomography/Computed Tomography Imaging in Alzheimer's Disease Studies

Karin Knešaurek

Department of Radiology, Division of Nuclear Medicine, Icahn School of Medicine at Mount Sinai, New York City, NY, USA

Abstract

The goal was to improve Alzheimer's 2-deoxy-2- ^{18}F -fluoro-D-glucose (^{18}F FDG)-positron emission tomography (PET)/computed tomography (CT) imaging through application of a novel, hybrid Fourier-wavelet windowed Fourier transform (WFT) restoration technique, in order to provide earlier and more accurate clinical results. General Electric Medical Systems downward-looking sonar PET/CT 16 slice system was used to acquire studies. Patient data were acquired according to the Alzheimer's disease Neuroimaging Initiative (ADNI) protocol. Here, we implemented Fourier-wavelet regularized restoration, with a Butterworth low-pass filter, order $n = 6$ and a cut-off frequency $f = 0.35$ cycles/pixel and wavelet (Daubechies, order 2) noise suppression. The original (PET-O) and restored (PET-R) ADNI subject PET images were compared using the Alzheimer's discrimination analysis by dedicated software. Forty-two PET/CT scans were used in the study. They were performed on eleven ADNI subjects at intervals of approximately 6 months. The final clinical diagnosis was used as a gold standard. For three subjects, the final clinical diagnosis was mild cognitive impairment and those 13 PET/CT studies were not included in the final comparison, as the result was considered as inconclusive. Using the remaining 29 PET/CT studies (23 AD and 6 normal), the sensitivity and specificity of the PET-O and PET-R were calculated. The sensitivity was 0.65 and 0.96 for PET-O and PET-R, respectively, and the specificity was 0.67 and 0.50 for PET-O and PET-R. The accuracy was 0.66 and 0.86 for PET-O and PET-R, respectively. The results of the study demonstrated that the accuracy of three-dimensional brain F-18 FDG PET images was significantly improved by Fourier-wavelet restoration filtering.

Keywords: Alzheimer's disease, image improvement, positron emission tomography/computed tomography imaging

Introduction

The incidence of Alzheimer's disease (AD) is growing rapidly due to the increase in life expectancy among the general population. Positron emission tomography (PET) imaging seems to be a very promising noninvasive tool in early diagnosis, in guiding effective treatment, and in defining and developing prevention strategies.^[1-4] The advantage of PET imaging is its capability to detect biological changes in the brain that are attributable to AD earlier than any other diagnostic test. Early

detection and confirmation of AD allows for early drug therapy, slowing the loss of functional ability, future planning before the loss of mental capacity, positive and accurate diagnosis of other dementing processes, as well as aiding in the discovery and development of new therapies. Not long ago, The National Institute of Aging published recommendations for studies on aging that utilized PET data^[5] while at the same time acknowledged prior limitations of PET studies. The major limitation of PET studies is relatively poor resolution in comparison with magnetic resonance imaging (MRI) and computed tomography (CT) imaging. However, it has been reported^[6] that after PET image reconstruction, the spatial resolution variation in the central-field-of-view, used for brain imaging, is about 5%. Therefore, the stationary restoration approach^[7-9] is a reasonable approximation. Our institution participates in the Alzheimer's disease Neuroimaging Initiative (ADNI),^[10] and thus we

Access this article online

Quick Response Code:



Website:

www.wjnm.org

DOI:

10.4103/1450-1147.163246

Address for correspondence:

Dr. Karin Knešaurek, Division of Nuclear Medicine, Icahn School of Medicine at Mount Sinai, One Gustave Levy Place, Box 1141, New York, NY 10029, USA. E-mail: karin.knesaurek@mssm.edu

have been acquiring and processing^[11] phantom and patient data in a standardized way. Therefore, we have great incentive to improve the methodology of PET Alzheimer's imaging. The benefits of the restoration approaches are more accurate radiotracer distribution in images and better absolute quantification of tracer uptake. The main objective of our work is to improve the 2-deoxy-2-¹⁸F-fluoro-D-glucose (¹⁸F FDG) three-dimensional (3D) PET Alzheimer's imaging using a novel and hybrid Fourier-wavelet restoration technique.^[12-15] The initial results of improving ¹⁸F FDG PET brain images by the Fourier-wavelets restoration technique are presented.

Materials and Methods

Data acquisition

The General Electric (GE Medical Systems, Milwaukee, WI) downward-looking sonar PET-CT + 16 scanner was used in this study and all images were acquired in 3D mode. PET brain studies were acquired 40 min following intravenous administration of 370 MBq of ¹⁸F-FDG. PET scans were obtained as a 30 min dynamic emission scan (six 5 min/frames), but the summed 30 min reconstructed slices were used for analysis. Attenuation correction was performed using CT scans. The reconstruction matrix size was 128 × 128 and the pixel size was 4.3 mm. The images were reconstructed with the Kinahan-Rogers 3D filtered backprojection.^[11] Patient data were acquired in Health Insurance Portability and Accountability compliance at our institution, and according to ADNI rules, each patient was assigned a unique identifier. Also, following the ADNI rules, we have to put the following statement: "Data used in the preparation of this article were obtained from the ADNI database (adni.loni.ucla.edu). The ADNI was launched in 2003 by the National Institute on Aging, the National Institute of Biomedical Imaging and Bioengineering, the Food and Drug Administration, private pharmaceutical companies and nonprofit organizations, as a \$60 million, 5-year public-private partnership. The primary goal of ADNI has been to test whether serial MRI, PET, other biological markers, and clinical and neuropsychological assessment can be combined to measure the progression of mild cognitive impairment (MCI) and early AD. Determination of sensitive and specific markers of very early AD progression is intended to aid researchers and clinicians to develop new treatments and monitor their effectiveness, as well as lessen the time and cost of clinical trials. The principal investigator of this initiative is Michael W. Weiner, MD, VA Medical Center and University of California – San Francisco. ADNI is the result of efforts of many co-investigators from a broad range of academic institutions and private

corporations, and subjects have been recruited from over 50 sites across the U.S. and Canada. The initial goal of ADNI was to recruit 800 subjects, but ADNI has been followed by ADNI-GO and ADNI-2. To date, these three protocols have recruited over 1500 adults, ages 55–90, to participate in the research, consisting of cognitively normal older individuals, people with early or late MCI, and people with early AD. The follow-up duration of each group is specified in the protocols for ADNI-1, ADNI-2 and ADNI-GO. Subjects originally recruited for ADNI-1 and ADNI-GO had the option to be followed in ADNI-2. For up-to-date information, "see www.adni-info.org." Fourier restoration techniques have been successfully applied in nuclear medicine.^[7-9] However, not long ago, hybrid Fourier-wavelet restoration techniques^[12-15] have been developed, which have better properties, especially in reducing the amount of noise in the restored images. New, successful restoration techniques can have a significant quantitative and qualitative impact on restored PET images. Quantitative improvement is achieved through reducing partial volume effect, thereby providing more accurate activity and standard uptake values.

The restoration approach

Here, we have implemented the Fourier-wavelet regularized deconvolution (ForWaRD).^[12] The specific filters were created and optimized using the Hoffman 3D brain phantom study as described in our previous phantom restoration study.^[16,17] Briefly, the fast Fourier transform (FFT) restoration was applied with the Butterworth low-pass filter, order $n = 6$ and cut-off frequency $f = 0.35$ cycles/pixel. In addition, wavelet (Daubechies, order 2) noise suppression was applied by "hard threshold".^[14] Use of the threshold removes small coefficients, identified with the noise components, and the inverse operation restores the true signal. Different threshold filters were tested using interactive language Interactive Data Language V.6.1 (Research Systems, Inc., Boulder, CO). The filters were optimized using the 3D Hoffman brain study by evaluation of the true activity concentration in the phantom, by calculating the contrast and noise measured as a coefficient of variation (COV, $100 \times \text{SD}/\text{mean}$ (%)), using linear profiles, and by visual analysis.

Discrimination between Alzheimer's disease and normal subjects and clinical evaluation

The PET brain images, original, FFT restored, and Fourier-wavelet windowed Fourier transform (WFT) restored images were compared using the Alzheimer's discrimination analysis by dedicated software (PMOD

2.8, PMOD Technologies, Zurich, Switzerland).^[18] The applied automated method for the discrimination between Alzheimer's dementia and normal controls is based on the FDG data acquired in a large multi-center trial.^[19] The method is based on 110 normal controls and 395 patients with probable AD. Each subject's brain scan is compared with the age-adjusted normal template using the Student's *t*-test, by calculating the *t*-sums of those areas that are typical for AD that is, AD *t*-sums. The approach provided 93% sensitivity and specificity for distinction of mild to moderate probable AD from normals.^[19] Also, the readings of experienced nuclear medicine physicians were used for comparison, without discrepancy to date. The Alzheimer's discrimination analysis diagnosed each subject as AD positive or AD negative.

As a part of the ADNI protocol, each subject in addition to the PET imaging was reviewed by the study clinician. The clinical diagnosis was made using neuropsychological and caregiver assessments, (the Mini Mental State Examination, AD Assessment Scale, Neuropsychiatric Inventory, Functional Assessment Questionnaire, AD Cooperative Study - Activities of Daily Living, Global Clinical Dementia Rating), as well as the clinical interview, PET imaging reports and MRI reports if available. Any conversion between previous and current diagnoses was supplemented with the physician's notes to explain the change in diagnosis. The physician diagnosed each subject as having normal cognition, MCI, AD, or another type of dementia.

In our retrospective study of early diagnosis and prediction of AD, the final clinical diagnosis was used as the gold standard. For patients with MCI as the final diagnosis, results were classified as inconclusive because the Alzheimer's discrimination analysis gives only positive or negative AD results.

Results

Comparison between Fourier only (fast Fourier transform) and Fourier-wavelets (windowed Fourier transform) images

The results of an Alzheimer's subject are shown in Figure 1, which shows that FFT images were improved in terms of resolution and contrast, but suffered from relatively high levels of noise. However, the WFT images, as seen in the profiles, had the same number of counts and the same contrast as FFT images, but were significantly less noisy. The very same trend was shown in our previous 3D Hoffman brain phantom study^[16,17] in which FFT images were improved in terms of resolution, contrast and quantification, but suffered from relatively high levels of noise. However, the WFT phantom images, although almost identical

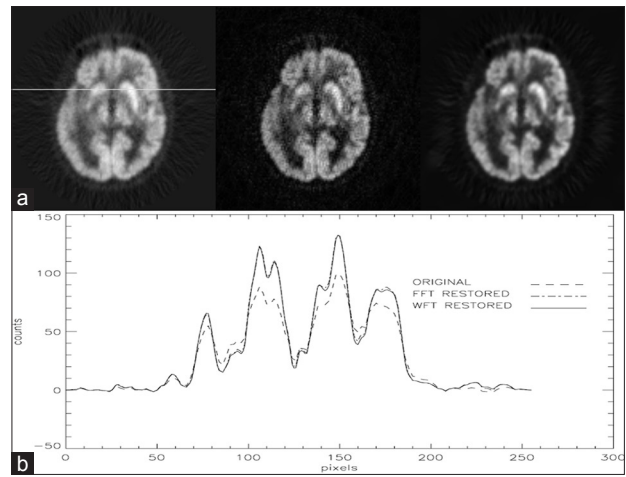


Figure 1: (a) Upper part of the figure, original, fast Fourier transform (FFT) and windowed Fourier transform (WFT) positron emission tomography (PET) brain images of Alzheimer's subject and (b) lower part of the figure, the profile along the line shown on original PET image. The FFT image is significantly noisier than WFT image, but FFT and WFT restored image profiles are practically the same, indicating the same improvement in quantification

in terms of resolution, contrast and quantification to FFT images, were significantly less noisy. This pattern was followed in our clinical studies [Figure 1] and in further analysis FFT images were not used for comparison between original (PET-O) and restored (PET-R) PET images.

Alzheimer's disease neuroimaging initiative subject study results

Forty-two PET/CT scans were used in the study, performed on eleven ADNI subjects at intervals of approximately 6 months for each subject [Table 1]. The final clinical diagnosis for three subjects was MCI and those 13 PET/CT studies were not included in the final comparison. Two subjects' final clinical diagnoses were normal, and there were six PET/CT studies performed on them. Six patients with a total of 23 PET/CT studies were finally diagnosed as AD. Three of these subjects converted from MCI to AD, and these were the most interesting cases. 13 original PET studies (PET-O) and 16 restored PET studies (PET-R) were in agreement with corresponding clinical diagnoses, which were made at the same time as PET acquisitions. Based on the final clinical diagnoses, 4 PET-R studies and 10 PET-O studies did not perform as well as the corresponding clinical diagnoses. For example, for subject 013_S_0575, PET-O and PET-R in two studies yielded an AD result, but clinical diagnosis was normal in both cases. The 6 PET-O and 9 PET-R performed better than corresponding clinical diagnoses because they predicted AD earlier for the subjects with AD as final diagnosis. This shows that PET/CT imaging, and especially restored PET/CT, has potential for diagnosing and predicting AD earlier in life.

Table 1: Results of 11 subjects used in the longitudinal study. BL is a base line study and other studies were done in 6 month intervals. PET-O and PET-R indicates results from original PET images and restored PET images, respectively. Dx denotes clinical diagnosis at each visit. AD denotes Alzheimer's disease, N normal findings and MCI mild cognitive impairment findings

Subject	PET-O	PET-R	Dx
013_S_0240			
Visit			
BL	N	AD	MCI
6	N	AD	MCI
12	N	AD	MCI
18	AD	AD	AD
24	N	AD	AD
013_S_0325			
Visit			
BL	AD	AD	MCI
6	AD	AD	MCI
12	AD	AD	MCI
18	AD	AD	AD
24	AD	AD	AD
013_S_0502			
Visit			
BL	N	N	N
6	N	N	N
12	N	AD	N
18	N	N	N
013_S_0575			
Visit			
BL	AD	AD	N
6	AD	AD	N
013_S_0699			
Visit			
BL	AD	AD	AD
013_S_0860			
Visit			
BL	AD	AD	MCI
6	AD	AD	MCI
6	AD	AD	MCI
12	AD	AD	AD
013_S_1120			
Visit			
BL	AD	AD	MCI
6	AD	AD	MCI
12	AD	AD	MCI
18	AD	AD	MCI
24	AD	AD	MCI
013_S_1161			
Visit			

Contd...

Table 1: Continued

Subject	PET-O	PET-R	Dx
BL	AD	AD	AD
6	AD	AD	AD
12	AD	AD	AD
18	AD	AD	AD
013_S_1186			
Visit			
BL	N	N	MCI
6	N	AD	MCI
12	N	N	MCI
18	N	AD	MCI
24	N	AD	MCI
013_S_1205			
Visit			
BL	N	N	AD
6	N	AD	AD
12	N	AD	AD
24	N	AD	AD
013_S_1275			
Visit			
BL	N	N	MCI
6	N	N	MCI
12	N	N	MCI

Subject 013_S_0240 demonstrated the most interesting pattern. The subject underwent five studies at approximately 6 month intervals. Even in the first study, the PET-O suggested a normal scan and PET-R suggested AD [Figures 2 and 3], and this pattern was repeated in the next two studies. In these three early studies, the subject's clinical diagnosis was MCI consistently. However, in the fourth study, both the original and restored data, as well as the clinical diagnosis suggested AD [Figures 4 and 5]. In the last, fifth study, again the PET-O suggested a normal scan, while PET-R suggested AD. The final clinical diagnosis was also AD. This shows that the PET-R images identified the correct diagnosis in the early AD stage a year and a half earlier than the original PET/CT study.

Subject 013_S_1205 underwent four PET/CT studies. Only in the first study the PET-O and the PET-R yielded normal results while, in the second, third and fourth studies, the PET-O continued to give normal results and the PET-R gave AD-positive results. The clinical diagnoses were AD for all four studies, showing that for this patient PET-R was significantly better than PET-O.

In patient 013_S_0502, four studies were performed at approximately 6 month intervals. In all four studies, clinical diagnosis as well as PET-O gave normal results.

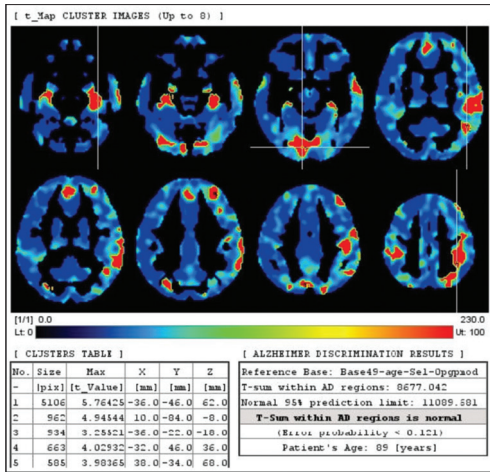


Figure 2: Alzheimer's discrimination analysis for subject 013_S_0240 in first, original positron emission tomography scan showing normal that is, nonalzheimer's disease (AD) result. The analysis normalizes each subject's brain and matches it by affine 12-parameter transformation to age-matched controls. The differences between control and subject's brain were calculated voxel-by-voxel and areas of significant difference are shown in red in the most prominent slices. A t-sum for AD areas was calculated and used for diagnosis. The current clinical diagnosis was mild cognitive impairment

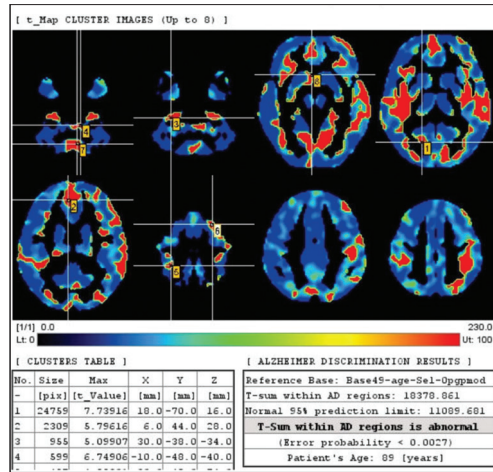


Figure 3: The same positron emission tomography study of the same 013_S_0240 subject with windowed Fourier transform restoration gives abnormal that is positive Alzheimer's disease (AD) result. The current diagnosis was mild cognitive impairment, but the final diagnosis was AD and consistent with this finding

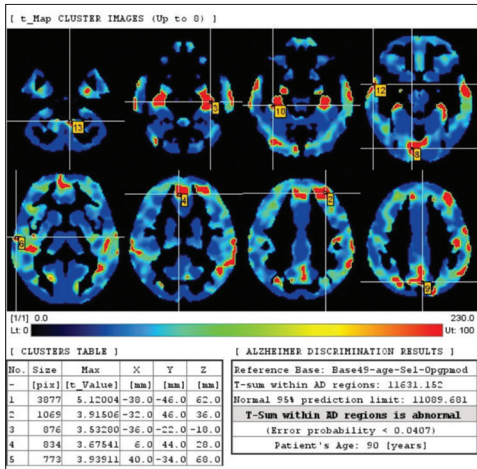


Figure 4: A year and a half after the first positron emission tomography (PET) study [Figures 2 and 3], for the same 013_S_0240 subject, original PET study shows positive for Alzheimer's disease (AD). The final clinical diagnosis was AD

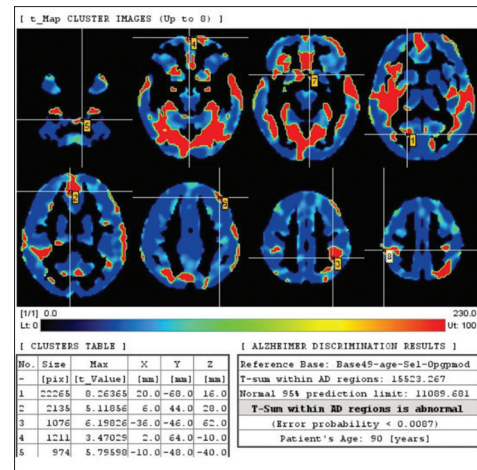


Figure 5: The windowed Fourier transform (WFT) restored positron emission tomography (PET) study of the 013_S_0240 subject a year and a half after the first study [Figures 2 and 3] also shows positive for Alzheimer's disease (AD). The final clinical diagnosis was AD. Comparison of Figures 2-5 shows that WFT restoration predicted AD a year and a half earlier than original PET study

PET-R also gave normal results in all studies except in the third PET/CT study, which indicated a positive AD scan. This was the only additional false-positive (FP) PET-R result in comparison with PET-O. The two other FP results for PET-O and PET-R were discussed above for subject 013_S_0575.

Using 29 PET/CT studies (23 AD and 6 normal studies), we calculated sensitivity and specificity of the PET-O and PET-R using the final clinical diagnosis as a standard. This is not the same sensitivity and specificity of 93% for PET imaging mentioned above in describing the Alzheimer's discrimination analysis.

Here, we do not compare PET imaging with the current clinical diagnosis but rather with the final clinical diagnosis. Sensitivity was 0.65 and 0.96 for PET-O and PET-R, respectively and specificity was 0.67 and 0.50 for PET-O and PET-R. The accuracy was 0.66 and 0.86 for PET-O and PET-R, respectively. Although PET-R had significantly higher sensitivity and accuracy than PET-O, it had lower specificity most probably due to relatively limited number of images in the study.

This preliminary data, although limited in number of subjects, suggest that our approach can improve 3D PET Alzheimer's imaging, allowing for an earlier diagnosis

and providing overall better 3D brain ^{18}F FDG PET images.

Discussion

The application of the Fourier-wavelet restoration in our previous Hoffman 3D brain phantom study^[16,17] showed significant improvement in quantification, resolution, contrast and background subtraction in restored images compared to the original PET/CT image. In this study, the clinical images [Figure 1] followed the same pattern and the restored images had better contrast and resolution. Consequently, the restored images enabled earlier AD diagnosis and had significantly better sensitivity and accuracy. The limitations of the study are the relatively limited number of subjects, and using the clinical diagnosis as a gold standard instead of the postmortem diagnosis of AD.

In a recent review article,^[20] it was stated that ^{18}F -FDG PET is an effective and safe modality to identify the diagnostic patterns of glucose hypometabolism in neurodegenerative dementias and is an effective and useful adjunct to the other diagnostic information in the assessment of patients with progressive cognitive impairment. Even more, ^{18}F -FDG PET has shown to be very useful to distinguish other neurodegeneration, such as dementia with Lewy bodies and frontotemporal dementia (FTD) from AD. ^{18}F -FDG PET scans have received approval in the United States for Medicare reimbursement to aid in the distinction of AD from FTD.^[21] However, there are certain limitations of the ^{18}F -FDG PET in the evaluation of dementia. A meta-analysis of the literature from 1990 to 2000 found ^{18}F -FDG PET to have a summary sensitivity of 86% and a summary specificity of 86% for AD diagnosis. The more recent analysis shows comparable or better values.^[20] However, there is a need for improvement of PET imaging in evaluations of AD and other dementias, using ^{18}F -FDG or other tracers. Recently, tracers specific for β -amyloid plaques, such as the Pittsburgh compound B (^{11}C -PiB) and ^{18}F -labeled amyloid tracers, florbetapir (previously known as atrioventricular [AV]-45), flutemetamol, and florbetaben (previously known as AV-1), have been developed and currently are in the late phase of clinical development.^[22] The accuracy of amyloid PET imaging is still a subject of investigations, but it is expected to be over 90% for patients under the age of 70 years.^[22] These developments strongly indicate that PET imaging seems to be the most promising tool in early noninvasive diagnosis, in guiding the effective treatment and in defining prevention strategies in patients with AD and other dementias. However, due to relatively poor spatial resolution, PET imaging often lacks anatomic information and position of the tracer concentration.

This latter fact has led to the development of combined PET-CT scanners^[23] and more recently, development of combined PET-MRI systems.^[24] One approach to improve PET images is to use synergistically multimodal PET-CT or PET-MRI information.^[25-27] The second and more common approach is based on the deconvolution of PET images with the point-spread function (PSF) of the scanner.^[7-9] However, the main problem in applying the deconvolution approaches is that they increase noise in restored images. The newly developed restoration Fourier-wavelet^[12-15] techniques have significantly suppressed noise without loss in resolution recovery. The third approach is to apply resolution recovery as a part of the image reconstruction process. However, the postprocessing approach used in the study has several advantages: It is affordable, doesn't require knowledge of the proprietary file structures of different PET/CT vendors and is fast and easily implemented on different PET/CT scanners, once the PSF has been obtained. The results in the study strongly indicate that the approach used is a step forward in improving PET AD imaging.

Conclusions

This study showed that the quality and quantification of 3D brain ^{18}F -FDG PET images can be significantly improved by Fourier-wavelet (WFT) restoration filtering and hence a more accurate and earlier diagnosis of AD by PET imaging could be achieved.

The full potential value of PET imaging in the evaluation of AD and other dementias awaits the development of an effective therapy to slow, halt, or reverse the disease process. Such a therapy will be most beneficial when given early, before dementia has developed. Development of new biomarkers such as amyloid imaging, improving PET technology, combining PET with CT and/or MRI and using better image processing techniques will hopefully make the development of these therapies feasible.

References

1. Fouquet M, Desgranges B, Landeau B, Duchesnay E, Mézenge F, de la Sayette V, *et al.* Longitudinal brain metabolic changes from amnesic mild cognitive impairment to Alzheimer's disease. *Brain* 2009;132:2058-67.
2. Mosconi L, Tsui WH, Herholz K, Pupi A, Drzezga A, Lucignani G, *et al.* Multicenter standardized ^{18}F -FDG PET diagnosis of mild cognitive impairment, Alzheimer's disease, and other dementias. *J Nucl Med* 2008;49:390-8.
3. Hammoud DA, Hoffman JM, Pomper MG. Molecular neuroimaging: From conventional to emerging techniques. *Radiology* 2007;245:21-42.
4. Drzezga A, Grimmer T, Riemenschneider M, Lautenschlager N, Siebner H, Alexopoulos P, *et al.* Prediction of individual clinical outcome in MCI by means of genetic assessment and (18) F-FDG PET. *J Nucl Med* 2005;46:1625-32.

5. PET-Working Group PET Working Group: NIH/NIA Neuroimaging Initiative; 2005. Available from: <http://www.nia.nih.gov/ResearchInformation/ExtramuralPrograms/NeuroscienceOfAging/Summary+%E2%80%93+PET+Working+Group.htm>. [Last accessed on 2012 Aug 16].
6. Sorenson JA, Phelps ME. Physics in Nuclear Medicine. 2nd ed. Philadelphia, Pa: W. B. Saunders Company; 1987. p. 435-6.
7. King MA, Schwinger RB, Penney BC, Doherty PW, Bianco JA. Digital restoration of indium-111 and iodine-123 SPECT images with optimized Metz filters. *J Nucl Med* 1986;27:1327-36.
8. Penney BC, King MA, Schwinger RB, Baker SP, Doherty PW. Modifying constrained least-squares restoration for application to single photon emission computed tomography projection images. *Med Phys* 1988;15:334-42.
9. Knešaurek K, Machac J. Improving 3D PET imaging by restoration: A phantom study. *Comput Med Imaging Graph* 2005;29:15-9.
10. Available from: <http://www.loni.ucla.edu/ADNI/2005>. [Last accessed on 2013 Jul 15].
11. Kinahan PE, Rogers JG. Analytic three dimensional image reconstruction using all detected events. *IEEE Trans Nucl Sci* 1989;NS-36:964-8.
12. Neelamani R, Choi H, Baranuik RG. ForWaRD. Fourier-wavelet regularized deconvolution for ill-conditioned systems. *Trans Signal Process* 2004;52:418-33.
13. Johnstone IM, Kerkyacharian G, Picard D, Raimondo M. Wavelet deconvolution in a periodic setting. *J R Stat Soc Ser B Methodol* 2004;66:547-73.
14. Kalifa J, Mallat S, Rouge B. Deconvolution by Thresholding in Mirror Wavelet Bases. 2003. Available from: <http://www.cmap.polytechnique.fr/~kalifa/DeconvMirr.pdf>. [Last accessed on 2013 Jul 15].
15. Jalobeanu A, Blanc-Féraud L, Zerubia J. Satellite image deblurring using complex wavelet packets. *Int J Comput Vision* 2003;51:205-17.
16. Knešaurek K, Machac J, Zhang Z. Early detection of Alzheimer's disease in PET/CT studies. *Eur J Nucl Med Mol Imaging* 2009;36 Suppl 2:S217.
17. Knešaurek K. Fourier-wavelets restoration in PET/CT brain studies. *Nucl Instrum Methods A* 2012;689:29-34.
18. Mikolajczyk K, Szabatin M, Rudnicki P, Grodzki M, Burger C. A JAVA environment for medical image data analysis: Initial application for brain PET quantitation. *Med Inform (Lond)* 1998;23:207-14.
19. Herholz K, Salmon E, Perani D, Baron JC, Holthoff V, Frölich L, *et al.* Discrimination between Alzheimer dementia and controls by automated analysis of multicenter FDG PET. *Neuroimage* 2002;17:302-16.
20. Bohnen NI, Djang DS, Herholz K, Anzai Y, Minoshima S. Effectiveness and safety of 18F-FDG PET in the evaluation of dementia: A review of the recent literature. *J Nucl Med* 2012;53:59-71.
21. Medicare National Coverage Determinations Manual: Part 4. Ch. 1. (Sections 200-310.1) –Coverage Determinations. Centers for Medicare and Medicaid Services Web site. Available from: http://www.cms.gov/manuals/downloads/ncd103c1_Part_4.pdf. [Last accessed on 2012 Aug 16].
22. Rowe CC, Villemagne VL. Brain amyloid imaging. *J Nucl Med* 2011;52:1733-40.
23. Beyer T, Townsend DW, Brun T, Kinahan PE, Charron M, Roddy R, *et al.* A combined PET/CT scanner for clinical oncology. *J Nucl Med* 2000;41:1369-79.
24. Pichler BJ, Judenhofer MS, Catana C, Walton JH, Kneilling M, Nutt RE, *et al.* Performance test of an LSO-APD detector in a 7-T MRI scanner for simultaneous PET/MRI. *J Nucl Med* 2006;47:639-47.
25. Zaidi H, Ruest T, Schoenahl F, Montandon ML. Comparative assessment of statistical brain MR image segmentation algorithms and their impact on partial volume correction in PET. *Neuroimage* 2006;32:1591-607.
26. Turkheimer FE, Boussion N, Anderson AN, Pavese N, Piccini P, Visvikis D. PET image denoising using a synergistic multiresolution analysis of structural (MRI/CT) and functional datasets. *J Nucl Med* 2008;49:657-66.
27. Boussion N, Hatt M, Lamare F, Rest CC, Visvikis D. Contrast enhancement in emission tomography by way of synergistic PET/CT image combination. *Comput Methods Programs Biomed* 2008;90:191-201.

How to cite this article: Knešaurek K. Improving ¹⁸F-Fluoro-D-Glucose-Positron Emission Tomography/Computed Tomography Imaging in Alzheimer's Disease Studies. *World J Nucl Med* 2015;14:171-7.

Source of Support: Nil, **Conflict of Interest:** None declared.