

Successful Intracascular Coil Embolization of Mycotic Pulmonary Artery Pseudoaneurysm Using the Balloon Remodeling Technique

Department of Radiology, Kansai Rosai Hospital, Japan

Hiroshi Yukimoto, Koji Mikami

Abstract

A 66-year-old man with ventricular septal defect was hospitalized for fever, dyspnea, and hemoptysis. Infectious endocarditis by *Streptococcus parasanguinis* was suspected. At 3 weeks after admission, massive hemoptysis suddenly occurred. Contrast-enhanced computed tomography showed a 2-cm aneurysmal formation in the right lower pulmonary artery. Rupture of a mycotic pulmonary artery pseudoaneurysm was diagnosed. Pulmonary angiography showed a wide-necked pseudoaneurysm at the trifurcation of the anterior, lateral, and posterior basal segmental arteries of the right lower lobe. Intracascular coil embolization with the balloon remodeling technique was successfully performed, preserving residual pulmonary function distal to the pseudoaneurysm.

Key words: mycotic pulmonary artery aneurysm, embolization, balloon remodeling technique

(Interventional Radiology 2022; 7: 104-108)

Introduction

Mycotic pulmonary artery aneurysm and pulmonary artery pseudoaneurysm (PAPA) are rare vascular abnormalities that can be life-threatening [1, 2]. These abnormalities are primarily caused by *Staphylococcus*, *Streptococcus*, or *Mycobacterium tuberculosis* infection. Previous treatment of mycotic PAPA has been with surgery or conservative management, although both have a high mortality rate [2, 3]. More recently, endovascular treatment (EVT) has largely replaced surgical approaches due to its lower invasiveness and greater safety, particularly in patients with life-threatening hemoptysis [2, 3]. This case report presents a patient with mycotic PAPA and associated infectious endocarditis of the mitral valve and ventricular septal defect (VSD) that was successfully treated by intracascular coil embolization with the balloon remodeling technique.

Case Report

A 60-year-old man with atrial fibrillation and untreated VSD presented with hemoptysis and respiratory failure and was transferred to the emergency department in our hospital. Plain computed tomography (CT) of the chest showed an infiltrative shadow in the right lower lung lobe. He was admitted for a detailed evaluation of pneumonia and bloody sputum. Blood cultures revealed an infection by *Streptococcus parasanguinis*. Transesophageal echocardiography revealed vegetation on the mitral valve and 4-mm membranous VSD with left-to-right shunt through the defect (peak velocity, 4.7 m/s; pressure gradient, 87 mmHg; pulmonary blood flow/systemic blood flow ratio, 1.67). Infectious endocarditis was suspected. Ampicillin sulbactam 3 g every 6 h and ceftriaxone 2 g every 24 h were administered for infectious endocarditis and pneumonia.

On hospital day 4, the bloody sputum disappeared. Bacteremia improved with antibiotic therapy, and pneumonia re-

solved as visualized on chest radiography. However, on hospital day 20, endotracheal intubation was performed due to severe hemoptysis (>100 mL) and respiratory failure. Blood pressure was 119/90 mm Hg, heart rate was 148 beats/min, body temperature was 36°C, and peripheral oxygen saturation was 92% (fraction of inspired oxygen, 65%). Laboratory tests showed these values: pH, 7.215; white blood cells, 8000/ μL ; red blood cells, $338 \times 10^4/\mu\text{L}$; hemoglobin, 9.9 g/dL; platelets, $616 \times 10^3/\mu\text{L}$; activated partial thromboplastin time, 38.0 s; prothrombin time, 13.1 s; fibrinogen, 490 mg/dL; D-dimer, 4.47 $\mu\text{g}/\text{mL}$; and C-reactive protein, 5.6 mg/

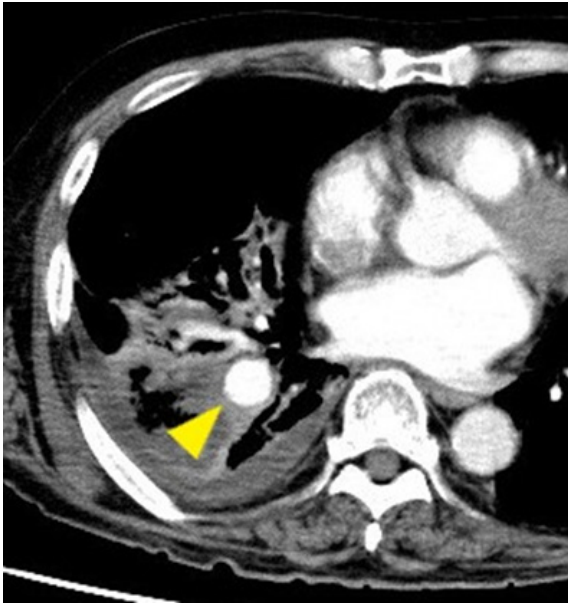


Figure 1. Contrast-enhanced computed tomography (CT) shows a 2-cm saccular aneurysm (arrowhead) in the right lower pulmonary artery.

dL. Contrast-enhanced CT of the chest revealed a 20-mm saccular aneurysm with an 8-mm wide neck at the trifurcation of the anterior, lateral, and posterior basal segmental arteries of the right lower lobe (**Fig. 1**). Previous CT and chest radiography revealed no aneurysms. Emergency pulmonary angiography and subsequent EVT were planned because the rupture of a mycotic PAPA was suspected.

A 6-Fr 90-cm guiding sheath (Destination, Terumo, Tokyo, Japan) was inserted in the right femoral vein to the main trunk of the right pulmonary artery. Pulmonary artery angiography revealed a wide-necked pseudoaneurysm at the trifurcation of the anterior, lateral, and posterior basal segmental arteries of the right lower lobe (**Fig. 2a**). Since rupture of the pseudoaneurysm during intrasaccular coil embolization was predicted, a 5.2-Fr, 100-cm balloon catheter (Selecon MP Catheter II, Terumo) was placed in the trunk of the right lower pulmonary artery, and EVT was performed under blood flow control. Intrasaccular coil embolization of the pseudoaneurysm was decided to preserve right lower lobe pulmonary function. A 2.7-/2.9-Fr, 150-cm microcatheter (Excelsior XT-27, Stryker, Kalamazoo, MI, USA) was inserted through the balloon catheter into the pseudoaneurysm sac, which was embolized using 15 detachable microcoils: 11 Target XXL (Stryker) (24 mm \times 50 cm [3 coils], 22 mm \times 50 cm [1 coil], 18 mm \times 50 cm [1 coil], 8 mm \times 40 cm [1 coil], 6 mm \times 40 cm [2 coils], 6 mm \times 30 cm [1 coil], and 6 mm \times 20 cm [2 coil]) and 4 Penumbra POD Packing Coils (Penumbra, Alameda, CA, USA (60 cm [2 coils], 30 cm [1 coil])). In the final stage of the embolization, the balloon catheter tip was located at the wide neck of the mycotic pseudoaneurysm (**Fig. 3**). The balloon was temporarily inflated in front of the aneurysm neck during coil placement. Pulmonary angiography after intrasaccular coil embolization confirmed the disappearance of blood flow in

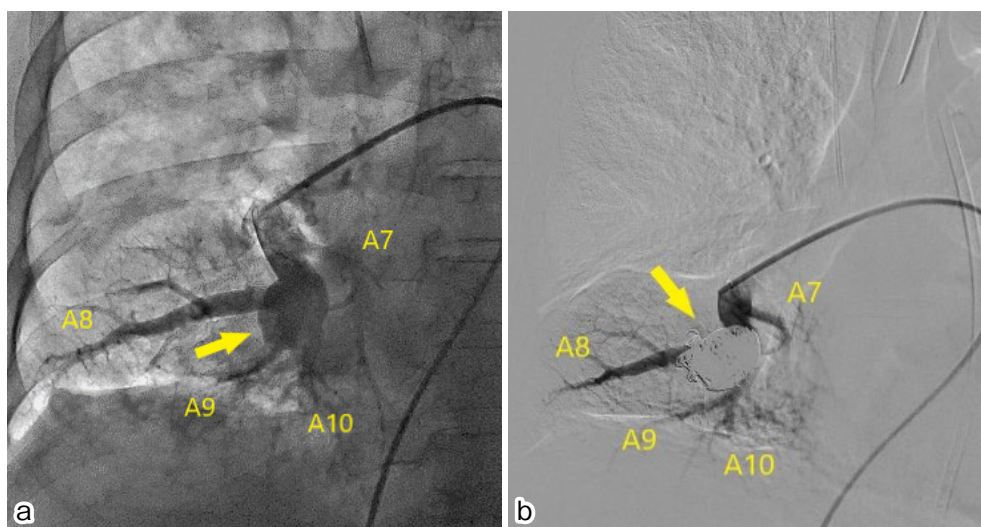


Figure 2. a) Angiography of the right lower pulmonary artery shows a pseudoaneurysm (arrow) located at the trifurcation of the anterior, lateral, and posterior basal segmental arteries of the right lower lobe. b) Digital subtraction angiography after coil packing of the pseudoaneurysm sac shows no inflow of contrast medium into the pseudoaneurysm while maintaining patency of the basal segmental pulmonary arteries.

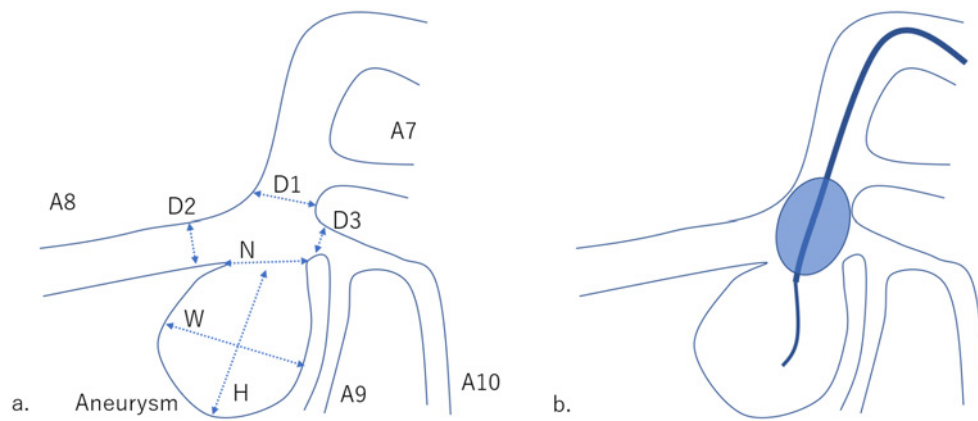


Figure 3. Anatomic and morphologic schema of pseudoaneurysm. a) Lines H, W, and N indicate height, width, neck of pseudoaneurysm: H, 24 mm; W, 20 mm; N, 8 mm. Lines D1, D2, and D3 indicate the diameter of the trunk of lower pulmonary artery, the anterior basal segmental artery and trunk of the lateral basal segmental artery and posterior basal segmental artery: D1, 8.6 mm; D2, 8.3 mm; D3, 3.8 mm. b) A balloon catheter was placed in front of the aneurysm neck to control blood flow and protect the parent artery and side-branching arteries during coil embolization.

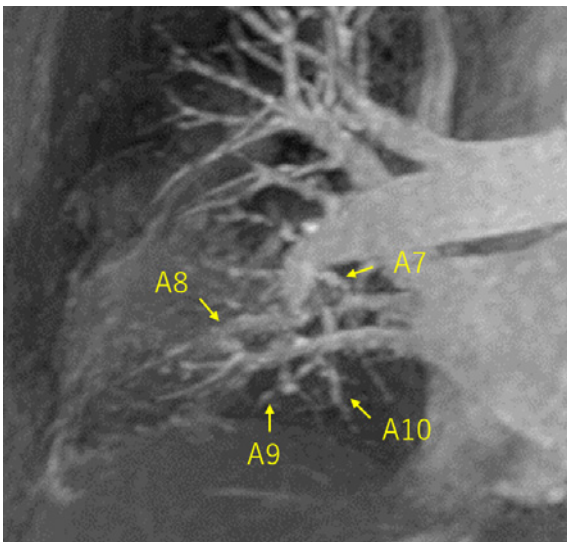


Figure 4. Maximum-intensity projection (MIP) image from time-resolved contrast-enhanced MRA shows patency of the peripheral right lower pulmonary artery.

the pseudoaneurysm and preservation of the distal right lower pulmonary artery (Fig. 2b).

After embolization, ampicillin sulbactam 3 g every 8 h and ceftriaxone 2 g every 24 h were administered for 7 days. The ceftriaxone was then stopped because of allergy; the ampicillin sulbactam 3 g every 8 h was continued, and levofloxacin 500 mg every 24 h was initiated and administered for the next 7 days, for a total of 2 weeks of ampicillin sulbactam administration.

At 3 weeks after embolization, contrast-enhanced magnetic resonance angiography (MRA) (time-resolved imaging of contrast kinetics imaging method; GE Healthcare, Chicago, IL, USA) confirmed the loss of blood flow in the pseudoaneurysm (Fig. 4). The bloody sputum then rapidly disappeared, and the patient was discharged 25 days after

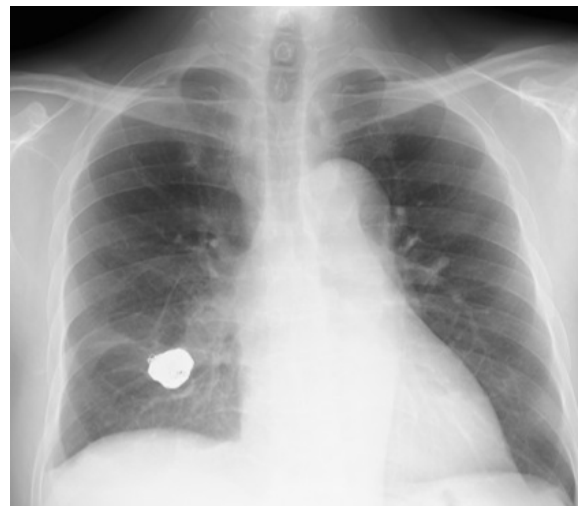


Figure 5. Chest radiography 6 months after intrasaccular coil embolization shows no coil compaction and migration.

embolization. At 6-month outpatient follow-up, successful embolization was confirmed without coil migration or compaction on chest radiography (Fig. 5) and without hemoptysis recurrence.

Discussion

A major predisposing factor for the development of a mycotic PAPA is endocarditis, which is commonly caused by suppurative bacterial infections such as *Staphylococci* and *Streptococci* or fungi, including *Candida* and *Aspergillus* [1-3]. Mycotic PAPA can develop by two pathways: (1) hematogenous spread of infectious microemboli into the vasa vasorum and (2) involvement of the pulmonary artery from an adjacent source of sepsis [1]. This infectious arteritis destroys the arterial wall with a subsequent contained rupture and aneurysmal formation; pseudoaneurysms can

then rapidly develop or enlarge.

Guidelines for the treatment of mycotic PAPA have not yet been established. The prognosis for mycotic PAPA without interventional treatment is poor with mortality rates of 40%-82% due to rupture [1], and therefore either surgical treatment or EVT is needed [2, 3]. In addition, the standard management of infectious aneurysms includes prolonged intravenous antibiotic therapy, similar to that used for endocarditis [4]. Therefore, embolization with coils for infectious aneurysm has a potential risk of aggravation of infection. However, in our case, we performed intrasaccular coil embolization because the infection was controlled. If the local infection is uncontrolled, surgical treatment can be the best option rather than EVT. Surgical treatments, including lobectomy, aneurysm, and partial lung resection, have been previously performed, depending on the location of the lesion.

Compared with surgery, EVT is less invasive and has recently been described as a first-line treatment method [2, 3]. The procedure is performed based on four PAPA types classified by Shin et al. according to the pattern of blood supply [5]. Type A PAPA has a patent feeding pulmonary artery without substantial bronchopulmonary shunting. Type B PAPA has stenosis of a feeding pulmonary artery or reversed flow in the feeding pulmonary arteries due to a bronchopulmonary shunt. Type C PAPA has an occluded feeding pulmonary artery and bronchial and non-bronchial systemic collateral arteries that play a role in the blood supply to PAs via a bronchopulmonary shunt. Type D PAPA has an occluded feeding pulmonary artery and a slow systemic pulmonary artery shunt. For type A or B PAPA, embolization via the bronchial and pulmonary arteries is effective. For type C or D PAPA, embolization of bronchial and non-bronchial systemic collateral arteries seems to be effective.

Furthermore, based on the anatomic information of PAPA, pulmonary artery embolization is performed by three methods: *feeding artery embolization*, *proximal-to-distal artery embolization* (the sandwich technique), and *intrasaccular embolization* (the sac-packing technique) [6]. The neck width of the pseudoaneurysm relative to the parent artery diameter is the determining factor for the choice of the embolization method [6]. In our case, a wide-necked pseudoaneurysm at the trifurcation of the anterior, lateral, and posterior basal segmental arteries of the right lower lobe was found on nonselective pulmonary angiography. Based on the PAPA classification, our patient had type A PAPA. In such a case, embolization only of the parent pulmonary artery will lead to incomplete embolization or recurrence due to retrograde filling from the bronchopulmonary shunt. Embolization of the parent pulmonary artery and the bronchial artery are required [5, 7]. However, embolization of three basal segmental pulmonary arteries with the sandwich technique and bronchial artery embolization may be more invasive for patients with VSD because the embolization could result in deterioration of respiratory function [3], and reduction of extensive pulmonary artery beds could lead to right

heart strain. Therefore, intrasaccular coil embolization of the pseudoaneurysm was considered useful for controlling hemoptysis and maintaining respiratory function [8]. Gilman et al. reported that 11 pseudoaneurysms in 12 patients treated with EVT were successfully treated by sac-packing coil embolization and 1 patient developed immediate recurrent hemorrhage [9].

Intrasaccular coil embolization is an effective method that maintains blood flow in the peripheral pulmonary arteries, but it must be performed with great caution due to the risk for rupture. Intrasaccular coil embolization is usually performed on saccular pseudoaneurysms with a narrow neck and in wide-necked pseudoaneurysms, such as in our case. An increased tendency for embolic material migration has been reported with intrasaccular coil embolization [6]. To overcome this potential complication, a successful approach is to perform intrasaccular coil embolization using the balloon remodeling technique, which can prevent coil movement during the procedure. In this case, a 5.2-Fr balloon catheter (9-mm balloon) was used for the balloon remodeling technique. However, if the balloon size were insufficient for a specific case, a 6-Fr balloon catheter (13-mm balloon) could be useful. If the pseudoaneurysm ruptured during the procedure, a better approach may be to embolize PAPA immediately by using the isolation technique.

Follow-up examinations after successful coil embolization are important to detect residual blood flow in the sac. The usefulness of time-resolved contrast-enhanced MRA has been reported for evaluating residual blood flow and recurrence of an aneurysm or pseudoaneurysm after coil embolization with the sac-packing technique [10]. In our case, time-resolved contrast-enhanced MRA confirmed the absence of residual blood flow in the pseudoaneurysm after intrasaccular coil embolization. Furthermore, it is important to confirm on chest radiography that coil compaction or migration has not occurred. As in this case, follow-up chest radiography 6 months after intrasaccular coil embolization confirmed that no coil compaction or migration had occurred.

Intrasaccular coil embolization with the balloon remodeling technique was successfully performed for a patient with mycotic PAPA associated with infectious endocarditis and VSD while preserving peripheral pulmonary artery blood flow. In such cases, intrasaccular coil embolization with the balloon remodeling technique may offer a safe, less-invasive treatment with the persistence of pulmonary function. However, intrasaccular coil embolization for mycotic PAPA should be performed with great caution due to the risk for rupture.

Conflict of Interest: None

Author Contribution: All authors revised the manuscript, approved the manuscript to be published, and agree to be accountable for all aspects of the work in ensuring that questions related to the accuracy or integrity of any part of the work are appropriately investigated and resolved.

Informed Consent: Informed consent was obtained from the patient for submission of this case report.

References

1. Bartter T, Irwin RS, Nash G. Aneurysms of the pulmonary arteries. *Chest*. 1988; 94: 1065-1075.
2. Benveniste O, Bruneel F, Bedos JP, et al. Ruptured mycotic pulmonary artery aneurysm: an unusual complication of right-sided endocarditis. *Scand J Infect Dis*. 1998; 30: 626-629.
3. Park HS, Chamarthy MR, Lamus D, Saboo SS, Sutphin PD, Kalva SP. Pulmonary artery aneurysms: diagnosis & endovascular therapy. *Cardiovasc Diagn Ther*. 2018; 8: 350-361.
4. Torpey E, Spears J, Saiegh YA, Roeser M. A conservative approach to a large mycotic pulmonary pseudoaneurysm. *Case Rep Pulmonol*. 2021; doi:10.1155/2021/6456216.
5. Shin S, Shin TB, Choi H, et al. Peripheral pulmonary arterial pseudoaneurysms: therapeutic implications of endovascular treatment and angiographic classifications. *Radiology*. 2010; 256: 656-664.
6. Madhusudhan KS, Venkatesh HA, Gamanagatti S, Garg P, Srivastava DN. Interventional radiology in the management of visceral artery pseudoaneurysms: a review of techniques and embolic materials. *Korean J Radiol*. 2016; 17: 351-363.
7. Sbrano H, Mitchell AW, Ind PW, Jackson JE. Peripheral pulmonary artery pseudoaneurysms and massive hemoptysis. *AJR*. 2005; 184: 1253-1259.
8. Davidoff AB, Udoff EJ, Schonfeld SA. Intraaneurysmal embolization of a pulmonary artery aneurysm for control of hemoptysis. *AJR*. 1984; 142: 1019-1020.
9. Chen Y, Gilman MD, Humphrey KL, et al. Pulmonary artery pseudoaneurysms: clinical features and CT findings. *AJR*. 2017; 208: 84-91.
10. Kurosaka K, Kawai T, Shimohira M, et al. Time-resolved magnetic resonance angiography for assessment of recanalization after coil embolization of visceral artery aneurysms. *Pol J Radiol*. 2013; 78: 64-68.

Interventional Radiology is an Open Access journal distributed under the Creative Commons Attribution-NonCommercial 4.0 International License. To view the details of this license, please visit (<https://creativecommons.org/licenses/by-nc/4.0/>).