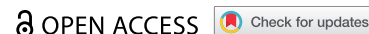





CASE REPORT



Non-alcoholic Wernicke's encephalopathy: toxic ingestion or an honest mis- steak?

Salahuddin Nasir ^a, Moustafa Abou Arede ^b, Elise L. Ma ^b, Robert D. Chow^b, Avelino Verceles^c
and Carol Chiung-Hui Peng ^b

^aAmerican University of Antigua, College of Medicine, Osbourn, Antigua and Barbuda; ^bDepartment of Medicine, University of Maryland Medical Center Midtown Campus, Baltimore, Maryland, USA; ^cDivision of Pulmonary, Critical Care, and Sleep Medicine, University of Maryland School of Medicine, Baltimore, Maryland, USA

ABSTRACT

A 21-year-old male presented with a 2-week history of nausea and non-bloody, non-bilious vomiting, accompanied by diffuse chronic myalgia. The patient endorsed headaches, dizziness, and diplopia that had started one day prior to admission. The patient had consumed a meat-only diet for the prior year. The patient was found to have a high anion gap metabolic acidosis with a superimposed normal anion gap metabolic acidosis in the setting of a several-month history of ingesting multiple naturopathic substances as well as recent use of disulfiram for management of his chronic myalgia. Magnetic resonance imaging (MRI) of the brain demonstrated symmetric hyperintensity involving bilateral thalami, periventricular regions, putamina, pons and medulla, with sparing of the mammillary bodies, consistent with Wernicke's encephalopathy (WE). The patient was treated with intravenous thiamine, a balanced nutritional diet, and hydration. Over the ensuing four days, his metabolic derangements resolved and a repeat MRI demonstrated significantly decreased FLAIR signal abnormality.

ARTICLE HISTORY

Received 30 June 2020
Accepted 23 October 2020

KEYWORDS

Wernicke encephalopathy;
Wernicke's syndrome;
Thiamine; Diet; High-protein

1. Introduction



Wernicke's encephalopathy (WE) is a condition that classically presents with the triad of ophthalmoplegia, gait ataxia, and altered mental state. WE is usually caused by thiamine deficiency, most commonly associated with chronic alcohol abuse[1]. Although alcohol is the most common cause, non-alcoholic etiologies are rare and can be easily missed. Low levels of intracellular thiamine are believed to cause a relative cellular energy deficit, which, if discovered early, is reversible with nutritional supplementation [2]. To account for the selective loss of neurons found in thiamine deficiency, numerous mechanisms have been proposed: cerebral energy dysfunction, breakdown of the blood-brain barrier, N-methyl-D-aspartate receptor-mediated excitotoxicity, increased free radical production, and induction of oxidative stress[2]. In WE of all etiologies, magnetic resonance imaging (MRI) brain typically shows symmetric signal intensity abnormalities in the thalami, periventricular regions, and periaqueductal areas [3,4]. Thiamine is not only an essential coenzyme in carbohydrate metabolism but it is also an osmotic gradient regulator [5]. Zuccoli et al. speculate that the osmotic gradient in the affected regions is strictly related to physiological levels of thiamine

concentration, and its deficiency may lead to early symmetric metabolic breakdown, as evidenced by MR findings[6]. We present the case of a young adult male who manifested symptoms of WE without significant alcohol ingestion history. However, he ingested a peculiar diet that led to severe metabolic derangements consistent with non-alcoholic WE.

2. Case report

A 21-year-old male presented to the hospital with a two-week history of nausea and non-bloody, non-bilious vomiting, and one day of headaches, dizziness, and double vision. His past medical history was significant for post-Lyme syndrome, chronic pain, subclinical hypothyroidism managed with levothyroxine, and Raynaud's phenomenon.

The patient stated that he was in his usual state of health until about two weeks prior to presentation, when he began feeling nauseous. He reported three to four episodes of clear, non-bloody, non-bilious vomiting over those two weeks. The patient also endorsed increased loose, watery bowel movements for four days prior to admission. The patient denied abdominal pain or cramping, except for chronic muscular abdominal pain, which was his baseline. The patient also complained of double vision, which was

CONTACT Carol Chiung-Hui Peng  carolpeng98@gmail.com  Department of Internal Medicine, University of Maryland Medical Center Midtown Campus, Baltimore, MD 21201, USA

© 2020 The Author(s). Published by Informa UK Limited, trading as Taylor & Francis Group on behalf of Greater Baltimore Medical Center. This is an Open Access article distributed under the terms of the Creative Commons Attribution-NonCommercial License (<http://creativecommons.org/licenses/by-nc/4.0/>), which permits unrestricted non-commercial use, distribution, and reproduction in any medium, provided the original work is properly cited.

fluctuating and worse with lateral gaze bilaterally. Finally, he experienced gait imbalance over the past week, but had not fallen. The patient denied any weakness, swelling, or paresthesias in any of his extremities.

The patient has had ill-defined chronic myalgia for the prior six years, for which he was prescribed pain medications and a multitude of naturopathic medications. These include Kratom (1 teaspoon daily), Chinese skullcap tinctures (1/2 teaspoons TID), Cortyceps tinctures (1/2 teaspoons TID), and Sida Acuta tinctures (1/2 teaspoons TID). He stated that he stopped using these supplements 6 weeks prior to admission, and instead took disulfiram 500 mg/day which was prescribed as an experimental treatment by one outside provider. Four days prior to admission, the provider reduced the dose of disulfiram to 250 mg/day.

On initial examination, the vital signs were temperature of 98.9 F (37.2 C), heart rate 88, blood pressure 116/61, respiratory rate 18, and SPO2 100%. The patient was oriented to person, place, and time. He appeared cachectic, with a BMI of 18.3. The patient's pupils were equal at 7 mm, round and reactive to light, without scleral icterus. There was visible horizontal diplopia at near distance that resolved with the covering of either eye. Saccades were noted on rapid lateral gaze. There was no pain with extraocular movements. The patient's cardiovascular and pulmonary examinations were unremarkable, except for a bluish discoloration in the nail beds bilaterally. The abdomen was only significant for mild tenderness on deep palpation of the right lower quadrant, without rebound or guarding. Dysmetria was evident on heel to shin testing; however, the patient was unable to tolerate gait assessment. Examination of the skin revealed a non-tender, nonpruritic, maculopapular rash without erythema on the back of his neck and abdomen.

The significant initial laboratory tests are listed in Table 1. Urine toxicology was negative for opiates and illicit substances of abuse. The urinalysis was positive for 2+ protein and 2+ ketones as well as

11–25 RBCs. The patient was managed with antiemetics and intravenous fluids, with careful consideration of osmolar gap and hemodynamic stability. Because of his visual symptoms, an MRI of the brain was pursued. T2/FLAIR MR imaging demonstrated symmetric hyperintensity involving the bilateral medial aspects of the thalami, periventricular regions, posterior aspects of the putamina, posterior pons, and medulla, but spared the mammillary bodies (Figure 1A,1C). These findings are most consistent with the metabolic derangements seen in WE.

The patient's meat-only diet, which lacked many key nutritional components, raised the suspicion for WE. The patient was started on intravenous thiamine, folate, multivitamin, and nutritional supplements, along with adequate carbohydrates and intravenous fluids for the treatment of WE and other potential nutritional deficiencies. An eye patch provided relief of visual symptoms. Over the ensuing several days, the patient's metabolic derangements improved; by day four, the anion gap was nine and bicarbonate level 25 mmol/L. Repeat MRI of brain showed significant decreased FLAIR signal abnormality involving the dorsal medial thalami and periaqueductal gray matter with near resolution of signal abnormality in the posterior putamina and dorsal brainstem (Figure 1B, 1D). Concurrent with the metabolic improvements, the patient also noted amelioration of his symptoms of headache, nausea, vomiting, and visual disturbances, including nystagmus and horizontal diplopia.

The patient was extensively counselled on the importance of a balanced diet and on the harms of an all-meat diet lacking vital nutrients. This case illustrates how a prolonged all-meat diet lacking key nutritional supplements can incite a severe metabolic derangement with imaging findings consistent with WE. Furthermore, the patient's symptoms and MRI brain findings were easily corrected with initiation of proper nutrition and fluids.

3. Discussion

Our case demonstrated a rare case of non-alcoholic Wernicke's encephalopathy (WE) caused by a meat-only diet that was completely reversed after proper nutritional supplementation.

WE was first described in 1881 by the German neurologist Carl Wernicke as a condition presenting with mental disturbance, impairment of memory and disorientation, ataxia and nystagmus, peripheral neuropathy, and reduced tendon reflexes [7]. Subsequently, most reported cases in the USA were related to chronic alcohol ingestion [8]. Non-alcoholic WE is rare, but several cases have also been reported. A multicenter observational study in 2017 found that though there is significant

Table 1. Initial laboratory tests.

Initial Laboratory Values	
pH (venous)	7.26
pCO ₂ (venous)	24 mmHg
Anion Gap	28
Bicarbonate	8 mEq/L
Chloride	110 mEq/L
Lactate	1.6 mmol/L
Serum Total Protein	10.5 g/dL
Albumin	5.1 g/dL
WBC count	2800/mcL
Hemoglobin	18.5 g/dL
Hematocrit	51.9%
Platelets	117/mcL
Serum CK	44 U/L
TSH	4.43 mU/L
T4	0.96 ug/dL

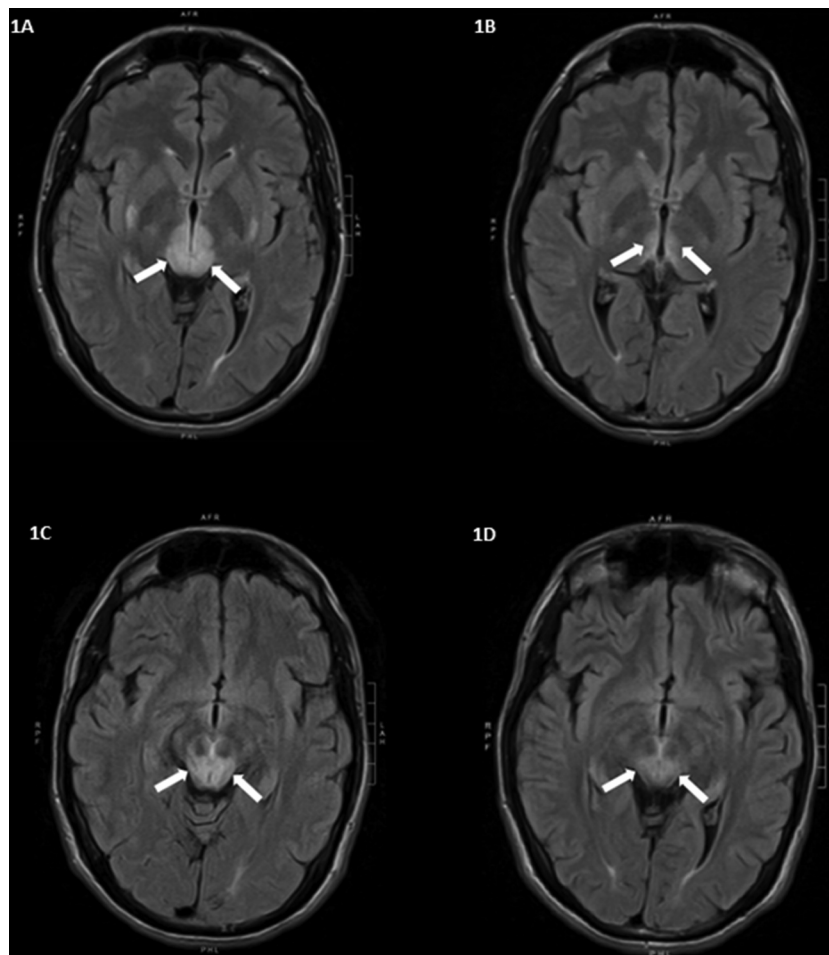


Figure 1. Comparison of signal intensity in brain magnetic resonance imaging before and after treatment with intravenous thiamine. Arrows on Figure 1A and 1B, pointed to the thalami and on Figure 1C and 1D, the arrows pointed to the midbrain. After treatment with intravenous thiamine, Figure 1B and 1D showed a significant reduction in signal intensity in magnetic resonance imaging in these regions, compared to Figure 1A and 1C, respectively.

overlapping symptomatology, non-alcoholic WE tends to present with fewer cerebellar symptoms, more ocular symptoms, and hypertension, in comparison to alcoholic WE [9]. Furthermore, those investigators found that cortico-subcortical atrophy to be more prevalent in alcoholic WE patients [9]. Interestingly, the non-alcoholic WE patients were more likely to have the typical lesions expected on MRI than alcoholic WE [9]. Finally, this study also included metabolic differences, noting that alcoholic WE patients had a higher frequency of hyponatremia [9]. A report by Fei et al. reviewed the radiological findings in 12 cases of patients with non-alcoholic WE, 5 of whom had initial CNS symptoms of dizziness, 3 had unsteadiness, and one had diplopia, symptoms all experienced by our patient [10]. The MR imaging for patients in this case series was significant for signal intensity in bilateral medial thalami, the capita of the caudate nucleus, around the third ventricle and periaqueductal regions, typical of WE and consistent with our case [10]. Their report found that most patients who presented with mild coma or lethargy exhibited features of symmetric

brain periventricular damage [10]. They also noted that those who did not present in deep coma or cortical damage recovered with treatment and had resolution of abnormal hyperintense signal intensity on T2-weighted and fluid-attenuated inversion recovery images within 2 weeks to 1 year after thiamine supplementation [10]. Though dietary requirement for thiamine is only 1 mg to 2 mg daily, treatment guidelines for WE include administration of intravenous or intramuscular thiamine 500 mg three times daily for two consecutive days, followed by 5 days of intravenous or intramuscular thiamine 250 mg once daily, and continued with oral thiamine supplements of 100 mg daily [11]. Furthermore, it is important to administer the thiamine prior to supplementation with glucose as glucose can worsen the thiamine deficit in the brain leading to worsening of neurological symptoms [11].

Given the patient's restricted diet, we could not rule out if the patient had concomitant nutritional deficiencies besides thiamine. According to the nutrition fact lists from the official website of Asia Pacific Journal of Clinical Nutrition, certain meats such as pork and fish,

do contain thiamine, but the levels per 100 g of these meats are much lower than the daily needed value of 1 mg to 2 mg [12]. Common vitamin deficiencies in a meat-only diet can include Vitamin A, Vitamin C, Vitamin E, and Vitamin K [13]. Therefore, he was also treated with multivitamin along with thiamine during hospitalization. The patient also presented with several dermatologic findings as well as microscopic hematuria, which were not related to thiamine deficiency. However, these symptoms could potentially be explained by his use of the herbal supplement, such as Chinese Skullcap, as it was reported to be related to some skin, digestive, and renal side effects [14].

When patients present with symptoms and signs of WE in the absence of alcohol use, exploring the details of patients' diet may help diagnose non-alcoholic WE. For example, nutritional deficiencies caused by ice-cream only diet or liquid-only diet were reported to cause non-alcoholic WE [15,16]. Other causes of non-alcoholic WE due to nutritional deficiencies include acquired immunodeficiency syndrome, bariatric surgery, cancer, hyperemesis gravidarum, inflammatory bowel disease, parenteral nutrition administration, renal disease with dialysis, starvation, and fasting [16]. Hepatic damage caused by the use of ataractics with further decreased nutrient absorption can also precipitate non-alcoholic WE [7].

Another case report detailed the development of non-alcoholic WE, even with thiamine supplementation, in the setting of a drastic slimming diet primarily consisting of meat [17]. That diet is similar to the diet used by our patient but was not as severe, as it did also consist of small portions of other food groups. To our knowledge, there has been no other case of non-alcoholic WE caused by a meat-only diet documented in the literature.

Thiamine is a water-soluble vitamin that is essential to energy metabolism. The body's thiamine stores can be depleted without supplementation within 3 to 6 weeks. The average requirement per day is 1.0–2.0 mg of thiamine, which can be found through a variety of dietary sources, including vegetables and fruits [18]. It is becoming increasingly important to be aware of non-alcoholic WE as a potential consequence of fad-diets, which have been construed to yield a variety of benefits, including management of mood disorders, diabetes, arthritis, and weight loss. Fortunately, based on the published cases [4,7,10,15,17] as well as our case, early diagnosis and initiation of nutritional support are able to correct the nutritional imbalance and reverse the adverse neurological consequences [19]. A thiamine serum measurement is not required to make this diagnosis as it is a clinical diagnosis made using the presenting symptomatology. A delay in diagnosis and treatment, however, can result in prolonged metabolic derangement,

leading to irreversible brain damage with short-term memory loss, termed Korsakoff's psychosis [2].

4. Conclusion

This case report featured a rare case of non-alcoholic WE caused by a meat-only diet. Complete remission without permanent neurological damage can be achieved with prompt balanced nutritional support, as was observed in our patient.

5. Consent

Written consent for publication has been obtained from the patient.

Disclosure statement

The author(s) declared no potential conflicts of interest with respect to the research, authorship, and/or publication of this article.

Funding

The author(s) received no financial support for the research, authorship, and/or publication of this article.

ORCID

Salahuddin Nasir  <http://orcid.org/0000-0002-2972-2934>
Moustafa Abou Areeda  <http://orcid.org/0000-0002-1867-6741>

Elise L. Ma  <http://orcid.org/0000-0003-4662-2262>

Carol Chiung-Hui Peng  <http://orcid.org/0000-0003-2352-6374>

References

- [1] Harper C, Fornes P, Duyckaerts C, et al. An international perspective on the prevalence of the Wernicke-Korsakoff syndrome. *Metab Brain Dis.* 1995;10(1):17–24.
- [2] Thomason AD, Marshall EJ. The natural history and pathophysiology of Wernicke's Encephalopathy and Korsakoff's Psychosis. *Alcohol Alcohol.* 2006;41(2):151–158.
- [3] Zuccoli G, Pipitone N. Neuroimaging findings in acute Wernicke's encephalopathy: review of the literature. *AJR Am J Roentgenol.* 2009;192(2):501–508.
- [4] Guler A, Alpaydin S, Sirin H, et al. A non-alcoholic Wernicke's encephalopathy case with atypical MRI findings: clinic versus radiology. *Neuroradiol J.* 2015;28(5):474–477.
- [5] Schroth G, Wichmann W, Valavanis A. Blood-Brain-Barrier Disruption in Acute Wernicke Encephalopathy. *Journal of Computer Assisted Tomography.* 1991;15(6):1059–1061.
- [6] Zuccoli G, Gallucci M, Capellades J, et al. Wernicke encephalopathy: MR findings at clinical presentation in twenty-six alcoholic and nonalcoholic patients. *AJNR Am J Neuroradiol.* 2007;28(7):1328–1331.

- [7] Gui QP, Zhao WQ, Wang LN. Wernicke's encephalopathy in nonalcoholic patients: clinical and pathologic features of three cases and literature reviewed. *Neuropathology*. 2006;26(3):231–235.
- [8] Sinha S, Kataria A, Kolla BP, et al. Wernicke Encephalopathy-Clinical Pearls. *Mayo Clin Proc*. 2019;94(6):1065–1072.
- [9] Chamorro AJ, Rosón-Hernández B, Medina-García JA, et al. Differences between alcoholic and nonalcoholic patients with Wernicke encephalopathy: a multicenter observational study. *Mayo Clin Proc*. 2017;92(6):899–907.
- [10] Fei GQ, Zhong C, Jin L, et al. Clinical characteristics and MR imaging features of nonalcoholic Wernicke encephalopathy. *AJNR Am J Neuroradiol*. 2008;29(1):164–169.
- [11] Cook CC, Hallwood PM, Thomson ADB. Vitamin deficiency and neuropsychiatric syndromes in alcohol misuse. *Alcohol Alcohol*. 1998;33(4):317–336.
- [12] B1 thiamine - water soluble vitamins. [cited 2020 Oct 6]. <http://apjcn.nhri.org.tw/server/info/books-phds/books/foodfacts/html/data/data4a.html>.
- [13] Daley CA, Abbott A, Doyle PS, et al. A review of fatty acid profiles and antioxidant content in grass-fed and grain-fed beef. *Nutr J*. 2010;9:10.
- [14] Zeng ZP, Jiang JG. Analysis of the adverse reactions induced by natural product-derived drugs. *Br J Pharmacol*. 2010;159(7):1374–1391.
- [15] Pugh G, Iqbal H, Bramall J. Suspected dietary-related Wernicke's encephalopathy. *J Intensive Care Soc*. 2019;20(3):274–276.
- [16] Hutcheon DA. Malnutrition-induced Wernicke's encephalopathy following a water-only fasting diet. *Nutr Clin Pract*. 2015;30(1):92–99.
- [17] Sechi G, Serra A, Pirastru MI, et al. Wernicke's encephalopathy in a woman on slimming diet. *Neurology*. 2002;58(11):1697–1698.
- [18] Graham, D., & Lantos, P. L. (2002). *The Wernicke-Korsakoff Syndromes*. *Greenfield's Neuropathology*, 7th ed, Vol. Arnold. London, p352-357, p455-457.
- [19] McCormick LM, Buchanan JR, Onwuameze OE, et al. Beyond alcoholism: Wernicke-Korsakoff syndrome in patients with psychiatric disorders. *Cogn Behav Neurol*. 2011;24(4):209–216.