

Available online at www.sciencedirect.com

ScienceDirect

journal homepage: <http://Elsevier.com/locate/radcr>

Case Report

Pancreatic lipoma with a solid nodule mimicking invasion from adjoining intraductal papillary mucinous neoplasm

Yoko Namiki MD^{a,*}, Eriko Maeda MD, PhD^a, Wataru Gono MD, PhD^a,
Nobuhisa Akamatsu MD, PhD^b, Masako Ikemura MD, PhD^c, Kuni Ohtomo MD, PhD^a

^a Department of Radiology, Graduate School of Medicine, The University of Tokyo, 7-3-1 Hongo, Bunkyo-ku, Tokyo 113-8655, Japan

^b Department of Hepatobiliary Surgery, Artificial Organ and Transplantation, Graduate School of Medicine, The University of Tokyo, 7-3-1 Hongo, Bunkyo-ku, Tokyo 113-8655, Japan

^c Department of Pathology, Graduate School of Medicine, The University of Tokyo, 7-3-1 Hongo, Bunkyo-ku, Tokyo 113-8655, Japan

ARTICLE INFO

Article history:

Received 15 December 2015

Accepted 28 February 2016

Available online 4 April 2016

Keywords:

Lipoma

Pancreas

Intraductal papillary mucinous neoplasm

Liposarcoma

Pancreatic tumor

Hamartoma

ABSTRACT

A 74-year-old man was referred to our hospital for a mass in the pancreatic head found during screening chest computed tomography. Contrast computed tomography showed a 5-cm multicystic mass with an irregular border containing a solid component showing contrast enhancement. Caudal to this mass, a 5-cm solid mass of fat density with a nodular soft-tissue component was found. Cytology of the aspirated pancreatic fluid revealed malignant cells, and surgery was performed for suspected intraductal papillary mucinous carcinoma. Pathologic analysis of the resected specimen revealed a collision tumor of intraductal papillary mucinous neoplasm (IPMN) with high-grade dysplasia and pancreatic lipoma. The soft-tissue component within the lipoma was a nodule consisting of pancreatic tissue with inflammatory infiltration and hyalinization and was not associated with IPMN invasion.

Copyright © 2016, the Authors. Published by Elsevier Inc. under copyright license from the University of Washington. This is an open access article under the CC BY-NC-ND license (<http://creativecommons.org/licenses/by-nc-nd/4.0/>).

Introduction

Although many reports of gastrointestinal tract lipoma appear in the literature, pancreatic lipoma is rare. The first report of pancreatic lipoma, published in 1989 by Bigard, has been followed by only about 50 similar reports [1,2]. Pancreatic lipomas are visualized in images as smooth masses of fat density that are histologically segmented from the pancreatic parenchyma by a thin, fibrous membrane. The actual prevalence of pancreatic lipomas is unknown, because small

pancreatic lipomas are difficult to differentiate from fat infiltration of the pancreatic parenchyma. Even when a distinct pancreatic lipoma is diagnosed on imaging, it is generally followed by further imaging and is rarely resected.

Intraductal papillary mucinous neoplasm (IPMN) is a pancreatic neoplasm characterized by papillary proliferation of intraductal mucin-producing epithelium. The disease mainly affects the elderly, with increasing numbers of cases reported because of the increased use of imaging examinations. IPMNs are classified into 3 categories depending on the

Competing Interests: The authors have declared that no competing interests exist.

* Corresponding author.

E-mail address: namiki-sim@umin.ac.jp (Y. Namiki).
<http://dx.doi.org/10.1016/j.radcr.2016.02.017>

1930-0433/Copyright © 2016, the Authors. Published by Elsevier Inc. under copyright license from the University of Washington. This is an open access article under the CC BY-NC-ND license (<http://creativecommons.org/licenses/by-nc-nd/4.0/>).

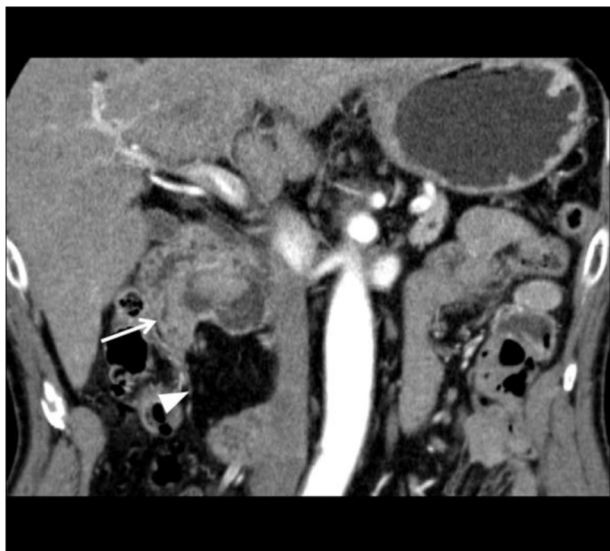


Fig. 1 – Contrast CT of the abdomen in the coronal view. The mass consists of an IPMN-like lesion (arrow) and a lipomatous lesion (arrowhead).

location of the disease: the main duct IPMN, the branch duct IPMN, and the mixed IPMN. The main duct IPMN has a high rate of malignant transformation and is generally resected. In contrast, the reported malignancy rate of resected branch duct IPMN is 25.5% (6.3%-46.5%) with invasive ductal carcinoma representing 17.7% (1.4%-36.7%) of the malignancies [3]. However, because the annual rate of malignant transformation of IPMN in the elderly is as low (2%-3%). Patients are generally followed using imaging unless obvious signs of malignancy are present.

In this report, we describe a patient with coexisting pancreatic lipoma and branch duct IPMN with a solid component. Malignancy was suspected because a soft-tissue nodule was found within the lipoma, suggesting IPMN invasion.

Case report

A 74-year-old man with a history of hyperuricemia and surgery for a chest wall lipoma was referred to our hospital

because a mass was found in the pancreatic head on screening chest computed tomography (CT). Blood chemistry examination showed no abnormality including the presence of carcinoembryonic antigen and carbohydrate antigen 19-9.

Contrast dynamic CT was performed using 320-row CT (Aquilion ONE Vision Edition; Toshiba Medical Systems Corporation, Otawara, Japan). After abdominal plain CT, 100 mL of contrast material (Iopamiron 370 mgI/mL; Bayer Pharmaceuticals, Osaka, Japan) was injected within 30 seconds, and the early and late arterial phases were scanned at 25 and 45 seconds, respectively, after the start of the injection. The delayed phase was scanned 90 seconds after the start of the injection. On noncontrast CT, a 60-mm diameter multicystic mass with an irregular border was found extruding from the border of the pancreatic head.

Contrast CT showed continuity to the branch duct in the uncinated process of the pancreas, suggesting branch duct IPMN (Figs. 1-3). The main pancreatic duct was dilated to 6 mm in diameter. The mass contained a solid, 23-mm component, exhibiting contrast enhancement. Caudal to the IPMN, a 50-mm mass of fat density was observed (Figs. 1, 2C). This mass contained a nodule of soft-tissue density in the cranial area adjacent to the IPMN, showing a small area of contrast enhancement. The radiologic diagnosis was lipoma with invasion from the adjacent IPMN or liposarcoma (Fig. 2B).

Magnetic resonance imaging was performed using a 1.5T scanner (Achieva 1.5T, Philips Healthcare, Andover, MA, USA). The multicystic mass showed hypointensity on T1-weighted turbo field echo (repetition time/echo time [TR/TE] = 3.3/1.6) and hyperintensity on T2-weighted imaging (TR/TE = 1,776/100). Magnetic resonance cholangiopancreatography revealed a dilated dorsal main duct and branch duct with continuity to the multicystic mass, suggesting a branch duct origin. The ventral main pancreatic duct of normal diameter was visualized ventral to the mass. The solid component within this mass showed mild hyperintensity on T2-weighted imaging, hyperintensity on diffusion-weighted imaging (TR/TE = 1,534/65), a reduced apparent diffusion coefficient (b-value 800), and no infiltration outside the multicystic mass (Fig. 3). The lipoma showed the same intensity as the surrounding fat tissue on T2-weighted imaging and hypointensity on fat-suppressed T2-weighted imaging (TR/TA = 1,330/88). The solid nodule inside the lipoma showed

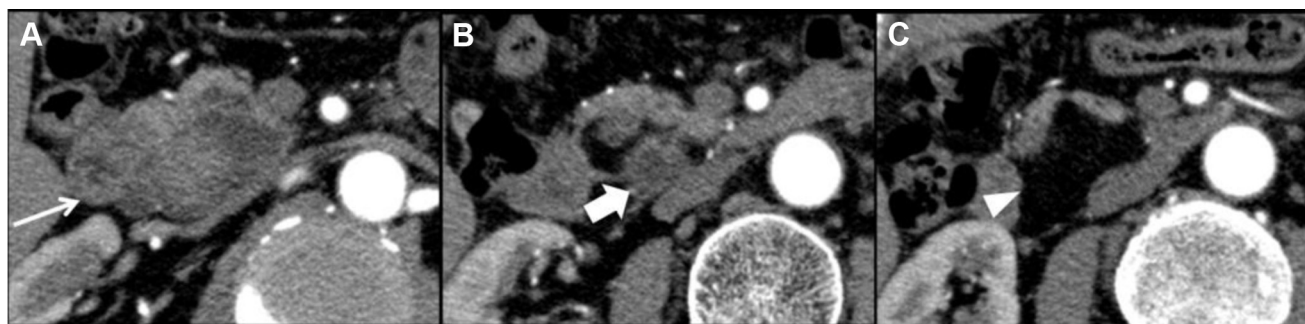


Fig. 2 – Contrast CT of the abdomen from the cranial (A) to caudal (C) direction. (A) 59-mm cystic lesion with a 23-mm enhanced nodule (arrow). (B) Soft-tissue nodule (wide arrow) within the lipomatous lesion located at the border between the cystic and lipomatous lesions. (C) Lipomatous lesion (arrowhead) is located caudal to the cystic lesion.

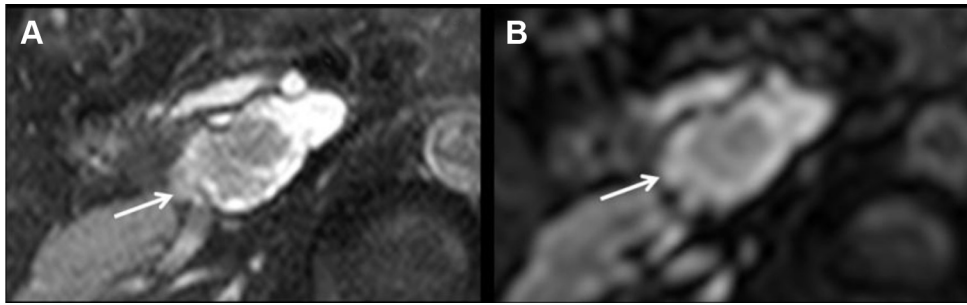


Fig. 3 – Noncontrast magnetic resonance imaging of the abdomen. (A) The mass (arrow) shows hyperintensity on T2-weighted imaging. (B) Diffusion-weighted imaging shows high signal intensity in association with low apparent diffusion coefficient values, indicating the mass (arrow) is likely to be IPMN with high-risk stigmata.

isohyperintensity to mild hyperintensity to the pancreatic parenchyma on fat-suppressed T2-weighted imaging (TR/TA = 1,330/88). The nodule did not show continuity with the wall of the IPMN on magnetic resonance imaging.

Endoscopic ultrasound was performed, confirming the solid component within the IPMN together with pancreas divisum. Cytology of the collected pancreatic fluid revealed malignant cells (class 5) suggesting intraductal papillary mucinous carcinoma. Therefore, pancreaticoduodenal resection with lymph node dissection was performed.

Pathologic investigation of the resected specimen confirmed IPMN with high-grade dysplasia and a mature lipoma. Macroscopically, the IPMN was a 40 × 30 × 20-mm multicystic mass with a 30 × 20 × 15-mm whitish solid nodule (Fig. 4). The mass was connected to the branch duct but did not show invasion. The main pancreatic duct was dilated to 9 mm in diameter, although it was not connected to the mass. Caudal to the IPMN was a 50 × 50 × 25-mm elastic, solid yellow mass with a smooth border, indicating pancreatic lipoma.

Microscopically, the cystic component of the IPMN consisted of a papillary proliferation of columnar tumor cells containing enlarged nuclei and mucinous vacuoles in the acidophilic matrix, around the edematous vascular connective tissue. A large percentage of the lesion was classified as low- to intermediate-grade dysplasia, but the rest of the area

showed round enlargement of the nuclei and distinct nucleoli indicating high-grade dysplasia. The stroma of the tumor had significant infiltration of lymphocytes and plasma cells, but no tumor invasion was observed (Fig. 5). The cut margin was free of tumor infiltration.

Microscopic examination of the lipoma revealed focal hyalinization and fibrosis adjacent to the border between the IPMN and the lipoma, correlating with the soft-tissue nodule. Although inflammatory infiltration was found within this site of hyalinization, no malignancy was found within the lipoma.

Discussion

Pancreatic lipomas are generally asymptomatic; most are found incidentally during abdominal ultrasound or CT examinations performed for other reasons. Pancreatic lipomas are reported to be rare, but the prevalence was reported to be as high as 6% in a retrospective report of abdominal CTs [4]. The diagnosis of pancreatic lipoma generally does not require pathologic confirmation unless there are findings suggestive of malignancy. This fact explains why less than 20 histologically confirmed cases of pancreatic lipoma have been reported [5]. Pancreatic lipomas are often found in the head of the pancreas, likely arising from migration of the adipose tissue between the dorsal and ventral lobes of the pancreas. Lipomas show uniform density or intensity of fat, occasionally with a thin septum or vessels, and do not show contrast enhancement. To our knowledge, no case of a pancreatic lipoma with a solid component has been reported. Because inhomogeneous density or a solid nodule within a lipid density mass is suggestive of liposarcoma, we recommended surgery [6,7]. We also considered that the solid nodule could have been malignant infiltration of IPMN because the nodule was found adjacent to the border of the 2 tumors. However, pathologic investigation revealed clear borders between the IPMN and the lipoma as well as inflammatory infiltration and hyalinization instead of IPMN infiltration. Pathologically, this histology was similar to that of inflammatory degeneration of the pancreatic tissue, and was thought to have spread from pancreatic inflammation unrelated to IPMN.

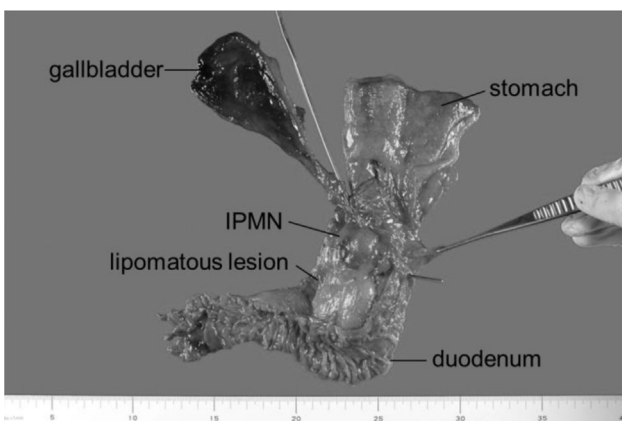


Fig. 4 – Photograph of the pancreatoduodenal resection specimen. The IPMN is located next to the lipomatous lesion.

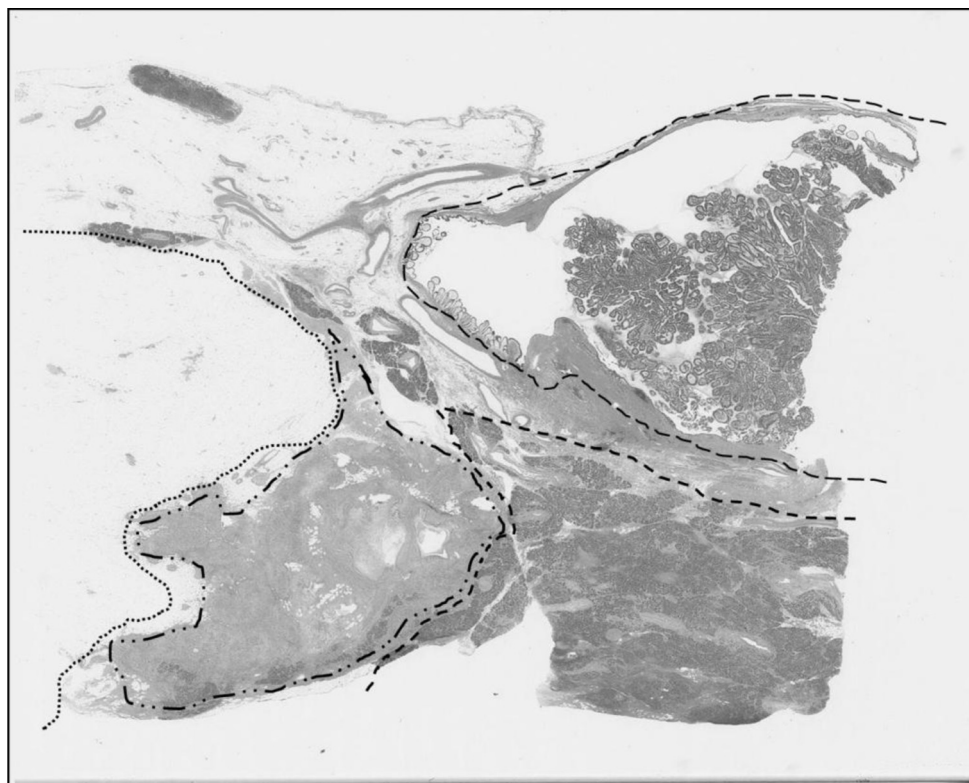


Fig. 5 – Gross appearance of the microscopic specimen with hematoxylin and eosin stain. The specimen consists of 4 components: a lipoma (dotted line), hyalinization with inflammatory cells (dotted and broken line), normal pancreatic parenchyma (thick broken line), and IPMN (thin and wavy broken line).

The solid component within the IPMN also supported our speculation that the solid nodule within the lipoma was malignant infiltration from the IPMN. The 2012 International Consensus guidelines for the management of IPMN and mucinous cystic neoplasm of the pancreas lists the following 6 worrisome features of IPMN: a cyst size larger than 3 cm, thickened enhanced cyst walls, a dilated (5–9 mm) main pancreatic duct, nonenhanced mural nodules, abrupt change in the main pancreatic duct caliber with distal pancreatic atrophy, and lymphadenopathy [3]. Examination using endoscopic ultrasound and cytology is recommended for nonenhanced mural nodules, as seen in our case [3]. Class 5 cytology of the pancreatic fluid was another reason for recommending surgery.

Differential diagnosis of a pancreatic mass containing fat density on CT includes focal fat replacement, lipoma, liposarcoma, teratoma, lipomatous pseudohypertrophy, fat replacement with obstruction of the main pancreatic duct and cystic fibrosis [8]. Liposarcoma should be considered in cases involving the elderly, rapid growth, a thickened wall and septum, a solid nodule, and inhomogeneous density. Surgical resection is inevitable if imaging findings are uncertain.

In conclusion, we observed a surgically proved case of benign IPMN with focally hyalinized pancreatic lipoma, which was preoperatively diagnosed as malignant IPMN infiltrating a pancreatic lipoma.

REFERENCES

- [1] Bigard MA, Boissel P, Regent D, Froment N. Intrapaneatic lipoma. First case in the literature. *Gastroenterol Clin Biol* 1989;13:505–7.
- [2] Zhan HX, Zhang TP, Liu BN, Liao Q, Zhao YP. A systematic review of pancreatic lipoma: how come there are so few cases? *Pancreas* 2010;39:257–60.
- [3] Tanaka M, Fernández-del Castillo C, Adsay V, Chari S, Falconi M, Jang JY, et al. International consensus guidelines 2012; for the management of IPMN and MCN of the pancreas. *Pancreatol* 2012;12:183–97.
- [4] Gossner J. Pancreatic lipomas—prevalence in patients undergoing abdominal CT. *Pol J Radiol* 2014;79:259–61.
- [5] Lee JY, Seo HI, Park EY, Kim GH, Park do Y, Kim S. Histologic confirmation of huge pancreatic lipoma: a case report and review of literatures. *J Korean Surg Soc* 2011;81:427–30.
- [6] Karaosmanoglu D, Karcaaltincaba M, Akata D, Ozmen M, Akhan O. Pancreatic lipoma computed tomography diagnosis of 17 patients and follow-up. *Pancreas* 2008;36:434–6.
- [7] Kransdorf MJ, Bancroft LW, Peterson JJ, Murphey MD, Foster WC, Temple HT. Imaging of fatty tumors: distinction of lipoma and well-differentiated liposarcoma. *Radiology* 2002;224:99–104.
- [8] Katz DS, Hines J, Math KR, Nardi PM, Mindelzun RE, Lane MJ. Using CT to reveal fat-containing abnormalities of the pancreas. *AJR Am J Roentgenol* 1999;172:393–6.