

The Evaluation of Palpable Thigh Nodularity in Vaccination-age Children – Differentiating Vaccination Granulomas from Other Causes

Douglas Mulholland*, Eimear A. Joyce, Ann Foran, Aisling Snow

Our Lady's Children's Hospital, Crumlin, Dublin, Ireland

Abstract

Palpable thigh nodularity is a relatively frequent indication for imaging of vaccination-age children, with patients often referred by their community physician or general practitioner. Ultrasound (US) is the imaging modality of choice to delineate the abnormality, and we present a number of characteristic findings that permit the radiologist and pediatrician to accurately identify the cause. A retrospective review was performed at the largest children's hospital in a European country between 2015 and 2017 over a 30-month period. A search was performed of the hospital's Picture Archiving and Communication System (PACS) for all children referred for a soft-tissue, upper limb, or lower limb US between January 2015 and July 2017. The findings were collated and stored in a spreadsheet. Nine patients were identified who developed subcutaneous nodules in the thigh at some point during their childhood vaccination schedule. Three of these patients had clinical histories strongly suggestive of a diagnosis of abscess or foreign body. The remaining six patients were selected for more in-depth analysis. Four of these patients had US features consistent with vaccination granuloma. Two patients were ultimately diagnosed with venolymphatic malformations. Palpable thigh nodularity in a child of vaccination age is encountered with a reasonable frequency. When encountered, granulomas tend to be located within the subcutaneous tissues, and we postulate that this is due to erroneous administration of a vaccine into the subcutis rather than into the muscle.

Keywords: Granuloma, pediatric, ultrasound, vaccination

INTRODUCTION

Palpable nodularity in the thigh in children of vaccination age may be a clinically challenging presentation, often requiring referral for ultrasound (US). Although the history and clinical/serologic findings may be suggestive of a specific cause, there is overlap in how patients with varying pathology present. US of the area of clinical concern is a valuable tool in further delineating the abnormality and allows referring clinicians to provide appropriate further care or reassurance as appropriate.

We present a series of nine patients who developed subcutaneous nodules in the thigh at some point during their childhood vaccination schedule and were referred for US. Vaccination granulomas are thought to have an incidence of 0.83%.^[1] We highlight the sonographic characteristics of postvaccination granulomas and explore the differential for thigh nodularity in a pediatric population of vaccination age.

CASE REPORT

Nine patients of childhood vaccination age (range 8–32 months) were referred for the evaluation of thigh nodularity over a 30-month period. Two patients presented with fever and thigh erythema on the background of vaccination <2 weeks prior; both had a large mixed echogenicity collection on US, consistent with abscess. A third patient referred for palpable thigh nodularity was a 10-year old whose ultrasound showed a splinter of wood visible in the subcutaneous fat of the lateral thigh.

The remaining six patients presented with a firm, nontender, palpable nodule or lump on the lateral thigh. Of these, two

Address for correspondence: Dr. Douglas Mulholland,
Our Lady's Children's Hospital, Crumlin, Dublin, Ireland.
E-mail: doug2057@gmail.com

Received: 06-04-2020 Revised: 18-05-2020 Accepted: 07-07-2020 Available Online: 14-05-2021

Access this article online

Quick Response Code:



Website:
www.jmuonline.org

DOI:
10.4103/JMU.JMU_51_20

This is an open access journal, and articles are distributed under the terms of the Creative Commons Attribution-NonCommercial-ShareAlike 4.0 License, which allows others to remix, tweak, and build upon the work non-commercially, as long as appropriate credit is given and the new creations are licensed under the identical terms.

For reprints contact: WKHLRPMedknow_reprints@wolterskluwer.com

How to cite this article: Mulholland D, Joyce EA, Foran A, Snow A. The evaluation of palpable thigh nodularity in vaccination-age children – Differentiating vaccination granulomas from other causes. J Med Ultrasound 2021;29:129-31.

patients (33%) had compressible low-flow lesions on US, consistent with venous or venolymphatic malformations. One patient (16%) had a single, ovoid, avascular hypoechoic nodule at the interface of the subcutaneous fat and the fascia of the vastus lateralis and subsequently underwent magnetic resonance imaging (MRI), which showed a corresponding short tau inversion recovery high-signal, T1 isointense lesion that had thin rim enhancement following contrast administration [Figure 1]. Three out of the six patients (50%) had a well-defined smoothly ovoid or slightly lobulated, hypoechoic, avascular nodule in the deep subcutaneous fat of the lateral thigh [Figures 2 and 3], sonographically consistent with a granuloma.^[2,3] Of these three patients, a single patient had two distinct nodules adjacent to one another. The lesions ranged from 0.8 to 2.6 cm (as taken by maximal dimension) with a mean size of 1.7 cm.

USs had been performed with a 12-MHz linear array transducer. Each US assessment included taking images in two planes, obtaining measurements of the detected lesions in three planes, and Doppler interrogation.

Demographic information regarding the selected patients was logged, as was the size and imaging characteristics of each lesion [Table 1].

Our institution’s IRB committee granted ethics approval for this retrospective study and consent was not required.

DISCUSSION

Childhood vaccinations have revolutionized pediatric health care in modern times. They have led to a dramatic reduction in several previously widespread diseases, and adverse effects associated with vaccinations are very rare. There are a number of case series of persistent nodules following vaccination, particularly in the context of aluminum-adsorbed vaccines.^[4-6] Aluminum-adsorbed vaccines within the vaccination schedule in Ireland include diphtheria, tetanus, hemophilus, hepatitis B, and *Pneumococcus*. The ideal route of administration of aluminium-adjuvanted vaccines is intramuscular,^[7] however, subcutaneous administration may occur.^[8]

All abnormalities in the current case series were located in the subcutaneous tissues, between the dermis and the muscle

fascia. It has previously been shown that the distance from the skin to the muscle compartment may be extremely variable in

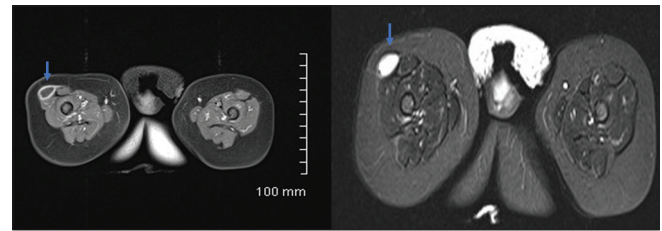


Figure 1: Multisequence magnetic resonance imaging of the thigh showing a T1 dark, T2/short-tau inversion recovery bright lesion, with rim enhancement (blue arrows)

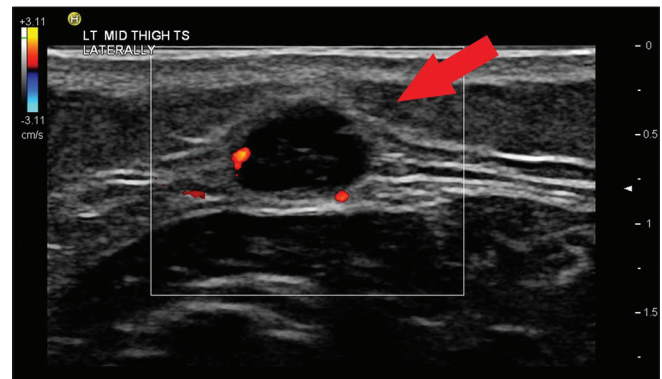


Figure 2: Avascular, hypoechoic lesion (red arrow) measuring 2.3 cm in the thigh

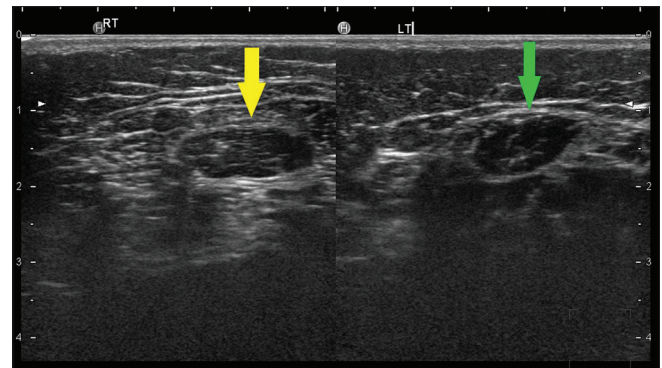


Figure 3: Two well-circumscribed hypoechoic lesions (green and yellow arrows) in the thigh

Table 1: Demographics and ultrasound findings in selected patients

Patient	Age (months)	Gender	Modalities	Doppler characteristics	Size (cm)	Diagnosis
1	8	Female	US, radiograph	Avascular	2.3	Vaccination granuloma
2	8	Male	US	Avascular	0.8, 0.9	Vaccination granuloma
3	15	Female	US	Avascular	1.4	Vaccination granuloma
4	12	Male	US, MR, radiograph	Avascular	2.6	Vaccination granuloma
5	23	Male	US	Low flow	1.9	Venolymphatic malformation
6	32	Male	US	Low flow	2.1	Venolymphatic malformation
7	17	Male	US	Avascular	3.5	Abscess
8	22	Female	US	Avascular	2.9	Abscess
9	122	Male	US, radiograph	Avascular	2.2	Foreign body

US: Ultrasound, MR: Magnetic resonance

pediatric patients and that standard needle lengths may be too short to effectively deliver medications to the intramuscular compartment.^[9] Granulomas are a local formation of specific cells including macrophages and lymphocytes, revealing a chronic inflammatory reaction against an inciting agent.^[10] The etiology of vaccination granulomas has been described as an inflammatory response incited by the injection of a vaccine, particularly those which are aluminum adsorbed.^[11]

There have been case series linking vaccination granulomas with aluminum-adsorbed vaccines.^[4-6] In our case series, all cases of vaccination granuloma were in the subcutaneous tissues, as such, we postulate that complete or partial subcutaneous injection of these vaccines, rather than the intended intramuscular route, is the cause for these granulomas. Resection of such a lesion in a well child with imaging findings typical of benign granuloma is not justified, precluding ready pathologic confirmation of our theory.

Given the importance of vaccines in the pediatric population and the increasing public concern about vaccine-induced adverse reactions, it is vital to correctly identify findings such as postvaccination granulomas that require no further follow-up such that referrers and parents can be reassured.

In addition to granulomas, the differential diagnosis for palpable nodularity in the thigh of an infant or a young child includes foreign body, infection, and vascular malformation. These etiologies can be distinguished with a combination of clinical history and US. In the case of vascular malformations, the presence of an ill-defined hypoechoic structure, Doppler flow or phleboliths within the lesion, and compressibility, particularly if present since birth, is highly suggestive.^[12] Abscess will be seen as anechoic or hypoechoic spherical collection of heterogenous or echogenic fluid. In the case of an abscess, there may be an echogenic capsule, but often, the borders are poorly defined; there should also be an appropriate clinical history suggestive of local infection.^[13] A foreign body can be readily detected on US, commonly as a linear echogenic area representing a thorn, wood, plastic, or glass.^[14]

Further evaluation with MRI is not routine and should only be performed in the presence of concerning clinical features, such as contact with the muscle fascia,^[15] increasing size, or signs of invasive local infection.

CONCLUSION

Palpable thigh nodularity in a child of vaccination age often necessitates a referral for US. In addition to a good clinical history, US is often adequate to make the diagnosis of vaccination granuloma. When encountered, we have found

that vaccination granulomas tend to be located within the subcutaneous tissues, and we postulate that this may be due to erroneous administration of a vaccine into the subcutis rather than into the muscle.

Financial support and sponsorship

Nil.

Conflicts of interest

There are no conflicts of interest.

REFERENCES

- Bergfors E, Hermansson G, Nyström Kronander U, Falk L, Valter L, Trollfors B. How common are long-lasting, intensely itching vaccination granulomas and contact allergy to aluminium induced by currently used pediatric vaccines? A prospective cohort study. *Eur J Pediatr* 2014;173:1297-307.
- Jarraya M, Hayashi D, de Villiers RV, Roemer FW, Murakami AM, Cossi A, *et al.* Multimodality imaging of foreign bodies of the musculoskeletal system. *AJR Am J Roentgenol* 2014;203:W92-102.
- Sechi A, Patrizi A, Vincenzi C, Savoia F, Tartari F, Leuzzi M, *et al.* Sonographic features of vaccination granulomas in children with delayed-type hypersensitivity to aluminum. *Pediatr Dermatol* 2019;36:1012-6.
- Bergfors E, Björkelund C, Trollfors B. Nineteen cases of persistent pruritic nodules and contact allergy to aluminium after injection of commonly used aluminium-adsorbed vaccines. *Eur J Pediatr* 2005;164:691-7.
- Lauren CT, Belsito DV, Morel KD, LaRussa P. Case report of subcutaneous nodules and sterile abscesses due to delayed type hypersensitivity to aluminum-containing vaccines. *Pediatrics* 2016;138:4.
- Bergfors E, Trollfors B, Inerot A. Unexpectedly high incidence of persistent itching nodules and delayed hypersensitivity to aluminium in children after the use of adsorbed vaccines from a single manufacturer. *Vaccine* 2003;22:64-9.
- Cook IF. Evidence based route of administration of vaccines. *Hum Vaccin* 2008;4:67-73.
- Zuckerman JN. The importance of injecting vaccines into muscle. Different patients need different needle sizes. *BMJ* 2000;321:1237-8.
- Duong M, Botchway A, Dela Cruz J, Austin R, McDaniel K, Jaeger C. Skin to intramuscular compartment thigh measurement by ultrasound in pediatric population. *West J Emerg Med* 2017;18:479-86.
- Soler P, Bernaudin JF. Physiology of granulomas. *Rev Pneumol Clin* 1993;49:257-61.
- Chong H, Brady K, Metze D, Calonje E. Persistent nodules at injection sites (aluminium granuloma)-Clinicopathological study of 14 cases with a diverse range of histological reaction patterns. *Histopathology* 2006;48:182-8.
- Khunger N. Lymphatic malformations: Current status. *J Cutan Aesthet Surg* 2010;3:137-8.
- Tayal VS, Hasan N, Norton HJ, Tomaszewski CA. The effect of soft-tissue ultrasound on the management of cellulitis in the emergency department. *Acad Emerg Med* 2006;13:384-8.
- Tahmasebi M, Zareizadeh H, Motamedfar A. Accuracy of ultrasonography in detecting radiolucent soft-tissue foreign bodies. *Indian J Radiol Imaging* 2014;24:196-200.
- Chung HW, Cho KH. Ultrasonography of soft tissue "oops lesions." *Ultrasonography* 2015;34:217-25.