

HEPATIC INJURY ON A NUTRITIONAL BASIS IN RATS*

BY PAUL GYÖRGY, M.D., AND HARRY GOLDBLATT, M.D.

(From the Babies and Childrens Hospital, the Institute of Pathology, and the Departments of Pediatrics and Pathology, School of Medicine, Western Reserve University, Cleveland)

PLATES 20 TO 22

(Received for publication, May 13, 1939)

The diet originally (1) and still commonly used for the production of "rat acrodynia," the specific vitamin B₆ deficiency disease in this animal, consists of casein, cane sugar (or rice starch), melted butter fat, cod liver oil and salt mixture and is supplemented with vitamin B₁ and riboflavin. During the last few years it has become evident that this ration lacks at least two (2) and probably more factors (3), one of which is vitamin B₆. Under the conditions chosen, vitamin B₆ deficiency is the primary disturbance and prevails over the other deficiencies. This is an illustration of the phenomenon of "concurrence" or "competition" of vitamin deficiency diseases. In a previous paper (3) observations were reported to the effect that this rule might have its exception even under identical conditions. For example, in several instances of acrodynia which had developed in rats kept on the diet deficient in vitamin B₆, spontaneous improvement of the skin lesion occurred but the rats became, at the same time, progressively anemic, exhibiting the typical picture of panmyelophthisis with all its manifestations—agranulocytosis and hemorrhagic diathesis in addition to the anemia. In these rats the concurrence of deficiency diseases ended in favor of a disease which usually is relegated to a latent position. In view of this conception it was logical to expect to find, as was actually the case, panmyelophthisis present in the majority of the animals after the specific B₆ deficiency disease had been successfully treated with purified B₆ preparations.

Panmyelophthisis is not the only disease that might complicate experimental work on vitamin B₆ deficiency, owing to the fact that the ration used is deficient in several respects.

During the past 2 years deaths have occurred in our stock of experimental rats kept on the diet devoid of B₆. At first no explanation could be found.

* Presented in part at the meeting of the American Pediatric Society, Skytop, Pennsylvania, April 29, 1939.

The animals dying were free from specific symptoms of acrodynia or panmyelophthisis; intercurrent infections such as pneumonia or abscesses in the lung and kidney were also absent. Ten or twelve animals were discarded without further examination before the yellowish red patches in several lobes of the liver of one rat called our attention to the possibility that injury to the liver might be the cause of death. From this date (September, 1937) on, all rats in which the cause of death was not obvious have been examined histologically for hepatic injury.

Forty-eight rats with distinctly pathological changes in the liver have been observed in the period from September, 1937, to February, 1939.

EXPERIMENTAL DATA

The rats were fed the usual B₆ free diet (1, 3) with cane sugar or rice starch as the source of carbohydrate. Synthetic vitamin B₁ and synthetic or natural riboflavin¹ were used as basic supplements, with or without the further addition of purified vitamin B₆ preparations or crystalline B₆. The B₁ and riboflavin solutions were prepared from a crystalline compound without the addition of any antiseptic.

A definite diagnosis of hepatic changes during the lifetime of any individual rat was not possible. After preliminary observations of postmortem findings in the liver had suggested a causal relationship in some cases between the very excited, hyperactive behavior of that rat and the liver changes, it was considered that this behavior might hint the presence of disease of the liver. This behavior was in marked contrast to the complete suppression of growth and development in the young experimental animals.² The growth curve for all these animals was flat for 4 to 12 weeks and more, prior to death, and there were no specific symptoms of acrodynia, panmyelophthisis or infection. In rats in which after treatment with vitamin B₆ there was a distinct gain in growth, death due to liver injury was never observed. The diagnosis was made in the overwhelming majority of the animals only by macroscopic and microscopic examination of the liver.

Pathological Changes in Liver

Macroscopic Examination.—In the gross, the appearance of the livers of rats fed the diet deficient in a part of the B₂ complex varied greatly. Some livers appeared normal, some were obviously the seat of varying degrees of diffuse fatty change, while others showed uncommon and peculiar features. The outer surface of these latter livers exhibited either fine or coarse diffuse mottling of light yellow or dark red, or both, on a background of light or dark brown (Fig. 1 a), or large patches of light yellow or dark

¹ Synthetic vitamin B₁ and synthetic riboflavin were obtained from Merck and Company, synthetic riboflavin also from Winthrop Chemical Company and Hoffmann-La Roche, and natural riboflavin from the S.M.A. Corporation.

² Since this manuscript was submitted, two rats have been observed which, before death, presented severe jaundice (yellow ears, bile-stained urine), a finding which made possible the diagnosis of hepatic disease during the lifetime of the rat.

red in one or more lobes which were not otherwise the seat of obviously morbid change (Fig. 1 *b*). In some livers these yellow or red patches occupied the greater part of one or more lobes. All parts of the livers cut with great ease. In the cut surface, the same finely or coarsely mottled or patchy involvement was evident. The contrast between the light yellow, dark red and brown patches was very striking. In the gross, there was no indication of significant increase in fibrous connective tissue, for there was no nodularity of the surface or increased resistance of the tissue to cutting.

Microscopic Examination.—The livers which in the gross exhibited pathological changes, especially the mottled and patchy appearance, showed, microscopically, parenchymatous and fatty degeneration in varying degree as well as necrosis of liver tissue, with or without hyperemia and hemorrhage in the region of the degeneration and necrosis. In the livers of some of the rats there was only focal, central parenchymatous degeneration, characterized by granular cytoplasm which took a pale pink stain, with or without vacuoles and pyknosis or rhexis of some of the nuclei of the liver cells (Fig. 2). In many livers these changes involved the midzonal as well as the central portions of the lobules (Fig. 3). In some lobules the only relatively well preserved parenchyma was in the form of peripheral islets of varying size; the remainder of the lobules was the seat of severe parenchymatous or fatty degeneration and necrosis with or without hyperemia and hemorrhage (Fig. 4). Even in the islets of fairly well preserved liver tissue there was usually a variable amount of parenchymatous and fatty degeneration. This was most marked in the cells farthest from the portal space. In some of the central zones that were the seat of extravasated blood, the parenchyma was almost completely destroyed and the sinusoids were not recognizable; in others the remains of some of the liver cords were still distinguishable in the form of large cells with finely granular cytoplasm, stained a pale pink, which contained mostly small but some large vacuoles accompanied by pyknosis or rhexis of nuclei. In frozen sections some of the vacuoles gave the reactions for lipoids. Those vacuoles that did not give these reactions were probably an indication of hydropic degeneration. In four livers examined for glycogen, no glycogen was found in the vacuoles or cytoplasm of the liver cells. In only a few of the organs was fatty degeneration severe. Fat infiltration was common, varied in amount, and also affected those portions of the liver that were not otherwise the seat of morbid changes. In the relatively well preserved peripheral (periportal) islets of liver cells, active regeneration of liver tissue was frequently evidenced by abundant mitoses of various kinds, abnormal nuclear forms, binucleate cells and giant nuclei (Figs. 7 and 8). There were large portions of liver in which only the connective tissue, bile ducts and blood vessels of the portal spaces were recognizable. The remainder of the lobules consisted of degenerated, necrotic and hemorrhagic liver tissue. All through these lobules, wherever sinusoids were still well preserved, especially in the periportal islets, many of the Kupffer cells were swollen and prominent, with pale cytoplasm and small, dense nuclei. The cytoplasm of some of these cells contained hemosiderin. In regions of severe degeneration, necrosis and hemorrhage, the Kupffer cells also exhibited more advanced degenerative changes. In some of the livers the foci of necrosis, with or without hemorrhage, were infiltrated with small round cells and histiocytes (Fig. 5). In some of the livers there was diffuse involvement of the entire organ by either the focal or the confluent degenerative and necrotic lesions, and in some almost an entire lobe was necrotic. In a few there was slight condensation fibrosis

in the degenerated and necrotic foci, with or without cellular infiltration, and in four rats moderate to severe proliferative fibrosis was observed in the portal regions. In two livers (see Fig. 6) this change was so severe as to warrant the diagnosis of localized cirrhosis. In one of these rats there was also some multiplication of bile ducts.

The distribution of histological changes in the livers examined is summarized as follows:

	No. of livers
Parenchymatous (with or without fatty) degeneration (focal), involving varying amounts of liver	48
Necrosis, focal or patchy, involving varying amounts of liver	29
Hemorrhage accompanying necrosis	18
Perilobular and condensation fibrosis	4

Pathogenesis and Etiology

The fact that in some livers there were many small central and midzonal foci of degenerated and necrotic liver tissue, with or without accompanying hemorrhage, as well as the fact that the extravasated blood was found only in severely degenerated and necrotic foci, has been interpreted as indicative that the degeneration and necrosis were the primary changes. When the disintegration of the parenchyma was sufficiently advanced, the sinusoids ruptured and blood was extravasated. The cellular infiltration, with or without condensation and proliferative fibrosis, and the signs of liver cell regeneration have been interpreted as the healing or perhaps the precirrhotic phase of this type of liver necrosis. The massive character of some of the necrotic lesions suggests an ischemic origin, but no obliterative vascular lesions or intrahepatic thrombi were found to corroborate this view. That there might be an extrahepatic vascular lesion, although such a lesion was not found, has not been entirely eliminated as a cause of the patchy necrosis.

The only pathological manifestations were in the liver. As to the cause of the liver changes, three possibilities (and eventually the combination of them) have to be taken into consideration. They are (a) infectious, (b) toxic and (c) nutritional.

Bacteriological studies have been carried out on nine rats to clarify the question of infection. Three of these animals were examined shortly after death, which followed a rather extended period in which they were moribund. In the liver and spleen of these rats, a few *Escherichia coli* were found. In six animals the liver disease was suspected on account of peculiar behavior (excitement, hyperagility, flat growth curve). These rats were killed, and the negative results of the comprehensive bacteriological examination justify the conclusion that neither a primary nor a secondary infection with bacteria of a demonstrable sort was concerned with the production of the hepatic lesions.

In indirect proof of the non-infectious nature of the liver changes observed in this series of rats, the following points should be emphasized.

1. In several thousand rats that were ill with different deficiency diseases and died because of them, liver changes have never been encountered except under the conditions reported in this paper.

2. In the same animal room, many hundred rats were kept at the same time under normal and deficient nutritional conditions. In particular, experiments have been simultaneously carried out on riboflavin deficiency, egg white injury and massive radiation with roentgen rays, without any incidence of liver injury in these groups of rats. Liver injury was limited to one specific group.

3. The liver changes were not confined to the period in which the animals were moribund. In many rats their presence was suspected for days and weeks, and examination showed them to be present.

The experimental conditions of this group of rats exclude the possibility that a common exogenous toxic agent is the cause of the hepatic injury unless there is present in the diet some unidentifiable poison.

In the etiology of the hepatic injury, as in the case of panmyelophthisis (3), circumstantial evidence favors a nutritional basis.

Injury to the liver was never encountered in rats which had been fed for from 3 to 6 months a diet deficient in the vitamin B complex and supplemented with B₁, riboflavin and yeast (0.5 gm. daily). Nor was it found in rats fed the same basal diet supplemented with vitamin B and yeast extract in the form of Peters' eluate (4). It can therefore be assumed that yeast or Peters' eluate contains a factor (or factors) which prevents the hepatic injury observed in rats kept on a diet free from this factor (or factors). As this liver disease was not prevented by administration of B₁, riboflavin and purified (even crystalline) B₆ preparations, the hypothetical liver factor must be different from these components of the vitamin B complex. Eleven of the forty-eight rats in which liver changes were found had received purified or crystalline B₆ in addition to the basal diet supplemented with B₁ and riboflavin. Perilobular and condensation fibrosis was found only in this latter group.

As was the case with panmyelophthisis in rats, liver injury could not be produced at will and was not a regular occurrence even under identical experimental conditions. Whether this fact was due to the phenomenon of concurrence of vitamin deficiency diseases—an interference which might be possible on account of the multiple deficiencies in the diet used—or to some other unknown experimental factors, cannot be answered at the present time.

DISCUSSION

The degenerative and necrotic changes observed in the livers of rats fed a diet deficient in the vitamin B complex and supplemented with B₁ and riboflavin or with B₁, riboflavin and purified B₆ preparations resemble, in location and character, the acute and precirrhotic changes seen in various kinds of poisoning, particularly that due to carbon tetrachloride (5). The striking differences are that (*a*), in general, the distribution of the lesions in the lobes is less uniform and (*b*) the amount of hemorrhage is greater and the fatty degeneration less than in poisoning caused by carbon tetrachloride, chloroform or other hepatotoxic chemicals. The lesions here reported are different from those due to paratyphoid infection in the livers of rats kept under laboratory conditions (6). The lesions observed bear some resemblance to the acute and subacute stages of yellow liver atrophy in man (7).

The possible relation of the hepatic changes in our rats to the defective diet, and in particular to the lack of a constituent (or constituents) of the vitamin B₂ complex, is borne out or at least strongly suggested by the fact that the injury could be regularly prevented by the addition of yeast or a fairly complete yeast extract, such as Peters' eluate, but not by the addition of vitamin B₁, riboflavin or vitamin B₆.

The fact that riboflavin was not efficacious as a prophylactic agent in our experiments rules out the possibility that the hepatic injury described by Sebrell (8) as yellow liver in dogs might be comparable to these lesions in rats. The condition in dogs was rarely accompanied by degenerative changes, and when these were present they were of minor character. Their cause, it was established, was deficiency of riboflavin in the diet. Heavier livers containing a higher percentage of total fatty acids have been observed by Halliday (9) in animals kept on a B₆ deficient diet similar to that used in our experiments.

The finding of a definite drop in oxygen uptake of liver tissue (10) in rats kept on a diet deficient in the vitamin B complex and supplemented with vitamin B₁ and riboflavin might be considered the first latent manifestation of a functional disturbance of the liver that precedes definite histological changes.

Rhoads and Miller (11) have recently described hepatic dysfunction in dogs fed a black-tongue-producing diet. Normal function was restored by supplementing the diet with liver extract.

Now that the production of an apparently nutritionally conditioned hepatic injury with necrosis and condensation fibrosis has become possible, the question arises whether some forms of toxic hepatitis and of cirrhosis

of the liver should not be regarded as a deficiency disease rather than as a toxic disease, in analogy to the conception of pellagra and polyneuritis as such. Patek (12), who recently also raised this question, believes that in preliminary clinical trials patients ill with alcoholic cirrhosis of the liver were benefited by "high vitamin therapy" which consisted mainly of medication in the form of the whole vitamin B complex.

In this connection the recent experiments of Forbes and his coworkers (13) on the prevention of necrosis and cirrhosis of the liver caused by poisoning by chloroform or carbon tetrachloride are of particular interest. They found that rats to which liver or specially prepared water-soluble liver extract had been administered before chloroform or carbon tetrachloride was given were protected to a high degree from the poisonous effect of both chloroform and carbon tetrachloride.

In extensive chemical and toxicological studies, Neale and Winter (14) have found that sodium xanthine and some other related purine derivatives including guanosine, guanine and hypoxanthine exhibited protective action against liver changes caused by poisoning due to chloroform or carbon tetrachloride. The protective action of sodium xanthine has been further confirmed by Barrett, MacLean and McHenry (15) and more recently by Fitzhugh (16). It remains to be shown whether the active principle (or principles) responsible for the prevention of nutritional hepatic injury in our rats belongs also in the group of purine substances. It is interesting that the diet used in the present experiments was practically devoid of purine substances.

SUMMARY

In forty-eight rats kept on a basal diet deficient in the vitamin B complex and supplemented with vitamin B₁ and riboflavin or with vitamin B₁, riboflavin and vitamin B₆, various pathological changes in the liver were observed. These changes were characterized mainly by parenchymatous and fatty degeneration, focal and massive necrosis, hyperemia and hemorrhage and, in some of the rats, by perilobular and condensation fibrosis. Addition of yeast or Peters' eluate (yeast extract) regularly prevented this hepatic injury. On the basis of the evidence obtained, it is assumed that the liver changes are of nutritional origin and should be correlated to deficiency of a part of the vitamin B₂ complex.

BIBLIOGRAPHY

1. György, P., *Nature*, 1934, **133**, 498; *Biochem. J.*, London, 1935, **29**, 741.
2. Lepkovsky, S., Jukes, T. H., and Krause, M. E., *J. Biol. Chem.*, 1936, **115**, 557.
3. György, P., Goldblatt, H., Miller, F. R., and Fulton, R. P., *J. Exp. Med.*, 1937, **66**, 579.

4. Kinnersley, H. W., O'Brien, J. R., Peters, R. A., and Reader, V., *Biochem. J.*, London, 1933, **27**, 225.
5. Cf. Cameron, G. R., and Karunaratne, W. A. E., *J. Path. and Bact.*, 1936, **42**, 1.
6. Pappenheimer, A. M., and von Wedel, H., *J. Infect. Dis.*, 1914, **14**, 180.
7. Karsner, H. T., *Human pathology*, Philadelphia, J. B. Lippincott Co., 4th edition, 1935, 688.
8. Sebrell, W. H., and Onstott, R. H., *Pub. Health Rep., U.S.P.H.S.*, 1938, **53**, 83. Sebrell, W. H., *Bull. Nat. Inst. Health, U.S.P.H.S.*, No. 162, 1933, 23.
9. Halliday, N., *J. Nutrition*, 1938, **16**, 285.
10. Muus, J., Bessey, O. A., and Hastings, A. B., *J. Biol. Chem.*, 1937, **119**, lxxii.
11. Rhoads, C. P., and Miller, D. K., *J. Exp. Med.*, 1938, **67**, 463.
12. Patek, A. J., Jr., *Proc. Soc. Exp. Biol. and Med.*, 1937-38, **37**, 329.
13. Forbes, J. C., Neale, R. C., and Scherer, J. H., *J. Pharmacol. and Exp. Therap.*, 1936, **58**, 402. Forbes, J. C., and McConnell, J. S., *Proc. Soc. Exp. Biol. and Med.*, 1937, **36**, 359. Forbes, J. C., *J. Biol. Chem.*, 1938, **123**, xxxvii.
14. Neale, R. C., and Winter, H. C., *J. Pharmacol. and Exp. Therap.*, 1938, **62**, 127.
15. Barrett, H. M., MacLean, D. L., and McHenry, E. W., *J. Pharmacol. and Exp. Therap.*, 1938, **64**, 131.
16. Fitzhugh, O. G., *Proc. Soc. Exp. Biol. and Med.*, 1939, **40**, 11.

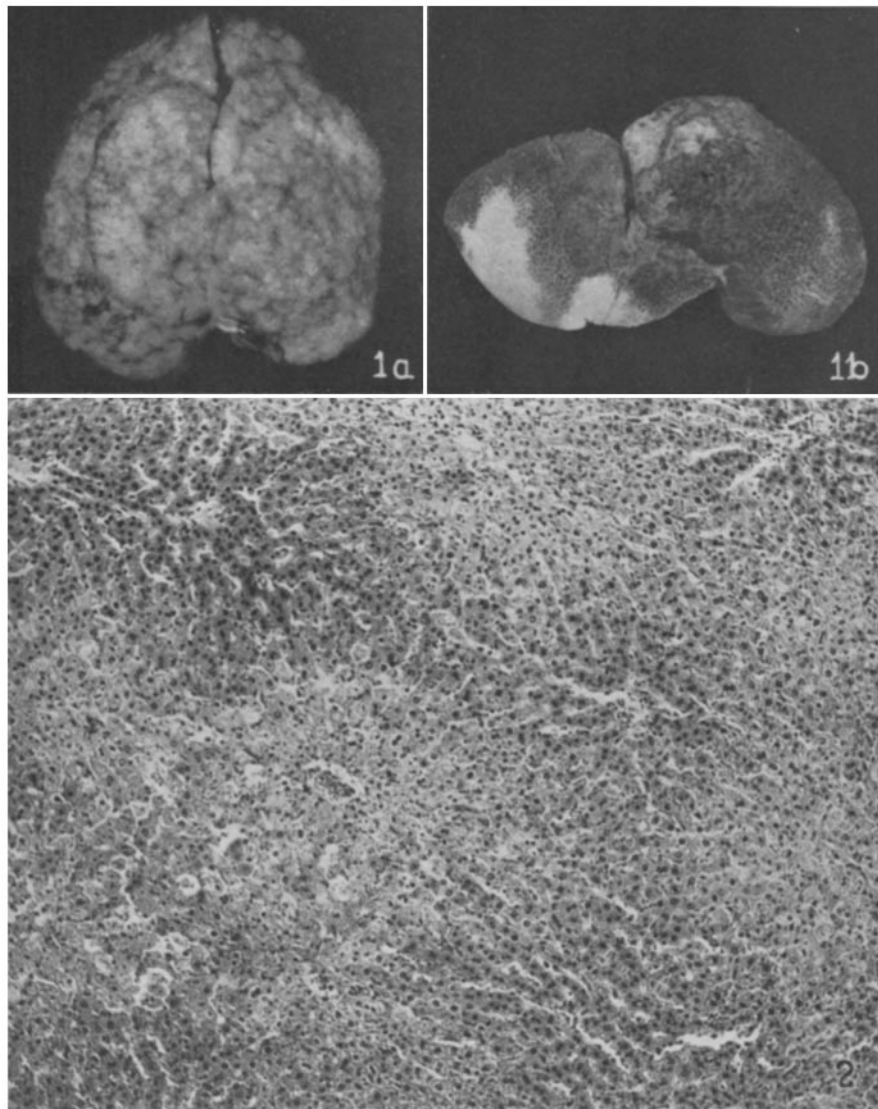
EXPLANATION OF PLATES

PLATE 20

FIG. 1 *a*. Gross appearance of liver of rat 1668, showing mottling due to extensive necrosis affecting all lobules.

1 *b*. Gross appearance of liver of rat 1408. Large patches of necrosis appear white.

FIG. 2. Section of liver, stained with hematoxylin and eosin. Rat 10168, after 7 weeks on a basal diet deficient in the vitamin B complex and supplemented with B₁, riboflavin and B₆. Shows a moderate degree of central parenchymatous degeneration of many lobules, without necrosis or hemorrhage. × 125.



(György and Goldblatt: Hepatic injury on nutritional basis)

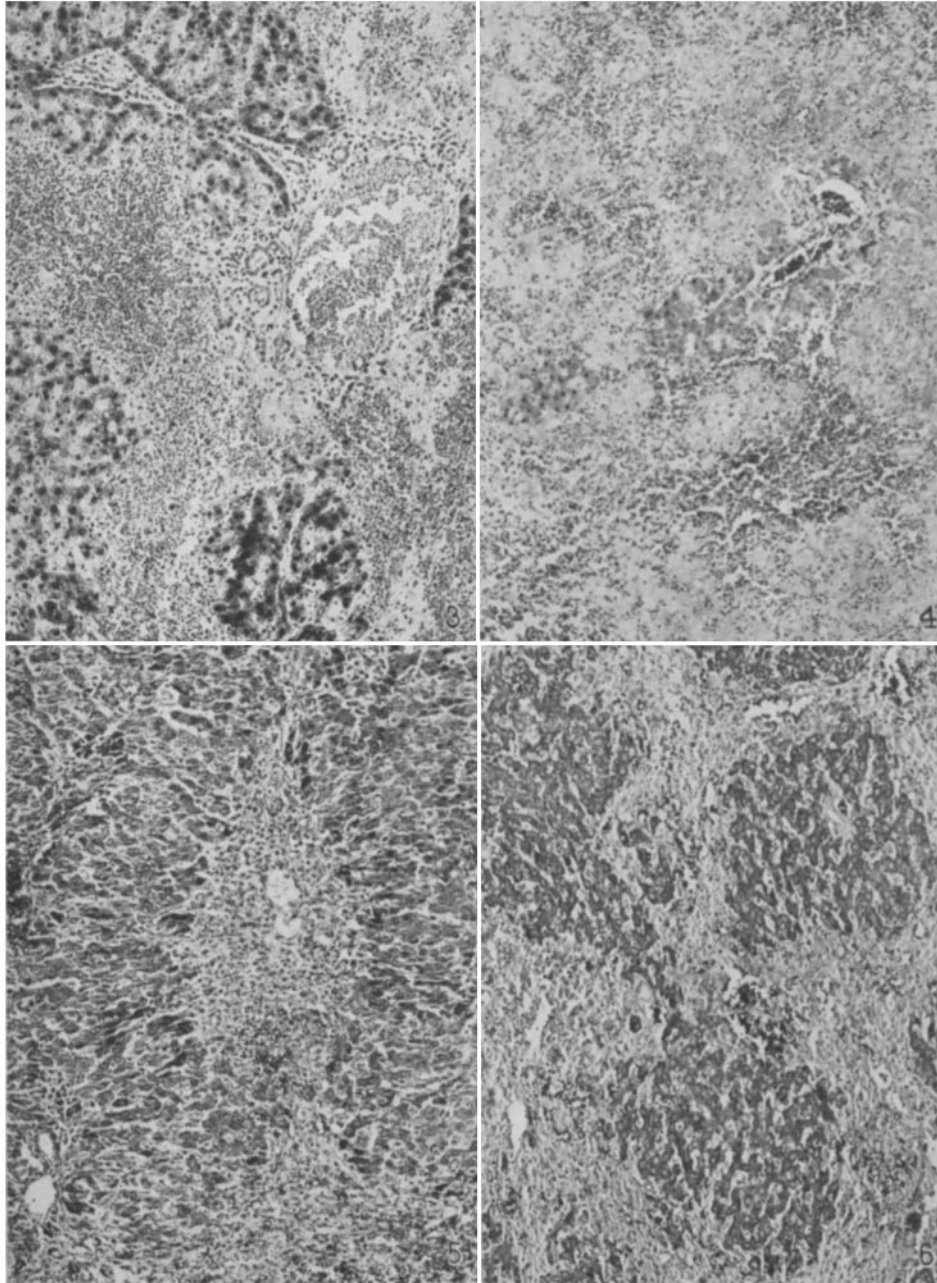
PLATE 21

FIG. 3. Section of liver, stained with hematoxylin and eosin. Rat 8706, after 10 weeks on a basal diet deficient in the vitamin B complex and supplemented with B₁ and riboflavin. Shows central and midzonal degeneration, necrosis and hemorrhage with fairly well preserved peripheral islets of liver cells. × 87.

FIG. 4. Section from a different lobe of liver of rat in Fig. 3. Shows similar changes but only a few severely degenerated liver cells still recognizable around a portal space. There is extensive necrosis of liver cells and much extravasated blood. × 87.

FIG. 5. Section of liver, stained with hematoxylin and eosin, showing a central zone the seat of necrosis and infiltration with small and large round cells. Rat 9577, after 12 weeks on a basal diet deficient in the vitamin B complex and supplemented with B₁, riboflavin and B₆. × 118.

FIG. 6. Section from a different lobe of liver in Fig. 5, stained for connective tissue by Mallory's method. There is great increase in perilobular connective tissue and some intralobular condensation fibrosis in large portions of several lobes. × 118.

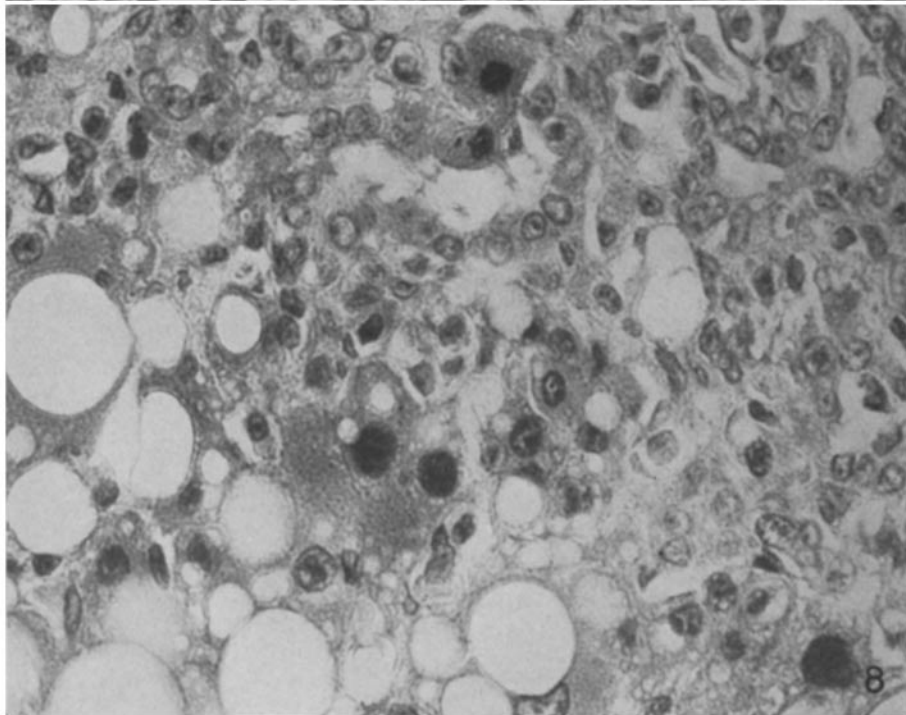
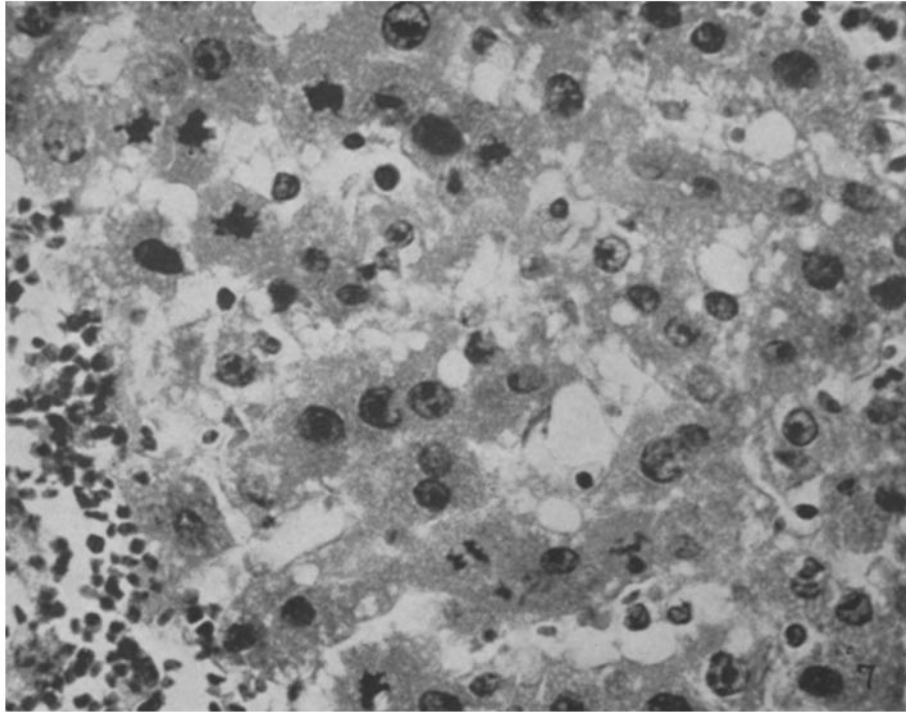


(György and Goldblatt: Hepatic injury on nutritional basis)

PLATE 22

FIG. 7. Portion of a peripheral zone showing many mitoses in different phases and considerable variability in size and density of staining of the nuclei. Rat 9577, after 12 weeks on a basal diet deficient in the vitamin B complex and supplemented with B₁, riboflavin and B₆. Stained with hematoxylin and eosin. × 675.

FIG. 8. Portion of a peripheral zone showing binucleate cells and large hyperchromatic nuclei. Rat 9975, after 14 weeks on a basal diet deficient in the vitamin B complex and supplemented with B₁ and riboflavin. Stained with hematoxylin and eosin. × 592.



(György and Goldblatt: Hepatic injury on nutritional basis)