

Access this article online

Quick Response Code:



Website:

www.jfcmonline.com

DOI:

10.4103/jfcm.JFCM_230_20

A rare case of intraductal papilloma with atypical ductal hyperplasia in a male breast: A pathological diagnosis

Sushma Bharti, Jyotsna Naresh Bharti, Jeewan Ram Vishnoi¹, Arsha B. Soudamini

Abstract:

Male breast cancer is itself a very rare condition and represents 0.5%–1% of all breast cancers diagnosed. Atypical ductal hyperplasia (ADH), intraductal papilloma (IP), and ductal carcinoma in situ are also very rare in a male breast. Only a few cases of ADH with gynecomastia have been reported in English literature until now. Here, we report a rare case of an IP with ADH associated with gynecomastia in an elderly male, who complained of right nipple pain, discharge, and tiny retroareolar mass. Mammography showed a subareolar nodule graded as the Breast Imaging-Reporting and Data System 4B. It is difficult to differentiate, both clinically and radiologically, between benign and malignant papillary lesions and invasive carcinoma, because of the similarity of findings. Hence, any male with palpable unilateral hard fixed lesions in the retroareolar region with complaints of nipple discharge, skin changes, or axillary lymphadenopathy should have a histopathological evaluation.

Keywords:

Atypical ductal hyperplasia, breast, gynecomastia, male, papilloma

Introduction

Male breast cancer (MBC) constitutes 0.5%–1% of all breast cancers diagnosed worldwide,^[1] and its incidence has increased in the past 25 years.^[2] The rate of breast complaints has also increased from 0.8% to 2.4% over the past two decades.^[3] Pure ductal carcinoma *in situ* (DCIS) constitutes 0.1% of all MBCs. Intraductal papilloma (IP) and atypical ductal hyperplasia (ADH) are very rare conditions in the male breast pathology, with very few reported cases of ADH associated with gynecomastia.^[4] Only seven cases of IP have been reported in the indexed literature although often in females.^[5] Here, we report a rare case of an IP with ADH associated with gynecomastia in an elderly male.

This is an open access journal, and articles are distributed under the terms of the Creative Commons Attribution-NonCommercial-ShareAlike 4.0 License, which allows others to remix, tweak, and build upon the work non-commercially, as long as appropriate credit is given and the new creations are licensed under the identical terms.

For reprints contact: reprints@medknow.com

Case Report

A 60-year-old healthy male presented to the surgical outpatient clinic with complaints of right nipple pain; intermittent, reddish brown, and sometimes watery nipple discharge; and a subareolar mass measuring 1 cm in diameter noticed 6 months previously. Physical examination showed asymmetrical breasts with normal nipple–areolar complexes (NACs) with a firm, tender, well-circumscribed nodular mass palpable in the right retroareolar region. No erythema or dimpling in the skin was noted. The remaining right and left breasts were normal. No palpable bilateral axillary or supraclavicular lymph nodes were found. There was no history of local trauma, recent weight loss, and use of anabolic steroids or other drugs that cause gynecomastia. The family history was negative. Bilateral mammography showed an enlargement of the right nipple

How to cite this article: Bharti S, Bharti JN, Vishnoi JR, Soudamini AB. A rare case of intraductal papilloma with atypical ductal hyperplasia in a male breast: A pathological diagnosis. J Fam Community Med 2020;27:216-8.

Departments of Pathology and ¹Surgical Oncology, All India Institute of Medical Sciences, Jodhpur, Rajasthan, India

Address for correspondence:

Dr. Jyotsna Naresh Bharti,
Type III Quarters,
301/6, All India Institute
of Medical Sciences,
Jodhpur Residential
Complex, Basni Phase
II, Jodhpur - 342 005,
Rajasthan, India.
E-mail: jyotsnamamc@
gmail.com

Received: 29-06-2020

Revised: 06-07-2020

Accepted: 12-08-2020

Published: 25-09-2020

than the left with a small, irregular, spiculated lesion measuring 0.5 cm × 0.4 cm × 0.5 cm in the retroareolar region of the right breast [Figure 1]. However, there was no evidence of calcification and any architectural distortion and skin thickening in the right breast. It was graded as Breast Imaging-Reporting and Data System 4B with unremarkable bilateral axillary lymph nodes and left breast.

Cytology of nipple discharge was negative for malignancy. Fine-needle aspiration cytology from the mass was rendered as a proliferative breast lesion with atypia. Considering the age of the patient, mammography, and FNA findings, right modified radical mastectomy (MRM) was planned. We received the right MRM specimen. On sectioning through NAC, a well-circumscribed, retroareolar nodule measuring 1 cm in diameter was identified along with 26 lymph nodes extracted from the axillary tail, with the largest measuring 2 cm in diameter. Microscopy revealed an IP with dilated cystic structures with a papillary proliferation of epithelial cells with central cores [Figure 2a and b] without atypia and foci of ADH [Figure 2c]. The rest of the breast parenchyma was unremarkable. Lymph nodes showed features of reactive hyperplasia. No evidence of invasive malignancy was seen. The cells were strong and diffuse positive for estrogen receptor [Figure 2d], but calponin and smooth muscle actin were focally positive. The final diagnosis of IP with ADH was rendered. The postoperative course was uneventful, and the patient has continued medical follow-up.

Discussion

Male breast disease is usually unrecognized because of a lack of awareness, rarity of the disease, and little epidemiological data available in literature compared to that of the female breast.^[5,6] Male and female breasts are similar at birth. Subareolar ducts are histologically similar to ducts in prepubertal girls. A adult normal male breast consists mainly of large ducts without lobule and acini formation, which generally do not extend beyond the central subareolar portion. The ducts are embedded in the fibrous stroma and adipose tissue. The pectoralis muscle is more prominent, but lacks suspensory ligament of Cooper as there is no lobular unit.^[3] However, pathological gynecomastia can occur in any age group.^[4] The risk factors are similar for all breast lesions and include age, family history, endocrine and hormonal imbalance, Klinefelter syndrome, systemic diseases, neoplasms, medications, and obesity as well as a history of orchitis or testicular tumor, liver disease, thoracic radiotherapy, and genetic predisposition such as BRCA 2 gene and P53.^[2,7] Retroareolar mass in men can be of benign or malignant lesions such as IP or any soft-tissue tumors. The clinical presentation of benign

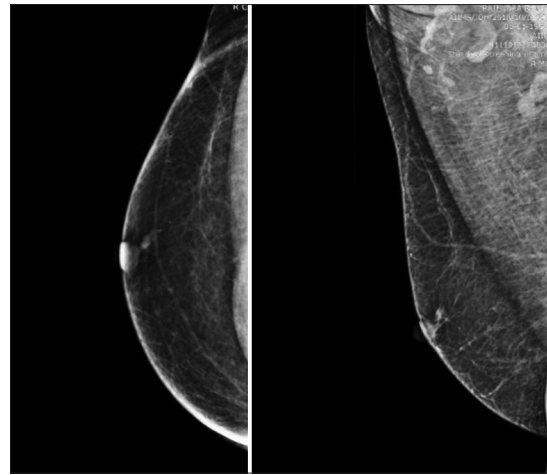


Figure 1: Right breast mammography showing a small, irregular, spiculated lesion in the retroareolar region

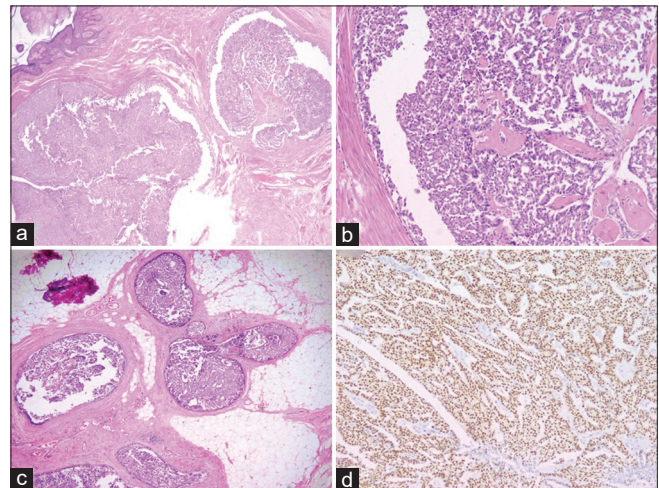


Figure 2: (a) Intraductal papilloma showing an intraluminal papillary lesion within a dilated duct along with epithelial hyperplasia (H and E, ×10). (b) Intraductal papilloma showing fibrovascular cores (H and E, ×40). (c) Atypical ductal hyperplasia showing solid hyperplasia and monotonous population (H and E, ×10). (d) Immunohistochemically showing strong and diffuse nuclear positivity of estrogen receptor

papilloma, malignant papilloma, *in situ* carcinoma, or invasive carcinoma is similar as single-duct bloody or serous discharge or discharge associated with a palpable, unilateral, hard, fixed lesion in the subareolar region in elderly males.^[7,8] It may be associated with skin changes or axillary lymphadenopathy. Although gynecomastia followed by lipoma and epidermal inclusion cysts is commonly seen in males,^[7] gynecomastia can be seen in association with IP, ADH, and invasive carcinoma.^[4]

Microscopy of IP shows an epithelium containing both luminal and myoepithelial cells and abundant stroma, forming a few broad fronds. ADH is defined as the filling and distension of the involved ducts by a monotonous population of hyperchromatic, small- to medium-sized, rounded, cuboidal, or polygonal cells, which remain

regularly spaced, sometimes with cribriform spaces or micropapillary formation.^[4,9] In the present case, IP with ADH was noted in a gynecomastia patient. This case is unique because both lesions are rarely seen in a male breast, and in this case, they were seen together and were associated with gynecomastia. ADH and low-grade DCIS have similar histological features, but ADH is a benign condition and the relative risk for future breast cancer is 4, but DCIS is more extensive and has the relative risk of 8–10 for later breast carcinoma.^[10] The clinical and radiological features are not sensitive and specific for the differentiation of benign and malignant papillary lesions.^[9] Therefore, cytological features or surgical excision is needed for appropriate diagnosis and treatment,^[8] as breast malignancy in males rapidly progresses to an advanced stage because the parenchyma in a male breast is inadequate and as a result presents with secondary signs of nipple retraction, fixation to deep tissue, skin ulceration, and lymphadenopathy.^[3] Breast cancer mortality rate is high in men because mammography screenings are fewer and consequently, detection in men compared to females is usually late.^[1,6,7]

Conclusion

The incidence of breast cancer in males and females has increased in the past 25 years. Owing to the lack of awareness and screening mammography and the resultant delayed diagnosis, there is a high mortality in men. Gynecomastia can be associated with IP, ADH, and invasive carcinoma with different clinical presentations. In addition, ADH and low-grade DCIS have similar histological features. Therefore, surgical excision and meticulous histopathological evaluation is mandatory.

Declaration of patient consent

The authors certify that they have obtained all appropriate

patient consent forms. In the form, the patient has given his consent for his images and other clinical information to be reported in the journal. The patient understands that his name and initial will not be published, and due efforts will be made to conceal his identity, but anonymity cannot be guaranteed.

Financial support and sponsorship

Nil.

Conflicts of interest

There are no conflicts of interest.

References

1. Siegel RL, Miller KD, Jemal A. Cancer statistics, 2017. *CA Cancer J Clin* 2017;67:7-30.
2. Yalaza M, İnan A, Bozer M. Male breast cancer. *J Breast Health* 2016;12:1-8.
3. Popli MB, Popli V, Bahl P, Solanki Y. Pictorial essay: Mammography of the male breast. *Indian J Radiol Imaging* 2009;19:278-81.
4. Wells JM, Liu Y, Ginter PS, Nguyen MT, Shin SJ. Elucidating encounters of atypical ductal hyperplasia arising in gynecomastia. *Histopathology* 2015;66:398-408.
5. Vagios I, Nonni A, Liakea A, Constantinidou A, Kontos M. Intraductal papilloma of the male breast: A case report and review of the literature. *J Surg Case Rep* 2019;2019:rjz023.
6. Anderson WF, Jatoi I, Tse J, Rosenberg PS. Male breast cancer: A population-based comparison with female breast cancer. *J Clin Oncol* 2010;28:232-9.
7. Yitta S, Singer CI, Toth HB, Mercado CL. Image presentation. Sonographic appearances of benign and malignant male breast disease with mammographic and pathologic correlation. *J Ultrasound Med* 2010;29:931-47.
8. Al Sarakbi W, Worku D, Escobar PF, Mokbel K. Breast papillomas: Current management with a focus on a new diagnostic and therapeutic modality. *Int Semin Surg Oncol* 2006;3:1.
9. Lam WW, Chu WC, Tang AP, Tse G, Ma TK. Role of radiologic features in the management of papillary lesions of the breast. *AJR Am J Roentgenol* 2006;186:1322-7.
10. Degen AC, Visscher DW, Berman HK, Frost MH, Sellers TA, Vierkant RA, *et al.* Stratification of breast cancer risk in women with atypia: A Mayo cohort study. *J Clin Oncol* 2007;25:2671-7.