

# Bipolar herpes simplex infection in an human immunodeficiency virus-infected individual

Sonia Raghukumar, C. B. Ravikumar

Department of Dermatology, Hassan Institute of Medical Sciences, Hassan, Karnataka, India

---

## Address for correspondence:

Dr. C. B. Ravikumar, Department of Dermatology, Hassan Institute of Medical Science, Hassan - 573 201, Karnataka, India.  
E-mail: dr.ravikumarbc@gmail.com

---

## Abstract

Herpes simplex infection is the most common infection among the human immunodeficiency virus-infected individuals. However, the atypical manifestations of herpes simplex virus may confound even an astute physician. Hand involvement is rarely associated with genital herpes infection and the involvement of widespread areas healing with debilitating scarring is uncommon.

**Key words:** Bipolar herpes, coinfection, herpes simplex infection, human immunodeficiency virus infection

---

## INTRODUCTION

Herpes simplex virus (HSV) infection is a highly prevalent sexually transmitted disease and is the most common infection among the human immunodeficiency virus (HIV)-infected individuals.<sup>[1]</sup> In these patients, it may produce excessive lesions, as a primary infection or as a reactivated infection.<sup>[2]</sup> The atypical manifestations of HSV in an HIV-infected individual often construe a deceptive clinical picture, challenging the diagnostic acumen of even experienced dermatologists. Here, we report one such case of HSV infection with bipolar genital and hand involvement in the form of painful hemorrhagic crusted plaques, healing with scarring and contractures.

## CASE REPORT

A 35-year-old female presented with widespread painful crusted skin lesions over both palms and digits [Figure 1]. The largest lesion ranged from 3 cm × 5 cm and the smallest from 2 cm × 2 cm.

They were preceded by discrete deep-seated vesicles 2 weeks earlier, which ruptured within a day or two and coalesced to form plaques with minimal discharge. On examination, well-demarcated plaques were present, associated with thick, adherent reddish yellow crusts, accompanied by a foul-smelling odor and tenderness. Contracture of the middle finger of the right hand was observed owing to similar lesions in the past.

Further, genital examination revealed numerous painful genital ulcers over the labia majora, labia minora, and inner aspect of the thigh covered with a pale creamy discharge [Figure 2]. The inguinal lymph nodes were enlarged and tender. The lesions over the hand and genitalia appeared simultaneously.

The history of a similar episode was present 2 years ago; however, the treatment details could not be traced. She was diagnosed to be HIV positive 10 years ago and has been on regular “highly active antiretroviral treatment” since then.

Her CD4 count at the time of presentation to us was 236 cells/mm.<sup>[3]</sup>

Bacterial and fungal cultures failed to show any growth. Biopsy displayed nonspecific features and the laboratory parameters were unremarkable except for hemoglobin of 9.2 g%. The serological test for HSV IgM was strongly positive. Polymerase chain reaction and viral cultures could not be carried out due to unavailability and cost constraints.

Episodic treatment with tablet acyclovir 400 mg per oral, 5 times daily, was started for 2 weeks until the lesions healed completely.

One month later, she presented again with vesicles over the palms and with genital ulcers, and contractures from the previous episode were evident [Figure 1]. Biopsy of the vesicle for histopathological examination was consistent with herpes virus infection revealing an intraepidermal vesicle containing balloon cells, neutrophils, nuclear debris, and fibrin strands. Balloon cells were noted to have pale gray nuclei, some being multinucleated. Dense mononuclear infiltrate was present in the upper dermis [Figure 3].

The patient was commenced on suppressive therapy with tablet acyclovir 400 mg orally, 2 times daily, to which she responded satisfactorily. Follow-up at 6 months showed no new lesions.

## DISCUSSION

Contrary to HSV infection in an immunocompetent host, patients with HIV infections often exhibit atypical clinical manifestations.<sup>[3]</sup> The severity and duration of recurrent genital herpes may be more appalling than that seen in normal hosts<sup>[4]</sup> and is generally more necrotic and painful and further tends to slowly.<sup>[2]</sup>

The severity of the illness depends on several factors such as the anatomic site of the initial infection, degree of immunosuppression and whether the clinical episode represents a primary or recurrent infection.<sup>[4]</sup> Lesions in these patients may occur at unconventional sites such as buttocks and

lower back with several unusual manifestations such as hyperkeratotic verrucous lesions, deep necrotizing lesions, necrotic papules and pustules, and pseudotumoral lesions.<sup>[2,4,5]</sup> These atypical HSV infections may occur either in the context of severe immunosuppression, as part of an immune reconstitution syndrome or in stable patients on combination antiretroviral therapy with good CD4 counts.<sup>[3]</sup>

Incidences of extragenital herpes during a primary genital infection maybe 9%–25%.<sup>[5]</sup> However, the involvement of fingers accounts to <1%.<sup>[5]</sup> The hand herpetic lesions may mimic one of the following clinical patterns described such as the appearance of genital lesions, followed by hand lesions (autoinoculation), oral lesions, followed by hand lesions such as thumb lesions following herpetic stomatitis in thumb-sucking children or nail-biting adults, hand involvement first or in isolation as seen with inoculation of infected oral secretions by health-care professionals or simultaneous development of hand and genital lesions.<sup>[6,7]</sup> Our patient developed repeated episodes of simultaneous involvement of the genitalia and the hand. The proposed etiologies for simultaneous development are hematogenous dissemination or due to periodic reactivation during which the virus moves from the ganglia to the skin or less likely due to self-inoculation.

Anti-HSV nucleoside analogs (acyclovir, valacyclovir, and famciclovir) are the mainstay of treatment for genital herpes simplex. Based on the clinical profile of the patient, episodic and/or suppressive anti-HSV treatment needs to be instituted. They have a high therapeutic index, safe, and without any significant interactions with the antiretroviral medications. The benefits of suppressive anti-HSV therapy go beyond the clinical benefits of the symptomatic person.<sup>[1]</sup> Besides enabling the resolution of lesions, it reduces the incidences of reactivation of HSV and more importantly, has been demonstrated to reduce both the plasma and mucosal shedding of HIV thus

This is an open access journal, and articles are distributed under the terms of the Creative Commons Attribution-NonCommercial-ShareAlike 4.0 License, which allows others to remix, tweak, and build upon the work non-commercially, as long as appropriate credit is given and the new creations are licensed under the identical terms.

**For reprints contact:** WKHLRPMedknow\_reprints@wolterskluwer.com

**How to cite this article:** Raghukumar S, Ravikumar CB. Bipolar herpes simplex infection in an human immunodeficiency virus-infected individual. *Indian J Sex Transm Dis* 2021;42:72-5.

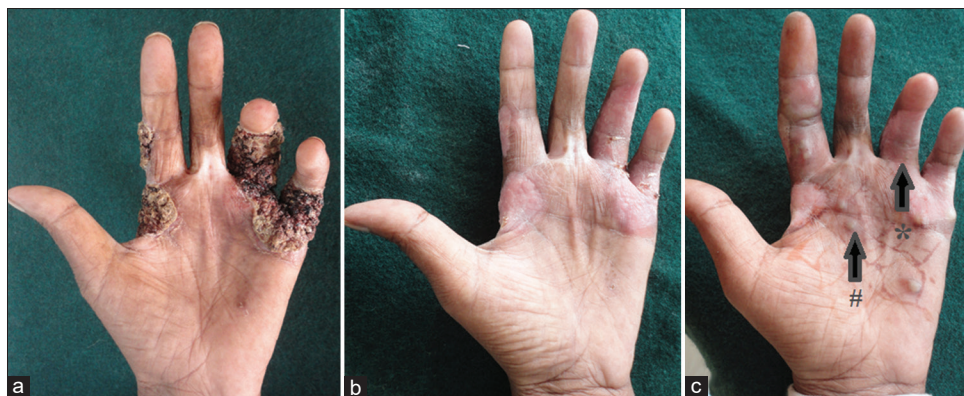**Submitted:** 15-Apr-2017

**Revised:** 17-Aug-2017

**Accepted:** 31-Aug-2020

**Published:** 15-Feb-2021

Access this article online	
<b>Quick Response Code:</b> 	<b>Website:</b> <a href="http://www.ijstd.org">www.ijstd.org</a>
	<b>DOI:</b> 10.4103/ijstd.IJSTD_43_17



**Figure 1: Hand involvement in herpes simplex (a) Crusted verrucous plaques on presentation. (b) Complete resolution, 2 weeks after tablet acyclovir 400 mg, TID. (c) Two months later; #fresh vesicle, \*contracture upon healing**

serving as an additional public health benefit and increasing the survival.<sup>[1]</sup>

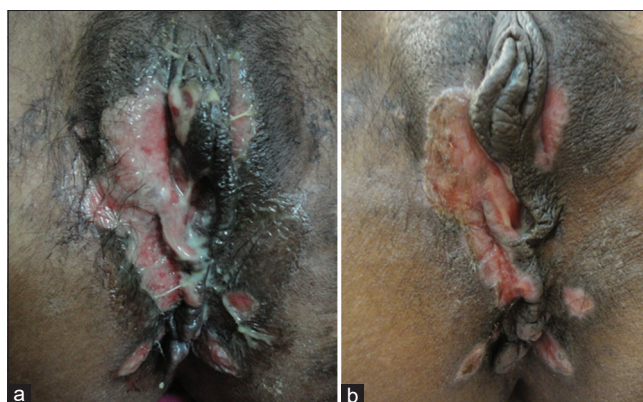
### Some general wound-care principles apply to all hand infections<sup>[1,2]</sup>

Excessive scarring following HSV infection in an HIV-infected individual is the norm. However, widespread lesions over hands should not be neglected as they heal with contractures further escalating the morbidity of the patient.

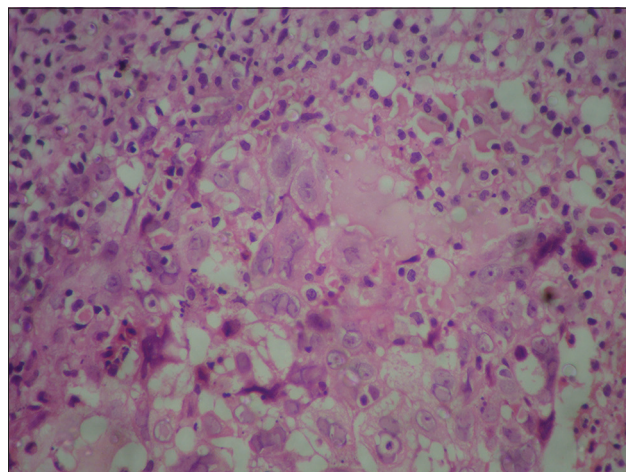
It is established that most hand infections can be treated with an initial period of rest, immobilization, and elevation.<sup>[8,9]</sup> Splint immobilization and elevation can protect the affected area, minimize edema, and decrease pain. Splinting depends on the site of involvement. If a single digit is infected, a finger splint supporting the interphalangeal joints in extension is usually adequate. If the palm, the metacarpophalangeal joint, or larger portions of the hand are infected, splinting in a position of function can help protect against flexion contractures and hasten rehabilitation.<sup>[8,9]</sup> Hence, in addition to antiviral therapy, it is imperative to educate the patient about the importance of exercise, physiotherapy, and rehabilitation to avoid debilitating deformities.

### CONCLUSION

Diagnosing the atypical manifestations of HSV in an HIV-infected individual requires a high index of clinical suspicion. Painful and hemorrhagic crusted plaques over the hands and in an HIV-infected individual must raise the possibility of HSV infection before other etiologies are sought for. This case is presented here for its unique morphology unusually progressing to form contractures and also to highlight the importance of physiotherapy in preventing deformities in such patients.



**Figure 2: Genital involvement in herpes simplex (a) Ulcer covered with creamy discharge. (b) Healing following treatment with tablet acyclovir 400 mg, TID**



**Figure 3: Histopathology picture showing ballooning degeneration, with some being multinucleated. Mononuclear infiltrate is seen in the upper dermis**

### Declaration of patient consent

The authors certify that they have obtained all appropriate patient consent forms. In the form the patient(s) has/have given his/her/their consent for his/her/their images and other clinical information to be reported in the journal. The patients understand that

their names and initials will not be published and due efforts will be made to conceal their identity, but anonymity cannot be guaranteed.

### Financial support and sponsorship

Nil.

### Conflicts of interest

There are no conflicts of interest.

### REFERENCES

1. Strick LB, Wald A, Celum C. Management of herpes simplex virus type 2 infection in HIV type 1-infected persons. *Clin Infect Dis* 2006;43:347-56.
2. Tyring SK, Carlton SS, Evans T. Herpes. Atypical clinical manifestations. *Dermatol Clin* 1998;16:783-8.
3. McKendry A, Narayana S, Browne R. Atypical presentations of genital herpes simplex virus in HIV-1 and HIV-2 effectively treated by imiquimod. *Int J STD AIDS* 2015;26:441-3.
4. Lupi O. Prevalence and risk factors for herpes simplex infection among patients at high risk for HIV infection in Brazil. *Int J Dermatol* 2011;50:709-13.
5. Benedetti JK, Zeh J, Selke S, Corey L. Frequency and reactivation of nongenital lesions among patients with genital herpes simplex virus. *Am J Med* 1995;98:237-42.
6. Gill MJ, Arlette J, Buchan K. Herpes simplex virus infection of the hand. A profile of 79 cases. *Am J Med* 1988;84:89-93.
7. Osio A, Fremont G, Petit A, Scieux C, Dubertret L, Janier M, *et al.* An unusual bipolar primary herpes simplex virus 1 infection. *J Clin Virol* 2008;43:230-2.
8. Hausman MR, Lisser SP. Hand infections. *Orthop Clin North Am* 1992;23:171-85.
9. Clark DC. Common acute hand infections. *Am Fam Physician* 2003;68:2167-76.