

Suleyman Kutluhan
Fidan Incekara
Ayşe Sozen
Hasan Rifat Koyuncuoglu
Rukiye Tak
Osman Gokalp
Fatih Gultekin

Temporary confusion depending on the usage of naratriptan

Received: 3 October 2007
Accepted in revised form: 8 October 2007
Published online: 17 December 2007

S. Kutluhan (✉) • F. Incekara • A. Sozen •
H. R. Koyuncuoglu • R. Tak
Department of Neurology, Medical Faculty,
Süleyman Demirel University
A.D. 32260 Isparta, Turkey
e-mail: skutluhan@hotmail.com
Fax: +90-246-2370240

O. Gokalp
Department of Pharmacology,
Medical Faculty, Süleyman Demirel
University

F. Gultekin
Department of Biochemistry,
Medical Faculty, Süleyman Demirel
University

Abstract In this report, a case with vitamin B12 deficiency showing a temporary confusion depending on the usage of naratriptan during the migraine attack was presented.

Keywords Naratriptan • Headache •
Vitamin B12 deficiency • Confusion

Introduction

Triptans are used very often in the treatment of migraine attacks. [1] Common side effects are tingling, numbness, a sensation of warmth, heaviness and pressure or tightness in different parts of the body including the chest and neck. [2] In addition, there are some other side effects such as agitation, aphasia, ataxia, confusion, tremor and vertigo. [3] Naratriptan is a second-generation triptan antimigraine drug. It is a 5-HT_{1B/1D} receptor agonist with a highly selective action on migraine pain and nausea, without significant effect on other pain or even other trigeminal pain [4].

Here, a case with vitamin B12 deficiency showing temporary confusion depending on the usage of naratriptan during the migraine attack is presented.

Case report

A 45-year-old woman with no specific medical and severe headache history was brought to the emergency service with a complaint of acute headache. Headache was unilateral, throbbing and came with nausea and photophobia. There was no pathologic evidence in physical and neurological examinations and the laboratory results were normal. Therefore, it was diagnosed as a migraine attack and common analgesics were applied. Her headache was not relieved. On the contrary, it increased. Then, 2.5-mg oral naratriptan tablet was given. After a while, the headache stopped. However, the next day she was brought to the emergency service again because of unconsciousness and not recognising the people around her. She was confused. Brain computed tomography was normal. On cranial

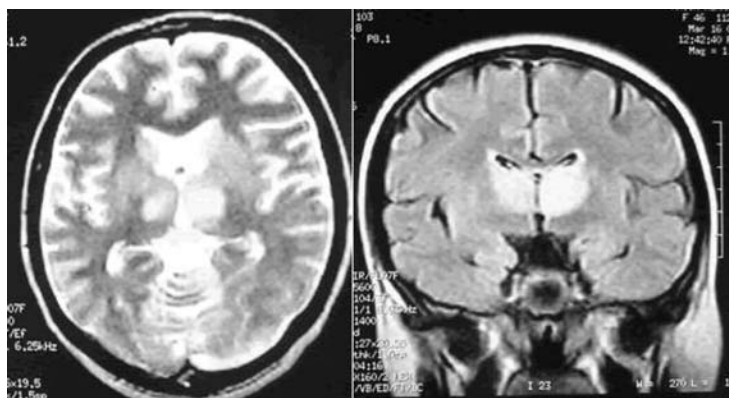


Fig. 1 In cranial MRG, hyperintense views which were determined TW2 and FLAIR sequences in bilateral basal ganglia

magnetic resonance imaging (MRI) TW2 and FLAIR sequences, bilateral basal ganglia hyperintensity was detected. On TW1 sequences no signal abnormality was seen (Figure 1). On the second day, she regained conscious. During the further laboratory examinations, carbon monoxide intoxication, Wilson disease, vasculitis and paraneoplastic syndrome were excluded. On the other hand, vitamin B12 level was found to be low (154 pg/mL, normal range 193–986 pg/mL) and replacement was started. The treatment of the patient was reorganised and she was monitored. Control cranial MRI performed three months later was normal. As a result, the case was diagnosed as confusion related to naratriptan usage.

Discussion

Although the etiology of CNS side-effects occurring with oral triptans is still unclear, the occurrence of these side-effects could be related to a number of factors. The differences in the pharmacokinetic profiles of each drug, such as bioavailability, lipophilicity, or metabolism may be important [3]. Naratriptan

has high lipophilicity ($(\log D(\text{pH})7.4 = -2.1$ almotriptan < -1.5 sumatriptan < -1.0 zolmitriptan < -0.7 rizatriptan < -0.2 naratriptan < 0.5 eletriptan) [5]. Lipophilic drugs of any therapeutic class tend to cause adverse events involving the CNS [6]. Also, Waeber and Moskowitz showed that 5-HT_{1B/1D} receptors which have a high affinity for naratriptan were placed in substantia nigra, periaqueductal gray matter, interpeduncular nucleus, hippocampus and superior colliculus [7].

In vitamin B12 deficiency, cerebral symptoms, such as mental slowing, depression, confusion, delusions and hallucinations are quite common, and occasionally patients present with only cognitive or psychiatric symptoms [8,9]. Our patient lost his conscious acutely and regained after a day. We thought that, because of its lipophilic feature and high affinity for the region around basal ganglion, naratriptan usage for migraine attack may lead to the transient and curable conscious change in the patient with vitamin B12 deficiency.

Even though naratriptan is commonly used in the treatment of migraine attacks, neurological side effects should not be disregarded. Advanced biochemical examinations should be done on patients showing side effects to naratriptan.

References

1. Tfelt-Hansen P (2007) Acute pharmacotherapy of migraine, tension-type headache and cluster headache. *J Headache Pain* 8:127–134
2. Nappi G, Sandrini G, Sances G (2003) Drug safety 26:93–107
3. Dodick DW, Martin V (2004) Triptans and CNS side effects: pharmacokinetic and metabolic mechanisms. *Cephalalgia* 24:417–424
4. Lambert GA (2005) Preclinical neuropharmacology of naratriptan. *CNS Drug Reviews* 11:289–316
5. Pascual J, Muñoz P (2005) Correlation between lipophilicity and triptan outcomes. *Headache* 45:3–6
6. So YT, Simon RP (2004) Deficiency disease of the nervous system. In: Bradley WG, Daroff RB, Fenichel GM, Jankovic J. *Neurology in Clinical Practice, The neurological disorders fourth edition*. Philadelphia, PA, pp 1694
7. Waeber C, Moskowitz MA (1997) 5-Hydroxytryptamine 1A and 5-hydroxytryptamine 1B receptors stimulate [³⁵S]guanosine-5'-O-(3-thio)triphosphate binding to rodent brain sections as visualized by in vitro autoradiography. *Mol Pharmacol* 52:623–631
8. Lucke T, Korenke GC, Poggenburg I et al (2007) Maternal vitamin B12 deficiency: cause for neurological symptoms in infancy. *Z Geburtshilfe Neonatol* 211:157–161
9. Juhasz-Pocsine K, Rudnicki SA et al (2007) Neurologic complications of gastric bypass surgery for morbid obesity. *Neurology* 68:1843–1850