


RESEARCH ARTICLE

Open Access



# Single-stage posterior debridement, decompression and transpedicular screw fixation for the treatment of thoracolumbar junction (T12-L1) tuberculosis with associated neurological deficit: a multicentre retrospective study

Yanping Zeng<sup>1†</sup>, Wenjie Wu<sup>1†</sup>, Jingtong Lyu<sup>1</sup>, Xun Liu<sup>1</sup>, Jiulin Tan<sup>1</sup>, Zhilin Li<sup>2</sup>, Yuan Chen<sup>3</sup>, Litao Li<sup>4</sup>, Yonghong Zheng<sup>5</sup>, Gaoju Wang<sup>6</sup>, Jianzhong Xu<sup>1\*</sup>  and Zehua Zhang<sup>1\*</sup>

## Abstract

**Background:** A multicentre retrospective study was conducted to evaluate the safety and efficacy of single-stage posterior debridement, decompression and transpedicular screw fixation for the treatment of thoracolumbar junction (T12-L1) tuberculosis in patients with associated neurological deficit.

**Methods:** Thoracolumbar junction (T12-L1) tuberculosis patients ( $n = 69$ ) with neurological deficit who underwent single-stage posterior debridement, decompression and transpedicular screw fixation from January 2005 to January 2015 were included in the study. Antituberculosis therapy was performed both before and after surgery. The surgery duration and patient blood loss were evaluated, in addition to the change in pain visual analogue score (pVAS), kyphotic angle, Oswestry disability index (ODI) score and American Spinal Injury Association (ASIA) grade assessed preoperatively, immediate postoperatively and at the final follow-up visit.

**Results:** The average blood loss was  $354 \pm 291$  mL. The average kyphosis angle was corrected from  $21 \pm 9^\circ$  preoperatively to  $9 \pm 4^\circ$  postoperatively, with a mean decrease in pVAS and ODI scores of 3.4 and 16, respectively. The postoperative ASIA grading was grade A for five patients, grade C for 15 and grade D for 49 patients, which had improved to grade C for four patients, grade D for three patients and grade E for 62 patients at the final follow-up. The neurological deficit did not worsen in any of the patients.

**Conclusions:** Single-stage posterior debridement, decompression and transpedicular screw fixation is an effective treatment method in thoracolumbar junction (T12-L1) tuberculosis patients with neurological deficit, with good neurological recovery and no progression of kyphosis.

**Keywords:** Spinal tuberculosis, Thoracolumbar junction, Neurological deficit, Posterior decompression

\* Correspondence: [xujzspine@126.com](mailto:xujzspine@126.com); [zhangzehuattmmu@163.com](mailto:zhangzehuattmmu@163.com)

<sup>†</sup>Yanping Zeng and Wenjie Wu contributed equally to this work and should both be considered first authors.

<sup>1</sup>Department of Orthopaedics, Southwest Hospital, Third Military Medical University, Chongqing 400038, China

Full list of author information is available at the end of the article



## Background

Tuberculosis poses a serious impact to human health, particularly in developing countries [1–3]. China still has the second greatest number of infected people worldwide [4]. The thoracolumbar spine is one of the major targets of metastatic tuberculosis of the musculoskeletal system [5]. It most commonly affects the thoracolumbar junction [6], and about 10–43% of patients with spinal tuberculosis have associated neurological complications [7]. Spinal tuberculosis may result in spinal deformities and paralysis, and it represents one of the most dangerous pathologies affecting the musculoskeletal system [8].

Chemotherapy and surgery can both achieve satisfactory results with timely diagnosis and long-term treatment [4]. Conservative treatment with antituberculous drugs and external immobilisation remain the preferred treatment options in most cases of spinal tuberculosis [9–12]. Mild spinal tuberculosis can be treated with standard chemotherapy alone [13]. Surgery is necessary for cases of spinal tuberculosis with spinal instability, neurological deficit and severe and/or progressive kyphosis deformity, as well as for patients who do not respond to chemotherapy or those with a large paraspinal abscess [14]. Suitable surgical intervention in a timely manner can improve the stability of the spine, eliminate compression on the spinal cord and prevent the progression of deformity, paralysis or death. Various surgical approaches have been used for the treatment of patients with spinal tuberculosis, including an anterior, antero-posterior or posterior only approach [15–17]. However, the optimum surgical approach remains uncertain amongst surgeons. Traditionally, the anterior spinal approach has been preferred for cases where the vertebral bodies and disc spaces are the main sites affected by tuberculosis as this approach provides direct access to the infection foci, making it convenient for debridement and reconstruction [18, 19]. However, advances in instrumentation systems and techniques have led to the increasing popularity of the posterior approach for the correction of kyphosis and spine stabilisation [20–22]. This approach has been proven to be effective for the treatment of many thoracolumbar and lumbar spinal disorders that lead to segmental instability [23]. In recent years, the treatment strategy for spinal tuberculosis has become more conservative and less invasive [24].

Although the use of the posterior approach for patients with spinal tuberculosis is widespread, to our knowledge, no studies have reported the effectiveness and safety of single-stage posterior debridement, decompression and transpedicular screw fixation for monosegmental spinal tuberculosis in patients with neurological deficit, focusing on the thoracolumbar junction (T12-L1) only. In this study, we report our findings regarding the treatment of patients with thoracolumbar junction tuberculosis and a related neurological deficit by this approach.

## Methods

The records of 33 men and 36 women who underwent single-stage posterior debridement, decompression and transpedicular screw fixation for thoracolumbar junction (T12-L1) tuberculosis with associated neurological deficit between January 2005 and January 2015 from six hospitals across China were reviewed. Patients were followed up for a minimum of 24 months. The average patient age was  $35.06 \pm 8.86$  years (range 16–53 years). In this study, we did not include patients with HIV co-infection.

The diagnosis of spinal tuberculosis was made based on clinical symptoms, physical signs, laboratory findings and radiological evidence. It was confirmed histologically after debridement in surgical patients. The ASIA score was used to evaluate the neurological function of patients, with five patients preoperatively classified as grade A, 15 patients as grade C and 49 patients as grade D. pVAS was used to evaluate several clinical factors including back pain for all patients. The Cobb technique was used to assess the local kyphotic angle. The ODI score was used to evaluate the functional outcome of patients. Only patients who had thoracolumbar junction tuberculosis with a neurological deficit were included in this study. Those patients who received conservative treatment, who were not affected in the T12-L1 segmental vertebrae only, or who could not undergo vertebral fixation were excluded from the study.

### Preoperative management

All cases were administered a chemotherapy regimen (isoniazid 300 mg/day, rifampicin 450 mg/day, ethambutol 750 mg/day and pyrazinamide 750 mg/day) for 2–4 weeks prior to the operation. Preoperative haemoglobin and ESR levels needed to be higher than 100 g/L and no higher than 40 mm/L, respectively, before surgery.

### Operation technique

All patients underwent general endotracheal anaesthesia, after which they were placed in the prone position on the spinal Table. A standard dorsal midline incision was performed, and the posterior tissues were exposed. Pedicle screws were inserted, and the correct placement was confirmed by intraoperative C-arm fluoroscopy. In general, the two superior and two inferior healthy vertebrae were embedded into the pedicle screw to ensure rigid spinal stability. A temporary pre-bent rod was installed on the side where the lesion was relatively mild in order to avoid spinal cord injury during decompression and focal debridement. A unilateral or bilateral Laminectomy was done according to the extent of cord compression. Then facetectomy and pediclectomy were performed at appropriate levels. The surgical area was washed with hydrogen peroxide and a large quantity of saline. Any abscesses, granulation tissue, sequestra, caseous necrosis, necrotic endplates and discs

were debrided as thoroughly as possible via the transpedicular space. Then, a pre-bent rod was temporarily installed on the other side and the rod installed previously was removed. The same process was performed on the side opposite to the lesion. Posterolateral fusion using autograft of suitable size or a titanium cage containing cancellous bone from the iliac crest was performed. The compression and expansion of the internal fixation instrument was used to rectify the kyphosis and scoliosis gradually and carefully, then the contoured rods were tightened. Finally, streptomycin (1.0 g) and isoniazid (0.3 g) were locally administered, and a local drainage tube was placed in the operation site before the incision was closed.

### Postoperative care

The drainage tube was removed when the amount of postoperative drainage was less than 10 ml/day. Preventive antibiotic treatment was administered during the first 48 h after the operation. All patients were recommended to wear the bracing apparatus until bony fusion was observed by radiography. Patients resumed oral Isoniazid, rifampicin, ethambutol, and pyrazinamide (HREZ) chemotherapy postoperatively, then pyrazinamide was discontinued at 6 months. Patients continued to receive a regimen of HRE chemotherapy for 9 to 12 months (6HREZ/9-12HRE) [25]. The liver function and ESR rates of the patients were carefully monitored at regular intervals. Follow-up examinations were conducted at 1, 3, 6, 12 and 18 months postoperatively. Subsequent follow-up examinations were performed at 12-month intervals.

### Statistical analysis

Continuous data are expressed as  $\bar{X} \pm$  standard deviation (SD). One-way ANOVA was used to evaluate the difference between preoperatively and postoperatively in ESR, pVAS score, ODI and kyphotic angle. Statistical analyses were performed using SPSS version 22 (SPSS, Inc., Chicago, USA). For all analyses, *P*-values less than 0.05 were considered significant.

### Results

Patients were aged between 16 and 53 years old, with an average age of  $35.06 \pm 8.86$  years at the time of surgery. The mean average blood loss volume was  $354 \pm 291$  mL (range 200–2200 mL). The average follow-up period was  $29.17 \pm 6.33$  months (range 24–52 months) (Table 1), with no patients lost to follow-up and no deaths. There

were no cases of non-union of bone, pseudarthrosis, internal fixation loosening or relapse at the final follow-up.

The ESR values of patients measured preoperatively, postoperatively and at the last follow-up are presented in Table 2. The average preoperative ESR value was  $36 \pm 22$  mm/h (range 2–99 mm/h), and the average values measured postoperatively and at the final follow-up were  $6 \pm 5$  mm/h (range 0–20 mm/h) and  $6 \pm 3$  mm/h (range 0–15 mm/h), respectively, which were within the normal range. Statistical analysis showed that there was a significant difference between the preoperative ESR values and those recorded 12 weeks postoperative ( $P < 0.05$ ). Significant differences in ESR also existed between 12 weeks postoperative and the final follow-up ( $P < 0.05$ ).

The average preoperative and postoperative spinal kyphotic Cobb's angles were  $21 \pm 9^\circ$  and  $9 \pm 4^\circ$ , respectively, and this difference was significant ( $P < 0.05$ ). The kyphosis angle was maintained at  $10 \pm 4^\circ$  on average at the final follow-up visit. Statistical analysis demonstrated that there was a significant difference between the postoperative angle and that measured at the final follow-up ( $P < 0.05$ ) (Fig. 1).

Severity grading according to the American Spinal Injury Association grading system is presented in Table 3. All patients had suffered from an evident neurological deficit before surgery. Of the 69 patients, 62 (89.86%) showed complete neurological recovery. According to ASIA grading, five patients were classified as grade A, 15 as grade C and 49 patients as grade D preoperatively. This had improved postoperatively to five patients classified as grade C, 16 as grade D and 48 as grade E, and at the final follow-up four patients were grade C, three were grade D and 62 were grade E. There was a significant difference between the preoperative and postoperative grades ( $P < 0.05$ ). The ODI scores decreased from  $36 \pm 9$  on average prior to surgery to  $20 \pm 8$  after surgery, with an average score at the final follow-up of  $4 \pm 3$ . The average preoperative and postoperative pVAS scores were  $6.0 \pm 1.5$  (range 3–9) and  $2.6 \pm 0.9$  (range 1–5), respectively. There was a significant difference between the preoperative and postoperative pVAS scores ( $P < 0.05$ ). At the final follow-up visit, the average pVAS score was calculated to be  $0.5 \pm 0.6$  (range from 0 to 2), and there was a significant difference between the postoperative and follow-up pVAS scores ( $P < 0.05$ ). There were four patients presented with water-electrolyte imbalance after surgery. Two patients experienced transient worse neurological deficit (grade D preoperatively to grade C postoperatively) but complete neurological recovery at the last follow-up. Six patients presented with anti-tuberculosis drug-induced liver and kidney dysfunction. Other complications such as

**Table 1** General data of study

Male/Femal	Age(years)	Follow-up time (mon)	Blood loss (ml)	Hospitalization day (days)
33/36	$35.06 \pm 8.86$	$29.17 \pm 6.33$	$354 \pm 291$	$26.36 \pm 7.04$

**Table 2** Clinical details of surgery

Schedule	ESR (mm/h)	VAS	ODI	Kyphosis angle (°)
Preoperative	36 ± 22	6.0 ± 1.5	36 ± 9	21 ± 9
postoperative	6 ± 5	2.6 ± 0.9	20 ± 8	9 ± 4
Final follow up	6 ± 3	0.5 ± 0.6	4 ± 3	10 ± 4

VAS visual analogue scale of pain, ESR erythrocyte sedimentation rate, Oswestry disability index (ODI) score

superficial or deep infection, cerebrospinal fluid leak, transpedicular screws loosening, slippage or fracture of graft, were not seen in patients of our study.

### Discussion

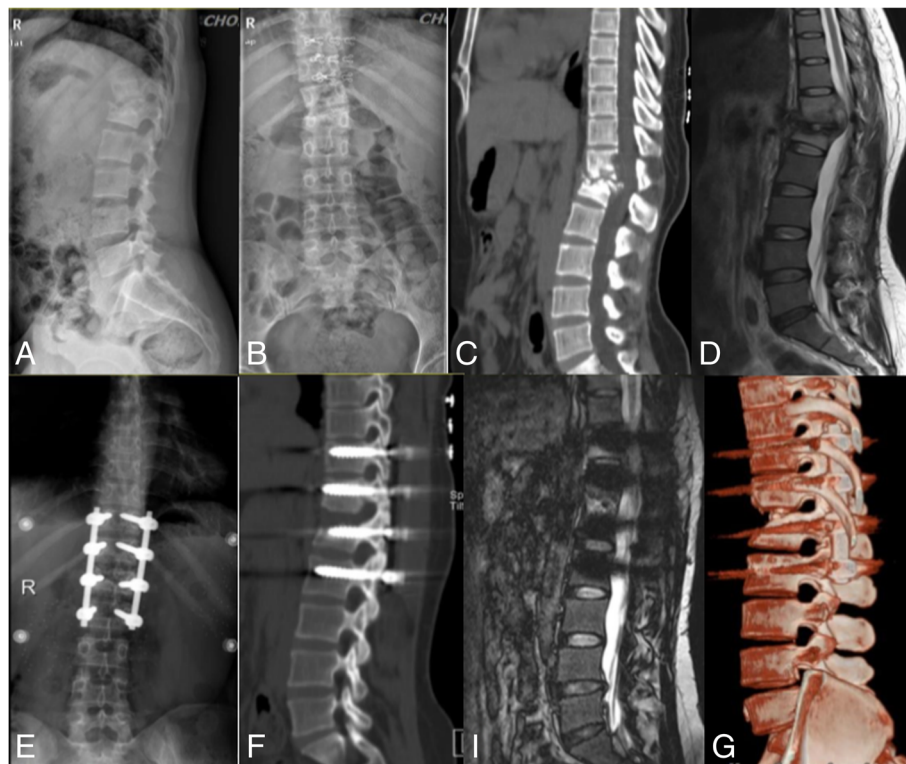
Our research shows that single-stage posterior debridement, decompression and transpedicular screw fixation is an effective and safe approach for the treatment of patients presenting thoracolumbar junction (T12-L1) tuberculosis with neurological deficits. However, standard antituberculosis chemotherapy, strict bed-rest and supportive therapy remain the fundamental approaches for treating spinal tuberculosis. Surgical intervention is only recommended for thoracolumbar spinal tuberculosis patients with significant neurological dysfunction [26].

**Table 3** The preoperative, postoperative and final follow up of neurological function was evaluated by ASIA grading

	Classification of neurological function by ASIA				
	A	B	C	D	E
Preoperative	5		15	49	
postoperative			5	16	48
Final follow up			4	3	62

In the present study, we evaluated the outcome of one-stage posterior debridement, decompression and transpedicular screw fixation for the treatment of 69 patients with thoracolumbar junction (T12-L1) tuberculosis and associated neurological deficits. The average blood loss of patients during surgery was  $354 \pm 291$  mL. This blood loss is lower than that reported by Rawall et al. [27], who reported an average blood loss of 419 mL. No perioperative complications appeared in the present study.

The ASIA scale scores recorded at the final follow-up visit were significantly better than the preoperative scores ( $p < 0.05$ ). Significant improvement in neurological grading was also evident, with complete neurological recovery of 89.86% of patients. This result is comparable with that reported in the study by Rawall et



**Fig. 1** Single-stage posterior debridement, decompression and transpedicular screw fixation of a 35-year-old woman with thoracolumbar junction tuberculosis with associated neurological deficit. (a, b) Preoperative lateral and anteroposterior X-rays; (c) preoperative computed tomography (CT); (d) preoperative MRI; (e) X-ray at 3 days postoperative; (f) CT scan at 12 months postoperative; (i) MRI at 12 months postoperative; and (g) 3D reconstruction of CT at 12 months postoperative.



al. [27] and better than that reported in the study by Zhang et al. [28]. The average pVAS scores of these cases decreased from  $6.0 \pm 1.5$  preoperatively to  $0.5 \pm 0.6$  at the final follow-up visit. The average preoperative and postoperative kyphotic Cobb angles recorded in the present study were  $21 \pm 9^\circ$  and  $9 \pm 4^\circ$ , respectively, which were significantly different ( $p < 0.05$ ). No intraoperative complications appeared in any of our cases. Thus, our study showed a satisfactory outcome in regard to the neurological dysfunction suffered by patients with thoracolumbar junction tuberculosis who were treated by a single-stage posterior debridement, decompression and transpedicular screw fixation approach.

Tuberculosis mainly affects the anterior column of the spine [29], and the most common form involves only a single motion segment. The anterior approach is preferred for decompression and debridement in spinal tuberculosis [14] as it allows direct access to the lesion site, radical debridement, adequate decompression and reduced muscle trauma.

Many experts believe that patients treated by the anterior approach experience greater blood loss. Furthermore, the duration of the operation itself and the hospitalisation period is longer than that of the posterior approach. Many authors report increased surgical complications associated with the anterior approach, such as nerve and vascular injuries [30, 31]. The advantages of the posterior approach include reduced bleeding and shorter hospitalisation and operation durations, in addition to relief of spinal nerve compression, corrected spinal kyphosis, regained spinal stability and improved quality of life. Moreover, the posterior approach may be a better surgical method in patients with less involved spinal tuberculosis for the anterior column that is mainly affected by tuberculosis achieving spontaneous fusion [32, 33]. Additionally, posterior pedicle screw fixation may improve neurological recovery, as rigid stabilisation enhances neurological improvement in patients with traumatic spinal cord injury [34].

We are also aware of the potential risk of tuberculosis spreading to the healthy posterior regions, as posterior debridement can result in diffusion of infection and fistulas. The stability of the spine would theoretically be affected because the normal posterior column of the spine can be destroyed due to debridement and decompression in this procedure. Fortunately, these complications were not found in our study. Long-term follow-up is needed to closely monitor the development of these potential complications.

Our research had some limitations. Firstly, it was a retrospective study rather than a prospective study. Secondly, the sample size was small. In addition, all surgeries were performed by the respective surgical team of the six teaching hospitals, which may cause a certain degree of bias due to differences in proficiency and ability.

## Conclusions

Our study demonstrated that single-stage posterior debridement, decompression and transpedicular screw fixation can be an effective treatment method for most patients with thoracolumbar junction (T12-L1) tuberculosis and associated neurological deficits, with good neurologic recovery, avoidance of kyphosis progression, and few complications.

## Abbreviations

ASIA: American Spinal Injury Association; CRP: C-reactive protein; ESR: Erythrocyte sedimentation rate; HREZ: Isoniazid, rifampicin, ethambutol, and pyrazinamide; ODI: Oswestry disability index; pVAS: Pain visual analogue score

## Acknowledgements

Not Applicable.

## Funding

We received no external funding for this study.

## Availability of data and materials

The data used and analysed during the current study is available from the corresponding author on reasonable request.

## Authors' contributions

JZX and ZHZ conceived of and designed this study. ZLL, LTL, JLT, and YC were involved in data collection. XL analyzed and interpreted the data. YZ and GW helped designed the study, interpreted the data, and contributed to the manuscript writing. JTL performed the chart abstraction and revised the manuscript. YPZ and WJW were major contributors in writing the manuscript. All authors read and approved the final manuscript.

## Ethics approval and consent to participate

The research was approved by the Ethics Committee of the First Affiliated Hospital of the Third Military Medical University, People's Liberation Army (PLA). All participants have been informed and gave written consent prior to data collection.

## Consent for publication

Not Applicable.

## Competing interests

The authors declare that they have no competing interests.

## Publisher's Note

Springer Nature remains neutral with regard to jurisdictional claims in published maps and institutional affiliations.

## Author details

<sup>1</sup>Department of Orthopaedics, Southwest Hospital, Third Military Medical University, Chongqing 400038, China. <sup>2</sup>Department of Orthopaedics, The Lanzhou General Hospital, Lanzhou Military Command of CPLA, Lanzhou, China. <sup>3</sup>Department of Orthopaedics, Yulin People's Hospital, Yu Lin, China. <sup>4</sup>Department of Orthopaedics, The People's Liberation Army No. 309 Hospital, Beijing, China. <sup>5</sup>Department of Orthopaedics, Xi'an Jiaotong University Affiliated Honghui Hospital, Xi'an, China. <sup>6</sup>Department of Orthopaedics, The Affiliated Hospital of Southwest Medical University, Luzhou, China.

Received: 24 June 2018 Accepted: 13 February 2019

Published online: 04 March 2019

## References

- Ding P, Li X, Jia Z, Lu Z. Multidrug-resistant tuberculosis (MDR-tuberculosis) disease burden in China: a systematic review and spatio-temporal analysis. *BMC Infect Dis.* 2017;17:57.
- Zumla A, George A, Sharma V, Herbert N, Baroness MOI. WHO's 2013 global report on tuberculosis: successes, threats, and opportunities. *Lancet.* 2013; 382:1765–7.

3. Zhao Y, Xu S, Wang L, et al. National survey of drug-resistant tuberculosis in China. *N Engl J Med*. 2012;366:2161–70.
4. Yao Y, Song W, Wang K, et al. Features of 921 patients with spinal tuberculosis: a 16-year investigation of a general hospital in Southwest China. *Orthopedics*. 2017;40:e1017–23.
5. Nagashima H, Yamane K, Nishi T, Nanjo Y, Teshima R. Recent trends in spinal infections: retrospective analysis of patients treated during the past 50 years. *Int Orthop*. 2010;34:395–9.
6. Jain AK, Dhammi IK, Jain S, Kumar J. Simultaneously anterior decompression and posterior instrumentation by extrapleural retroperitoneal approach in thoracolumbar lesions. *Indian J Orthop*. 2010;44:409–16.
7. Sai KN, Vaishya S, Kale SS, Sharma BS, Mahapatra AK. Surgical results in patients with tuberculosis of the spine and severe lower-extremity motor deficits: a retrospective study of 48 patients. *J Neurosurg Spine*. 2007;6:320–6.
8. Jin D, Qu D, Chen J, Zhang H. One-stage anterior interbody autografting and instrumentation in primary surgical management of thoracolumbar spinal tuberculosis. *Eur Spine J*. 2004;13:114–21.
9. Mak KC, Cheung KM. Surgical treatment of acute tuberculous spondylitis: indications and outcomes. *Eur Spine J*. 2013;22(Suppl 4):603–11.
10. Bakhsh A. Medical management of spinal tuberculosis: an experience from Pakistan. *Spine (Phila Pa 1976)*. 2010;35:E787–91.
11. Jain AK. Tuberculosis of the spine: a fresh look at an old disease. *J Bone Joint Surg Br*. 2010;92:905–13.
12. Leone A, Guglielmi G, Cassar-Pullicino VN, Bonomo L. Lumbar intervertebral instability: a review. *Radiology*. 2007;245:62–77.
13. Zhang Z, Luo F, Zhou Q, Dai F, Sun D, Xu J. The outcomes of chemotherapy only treatment on mild spinal tuberculosis. *J Orthop Surg Res*. 2016;11:49.
14. Tuli SM. Tuberculosis of the spine: a historical review. *Clin Orthop Relat Res*. 2007;460:29–38.
15. Jain S. Comment on Huang et al.: one-stage surgical management for children with spinal tuberculosis by anterior decompression and posterior instrumentation. *Int Orthop*. 2010;34:769–70.
16. Zhang HQ, Wang YX, Guo CF, et al. One-stage posterior approach and combined interbody and posterior fusion for thoracolumbar spinal tuberculosis with kyphosis in children. *Orthopedics*. 2010;33:808.
17. Oguz E, Sehrioglu A, Altinmakas M, et al. A new classification and guide for surgical treatment of spinal tuberculosis. *Int Orthop*. 2008;32:127–33.
18. Jain AK, Dhammi IK, Prasad B, Sinha S, Mishra P. Simultaneous anterior decompression and posterior instrumentation of the tuberculous spine using an anterolateral extrapleural approach. *J Bone Joint Surg Br*. 2008;90:1477–81.
19. Benli IT, Kaya A, Acaroglu E. Anterior instrumentation in tuberculous spondylitis: is it effective and safe? *Clin Orthop Relat Res*. 2007;460:108–16.
20. Zhang H, Sheng B, Tang M, et al. One-stage surgical treatment for upper thoracic spinal tuberculosis by internal fixation, debridement, and combined interbody and posterior fusion via posterior-only approach. *Eur Spine J*. 2013;22:616–23.
21. Machino M, Yukawa Y, Ito K, Nakashima H, Kato F. A new thoracic reconstruction technique "transforaminal thoracic interbody fusion": a preliminary report of clinical outcomes. *Spine (Phila Pa 1976)*. 2010;35:E1000–5.
22. Zaveri GR, Mehta SS. Surgical treatment of lumbar tuberculous spondylodiscitis by transforaminal lumbar interbody fusion (TLIF) and posterior instrumentation. *J Spinal Disord Tech*. 2009;22:257–62.
23. Zindrick MR, Wiltse LL, Widell EH, et al. A biomechanical study of intrapeduncular screw fixation in the lumbosacral spine. *Clin Orthop Relat Res*. 1986;99–112.
24. Chacko AG, Moorthy RK, Chandy MJ. The transpedicular approach in the management of thoracic spine tuberculosis: a short-term follow up study. *Spine (Phila Pa 1976)*. 2004;29:E363–7.
25. Dai L, Jiang L, Wang Y, Jiang S. Chemotherapy in anterior instrumentation for spinal tuberculosis: highlighting a 9-month three-drug regimen. *World Neurosurg*. 2010;73:560–4.
26. Mehta JS, Bhojraj SY. Tuberculosis of the thoracic spine. A classification based on the selection of surgical strategies. *J Bone Joint Surg Br*. 2001;83:859–63.
27. Rawall S, Mohan K, Nene A. Posterior approach in thoracolumbar tuberculosis: a clinical and radiological review of 67 operated cases. *Musculoskelet Surg*. 2013;97:67–75.
28. Shi J, Tang X, Xu Y, et al. Single-stage internal fixation for thoracolumbar spinal tuberculosis using 4 different surgical approaches. *J Spinal Disord Tech*. 2014;27:E247–57.
29. Moon MS. Tuberculosis of the spine. Controversies and a new challenge. *Spine (Phila Pa 1976)*. 1997;22:1791–7.
30. Pang X, Shen X, Wu P, Luo C, Xu Z, Wang X. Thoracolumbar spinal tuberculosis with psoas abscesses treated by one-stage posterior transforaminal lumbar debridement, interbody fusion, posterior instrumentation, and postural drainage. *Arch Orthop Trauma Surg*. 2013;133:765–72.
31. Garg B, Kandwal P, Nagaraja UB, Goswami A, Jayaswal A. Anterior versus posterior procedure for surgical treatment of thoracolumbar tuberculosis: a retrospective analysis. *Indian J Orthop*. 2012;46:165–70.
32. Hee HT, Majd ME, Holt RT, Pienkowski D. Better treatment of vertebral osteomyelitis using posterior stabilization and titanium mesh cages. *J Spinal Disord Tech*. 2002;15:149–56.
33. Hodgson AR, Stock FE, Fang HS, Ong GB. Anterior spinal fusion. The operative approach and pathological findings in 412 patients with Pott's disease of the spine. *Br J Surg*. 1960;48:172–8.
34. Zhang HQ, Guo CF, Xiao XG, Long WR, Deng ZS, Chen J. One-stage surgical management for multilevel tuberculous spondylitis of the upper thoracic region by anterior decompression, strut autografting, posterior instrumentation, and fusion. *J Spinal Disord Tech*. 2007;20:263–7.

**Ready to submit your research? Choose BMC and benefit from:**

- fast, convenient online submission
- thorough peer review by experienced researchers in your field
- rapid publication on acceptance
- support for research data, including large and complex data types
- gold Open Access which fosters wider collaboration and increased citations
- maximum visibility for your research: over 100M website views per year

**At BMC, research is always in progress.**

Learn more [biomedcentral.com/submissions](https://biomedcentral.com/submissions)

