

Contents lists available at [ScienceDirect](http://www.sciencedirect.com)

International Journal of Surgery Case Reports

journal homepage: www.casereports.com

Osteochondrosis of the medial malleolar epiphysis: A case report and review of the literature



Marco Turati^{b,c,*}, Yann Glard^a, Jacques Griffet^b, David Afonso^a, Aurélien Courvoisier^b, Marco Bigoni^{c,d}

^a Department of Paediatric Orthopaedics, Saint Joseph Hospital, Marseille, France

^b Department of Paediatric Orthopedic Surgery, University Hospital Grenoble-Alpes, University Grenoble-Alpes, France

^c Orthopedic Department, San Gerardo Hospital, University of Milano-Bicocca, Monza, Italy

^d Department of Medicine and Surgery, University of Milano-Bicocca, 20900 Monza, Italy

ARTICLE INFO

Article history:

Received 2 May 2017

Received in revised form 5 August 2017

Accepted 8 August 2017

Available online 14 August 2017

Keywords:

Medial malleolus

Osteochondrosis

Ankle

Bone diseases

Epiphysis

Child

Case report

ABSTRACT

INTRODUCTION: Osteochondrosis is characterized by a disturbance of enchondral ossification in skeletally immature patients and should be investigated in children having a history of persistent foot and ankle pain. Involvement of the medial malleolar epiphysis is rarely reported.

PRESENTATION OF CASE: We describe the case of a sporty 12-year-old male with osteochondrosis of the left medial malleolar epiphysis treated with a conservative management.

DISCUSSION: Calcaneal, navicular and metatarsal apophysis are the most common locations for osteochondrosis in ankle and foot. Anyway other osteochondrosis should be excluded. Medial malleolar osteochondrosis is occasionally described. We performed a review of the relevant literature and we summarized clinical aspects, radiological characteristics and reported management of this painful and probably underestimated condition.

CONCLUSION: Medial malleolar osteochondrosis is a rare but well recognized condition. Only seven cases are described in literature.

© 2017 The Authors. Published by Elsevier Ltd on behalf of IJS Publishing Group Ltd. This is an open access article under the CC BY-NC-ND license (<http://creativecommons.org/licenses/by-nc-nd/4.0/>).

1. Introduction

Foot and ankle pain is a common condition in skeletally immature patients. Sport related and traumatic injuries are the most common causes of foot pain with children and adolescents [1–3]. However several different etiologies could lead to ankle and foot problems with this age group. Tarsal coalition, painful accessory bone, biomechanical problems and alteration of the enchondral ossification should be considered and excluded [4].

The increased involvement of skeletally immature patients in sport practice and the growing awareness for injuries, lead to an increasing detection of foot osteochondral alteration with children and adolescents [5–7]. Osteochondrosis is a focal multifactorial breakdown of enchondral ossification in a region of previously normal enchondral growth. During childhood all ossification centres are likely to develop osteochondrosis and a meticulous clinical examination is essential in the diagnostic process. Osteo-

chondrosis of the medial malleolar epiphysis is a rare situation and few cases are reported in literature [8–12].

We reported a case of osteochondrosis of the medial malleolar epiphysis in a sporty male child. We also reviewed the relevant literature about this alteration of the medial malleolar epiphysis being aware that an increased clinical attention to this painful condition could lead to improved diagnosis and treatment among the pediatric population. For the publication of this case report we have taken into account the SCARE-criteria for good clinical case reports [13].

2. Presentation of case

An eutrophic and previously healthy 12-year-old French boy with a 3-week history of left ankle pain was examined in our outpatient department. The pain which started without traumatic events or sport injury, grew heavier and heavier. No history of trauma or ankle infections were reported. He regularly practiced artistic gymnastic ten hours a week. Examination indicated swelling and tenderness of the medial side of the ankle. Pain was located at the medial malleolus and at the malleolar insertion of the deltoid ligament. Ankle and foot range of motion was completed with painful supination and dorsiflexion at the extreme degrees.

* Corresponding author at: Department of Paediatric Orthopedic Surgery, Hospital Couple Enfants, Grenoble Alpes University, CS 10217, 38043 Grenoble Cedex 9, France.

E-mail address: turati.mrc@gmail.com (M. Turati).

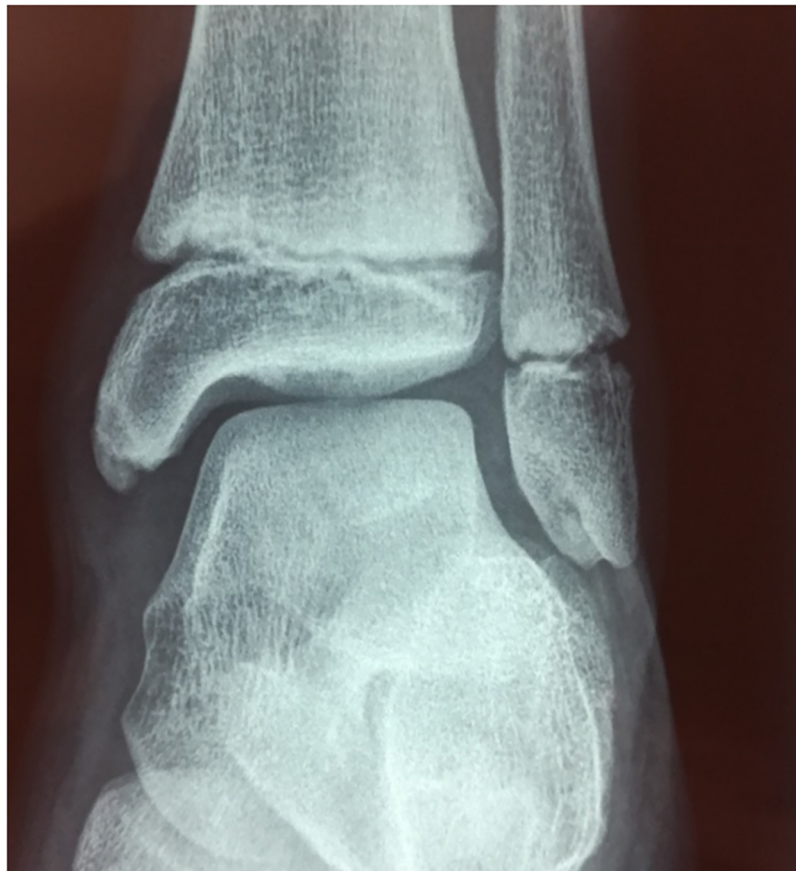

Fig. 1. Anteroposterior of the 12-year old patient showed a radiolucent alteration at the apex of the left medial malleolus. The rest of the ankle joint is normal.

No lower limb discrepancy or malalignment were observed. The radiography showed a radiolucent focal uptake in the medial malleolus apex and a partially fused secondary ossification center of the medial malleolus (Fig. 1). Thickening of proximal portion of the deltoid ligament was revealed with an ultrasonography evaluation. Inflammatory and infectious diseases were excluded after laboratory exams and it was decided to treat this ankle by a short leg cast for a four week period. At this time the state of the patient was reassessed but the pain resumed at the medial part of the ankle. A CT scan and a MRI were performed. CT scan showed fragmentation at the tip of the medial malleolus (Fig. 2) and MRI demonstrated the presence of fragmentation and bone-marrow edema at the medial malleolus (Fig. 3) which led to the diagnosis of osteochondrosis of the medial malleolus.

He was treated with a cast immobilization for another four weeks. The pain did not completely disappeared after the second cast but a partial weight-bearing walking was permitted. After another 2 months the patient was asymptomatic with a full range of motion for his ankle. A new MRI showed a healing of the medial malleolus and the boy was allowed to resume all his sport activities. No symptoms were reported at the 2-years follow-up.

3. Discussion

Osteochondrosis of the medial malleolus is a rare condition described occasionally in literature [8–11]. Medial malleolus could show an accessory ossification center as a normal variant in growing children. Different studies report an incidence of this secondary ossification center between 1.6 and 47% [14–17].

Age, gender and sport activity may play a part in the explanation of such a high variation of results. Medial malleolus accessory

ossification center usually appear from six to eleven years of age and is more frequent in female patients [10].

Sport activities could influence the formation of this accessory ossification center. Tajima et al. compared ankle x-rays of 292 children of a junior football club to 124 control subjects. He reported an accessory center in 11.2% of young football players and in only 1.6% of the control group [17].

Mechanical repetitive tractions of the deltoid ligament were indicated as a possible etiologic key factor to the accessory ossification center formation [10,17]. On the other hand, a recent study analyzed 550 ankle x-rays observing four specific developmental stages of the medial malleolus. LaMont et al. stressed the concept that secondary ossification centres appears as part of a continuum of a development of the medial malleolus [18].

Different clinical problems as avulsion fractures of the accessory ossification center, traction apophysitis of the medial malleolus and osteochondrosis of the medial malleolus were described with the presence of a pediatric medial malleolus pain [8,10,12].

We reviewed PubMed, Medline, Cochrane and Embase databases to identify all patients who had an osteochondrosis of the medial malleolus. We searched for “osteochondrosis” OR “apophysitis” OR “avascular necrosis” AND “medial malleolus”. All of the articles found were included. Five articles discussing 6 cases of osteochondrosis of the medial malleolus were found to which we add our case (Table 1). The seven cases studied consisted of 5 males and 2 females with a mean age of 11 years (range 8–13 years) [8–12]. In all cases medial malleolus alteration were not related to ankle injuries and tibial fractures.

Local and systemic biochemical inflammatory activations, genetic predisposition, local ischemia, and mechanical alteration are etiological key factors in osteochondrosis pathogenesis [19].

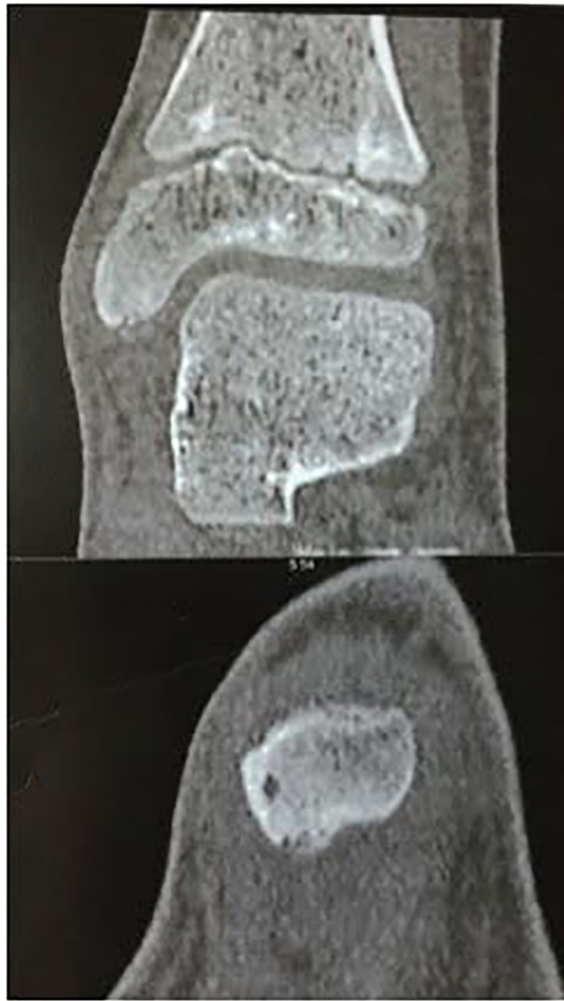


Fig. 2. Coronal and sagittal CT scan show a fragmentation on the apex of the symptomatic left medial malleolus.

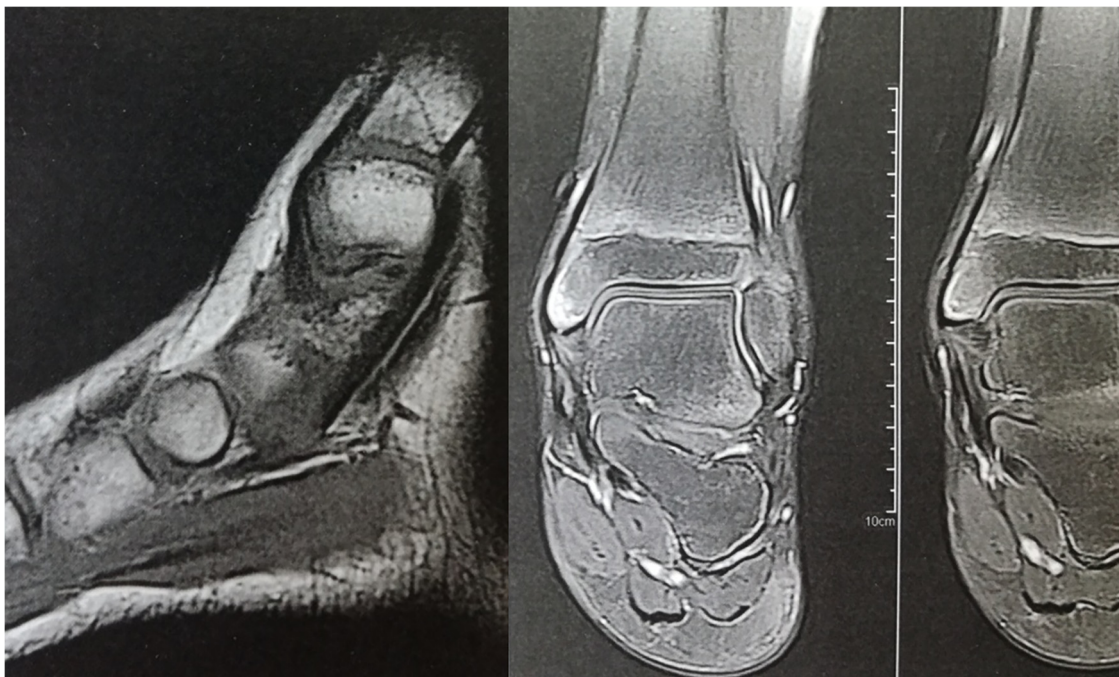


Fig. 3. Sagittal T1-weighted and coronal T2-weighted magnetic resonance image show the area of osteochondritis of the left medial malleolus with low-signal intensity lesion on T1-images and a signal suggestive of sclerosis with bone marrow edema on T2-images. There is no alteration of articular cartilage of the ankle joint.

Table 1
Summary and comparison of published cases of medial malleolar osteochondrosis. FU indicates Follow-up.

Case	Author	Year	Sex	Age	Etiology	Clinical presentation	Radiology	Treatment and clinical evolution
1	Ogden and Lee [12]	1990	M	12	Known to have bilateral accessory ossification of medial malleolus	Chronic pain right side	(i) X-ray: irregular ossification at malleolar tip (ii) Bilateral bone scan: increased uptake on the symptomatic side	Cast immobilization.
2	Ishi et al. [10]	1994	F	8	Known to have: (i) pain after sport (basketball) (ii) hyperpronated feet (iii) No traumatic injury	Local tenderness of the medial malleolus, swelling, painful foot pronation-eversion	i) X-ray: presence of the accessory ossification center of medial malleolus (ii) T1-weighted MRI: reduced signal in the medial apophyseal cartilage	Conservative without cast. Time to heal from 1° visit: 1 month
3	Ishi et al. [10]	1994	M	10	Known to have: (i) pain after sport (baseball) (ii) bilateral pain (iii) No traumatic injury	Bilateral local tenderness of the medial malleolus, swelling, painful foot pronation-eversion	(i) left ankle MRI: Fusion of fragmented accessory center of the left medial malleolus, (ii) right ankle MRI: Fragmentation of the accessory center	Conservative without cast. Time to heal from 1° visit: 3 months
4	Klein et al. [9]	2008	M	12	Known to have: (i) flexible pes planovalgus (ii) pain after playing football	Pain, tenderness and swelling on the medial malleolus	(i) X-ray (6 weeks after football): fragmentation of the epiphysis of the medial malleolus (ii) MRI (10 weeks after football): soft tissue and bone marrow oedema of medial malleolus (iii) X-ray (same time): reconstitution of the medial malleolar epiphysis	Conservative; Ankle tape dressing for 4 weeks; 10 weeks FU: no pain; no clinical abnormality
5	Gupta et al. [11]	2008	M	13	Known to be very sport active; No traumatic injury; pain increased after activity	Tenderness of the medial malleolus, ankle valgus test +	(i) MRI: fragmented medial malleolus apophysis	Cast for 3 weeks, rest for 8 weeks; 8 weeks FU: no pain.
6	Farsetti et al. [8]	2015	F	11	Known to have: bilateral accessory ossification center; pain increased after activity	Mild swelling and painful palpation of the medial malleolus; painful foot pronation-eversion at extremes degrees	(i) X-ray: fragmentation of the accessory ossification center (ii) MRI: fragmentation of the ossification center and oedema of the distal part of the medial malleolus (iii) X-ray (6 months FU): complete remodeling of the medial malleolus	Rest without cast and brace for 6 months; 6 months FU: no pain; no clinical abnormality
7	Turati et al. [5]	2016	M	12	No traumatic injury; artistic gymnastic 10 h/week	Swelling and pain localized to the medial malleolus and to the malleolar insertion of the anterior fibular astragal ligament.	(i) X-ray: focal uptake in the medial malleolus apex (ii) CT: fragmentation at the tip of the medial malleolus (iii) MRI: bone-marrow oedema at the medial malleolus (iv) MRI (5 months FU): healing of the medial malleolus	Conservative; Cast for 3 months and then partial weight-bearing walking; 2 years FU: no pain

Mechanical excessive load on the medial epiphysis and repetitive micro trauma seems to be an important etiological role in this osteochondrosis as in Osgood-Schlatter's disease and Sinding-Larsen-Johansson syndrome [20]. Indeed five patients were involved in regular sport activities and with all patients except one the pain became worse with sport activities. Two cases were associated to flexible pes planovalgus [9,10]. It's interesting to notice that the pes planovalgus was considered as a bio-mechanical alteration that could lead to an overload on the medial structures of the ankle stressing the importance of the mechanical alteration in osteochondrosis etiology.

Clinical examination showed swelling and painful palpation of the medial malleolus often associated to painful ankle foot pronation-eversion. Bilateral accessory center of ossification was described in four patients [8,10–12]. Three cases healed spontaneously without immobilization and the other four patients required a cast immobilization (range time of immobilization 3 weeks–3 months). Klein hypothesizes a surgical treatment in some cases but actually no surgical treatments were described [9].

4. Conclusion

The present study reports a child's clinical case with radiological and clinical findings compatible to the diagnosis of osteochondrosis

of the medial malleolar epiphysis. Medial malleolar osteochondrosis is a very rare entity and up to the present time, just others 6 cases has been described in medical literature. The mechanism of this disease could be the association of mechanical excessive load on the medial epiphysis, repetitive micro trauma and congenital anomalous blood supply of the medial malleolar epiphysis. It is a self-limited disease and in all cases described conservative treatment lead to a good clinical evolution without severe ankle and foot deformities. We believe that this pathological condition is probably underestimated and that in skeletally immature patients with atraumatic medial ankle pain, especially if they are sporty and active, the assessment should consider the osteochondrosis of the medial malleolar epiphysis as a possible diagnosis. We strongly recommended radiographs and MRI assessment in case of clinical doubt to search a possible fragmentation of the epiphysis of the medial malleolus.

Conflict of interest

The authors declare that they have no conflict of interest.

Funding

None.

Ethical approval

Not required.

Consent

Written signed consent was obtain from the parents of the child

Author contribution

Author contribution statement: Design of the study: Marco Turati, Yann Glard, Jacques Griffet, David Afonso, Aurélien Courvoisier, Marco Bigoni. Performed clinical and radiological evaluation: Marco Turati, Yann Glard, Jacques Griffet, David Afonso, Aurélien Courvoisier, Marco Bigoni. Drafting of the manuscript: Marco Turati, Yann Glard, Jacques Griffet, David Afonso, Aurélien Courvoisier, Marco Bigoni.

Manuscript final revision: Marco Turati, Yann Glard, Jacques Griffet, David Afonso, Aurélien Courvoisier, Marco Bigoni.

All authors approved the final version of manuscript for submission.

Guarantors

Marco Turati, Yann Glard, Jacques Griffet, Aurélien Courvoisier, Marco Bigoni.

References

- [1] M. Bigoni, D. Gaddi, M. Gorla, D. Munegato, M. Pungitore, M. Piatti, et al., Arthroscopic anterior cruciate ligament repair for proximal anterior cruciate ligament tears in skeletally immature patients: surgical technique and preliminary results, *Knee* 24 (2017) 40–48.
- [2] F. Bastos, F. Vanderlei, L.C.M. Vanderlei, J. Júnior, C. Pastre, Investigation of characteristics and risk factors of sports injuries in young soccer players: a retrospective study, *Int. Arch. Med.* 6 (2013), 14–14.
- [3] M. Bigoni, M. Turati, M. Gandolla, C.A. Augusti, A. Pedrocchi, A. La Torre, et al., Balance in young male soccer players: dominant versus non-dominant leg, *Sport Sci. Health* (2016) 1–6.
- [4] A. Aiyer, W. Hennrikus, Foot pain in the child and adolescent, *Pediatr. Clin. North Am.* 61 (2014) 1185–1205.
- [5] M. Turati, Y. Glard, D. Afonso, J. Griffet, M. Bigoni, Osteochondral alteration in a child treated with levetiracetam: a rare case of juvenile osteochondritis dissecans of the talar head, *J. Pediatr. Orthop. B* 26 (March(2)) (2017) 189–192, <http://dx.doi.org/10.1097/BPB.0000000000000354>, PubMed PMID: 27341121.
- [6] M. Turati, D. Afonso, B. Salazard, M. Maillé Declerck, M. Bigoni, Y. Glard, Bilateral osteochondrosis of the distal tibial epiphysis: a case report, *J. Pediatr. Orthop. Part B* 24 (2015) 154–158.
- [7] A. Atanda, S. Shah, K. O'Brien, Osteochondrosis: common causes of pain in growing bones, *Am. Fam. Physician* 83 (2011) 285–291.
- [8] P. Farsetti, M. Dragoni, V. Potenza, R. Caterini, Osteochondrosis of the accessory ossification centre of the medial malleolus, *J. Pediatr. Orthop. Part B* 24 (2015) 28–30.
- [9] R. Klein, R. Burgkart, K. Woertler, R. Gradingner, S. Vogt, Osteochondrosis juvenilis of the medial malleolar epiphysis, *J. Bone Joint Surg. Br. Vol. 90* (2008) 810–812.
- [10] T. Ishii, S. Miyagawa, K. Hayashi, Traction apophysitis of the medial malleolus, *J. Bone Joint Surg. Br. Vol. 76* (1994) 802–806.
- [11] R. Gupta, S. Batra, A. Verma, V.K. Sharma, S. Grover, Traction apophysitis of medial malleolus: a case report with review of the literature, *Indian J. Orthop.* 42 (2008) 91–93.
- [12] J.A. Ogden, J. Lee, Accessory ossification patterns and injuries of the malleoli, *J. Pediatr. Orthoped.* 10 (1990) 306–316.
- [13] R.A. Agha, A.J. Fowler, A. Saeta, I. Barai, S. Rajmohan, D.P. Orgill, et al., The SCARE statement: consensus-based surgical case report guidelines, *Int. J. Surg.* 34 (2016) 180–186.
- [14] D.D. Hoed, S. Keijser, A separate centre of ossification for the tip of the internal malleolus, *Br. J. Radiol.: BIR Section* 30 (1925) 67–68.
- [15] H.D.W. Powell, Extra centre of ossification for the medial malleolus in children, *Incid. Signif.* 43-B (1961) 107–113.
- [16] S. Selby, Separate centers of ossification of the tip of the internal malleolus, *Am. J. Roentgenol. Radium Ther Nuclear Med* 86 (1961) 496–501.
- [17] T. Tajima, Radiological study on the foot and ankle of junior footballers, *Orthop. Surg. Traumatol.* 24 (1981) 1611–1618.
- [18] L. LaMont, H. Ladenhauf, F. Edobor Osula, E. Bogner, H. Do, D. Green, Secondary ossification centers in the development of the medial malleolus, *J. Pediatr. Orthoped.* 35 (2015) 314–317.
- [19] D. Allerstorfer, S. Longato, C. Schwarzer, R. Fischer Colbrie, A. Hayman, M.J.F. Blumer, VEGF and its role in the early development of the long bone epiphysis, *J. Anat.* 216 (2010) 611–624.
- [20] R.C. Medlar, E.D. Lyne, Sinding-Larsen-Johansson disease: its etiology and natural history, *J. Bone Joint Surg. Am.* 60 (1978) 1113–1116.

Open Access

This article is published Open Access at sciendo.com. It is distributed under the [IJSCR Supplemental terms and conditions](#), which permits unrestricted non commercial use, distribution, and reproduction in any medium, provided the original authors and source are credited.