



Contents lists available at ScienceDirect

International Journal of Surgery Case Reports

journal homepage: www.casereports.com

Management of radiation induced, bilateral Primary THA loosening with an aseptic Paprosky Type IIB acetabular defect and a contralateral septic Type IIIB acetabular defect: A case report and review of literature

Mohit M. Kukreja^{a,*}, Steven K. Nishiyama^b, Parminder S. Kang^c

^a Desert Orthopaedic Center, 2800 E. Desert Inn, Suite 100, Las Vegas, NV 89121, United States

^b Orthopedic Surgery Residency Program, Valley Hospital Medical Center, 620 Shadow Lane, Las Vegas, NV 89106, United States

^c Joint replacement Section Chief at Touro University, Valley Hospital Medical Center and Desert Orthopaedic Center, 2800 E. Desert Inn, Suite 100, Las Vegas, Nevada 89121, United States

ARTICLE INFO

Article history:

Received 23 October 2017

Received in revised form 5 December 2017

Accepted 5 December 2017

Available online 9 December 2017

Keywords:

Pelvic irradiation

Pelvic discontinuity

Periprosthetic infection

Trabecular metal

Cup-in-cup construct

ABSTRACT

INTRODUCTION: Primary THA in an irradiated hip poses risk for early loosening and inadequate ingrowth. Adverse effects such as decreased vascularity and increased infection risk pose a threat.

CASE PRESENTATION: Our patient was a case of post-irradiation (for cervical cancer) bilateral THA loosening causing aseptic acetabular loosening on one side and catastrophic septic loosening with a Paprosky type IIIB acetabular defect with pelvic discontinuity on the contralateral side.

DISCUSSION: There have been various studies documenting deleterious effects of irradiation on osseointegration and provide a challenge for long-term implant stability in THA patients.

CONCLUSION: A meticulous treatment protocol with contemporary implant technology and staged bilateral stepwise management can lead to satisfactory clinical outcomes. This case report highlights on such specific nuances and principles.

© 2017 The Authors. Published by Elsevier Ltd on behalf of IJS Publishing Group Ltd. This is an open access article under the CC BY-NC-ND license (<http://creativecommons.org/licenses/by-nc-nd/4.0/>).

1. Introduction

Pertes was one of the first to describe the effects of radiation on bone in 1903, showing growth retardation in wing bones of growing chicks [1]. Since that time, the resultant histological and radiographic changes of radiation on bone have been well documented [2,3]. Pelvic radiotherapy has been known to accelerate degenerative arthritic changes in a native hip and also has been implicated in early implant failure for Total Hip Arthroplasty (THA) [4,5]. THA in a patient with a post-irradiated pelvis remains a challenge due to the ability of bone to achieve reliable fixation through ingrowth. Numerous clinical studies have described compromised osseous ingrowth of the acetabular component in patients who had received prior pelvic irradiation [4–7]. Rates of early failure of traditional implants have been documented as high as 44% and 52% at 2–6 years [4,5]. In addition, there are adverse effects on the local

soft tissues such as decreased vascularity, increased fibrosis, and increased predisposition to infection.

Although there is no fixed cut-off, any radiation dosage over 500 cGy adds a higher propensity of causing bone degeneration and/or implant loosening [5]. Radiation therapy in pelvic tumors can be as high as 7000 cGy [2] and when faced with these patients for an elective THA, the surgeon is confronted with the question of what type of component fixation should be utilized. Several authors have advocated use of cemented cups with or without augmentation rings to prevent early loss of fixation [4,7]. However, reported outcomes of THA with cement for patients with an irradiated pelvis have been disappointing [4,5,7]. With the recent advent of tantalum trabecular metal cups and its material properties of a high coefficient of friction and high in vivo ingrowth potential, it has become a valid treatment option in situations like complex THA revisions [8–10] and in irradiated recipient bone [11,12].

Thus, we present a case report of post-irradiation (for cervical cancer) bilateral THA loosening due to deficient acetabular osseointegration causing aseptic acetabular loosening on one side and catastrophic septic loosening with a Paprosky type IIIB acetabular defect with pelvic discontinuity on the contralateral side. Furthermore, we will discuss some nuances of a successful treatment

* Corresponding author.

E-mail addresses: drmohit1234@gmail.com, drmohitkukreja@gmail.com (M.M. Kukreja), stevennisihyama@gmail.com (S.K. Nishiyama), parmkang42@gmail.com (P.S. Kang).

<https://doi.org/10.1016/j.ijscr.2017.12.012>

2210-2612/© 2017 The Authors. Published by Elsevier Ltd on behalf of IJS Publishing Group Ltd. This is an open access article under the CC BY-NC-ND license (<http://creativecommons.org/licenses/by-nc-nd/4.0/>).

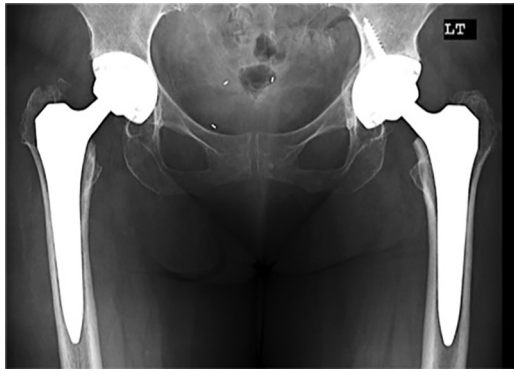


Fig. 1. Pelvic Anterior-Posterior radiograph of patient at index presentation (2 years post-primary THA) demonstrate Bilateral THAs with acceptable component positioning, stable asymptomatic fixation and normal bone quality.

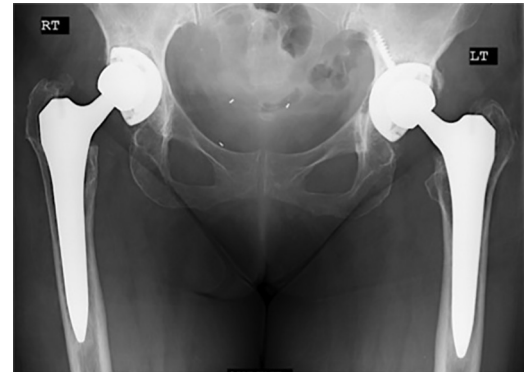


Fig. 2. Pelvic Anterior-Posterior radiograph of patient at 30 months status post-Primary THAs. Note the medial wall thinning of the acetabulum and subsidence on the left side and increased cup inclination on the right.

protocol in similar situations. We would like to state that the work has been reported in line with the SCARE criteria [13]. The case was examined, operated and clinically managed by the Senior author of this article (P.S.K.).

2. Case presentation

A 67-year-old female with a history of cervical cancer presented to our outpatient clinic with ongoing bilateral hip pain for the past 6 months (right >left). She had undergone bilateral primary THA for avascular necrosis 30 months prior by another treating surgeon. 12 months prior to index joint arthroplasty surgeries, she had previously been treated with an 8 week course of External beam radiation therapy and hysterectomy for her cervical cancer. The patient's presenting pain was dull-aching in nature, exacerbated with activity consistent with "start up pain". This was completely relieved with rest and an anti-inflammatory regimen. The patient rated her pain 4/10 on the Visual Analog Scale (VAS). There was no history of fall, trauma or any significant injury prior to the onset of pain. The patient denied pain at rest, symptoms of instability, or constitutional symptoms including fever, night sweats, or weight loss. Patient was a non-diabetic, non-smoker with a Body mass index of 20.2. There was no significant drug history, family history including any relevant genetic information, and psychosocial history. Radiographic images taken at the time of initial presentation showed implants in acceptable position with no evidence of implant, loosening, subsidence, or fracture (Fig. 1).

The patient followed-up in clinic 6 months after initial presentation (approximately 36 months post op) with complaints of increasing "start up" pain, difficulty walking, and difficulty performing household activities. She denied groin pain. She rated her pain 5/10 in the right hip with 2/10 on the left. She continued to deny constitutional symptoms including fever, chills, night sweats, and weight loss. She did, however, complain of a superficial abscess in her left buttock that had been drained by an ER (Emergency Room) physician 1-week prior that was thought to be unrelated to the arthroplasty. Radiographs done at this visit showed increased inclination of the right acetabular component with mild cup subsidence. The left hip exhibited an attenuated medial acetabular wall and significant medial cup migration with increasing cup anteversion and inclination (Fig. 2).

The patient was diagnosed at this point with post-irradiation bilateral acetabular component aseptic loosening, most likely due to insufficient osseointegration of the acetabular component. The patient refused our recommendation for surgical intervention at this point and preferred a conservative line of management, which included activity modification, physical therapy and anti-

inflammatories. She was advised to closely follow up with the admonition that her condition would likely worsen with time.

The patient presented back to clinic 6 months later (42 months following index surgeries) with increasing bilateral hip/groin pain and significant deterioration of her clinical symptoms. She had now developed a 5 mm sinus draining tract along her left hip incision. Radiographic images (Fig. 3) exhibited an acute progression of the left acetabular component with cup protrusion and further loss of the medial wall. The right acetabular component exhibited further cup inclination and superior migration. Laboratory blood work (complete blood count (CBC), Erythrocyte Sedimentation Rate (ESR), C-Reactive Protein (CRP)) were obtained to further investigate a periprosthetic infection. Both ESR and CRP were found to be elevated at 34 mm/hr and 3.7 mg/dL, respectively. WBC count was within normal limits at 6.1 k/ μ L.

Aspiration for both hips were performed; however, both hips exhibited no bacterial growth.

The patient was scheduled for a Left 2-stage revision THA and a right-sided isolated acetabular revision. The priority was to address the active periprosthetic infection on the left side with an explant, aggressive irrigation and debridement, and insertion of antibiotic spacer. This would be followed by parenteral antibiotic administration, both intravenously and locally via Hickman catheter. Once the infection had clinically resolved, the right side acetabular revision would be addressed as soon as possible in order to facilitate recovery and rehabilitation in anticipation of the left sided replant/reconstruction.

Via a standard posterolateral approach, the patient underwent an uneventful Left THA explant and insertion of static antibiotic laden spacer. Intraoperatively, she was found to have a Paprosky type IIIB acetabular defect and pelvic discontinuity with Paprosky Type II proximal femoral deficiency with extensive metaphyseal bone loss and intact diaphysis (Fig. 4). We had to refrain from using an articulating antibiotic spacer as there was significant medial pelvic wall deficiency and was at risk for further protrusion with an articulating spacer. Thus we implanted a non-biodegradable, non-articulating antibiotic laden cement spacer with 3 g of Vancomycin and 3.6 g of Tobramycin in 2 packs of Poly (methyl methacrylate) cement (PMMA) (Palacos R, Zimmer Biomet, Warsaw, IN). A Hickman catheter (CR Bard Inc., Salt Lake City, UT) was also placed for local antibiotic delivery and she was started on local antibiotic administration regimen of Vancomycin 500 mg in 10 mL of saline every 12 h for 6 weeks as described by Whiteside et al. [14]. A negative pressure incisional vacuum device (Prevena, Acelyt Inc, San Antonio, TX) was applied for dressings and left in place for 7 days post op as recommended by the manufacturer. The patient was restricted to NWB to the left LE and was immediately started on physical therapy.

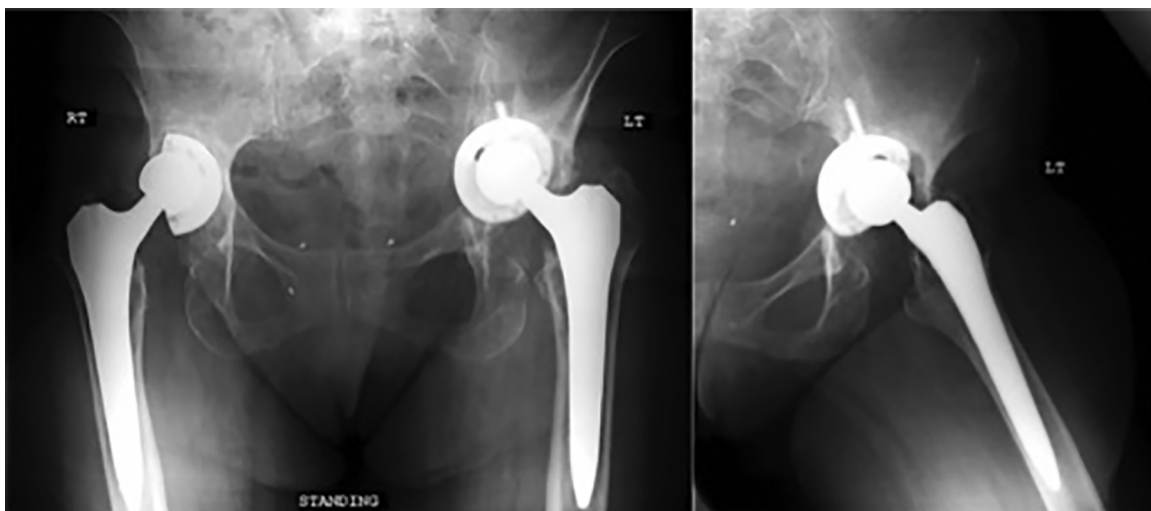


Fig. 3. Pelvic AP radiograph and Frog-lateral of the left hip 33 months status post bilateral primary THA. There is further loosening of the right acetabular component with an inclination of almost 90° and medial migration of the acetabular cup. Further left sided acetabular component migration with intra-pelvic protrusion and suspected pelvic discontinuity.

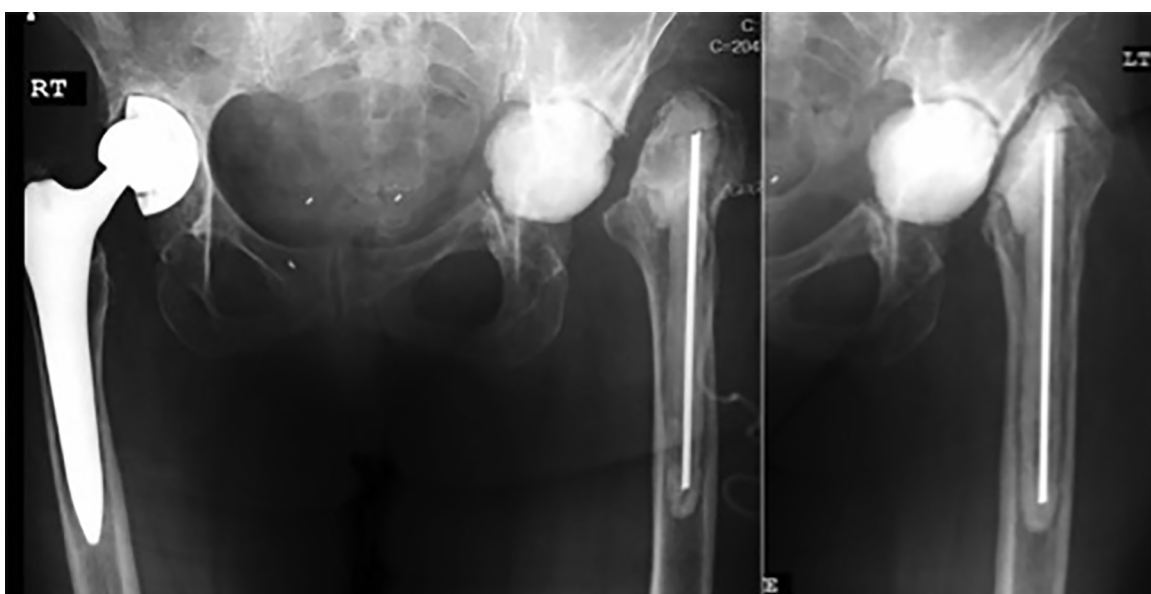


Fig. 4. Pelvic AP radiograph and Frog-lateral of the left hip status post left hip explant and placement of a static antibiotic cement spacer. A Hickman's catheter was placed for intra-articular antibiotic delivery.

The patient's postoperative course was uneventful and she continued on her intravenous and local antibiotic administration without adverse reaction or complication for 6 weeks. She received a 1-week antibiotic holiday and repeat infection laboratory studies (ESR, CRP) were performed and were found to be within normal limits (ESR = 20 mm/hr, CRP = <0.5 mg/dL). The patient returned to surgery at 8 weeks postop for Hickman catheter removal and a left hip aspiration, which showed a total nucleated cell of 867 and negative gram stain and culture, confirming resolution of the infection. It was then decided to be an appropriate time to address the right THA revision. The patient was taken to surgery and via a standard posterolateral approach, the right acetabulum was revised with a cementless tantalum trabecular metal (TM) cup with screws and a TM oblong augment for a Paprosky Type IIB superior lateral acetabular deficiency (Fig. 5) (Zimmer, Warsaw, IN; Continuum 56 mm multihole trabecular metal revision shell with a 40 mm cemented Continuum liner, 50 mm × 10 mm oblong augment with a 40 mm + 0 cobalt chrome head). The TM cup and augment were

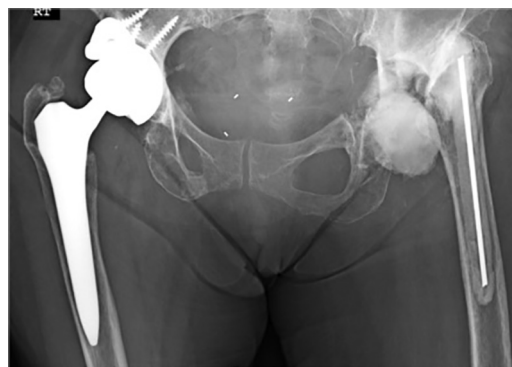

Fig. 5. AP pelvic radiograph status post Right hip Acetabular component revision for aseptic loosening. Note the superior trabecular metal augment fixed with screws for a Paprosky Type IIB acetabular defect.

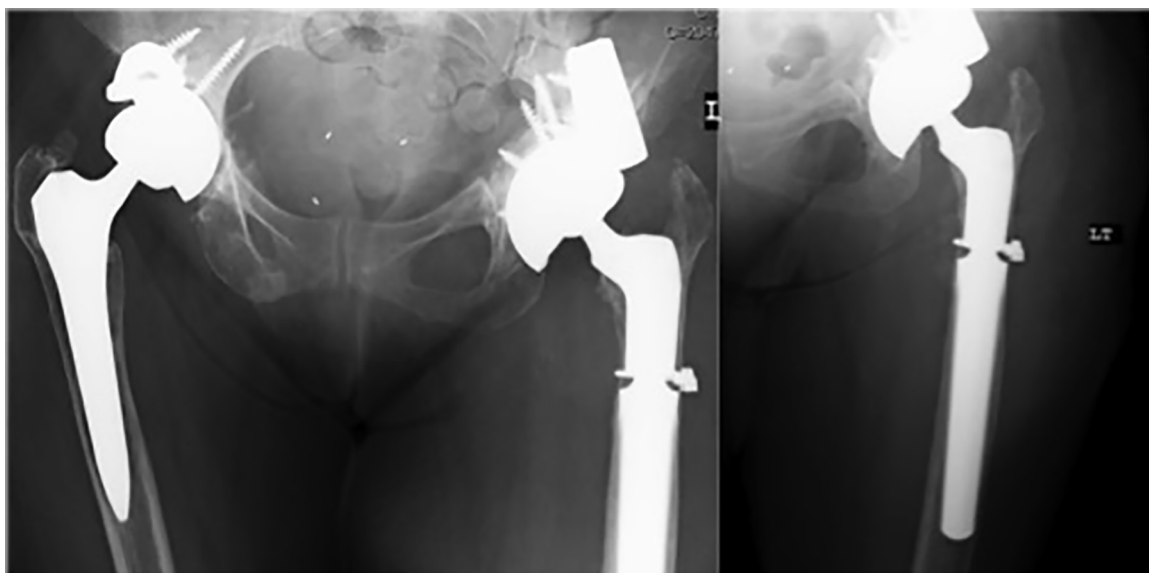


Fig. 6. Pelvic AP radiograph and AP of the left hip status post left sided THA replant with a “Cup-in-Cup” construct, Trabecular metal augment, dual-mobility head, and a distal fixation modular cementless femoral revision stem.

fixed with screws and was also cemented at the augment-cup interface. The femoral component was not revised as it was found to be stable without evidence of loosening or osteolysis. The patient was allowed to TTWB to the Right LE and starting on a physical therapy regimen focused on transfers to a wheelchair. The patient’s postoperative course was uneventful and was allowed to start full weight bearing at 6 weeks post op.

4-weeks status post Right hip THA revision, attention was directed back to the left hip where repeat infection laboratory studies (ESR, CRP) continued to remain within normal limits (ESR = 24 mm/hr, CRP = < 0.5 mg/dL). The patient was taken to surgery for the second stage left hip replantation of acetabular and femoral components. However, intraoperatively there was an unexpected torrential major bleeding event, likely due to violation of the internal iliac vessels and dense post-irradiation fibrotic scar tissue. An intraoperative Vascular consultation/intervention was obtained and hemostasis was achieved. Further blood loss was anticipated if the surgery were to continue, so the replantation was abandoned in favor of patient stabilization and it was decided to return at a later time for definitive replantation. In hopes to reconstitute some of the medial acetabular defect, 30 cc of allograft bone chips with demineralized bone matrix (DBM) was implanted via an impaction grafting technique. A repeat static antibiotic spacer was then placed and further reconstruction was abandoned. The patient’s postoperative course was otherwise uneventful.

The patient followed up in clinic at 2 and 4 weeks postoperative. At the 4 week visit, repeat infection blood laboratory studies were obtained (CBC, ESR, CRP) confirming continued resolution of infection. The patient was then taken to surgery for definitive reconstruction. An intraoperative frozen section confirmed no infectious process occurring. Via an extended posterolateral approach, the acetabular defects were further prepared with bone chips allograft and DBM via impaction grafting technique. Acetabular reconstruction was achieved by a Cup-in-cup construct as described by Blumenfeld et al. [15] 64 mm Revision TM Jumbo acetabular cup (Zimmer, Warsaw, IN) with a cemented titanium shell (48 mm ADM Shell; Stryker Co, Kalamazoo, MI), a 54 mm TM buttress (Zimmer, Warsaw, IN) augment, a 42 mm dual mobility poly with a 28 mm –6 mm head (Biomet Co, Warsaw, IN). Femoral reconstruction was achieved via a distal fixation noncemented modular revision stem (Arcos STS Stem), Size C, 60 mm proximal

cone body (Biomet Co, Warsaw, IN) and supplemented with one stainless steel cable (Accord, Smith and Nephew Memphis, TN) (Fig. 6).

Due to a prolonged staging period, prolonged joint immobility, and a severely contracted soft tissue envelope, 1 cm of leg length discrepancy resulted. A negative pressure incisional vacuum device (Prevena, Acelyt Inc, San Antonio, TX) was applied for dressings and left in place for 7 days post op as recommended by the manufacturer. The patient was allowed to toe-touch weight bear to the left lower extremity while at this point had progressed to weight bearing as tolerated to the right lower extremity. Her postoperative hospital course was uneventful.

The patient was closely followed as an outpatient with intense physical therapy and periodic radiographs at regular intervals. At her 1-year outpatient follow up, the patient was ambulating independently without the use of an assistive device and had painless, complete range of motion with no significant post-operative sequelae. 1-year postoperative radiographs showed continued acceptable position of bilateral hip implants with no evidence of subsidence, loosening, or fracture (Fig. 7). Acceptable incorporation of bone graft and in-growth of components was observed. There were no residual signs of infection and she was instructed to follow up at regularly schedule 1 year intervals.

3. Discussion & review of literature

Patients with urogenital/gynecologic cancer are generally older, and it is not uncommon that orthopedic surgeons encounter patients with cancer and severe arthritis of the hip who are candidates for THA. Radiation therapy has become a common treatment modality in such patients. Because of the anatomic vicinity of these cancers, the femoroacetabular articulation and the pelvis can be exposed to a large dose of radiation.

The pathogenesis of radiation injury to the hip has been discussed previously in literature [16]; however, the exact biologic mechanism causing radiation induced osteonecrosis and chondrolysis has yet to be identified. Cell injury or death can result directly from radiation effects, but can also be the consequence of progressive interstitial and vascular fibrosis. Ionizing radiation has been shown to decrease osteocyte numbers, suppress osteoblast activity, and diminished vascularity [3]. These changes may be deleterious

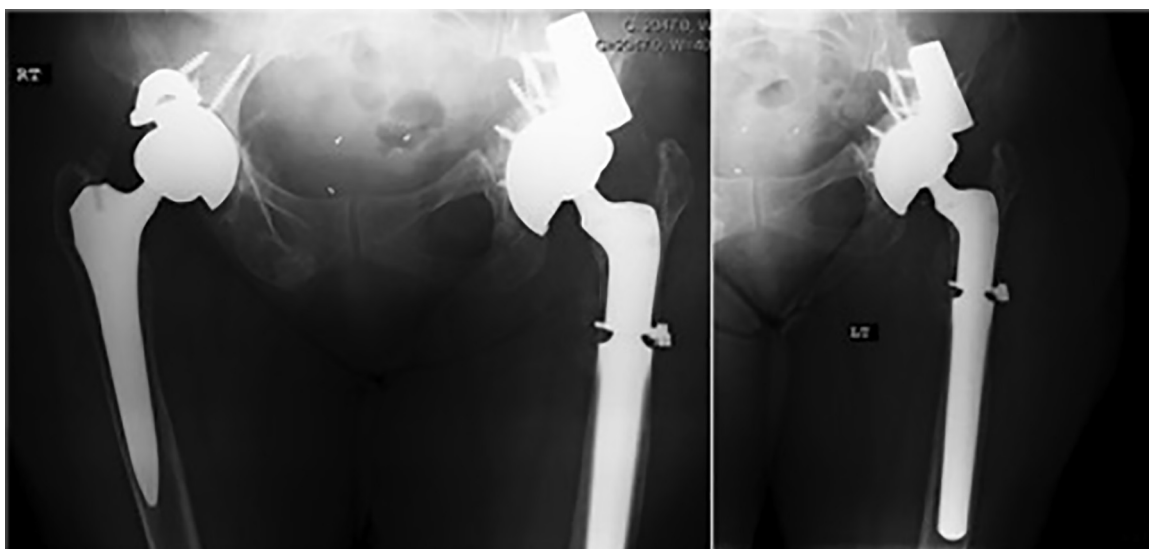


Fig. 7. Pelvic AP radiograph and AP of the left hip 1-year status post left hip revision THA. Note the complete graft incorporation and stable bone-implant osseointegration, with no signs of loosening/osteolysis/graft resorption.

effects on osseointegration and provide a challenge for long-term implant stability in THA patients. This holds even more significant as 50% of patients that had previously undergone pelvic irradiation for prostate cancer remain alive at 10 years post operative [17].

Relatively few studies are available to investigate outcomes of THA in a previously irradiated pelvis. Most previous studies have shown acetabular loosening rates as high as 44% to 52% at 2–6 years with the use of both traditional cemented and noncemented implants [4,5,7]. In a study of 49 patients with various cemented acetabular implants, Massin et al. [7] reported a 52% rate of component loosening at mean follow up of 69 months. In a study by Jacobs et al. [4], 4 of 9 noncemented titanium fiber metal acetabular components failed at an average of twenty-five months. Cho et al. [5] reported an acetabular loosening rate as high as 50% in a cohort combining both cemented and noncemented acetabular cups. In contrast, a study by Kim et al. [18] evaluated use of noncemented THA (plasma-sprayed hemispherical acetabular component) following pelvic irradiation specifically in prostate cancer patients. At short term follow up (2 years), a 93% implant survival was noted.

Multi-hole Tantalum trabecular metal cups in a primary setting have been shown to be a viable option for a post-irradiated pelvis. Joglekar et al. [17] investigated outcomes of 22 hips undergoing primary THA using tantalum TMA acetabular cups in patients with a diverse group of cancers (cervical, prostate, uterine, ovarian, colon and hematologic malignancies (myeloma and lymphoma)) who had previously undergone radiation therapy to their pelvis. At 5-year follow-up, no patients exhibited signs of acetabular loosening and thus, no revisions for fixation failure were necessary. The authors attribute their success to the properties of tantalum trabecular metal, the use of numerous multi-angled screw fixation, in addition to cementing the liner in the cup to create a stable, single-unit construct to provide maximal initial fixation and prevent motion during the early postoperative period.

The properties of a high coefficient of friction, high in-vivo growth potential, and a multi-hole revision shell construct provide the potential for stable, long-term fixation. As previously described in the literature [17,19,20], the technique of cementing polyethylene liners into acetabular shells also provides a locking effect to the screw heads and unifies the polyethylene liner with the cup, preventing backside wear. In this case, both hips (Right side: polyethylene liner cemented to cup, Left side: titanium shell (for

dual-mobility head) cemented to cup) created a single, stable construct to which accommodated bony ingrowth to the tantalum TM cup.

Concomitant infection in the setting of significant acetabular defects and previously irradiated bone creates a particularly difficult reconstruction scenario, as was the case in this patient's left hip. An additional advantage of using tantalum trabecular metal in this case is that it may serve a potential protective effect from continued periprosthetic infection. Tokarski et al. [21] recently reported on 990 hips that had undergone revision THA with titanium and tantalum revision components. Incidence of failure was lower in the tantalum group (4.4%; 20/454 hips) compared to the titanium group 9.9% (53/536 hips) ($p < 0.001$). Of particular interest were the patients that underwent revision in the setting of periprosthetic infection; among the 144 hips (64 Tantalum, 80 Titanium) for which revision had been performed because of infection, subsequent revision failure due to an infection was lower in the Tantalum group at 3.1% (2/64 hips) compared with 17.5% (14/80 hips) for the Titanium group ($p = 0.006$). Thus, the authors suggest a possible protective effect tantalum may serve in the setting of revision arthroplasty for periprosthetic infection.

In conclusion, despite of the limitations of this being a single case scenario experience with short-term follow-up of 1 year, we would like to suggest some principles and learning points in treating patients with similar, difficult clinical presentations.

1. Careful attention must be given to a patient's medical history, especially if they have been previously treated with radiation to their pelvis for prior malignancy. Although further clinical studies are needed in this patient population, cementless fixation, particularly with tantalum trabecular metal provide stable long-term fixation.
2. In the face of an aseptic and contralateral septic loosening of THA components, careful staging of treatment is of utmost importance. Following initial management of the more urgent, septic hip with explant, antibiotic spacer implant, and continued intravenous antibiotic administration to eradicate infection, management of the contralateral aseptic hip can be addressed to better accommodate rehabilitation for the anticipated second-stage reconstruction

3. Surgical dissection of post-irradiated hips can be difficult due to extensive fibrosis, scarring, and vascular friability. It can lead to extensive bleeding while negotiating surgical planes. This can be particularly treacherous if this is associated with persistent infection. It is always advisable to keep a Vascular surgeon on standby in such cases where bleeding complications may occur intraoperatively.
4. Although it is worthwhile to keep the Cup-cage/Triflange options in the surgical armamentarium in the case of severe bone loss (Paprosky Type IIIA and IIIB defects) the cup-in-cup technique (with augments and/or buttress') is an option to achieve stable fixation and bridge to remaining native bone.
5. Trabecular augments can be used for tiding over segmental acetabular defects in these Paprosky type IIIB, pelvic discontinuity cases. It can also serve as another cementless adjuvant to the construct with potential for ingrowth and osseointegration.
6. Dual-mobility heads can serve additional benefit by providing a larger, more native sized head, a decreased chance of dislocation and higher range of motion.

Conflicts of interest

None.

Funding

None.

Ethical approval

There was no requirement of Ethical approval from the Institute for the publication of this Case report as the content of the article mainly analyses a Step-wise clinical management protocol for similar Bilateral irradiated Infected Total Hip Arthroplasties with Loosening.

Consent

The authors have obtained the patients' written informed consent for print and electronic publication of the report (and for reprinting in foreign editions of the journal).

Author contribution

Dr Mohit M Kukreja- Review of Literature, Manuscript preparation and writing.

Dr.Steven Nishiyama- Assistance in Manuscript formation, contribution to literature and some editing.

Dr Parminder S Kang- Review of Manuscript, Edits and final updates.

Guarantor

Dr. Mohit M. Kukreja, MD is the guarantor and accepts full responsibility of submission to publication.

References

- [1] G. Perthes, Ueber den Einfluss der Rontgenstrahlen auf epithiale Gewebe, insbesondere auf das Carcinom, Arch. k/itt. C/tir. 71 (1903) 955–1000.
- [2] J.W. Kwon, S.J. Huh, Y.C. Yoon, S.H. Choi, J.Y. Jung, D. Oh, B.K. Choe, Pelvic bone complications after radiation therapy of uterine cervical cancer: evaluation with MRI, AJR Am. J. Roentgenol. 191 (2008) 987–994.
- [3] M.E. Dudziak, P.B. Saadeh, B.J. Mehrara, D.S. Steinbrech, J.A. Greenwald, G.K. Gittes, M.T. Longaker, The effects of ionizing radiation on osteoblast-like cells in vitro, Plast. Reconstr. Surg. 106 (2000) 1049–1061.
- [4] J.J. Jacobs, L.R. Kull, G.A. Frey, S. Gitelis, M.B. Sheinkop, T.S. Kramer, A.G. Rosenberg, Early failure of acetabular components inserted without cement after previous pelvic irradiation, J. Bone Joint Surg. Am. 77 (1995) 1829–1835.
- [5] M.R. Cho, K.W. Kwun, D.H. Lee, S.Y. Kim, J.D. Kim, Latent period best predicts acetabular cup failure after total hip arthroplasties in radiated hips, Clin. Orthop. Relat. Res. 438 (2005) 165–170.
- [6] H.W. Deleu, L.A. Pottenger, Osteonecrosis of the acetabulum following radiation therapy. A report of two cases, J. Bone Joint Surg. Am. 70 (February (2)) (1988) 293–299.
- [7] P. Massin, J. Duparc, Total hip replacement in irradiated hips: a retrospective study of 71 cases, J. Bone Joint Surg. Br. 77 (1995) 847–852.
- [8] J.H. Davies, G.Y. Laflamme, J. Delisle, J. Fernandes, Trabecular metal used for major bone loss in acetabular hip revision, J. Arthroplasty 26 (2011) 1245–1250.
- [9] M. Fernandez-Fairen, A. Murcia, A. Blanco, A. Merono, A. Murcia Jr., J. Ballester, Revision of failed total hip arthroplasty acetabular cups to porous tantalum components: a 5-year follow-up study, J. Arthroplasty 25 (2010) 865–872.
- [10] S.M. Sporer, W.G. Paprosky, Acetabular revision using a trabecular metal acetabular component for severe acetabular bone loss associated with a pelvic discontinuity, J. Arthroplasty 21 (Suppl. 2) (2006) 87–90.
- [11] J.D. Boby, R.A. Poggie, J.J. Krygier, D.G. Lewallen, A.D. Hanssen, R.J. Lewis, A.S. Unger, T.J. O'Keefe, M.J. Christie, S. Nasser, J.E. Wood, S.D. Stulberg, M. Tanzer, Clinical validation of a structural porous tantalum biomaterial for adult reconstruction, J. Bone Joint Surg. Am. 86 (Suppl. 2) (2004) 123–129.
- [12] R.M. Meneghini, K.S. Ford, C.H. McCollough, A.D. Hanssen, D.G. Lewallen, Bone remodeling around porous metal cementless acetabular components, J. Arthroplasty 25 (2010) 741–747.
- [13] R.A. Agha, A.J. Fowler, A. Saetta, I. Barai, S. Rajmohan, D.P. Orgill, The SCARE Group, The SCARE Statement: consensus-based surgical case report guidelines, Int. J. Surg. 34 (October) (2016) 180–186.
- [14] L.A. Whiteside, M. Peppers, T.A. Nayfeh, M.E. Roy, Methicillin-resistant Staphylococcus aureus in TKA treated with revision and direct intra-articular antibiotic infusion, Clin. Orthop. Relat. Res. 469 (January (1)) (2011) 26–33.
- [15] T.J. Blumenfeld, W.L. Bargar, A cup-in-cup technique to restore offset in severe protrusio acetabular defects, Clin. Orthop. Relat. Res. 470 (2012) 435–441.
- [16] P. Rubin, N.A. Elbadawi, R.A. Thomson, R.A. Cooper, Bone marrow regeneration from cortex following segmental fractionated irradiation, Int. J. Radiat. Oncol. Biol. Phys. 2 (1977) 27–38.
- [17] S.B. Joglekar, P.S. Rose, D.G. Lewallen, F.H. Sim, Tantalum acetabular cups provide secure fixation in THA after pelvic irradiation at minimum 5-year followup, Clin. Orthop. Relat. Res. 470 (November (11)) (2012) 3041–3047.
- [18] K.I. Kim, G.R. Klein, J. Sleeper, A.P. Dicker, R.H. Rothman, J. Parvizi, Uncemented total hip arthroplasty in patients with a history of pelvic irradiation for prostate cancer, J. Bone Joint Surg. Am. 89 (2007) 798–805.
- [19] H.S. Khanuja, A. Aggarwal, M.W. Hungerford, D.S. Hungerford, L.C. Jones, M.A. Mont, Cementing polyethylene liners into nonmodular acetabular components in revision total hip arthroplasty, J. Orthop. Surg. (Hong Kong) 18 (2010) 184–188.
- [20] B.D. Springer, A.D. Hanssen, D.G. Lewallen, Cementation of an acetabular liner into a well-fixed acetabular shell during revision total hip arthroplasty, J. Arthroplasty 18 (Suppl. 1) (2003) 126–130.
- [21] A.T. Tokarski, T.A. Novack, J. Parvizi, Is tantalum protective against infection in revision total hip arthroplasty? Bone Joint J. 97-B (2015) 45–49.

Open Access

This article is published Open Access at [sciencedirect.com](https://www.sciencedirect.com). It is distributed under the [IJSCR Supplemental terms and conditions](#), which permits unrestricted non commercial use, distribution, and reproduction in any medium, provided the original authors and source are credited.