

Changes in Retinal Vessel and Retinal Layer Thickness After Vitrectomy in Retinal Detachment via Swept-Source OCT Angiography

Eun Hee Hong, Heeyoon Cho, Du Roo Kim, Min Ho Kang, Yong Un Shin, and Mincheol Seong

Department of Ophthalmology, Hanyang University College of Medicine, Seoul, Korea

Correspondence: Yong Un Shin, Department of Ophthalmology, Hanyang University College of Medicine, Seoul 04763, Korea; syu2000@hanmail.net.
Mincheol Seong, Department of Ophthalmology, Hanyang University College of Medicine, Seoul 04763, Korea; goddns76@hanmail.net.

EHH and HC contributed equally to this work.

Received: April 19, 2019
Accepted: December 3, 2019
Published: February 21, 2020

Citation: Hong EH, Cho H, Kim DR, Kang MH, Shin YU, Seong M. Changes in retinal vessel and retinal layer thickness after vitrectomy in retinal detachment via swept-source OCT angiography. *Invest Ophthalmol Vis Sci.* 2020;61(2):35. <https://doi.org/10.1167/iovs.61.2.35>

PURPOSE. To compare postvitrectomy retinal and choroidal vessel density (VD) and retinal layer thickness between eyes with macula-off and macula-on rhegmatogenous retinal detachment (RRD) using swept-source optical coherence tomography (SS-OCT) and optical coherence tomography angiography (OCTA) and to identify OCTA factors associated with visual outcomes.

METHODS. We retrospectively reviewed 31 eyes that underwent pars plana vitrectomy for primary RRD. Eyes with macula-off and macula-on RRD were compared with healthy fellow eyes. Both OCT and OCTA were performed 6 months after surgery, and the macula-off RRD group was divided into two subgroups according to the presence of an outer retinal defect. The correlations between postoperative best-corrected visual acuity (BCVA) at 6 months and SS-OCT and OCTA measurements were analyzed.

RESULTS. Twenty eyes with macula-off RRD and 11 eyes with macula-on RRD were included. In the macula-off RRD group, the central retinal thickness was significantly decreased 6 months postoperatively compared with the fellow eyes ($228.9 \pm 29.7 \mu\text{m}$ and $253.6 \pm 27.7 \mu\text{m}$, $P = 0.009$). In the outer retinal defect group, the choriocapillaris plexus (CCP) VD was significantly decreased compared with the fellow eyes ($56.4\% \pm 4.8\%$ and $60.2\% \pm 4.0\%$, $P = 0.026$). In the macula-off RRD group, the postoperative BCVA at 6 months correlated significantly with the ratio of the center CCP VD of the detached eyes to that of the fellow eyes ($R^2 = 0.207$, $P = 0.025$).

CONCLUSIONS. The CCP VD could be related to the anatomical restoration of the outer retinal layer in macula-off RRD. The CCP VD as determined by OCTA could be an indicator of the visual outcome after surgery in macula-off RRD.

Keywords: rhegmatogenous retinal detachment, optical coherence tomography angiography, retinal vessel density, swept-source optical coherence tomography

Rhegmatogenous retinal detachment (RRD) is the separation of the neurosensory retina from the underlying retinal pigment epithelium (RPE) with subretinal fluid accumulation, accompanied by a break (or breaks) in the retina. It often causes severe visual loss when it involves the macula.¹ To reattach the detached retina and prevent further detachment, various treatments can be performed, including vitrectomy, scleral buckling, a combination of the two, pneumatic retinopexy, laser coagulation, or cryocoagulation.^{2,3} However, even after successful anatomic reattachment, the functional results show a wide range of visual outcomes. Poor visual acuity, permanent functional damage, persistent metamorphopsia, and color vision defects can remain after surgery, especially in cases with macular involvement.^{4,5} Factors that affect the visual outcomes of macula-off RRD include preoperative visual acuity, age of patient, duration of detachment, extent of detachment, degree of proliferative vitreoretinopathy, and concomitant preoperative choroidal detachment, along with other ophthalmologic conditions such as preretinal membrane formation, vitre-

ous membranes, macular cysts or holes, senile cataracts, or history of glaucoma.⁵⁻⁸

In some optical coherence tomography (OCT) studies, microstructures, such as the preoperative ellipsoid zone (EZ)/external limiting membrane (ELM) integrity or back-reflection integrity, postoperative EZ/ELM integrity, cone interdigitation zone (CIZ), or foveal bulge, were reported as prognostic factors after macula-off RRD surgery.⁹⁻¹¹ Kobayashi et al.¹¹ reported that the degree of restoration of the outer retinal layers at the fovea is important in predicting the final best corrected visual acuity (BCVA). Recently, Woo et al.¹² used optical coherence tomography angiography (OCTA) and reported an association between the deep foveal avascular zone (FAZ) area and final BCVA after macula-off RRD surgery. However, insufficient data are available to clearly delineate the relationship between visual outcomes after macula-off RRD surgery and retinal vessel density (VD) measured using OCTA or inner retinal thickness.

Therefore, the aim of this study was to analyze the postvitrectomy retinal thickness and VD of each layer in eyes

with macula-off and macula-on RRD using swept-source OCT (SS-OCT) and OCTA and to find OCTA factors related to postoperative visual outcomes.

METHODS

This retrospective study was approved by the Institutional Review Board (IRB) of Hanyang University Guri Hospital, Gyunggi-do, Korea, and all research conducted adhered to the tenets of the Declaration of Helsinki (IRB no. 2018-07-018). The IRB waived the need for consent, and data were accessed anonymously.

Patients who had been diagnosed with primary recent-onset RRD and surgically treated for RRD between January 1, 2016, and December 31, 2017, in the Department of Ophthalmology of Hanyang University Guri Hospital were reviewed. Thirty eyes in 30 patients who were successfully repaired with a single, uncomplicated surgical procedure (pars plana vitrectomy with C3F8 gas [14% tamponade] and who underwent ophthalmic examinations, including SS-OCT and OCTA both preoperatively and 6 months postoperatively, were included in this study. In eyes with cataracts, phacoemulsification and intraocular lens implantation were performed at the time of the vitrectomy. All surgeries were performed by two retinal surgeons (YUS and HC).

Patients with a high refractive error (spherical equivalent more than ± 6), high myopia (axial length ≥ 26.0 mm), axial length difference more than 0.3 mm between the eyes, other concomitant ocular diseases (diabetic retinopathy, glaucoma, age-related macular degeneration, uveitis, retinal vascular disease, or epiretinal membrane in either eye), postoperative complications (re-detachment, proliferative vitreoretinopathy, or vitreous hemorrhage), prior vitreoretinal surgery, or prior retinal detachment in either eye were excluded. Patients were also excluded if the fellow eye did not undergo SS-OCT and OCTA or if the SS-OCT and OCTA measurements showed poor scan quality (an image quality score lower than 45), measurement errors (such as segmentation error, centering error, or fixation error), or artifacts (defocus, blink lines, or motion artifacts).

All patients underwent a complete ophthalmic examination, including BCVA (the Snellen visual acuity with refraction), intraocular pressure (Goldman applanation tonometry), slit-lamp biomicroscopy, funduscopy, SS-OCT, and OCTA, along with a complete medical history. All evaluations were repeated 6 months postoperatively.

We defined patients with an RRD not involving the fovea as the macula-on RRD group and those with an RRD with foveal detachment as the macula-off RRD group, which was further divided into two groups: an outer retinal defect group, if the SS-OCT 6 months postoperatively showed defects in the outer retinal layer (ELM, EZ, or CIZ defect on subfovea), and an intact outer retina group otherwise. Measurements made in the unaffected fellow eye were used as control data.

SS-OCT and OCTA Imaging

All patients underwent imaging with SS-OCT and OCTA (DRI OCT Triton; Topcon Corporation, Tokyo, Japan). The SS-OCT and OCTA images were interpreted using the image viewer (IMAGeNet 6 Version 1.20.11109; Topcon Corporation). SS-OCT was performed by acquiring a 12-mm \times 9-mm three-dimensional-wide scan comprising 256 B-scans,

each of which comprised 512 A-scans (512 \times 256 A-scans, 512 A-scans for each of 256 B-scans). The total retinal thickness, retinal nerve fiber layer (RNFL) thickness, ganglion cell-inner plexiform layer (GC-IPL) thickness, and choroidal thickness were automatically calculated using auto-segmentation and manual error correction. In addition, the central EZ-RPE thickness was measured manually as the thickness between the EZ and RPE layers.

OCTA was performed by acquiring a 4.5-mm \times 4.5-mm macular cube, with each cube consisting of 320 clusters of four repeated B-scans. Each B-scan was constructed from 300 A-scans centered on the fovea. The scan size of 4.5 \times 4.5 mm was derived from the calculation of the linear distance on the surface of the retina by using a defined axial length set by the OCT device manufacturer. For DRI OCT Triton (Topcon Corporation), this length was 24.39 mm. Therefore, the actual linear dimensions of the image may vary in proportion to the axial length. To avoid potential errors according to the axial length, we adjusted the scale of the OCTA images by using a previously introduced formula^{13,14}: $[D_t^2/D_m^2 = 0.00196 (AL - 1.82)^2]$, where D_t is the true diameter on the fundus, D_m is the measured OCTA image diameter, and AL is the axial length. Thereafter, using ImageJ version 1.8.0 (National Institutes of Health, Bethesda, MD, USA), the calculated D_t was assigned to the true image size. The VD ([total vessel area]/[total measured area] %) of the superficial retinal capillary plexus (SCP) and deep retinal capillary plexus (DCP) was measured in two regions: the central region 1 mm in diameter centered on the foveal center and the parafoveal region of a circular annulus region between 1 and 3 mm in diameter (the average of the superior, temporal, inferior, and nasal subfields) (Figs. 1–3). In the choriocapillaris plexus (CCP), we used postprocessing to compensate for choriocapillaris signal attenuation due to structural changes in the RPE/basement membrane complex by using the en face structural CCP image and the en face flow CCP image, as described by Zhang et al.¹⁵ Using the compensated CCP image, we performed automatic local thresholding to obviate small regional variations, as described by Spaide¹⁶ using ImageJ. Thereafter, using this thresholded binarized CCP image, the percentage of flow deficits (FD%, the percentage of flow deficit areas in each analyzed area) in each of the central and parafoveal regions was calculated using ImageJ. Using FD%, we calculated the VD of CCP. The FAZ area was defined as the area inside the central border of the capillary network. The superficial FAZ area was determined by manually outlining the inner border of the foveal capillaries using OCTA system software and then automatically calculated. Manual error correction, manual thickness measurement, and manual outlining of the FAZ were all done by two independent investigators (EHH and DRK), who were blinded to the group assignment, and the average of the two measurements was used in the analyses. To investigate the correlation between OCTA parameters and postoperative BCVA, we used the retinal detachment (RD)/fellow (F) ratio, defined as the ratio between the measurements in the RD eye and those in the fellow eye (e.g., center CCP_{RD/F} ratio = center CCP VD in the RD eye/center CCP VD in the fellow eye).

Statistical Analysis

All statistical analyses were performed using IBM SPSS Statistics for Windows, version 22.0 (IBM Corp., Armonk,

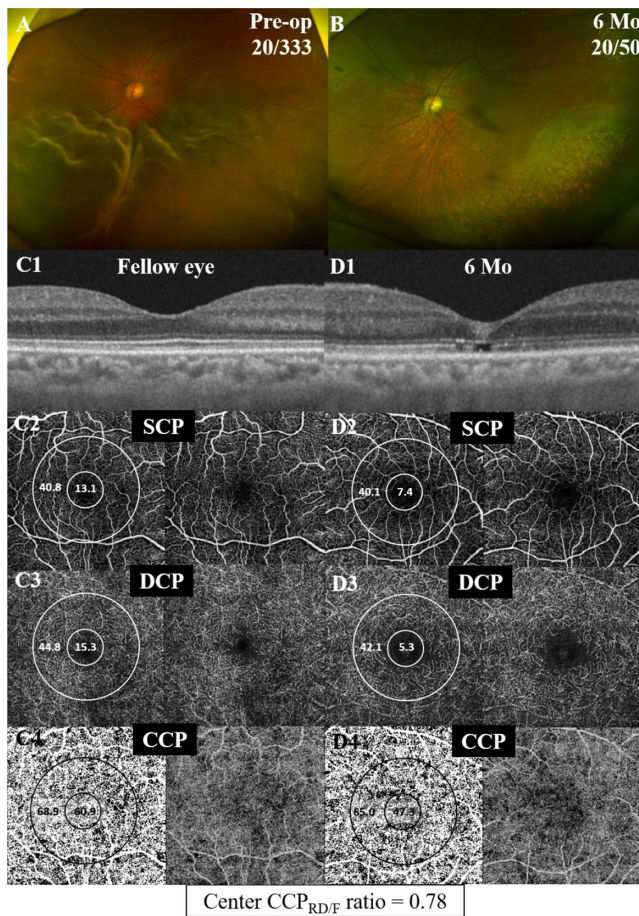


FIGURE 1. A representative case of a 60-year-old male patient with macula-off RRD in his left eye. (A) Preoperative fundus image shows inferior bullous macula-off RRD. The preoperative BCVA was 20/333. (B) Six months postoperatively, the fovea was attached successfully, but the postoperative BCVA was 20/50. (C, D) SS-OCT images show disruption of the CIZ and EZ in the affected eye (D1), compared with the fellow eye (C1). C2-4 and D2-4 show topographic measurements of the VD in the SCP, DCP, and CCP. The measured areas are the central region of 1 mm in diameter centered on the foveal center and the parafoveal region of a circular annulus region between 1 and 3 mm in diameter. The central CCP VD is decreased to 47.3 in the affected eye (D4), compared with 60.9 in the fellow eye (C4). The center $CCP_{RD/F}$ ratio (= center CCP VD in the RD eye/center CCP VD in the fellow eye) is 0.78.

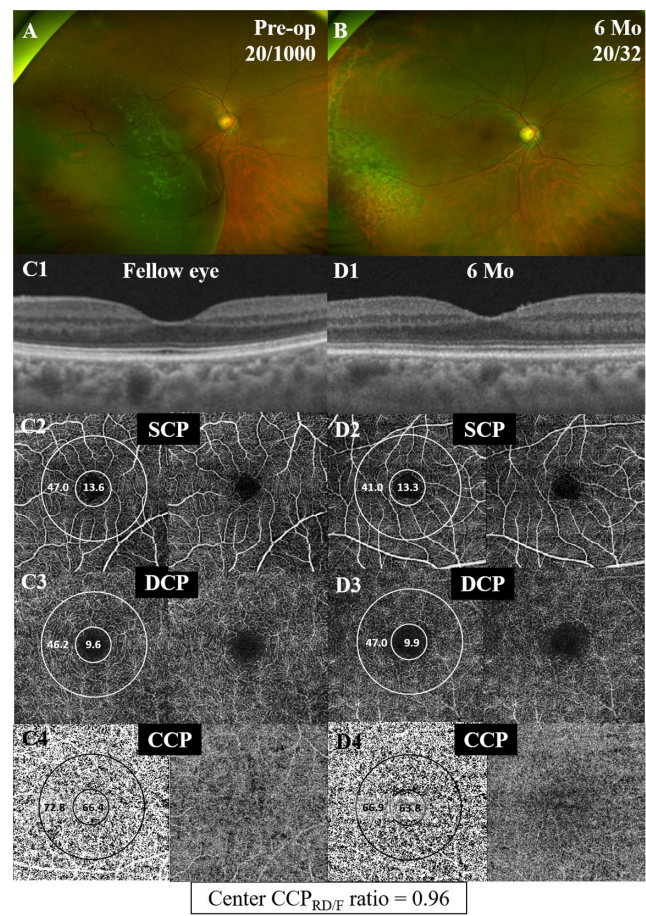


FIGURE 2. A representative case of a 69-year-old female patient with macula-off RRD in her right eye. (A) Preoperative fundus image shows inferotemporal bullous macula-off RRD. The preoperative BCVA was 20/1000. (B) Six months postoperatively, the fovea was attached successfully, but the postoperative BCVA was 20/32. (C, D) SS-OCT images show intact outer retinal layer in both the affected eye (D1) and the fellow eye (C1). C2-4 and D2-4 show topographic measurements of the VD in the SCP, DCP, and CCP. The measured areas are the central region of 1 mm in diameter centered on the foveal center and the parafoveal region of a circular annulus region between 1 and 3 mm in diameter. The central CCP VD is 63.8 in the affected eye (D4) and 66.4 in the fellow eye (C4). The center $CCP_{RD/F}$ ratio (= center CCP VD in the RD eye/center CCP VD in the fellow eye) is 0.96.

RESULTS

A total of 31 patients (23 men, 8 women) with a mean age of 53.3 ± 14.4 years were included in this study. Eleven eyes had a macula-on RRD, and 20 eyes had a macula-off RRD, of which 11 eyes were in the outer retinal defect group, and 9 eyes were in the intact outer retina group. Figures 1 to 3 show representative cases from the outer retinal defect, intact outer retina groups, and macula-on RRD, respectively. The mean onset duration from initial symptoms was 7.2 ± 6.1 days. Baseline patient demographic parameters and ocular characteristics are summarized in Table 1. The preoperative and postoperative BCVA (logarithm of the minimum angle of resolution [logMAR]) was significantly better in the macula-on RRD group than in the macula-off RRD group (1.02 ± 0.76 and 1.45 ± 0.57 , $P < 0.001$; 0.26 ± 0.28 and 0.33 ± 0.30 , $P = 0.029$, respectively) (Table 1). The

NY, USA). Continuous variables are presented as mean values \pm standard deviations (SDs). Interobserver agreement between the two independent investigators was evaluated using intraclass correlation coefficients (ICCs). The Wilcoxon signed rank test was used to compare differences between the RD eyes and their unaffected fellow eyes in each group. The Mann-Whitney U test and Pearson chi-square test were used to compare differences between two groups (macula-on RRD versus macula-off RRD, outer retinal defect versus intact outer retina). Spearman's rank correlation analyses were used to examine the relationships between OCT and OCTA measurements and postoperative BCVA. Univariate and multivariate regression analyses were used to find the OCTA parameters most associated with postoperative BCVA in the macula-off RRD group. Statistical significance was defined as $P < 0.05$.

TABLE 1. Baseline Demographic and Ocular Characteristics in Eyes With a Macula-On or Macula-Off Rhegmatogenous Retinal Detachment

Characteristic	Macula-On RRD (n = 11)	Macula-Off RRD (n = 20)	P*	Macular-Off RRD		P†
				Outer Retinal Defect (n = 11)	Intact Outer Retina (n = 9)	
Age (y)	53.1 ± 10.9	53.4 ± 16.3	0.730	60.4 ± 11.4	45.8 ± 19.4	0.056
Sex (male/female)	9/2	14/6	0.472§	8/3	6/3	0.769‡
Axial length (mm)	25.8 ± 2.3	25.3 ± 2.5	0.699	24.5 ± 1.60	26.4 ± 3.05	0.201
Preoperative BCVA (logMAR)	0.24 ± 0.33	1.45 ± 0.57	<0.001	1.34 ± 0.55	1.58 ± 0.59	0.295
(Snellen)	20/30	20/250		20/222	20/286	
Postoperative BCVA (logMAR)	0.14 ± 0.18	0.33 ± 0.30	0.029	0.45 ± 0.34	0.17 ± 0.14	0.038
(Snellen)	20/25	20/36		20/45	20/29	
Onset duration (days)	6.4 ± 5.5	7.7 ± 6.5	0.670	8.7 ± 7.6	6.3 ± 4.8	0.824
Central retinal thickness (μm)	270.0 ± 35.8	228.9 ± 29.7	0.001	212.1 ± 27.4	240.7 ± 27.3	0.201

Postoperative BCVA and central retinal thickness were measured 6 months postoperatively.

Data are presented as mean ± standard deviation for continuous variables.

* Mann-Whitney *U* test, macula-on RRD versus macula-off RRD;

† Mann-Whitney *U* test, outer retinal defect versus intact outer retinal defect.

‡ Pearson chi-square test.

postoperative BCVA (logMAR) was better in the intact outer retina group than in the outer retinal defect group (0.17 ± 0.14 and 0.45 ± 0.34 , $P = 0.038$; Table 1). The ICCs for the FAZ area measurements and all OCT and OCTA parameters were greater than 0.8, indicating good agreement.

Table 2 compares the retinal thickness parameters in the RD eyes 6 months postoperatively with those of the fellow eyes in the macula-on RRD, macula-off RRD, outer retinal defect, and intact outer retinal groups. Six months postoperatively, the central retinal thickness was significantly thinner in the detached eyes than in the fellow eyes in the macula-off RRD and outer retinal defect groups (macula-off RRD, 228.9 ± 29.7 and 253.6 ± 27.7 , $P = 0.009$; outer retinal defect group, 219.2 ± 29.1 and 254.4 ± 35.5 , $P = 0.016$). The RNFL thickness, GC-IPL thickness, and choroidal thickness in the macula-on and macula-off RRD eyes did not differ significantly from that of the fellow eyes. The EZ-RPE thickness was significantly thinner in the detached eyes than in the fellow eyes in the macula-off RRD group, and it was thinner in the outer retinal defect group than in the intact outer retinal defect group.

Table 3 compares the VD parameters in the RD eyes 6 months postoperatively with those of the fellow eyes in the macula-on RRD, macula-off RRD, outer retinal defect, and intact outer retinal groups. Six months postoperatively, the center CCP VD was markedly decreased in the detached eyes compared with the fellow eyes in the outer retinal defect group ($56.4\% \pm 4.8\%$ and $60.2\% \pm 4.0\%$, $P = 0.026$). The SCP and DCP VD in the detached eyes did not differ significantly from those in the fellow eyes in any of the groups.

Correlation analyses were performed to further evaluate which OCT and OCTA parameters correlated with postoperative BCVA in the macula-off RRD group (Table 4). Among the parameters, only the center $CCP_{RD/F}$ ratio showed significant correlation with postoperative BCVA ($R = -0.551$, $P = 0.012$; Figure 4). The univariate regression analysis also showed that only the center $CCP_{RD/F}$ ratio was significantly

associated with postoperative BCVA ($R^2 = 0.207$, $P = 0.025$). A stepwise multivariate regression analysis including age, sex, onset duration, and OCT and OCTA parameters showed that the parameter most associated with postoperative BCVA was the center $CCP_{RD/F}$ ratio (standardized $B = -0.499$; $B = -1.131$; $P = 0.025$).

DISCUSSION

In the present study, we compared the retinal thickness of each layer and the retinal and choroidal vessel density of eyes with macula-off RRD with those of eyes with macula-on RRD and found that the postoperative subfoveal vessel density of the choriocapillaris correlated significantly with visual outcomes in macula-off RRD. This is the first study to use OCTA VD measurements to investigate visual prognostic factors after RRD surgery.

Several previous studies have reported the recovery of outer retinal thickness and photoreceptors over time after retinal detachment surgery in macula-off RRD.^{10,11,17} Ra et al.¹⁷ used electroretinography and OCT to report a long-term increase in cone density and outer retinal layer thickness after buckling surgery for RRD. They divided EZ-RPE thickness into EZ-CIZ thickness and CIZ-RPE thickness and showed an increase in both of them 12 months postoperatively compared with 6 months postoperatively. Park et al.¹⁰ revealed an increase in outer segment (OS) length and a decrease in the inner segment/OS length ratio from 1 month to 6 months after reattachment. They also showed that the OS length ratio between the RD eye and its fellow eye correlated well with postoperative visual acuity after surgery. Kobayashi et al.¹¹ demonstrated that restoration of the outer retinal layers/bands at the fovea occurs following macula-off RRD repair, and the reappearance of a foveal bulge correlated significantly with postoperative visual acuity. Eyes with complete restoration of outer retinal layers, including the foveal bulge, showed better visual outcomes than eyes with partial restoration. In the present

TABLE 2. Comparison Between the Retinal Thickness of Eyes With Rhegmatogenous Retinal Detachment 6 Months Postoperatively and That of the Fellow Eyes

	Macula-On RRD (<i>n</i> = 11)						Macula-Off RRD (<i>n</i> = 20)						Macula-Off RRD					
	Macula-On RRD (<i>n</i> = 11)			Macula-Off RRD (<i>n</i> = 20)			Outer Retinal Defect (<i>n</i> = 11)			Intact Outer Retina (<i>n</i> = 9)			Macula-Off RRD			Macula-Off RRD		
	On RD	Fellow	<i>P</i> [‡]	Off RD	Fellow	<i>P</i> [‡]	Defect(+)	Off RD	Fellow	<i>P</i> [‡]	Defect(-)	Off RD	Fellow	<i>P</i> [‡]	Off RD	Fellow	<i>P</i> [‡]	
Total retinal thickness																		
Center	270.0 ± 35.8	247.0 ± 26.0	0.130	228.9 ± 29.7	253.6 ± 27.7	0.009	219.2 ± 29.1	254.4 ± 35.5	0.016	240.7 ± 27.3	252.7 ± 15.6	0.214	0.001	0.201	270.0 ± 35.8	247.0 ± 26.0	0.130	228.9 ± 29.7
Parafovea	316.7 ± 22.5	307.8 ± 18.1	0.248	300.4 ± 23.9	308.1 ± 20.4	0.296	299.5 ± 27.4	317.3 ± 13.5	0.155	301.5 ± 20.5	296.9 ± 22.4	0.953	0.049	1.00	316.7 ± 22.5	307.8 ± 18.1	0.248	300.4 ± 23.9
RNFL thickness																		
Center	11.8 ± 6.5	8.4 ± 3.6	0.140	9.3 ± 4.4	9.4 ± 5.9	0.722	9.7 ± 4.9	10.1 ± 7.7	0.858	8.8 ± 3.9	8.6 ± 2.8	0.752	0.403	0.824	11.8 ± 6.5	8.4 ± 3.6	0.140	9.3 ± 4.4
Parafovea	30.2 ± 5.5	28.9 ± 4.9	0.449	31.2 ± 4.7	29.2 ± 3.9	0.107	32.4 ± 5.0	30.3 ± 4.4	0.373	29.7 ± 4.0	27.8 ± 2.6	0.123	0.761	0.261	30.2 ± 5.5	28.9 ± 4.9	0.449	31.2 ± 4.7
GC-IPL thickness																		
Center	54.9 ± 14.4	50.5 ± 8.7	0.689	45.2 ± 10.8	47.7 ± 11.7	0.519	45.2 ± 12.8	47.6 ± 12.9	0.789	45.2 ± 8.7	47.7 ± 10.9	0.483	0.054	0.882	54.9 ± 14.4	50.5 ± 8.7	0.689	45.2 ± 10.8
Parafovea	86.4 ± 13.6	91.3 ± 10.2	0.248	82.7 ± 15.2	85.8 ± 11.0	0.455	83.3 ± 18.2	91.0 ± 7.1	0.477	81.8 ± 11.6	79.4 ± 12.0	0.953	0.502	0.503	86.4 ± 13.6	91.3 ± 10.2	0.248	82.7 ± 15.2
EZ-RPE thickness																		
Center	50.1 ± 7.1	53.0 ± 10.5	0.196	42.9 ± 9.4	50.9 ± 8.4	<0.001	38.8 ± 9.2	47.9 ± 7.5	0.008	47.9 ± 7.3	54.6 ± 8.3	0.020	0.066	0.020	50.1 ± 7.1	53.0 ± 10.5	0.196	42.9 ± 9.4
Choroidal thickness																		
Center	198.5 ± 98.5	190.1 ± 95.9	0.415	176.5 ± 69.4	180.2 ± 74.4	0.668	202.5 ± 72.0	195.2 ± 79.7	0.657	144.7 ± 53.6	161.8 ± 67.2	0.374	0.611	0.067	198.5 ± 98.5	190.1 ± 95.9	0.415	176.5 ± 69.4
Parafovea	185.7 ± 89.7	176.1 ± 86.6	0.203	174.9 ± 66.4	177.6 ± 67.8	0.601	194.0 ± 71.3	189.4 ± 73.3	0.859	151.5 ± 54.8	163.2 ± 61.5	0.374	0.919	0.112	185.7 ± 89.7	176.1 ± 86.6	0.203	174.9 ± 66.4

Data are presented as mean ± standard deviation. *P* values derived using Mann-Whitney *U* test.

* Macula-on RRD versus macula-off RRD.

† Outer retinal defect(+) versus outer retinal defect(-).

‡ *P* values derived using the Wilcoxon signed rank test.

TABLE 3. Comparison Between the Vessel Density in the Superficial Retinal Capillary Plexus, Deep Retinal Capillary Plexus, and Choriocapillaris of Eyes With Rhegmatogenous Retinal Detachment 6 Months Postoperatively and That of the Fellow Eyes

	Macula-Off RRD											
	Macula-On RRD (<i>n</i> = 11)			Macula-Off RRD (<i>n</i> = 20)			Outer Retinal Defect (<i>n</i> = 11)			Intact Outer Retina (<i>n</i> = 9)		
	On RD	Fellow	<i>P</i> [‡]	Off RD	Fellow	<i>P</i> [‡]	Defect(+) Off RD	Fellow	<i>P</i> [‡]	Defect(-) Off RD	Fellow	<i>P</i> [‡]
SCP VD												
Center	14.5 ± 5.3	13.1 ± 4.3	0.790	15.3 ± 5.7	14.8 ± 4.0	0.940	14.7 ± 6.9	14.1 ± 4.3	0.929	16.0 ± 4.0	15.7 ± 3.6	0.859
Parafovea	44.4 ± 2.6	45.0 ± 3.9	0.328	45.0 ± 2.4	45.5 ± 2.6	0.135	44.4 ± 2.2	44.8 ± 2.6	0.424	45.6 ± 2.5	46.3 ± 2.5	0.260
DCP VD												
Center	15.4 ± 5.4	13.8 ± 6.4	0.657	14.8 ± 6.1	12.6 ± 5.9	0.173	14.4 ± 7.5	11.9 ± 5.7	0.534	15.2 ± 4.2	13.4 ± 6.4	0.123
Parafovea	50.1 ± 2.9	49.5 ± 3.4	0.534	48.6 ± 2.8	50.0 ± 3.8	0.079	47.4 ± 2.2	48.7 ± 2.4	0.286	49.9 ± 2.8	51.5 ± 4.8	0.214
CCP VD												
Center	58.1 ± 9.2	58.9 ± 10.2	0.657	59.6 ± 9.4	61.9 ± 5.1	0.067	56.4 ± 4.8	60.2 ± 4.0	0.026	63.5 ± 12.3	64.0 ± 5.8	0.761
Parafovea	66.1 ± 5.3	65.8 ± 5.4	0.859	66.1 ± 6.3	68.0 ± 5.3	0.086	65.7 ± 4.9	67.5 ± 4.5	0.131	66.5 ± 8.1	68.6 ± 6.4	0.374
FAZ area	244.1 ± 92.1	247.2 ± 90.9	0.534	312.8 ± 127.3	299.4 ± 96.7	0.627	346.5 ± 150.4	325.2 ± 102.7	0.477	271.5 ± 81.9	267.9 ± 83.5	0.953

Data are presented as mean ± standard deviation. *P* values derived using the Mann-Whitney *U* test.

* Macula-on RRD versus macula-off RRD.

† Outer retinal defect(+) versus outer retinal defect(-).

‡ *P* values derived using the Wilcoxon signed rank test.

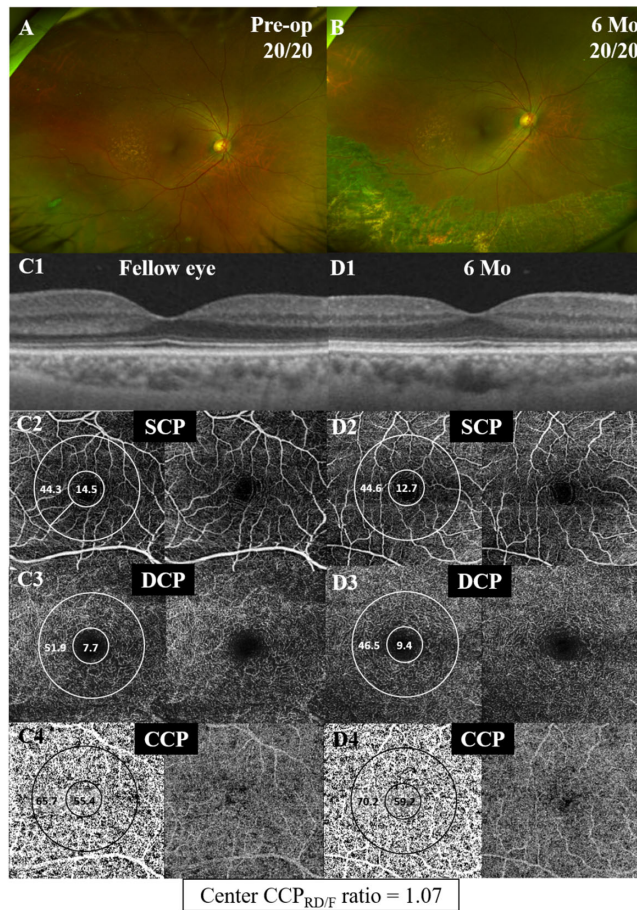


FIGURE 3. A representative case of a 60-year-old female patient with macula-on RRD in her right eye. (A) Preoperative fundus image shows inferotemporal macula-on RRD. The preoperative BCVA was 20/20. (B) Six months postoperatively, the fovea was attached successfully, but the postoperative BCVA was 20/20. (C, D) SS-OCT images show intact outer retinal layer in both the affected eye (D1) and the fellow eye (C1). C2-4 and D2-4 show topographic measurements of the VD in the SCP, DCP, and CCP. The measured areas are the central region of 1 mm in diameter centered on the foveal center and the parafoveal region of a circular annulus region between 1 and 3 mm in diameter. The central CCP VD is 59.2 in the affected eye (D4) and 55.4 in the fellow eye (C4). The center CCP_{RD/F} ratio (= center CCP VD in the RD eye/center CCP VD in the fellow eye) is 1.07.

study, we compared macular-off RD eyes according to their recovery of the outer retinal layer after reattachment. Consistent with previous studies, total retina thickness and EZ-RPE thickness decreased after surgery in the macula-off RD eyes compared with the fellow eyes.

Previous studies have reported changes in the inner retinal thickness after macula-off RRD surgery.¹⁷⁻²⁰ Menke et al.¹⁸ reported that the GC-IPL thickness decreased over time after surgery, which was supported by the study by Faude et al.¹⁹ that showed a loss of ganglion cell axons and considerable ganglion cell death, particularly in the detached retina. In contrast, Ra et al.¹⁷ reported that the thickness of the inner retinal layer did not differ significantly between RD eyes and fellow eyes after surgery. We also found that the RNFL and GC-IPL thickness in the RD eyes did not differ significantly from those in the fellow eyes after reattachment. In the experimental study by Guerin et al.,²⁰

TABLE 4. Spearman's Rank Correlation of OCT and OCTA Parameters (RD/F ratio) and Postoperative Best-Corrected Visual Acuity (logMAR) in Macula-Off RRD Group

Characteristic	Center	Parafovea
OCTA RD/F ratio		
VD		
SCP VD	-0.244 (<i>P</i> = 0.301)	0.095 (<i>P</i> = 0.690)
DCP VD	0.175 (<i>P</i> = 0.460)	-0.167 (<i>P</i> = 0.480)
CCP VD	-0.551 (<i>P</i> = 0.012)	-0.163 (<i>P</i> = 0.491)
FAZ	-0.195 (<i>P</i> = 0.410)	
OCT RD/F ratio		
Thickness		
Total retina	-0.147 (<i>P</i> = 0.536)	-0.144 (<i>P</i> = 0.545)
RNFL	-0.405 (<i>P</i> = 0.076)	-0.292 (<i>P</i> = 0.212)
GC-IPL	-0.271 (<i>P</i> = 0.249)	-0.163 (<i>P</i> = 0.492)
Choroid	0.095 (<i>P</i> = 0.691)	-0.014 (<i>P</i> = 0.952)
EZ-RPE	-0.304 (<i>P</i> = 0.193)	

RD/F ratio is the ratio between the measurements in the RD eye and the fellow eye. *P* values derived using Spearman's rank correlation analysis.

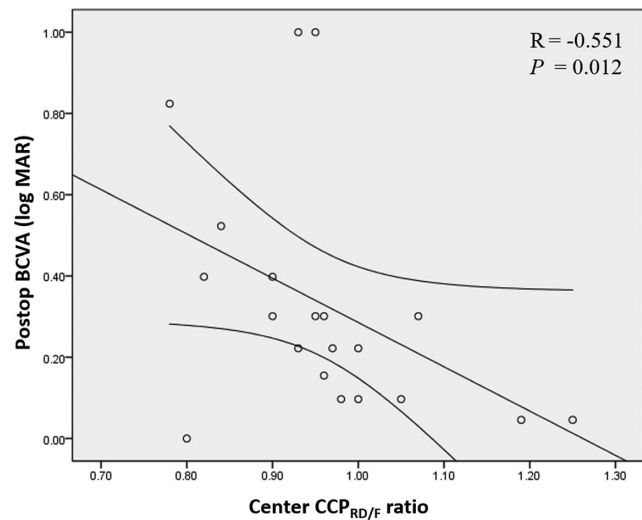


FIGURE 4. Correlation between postoperative BCVA and center CCP_{RD/F} in macula-off retinal detachment. The curved lines indicate the 95% confidence interval of the linear regression line. Center CCP_{RD/F} ratio = center CCP vessel density in the RD eye/center CCP vessel density in the fellow eye.

the inner segment remained intact during 7 days of retinal detachment. Therefore, our results were probably due to the short onset duration of macula-off RRD before surgery.

Recently, a few studies of postoperative change in RRD have used OCTA to consider the FAZ area.^{12,21} Woo et al.¹² showed that both the superficial and deep FAZ areas correlated negatively with BCVA in the first 2 months after RRD repair in macula-off RRD patients, and the deep FAZ area in macula-off RD eyes was larger than in macula-on RRD. They suggested that the DCP might be vulnerable to tissue hypoxia, and the increase in deep FAZ area might indicate the severity of macular ischemia. On the other hand, Sato et al.²¹ reported that the superficial and deep FAZ area had no correlation with postoperative BCVA at 1, 3, and 6 months after vitrectomy in macula-off RRD. In the present study, the superficial FAZ area in macula-off RRD 6 months after RRD repair did not differ significantly from that in the fellow eye,

and we found no correlation with postoperative BCVA, as Sato et al.²¹ reported.

Our results imply that the recovery state of the outer retinal layer after surgery is associated with the postoperative VD of the subfoveal choriocapillaris, which correlates well with visual outcomes. In the intact outer retina group, the center CCP VD of the RD eye did not differ from that of the fellow eye. However, in the outer retinal defect group, the center CCP VD of the RD eye was significantly lower than that of the fellow eye. The blood supply to the retina differs between the outer retina and the inner retina. The RPE, photoreceptor layer, ELM, and outer nuclear layer (ONL) layer are supplied by choriocapillaris, whereas the outer plexiform layer is supplied by the central retinal artery and partially by choriocapillaris, forming the DCP. The inner retina is supplied by the central retinal artery, forming the SCP.²² Thus, well-preserved CCP blood flow could result in the restoration of the outer retina. The association between CCP blood flow and the outer retinal layer has been reported in some diseases related to choroidopathy.^{23–25} One of these studies reported greater areas of flow voids in the CCP layer beneath the area of disrupted photoreceptors than in the CCP layer beneath the area of intact photoreceptors in ischemic maculopathy.²⁵ Although the causal relationship between decreased CCP blood flow and the defect of the photoreceptor layer in macula-off RRD could not be elucidated in this retrospective study, studies have shown that the subretinal fluid (SRF) contains inflammatory cytokines and other factors that contribute to triggering and enhancing the inflammatory and immune responses.^{26,27} The blood-retina barrier may also get damaged during RD, similar to the RPE cells,^{28,29} and vasoconstrictors, such as endothelin, are known to be present in the SRF.^{30,31} Taken together, we could hypothesize that, after RRD occurred, the detached neurosensory retina might be damaged by inflammatory cytokines in the SRF, and CCP blood flow might be impaired because of such cytokines. After successful attachment, the well-recovered CCP blood flow may influence the restoration of the outer retinal layer; alternatively, the poorly recovered CCP blood flow may influence the permanent impairment or slow recovery of the outer retinal layer. As mentioned above, we could not prove this hypothesis in this retrospective study. However, Wang et al.³² also reported decreased CCP VD at 2 weeks postoperatively, which gradually recovered until 8 weeks postoperatively.

We further evaluated the correlation between the OCT and OCTA parameters and postoperative visual acuity and found that center CCP VD ratio correlated well with postoperative visual acuity. However, our results should be interpreted with caution. Contrary to other studies that reported the correlation between postoperative visual acuity and the integrity of outer retinal layer,^{9–11,17,33} the EZ-RPE thickness (a parameter related to the outer retinal layer status used in this study) was not a significant contributing factor. Based on the results shown in Table 1, the EZ-RPE thickness was decreased in the RRD eyes compared with fellow eyes, both in the outer-retinal-defect group and the intact-outer-retina group. This suggests that the EZ-RPE thickness alone does not sufficiently reflect the integrity of the outer retinal layer. Previously, other parameters, such as the ELM-EZ thickness,³³ the ELM-RPE thickness,³³ the EZ-CIZ thickness,¹⁷ the CIZ-RPE thickness,¹⁷ or the inner segment/outer segment ratio,¹⁰ have been used to reflect the status of the outer retinal layer. Our limitation was that we used only the EZ-RPE thickness as an OCT parameter to establish the outer reti-

nal status. Further analyses, which include the other outer retinal layer parameters with larger samples, may assist in establishing a stronger relationship. The result here regarding the OCTA parameter is partially consistent with the findings of a recent report by Wang et al.,³² which showed that parafoveal SCP VD, DCP VD, and CCP VD increased over time (from 2 to 12 weeks) in eyes with macula-off RRD after successful pars plana vitrectomy (PPV), and the final BCVA was positively associated with CCP VD. The difference is that we analyzed both the parafoveal and central VDs at 6 months after PPV in this study, whereas Wang et al.³² analyzed only parafoveal VD up to 12 weeks after PPV, and they did not investigate central VD. Taken together, we could hypothesize that in some patients with macula-off RRD whose subfoveal CCP blood flow does not normalize to the level before the RRD even after successful reattachment for some reasons, the restoration of the outer retina is also disrupted and the final visual outcome is poorer than that of patients whose subfoveal CCP blood flow is well normalized. This is the first study to show a possible relationship between outer retinal restoration, the central VD of the choriocapillaris, and visual prognosis in macula-off RD eyes after vitrectomy.

This study has several limitations. First, it was retrospective and had a relatively small sample size, which could have resulted in an insufficient number of patients for adequate analysis. However, recent OCT and OCTA studies on RRD also used similar sample sizes. Recently, Wang et al.³² studied 14 eyes with macular-off RRD to investigate OCTA parameters to predict postoperative visual outcomes in macular-off RRD. Woo et al.³² included 34 eyes with RRD, wherein 19 eyes had macula-off RRD,¹² and Sato et al.²¹ enrolled 22 eyes with macula-off RRD to investigate the correlation between FAZ area and visual outcome. Therefore, this study, despite its small sample size, is still worth comparing with other studies. Second, we did not include cases of chronic retinal detachment. A longer duration of detachment is known to correlate with less visual acuity, so it might also affect the restoration of outer retinal structures. Third, we included only patients who received vitrectomy with intravitreal C3F8 (14%) gas tamponade. Further studies including cases of successful reattachment via other surgical procedures, including PPV with silicone oil tamponade or scleral buckling surgery, are needed to compare the results according to the surgical procedures. Fourth, segmentation errors and artifacts might exist in the OCT and OCTA images even though we excluded cases with poor quality. However, the SS-OCTA used in this study has the longest wavelength, which means that using it could be an advantage in obtaining quantitative data about deeper layers such as the CCP VD, an important parameter in this study. A previous report showed that the SS-OCTA used in this study resulted in fewer projection artifacts than did other OCTAs based on spectral-domain OCT because of its swept-source light source.³⁴ We also performed manual error correction as much as possible to reduce segmentation errors. In addition, although we used postprocessing on CCP images to reduce projection artifacts, these could still affect the CCP VD measurements. Currently, no “gold-standard” method is available to completely solve this problem in OCTA assessments. However, most projection artifacts were observed outside the central and parafoveal areas. Usually, no vessels are present in the central foveal area (FAZ area). Therefore, the VD of the central subfield area in the choriocapillaris layer is less affected by projection artifacts. Fifth, because it is a retrospective review, we could not evaluate the repeata-

bility of the OCT and OCTA measurements. Finally, we do not have OCT and OCTA measurements prior to the RRD, so we could not compare the retinal thickness and VD before the RRD and after the surgery. Instead, we used measurements from the fellow eyes as the control.

In conclusion, the results of this study suggest that the CCP VD is related to anatomical and functional restoration of the outer retinal layer in macula-off RRD. The subfoveal CCP VD ratio can be considered an OCTA marker that shows good correlation with visual outcomes after surgery for macula-off RRD.

Acknowledgments

Supported by National Research Foundation of Korea grants NRF-2017R1D1A1B03030905 (YUS), NRF-2017R1D1A1B03031934 (HC), and NRF-2019R1A2C1011676 (MS).

Disclosure: **E.H. Hong**, None; **H. Cho**, None; **D.R. Kim**, None; **M.H. Kang**, None; **Y.U. Shin**, None; **M. Seong**, None

References

- Machemer R. The importance of fluid absorption, traction, intraocular currents, and chorioretinal scars in the therapy of rhegmatogenous retinal detachments: XLI Edward Jackson Memorial Lecture. *Am J Ophthalmol*. 1984;98:681–693.
- Vrabec TR, Bauman CR. Demarcation laser photocoagulation of selected macula-sparing rhegmatogenous retinal detachments. *Ophthalmology*. 2000;107:1063–1067.
- Nemet A, Moshiri A, Yiu G, Loewenstein A, Moisseiev E. A review of innovations in rhegmatogenous retinal detachment surgical techniques. *J Ophthalmol*. 2017;2017:4310643.
- Tani P, Robertson DM, Langworthy A. Prognosis for central vision and anatomic reattachment in rhegmatogenous retinal detachment with macula detached. *Am J Ophthalmol*. 1981;92:611–620.
- Burton T. Preoperative factors influencing anatomic success rates following retinal detachment surgery. *Trans Am Ophthalmol Soc*. 1977;83:OP499–OP505.
- Ross W. Visual recovery after macula-off retinal detachment. *Eye*. 2002;16:440.
- Burton TC. Recovery of visual acuity after retinal detachment involving the macula. *Trans Am Ophthalmol Soc*. 1982;80:475.
- Mowatt L, Tarin S, Nair R, Menon J, Price N. Correlation of visual recovery with macular height in macula-off retinal detachments. *Eye*. 2010;24:323.
- Kang HM, Lee SC, Lee CS. Association of spectral-domain optical coherence tomography findings with visual outcome of macula-off rhegmatogenous retinal detachment surgery. *Ophthalmologica*. 2015;234:83–90.
- Park DH, Choi KS, Sun HJ, Lee SJ. Factors associated with visual outcome after macula-off rhegmatogenous retinal detachment surgery. *Retina*. 2018;38:137–147.
- Kobayashi M, Iwase T, Yamamoto K, et al. Association between photoreceptor regeneration and visual acuity following surgery for rhegmatogenous retinal detachment. *Invest Ophthalmol Vis Sci*. 2016;57:889–898.
- Woo JM, Yoon YS, Woo JE, Min JK. Foveal avascular zone area changes analyzed using OCT angiography after successful rhegmatogenous retinal detachment repair. *Curr Eye Res*. 2018;43:674–678.
- Bennett AG, Rudnicka AR, Edgar DF. Improvements on Littmann's method of determining the size of retinal features by fundus photography. *Graefes Arch Clin Exp Ophthalmol*. 1994;32:361–367.
- Sampson DM, Gong P, An D, et al. Axial length variation impacts on superficial retinal vessel density and foveal avascular zone area measurements using optical coherence tomography angiography. *Invest Ophthalmol Vis Sci*. 2017;58:3065–3072.
- Zhang Q, Zheng F, Motulsky EH, et al. A novel strategy for quantifying choriocapillaris flow voids using swept-source OCT angiography. *Invest Ophthalmol Vis Sci*. 2018;59:203–211.
- Spaide RF. Choriocapillaris flow features follow a power law distribution: implications for characterization and mechanisms of disease progression. *Am J Ophthalmol*. 2016;170:58–67.
- Ra E, Ito Y, Kawano K, et al. Regeneration of photoreceptor outer segments after scleral buckling surgery for rhegmatogenous retinal detachment. *Am J Ophthalmol*. 2017;177:17–26.
- Menke MN, Kowal JH, Dufour P, et al. Retinal layer measurements after successful macula-off retinal detachment repair using optical coherence tomography. *Invest Ophthalmol Vis Sci*. 2014;55:6575–6579.
- Faude F, Francke M, Makarov F, et al. Experimental retinal detachment causes widespread and multilayered degeneration in rabbit retina. *J Neurocytol*. 2002;30:379–390.
- Guerin CJ, Lewis GP, Fisher SK, Anderson DH. Recovery of photoreceptor outer segment length and analysis of membrane assembly rates in regenerating primate photoreceptor outer segments. *Invest Ophthalmol Vis Sci*. 1993;34:175–183.
- Sato T, Kanai M, Busch C, Wakabayashi T. Foveal avascular zone area after macula-off rhegmatogenous retinal detachment repair: an optical coherence tomography angiography study. *Graefes Arch Clin Exp Ophthalmol*. 2017;255:2071.
- Ryan SJ. *Retina*. 4th ed. Philadelphia, USA: Elsevier; 2006.
- Saito M, Saito W, Hashimoto Y, et al. Correlation between decreased choroidal blood flow velocity and the pathogenesis of acute zonal occult outer retinopathy. *Clin Exp Ophthalmol*. 2014;42:139–150.
- Hashimoto Y, Saito W, Saito M, et al. Decreased choroidal blood flow velocity in the pathogenesis of multiple evanescent white dot syndrome. *Graefes Arch Clin Exp Ophthalmol*. 2015;253:1457–1464.
- Dodo Y, Suzuma K, Ishihara K, et al. Clinical relevance of reduced decorrelation signals in the diabetic inner choroid on optical coherence tomography angiography. *Sci Rep*. 2017;7:5227.
- Ricker LJ, Kijlstra A, Kessels AG, et al. Interleukin and growth factor levels in subretinal fluid in rhegmatogenous retinal detachment: a case-control study. *PLoS One*. 2011;6:e19141.
- Bakunowicz-Łazarczyk A, Sulkowski S, Moniuszko T. Comparative studies of morphological changes and interleukin concentration in subretinal fluid of patients with retinal detachment. *Ophthalmologica*. 1999;213:25–29.
- Josifovska N, Lumi X, Szatmari-Tóth M, et al. Clinical and molecular markers in retinal detachment—from hyper-reflective points to stem cells and inflammation. *PLoS One*. 2019;14:e0217548.
- Kirchhof B, Kirchhof E, Ryan S, et al. Macrophage modulation of retinal pigment epithelial cell migration and proliferation. *Graefes Arch Clin Exp Ophthalmol*. 1989;27:60–66.
- Roldán-Pallarès M, Sadiq-Musa A, Rollin R, et al. Retinal detachment: visual acuity and subretinal immunoreactive endothelin-1. *J Fr Ophthalmol*. 2008;31:36–41.
- Roldán-Pallarès M, Musa A-S, Bravo-Llatas C, Fernández-Durango R. Preoperative duration of retinal detachment and

- subretinal immunoreactive endothelin-1: repercussion on logarithmic visual acuity. *Graefes Arch Clin Exp Ophthalmol*. 2010;248:21–30.
32. Wang H, Xu X, Sun X, Ma Y, Sun T. Macular perfusion changes assessed with optical coherence tomography angiography after vitrectomy for rhegmatogenous retinal detachment. *Graefes Arch Clin Exp Ophthalmol*. 2019;257:733–740.
33. Dell’Omo R, Viggiano D, Giorgio D, et al. Restoration of foveal thickness and architecture after macula-off retinal detachment repair. *Invest Ophthalmol Vis Sci*. 2015;56:1040–1050.
34. Munk MR, Giannakaki-Zimmermann H, Berger L, et al. OCT-angiography: a qualitative and quantitative comparison of 4 OCT-A devices. *PLoS One*. 2017;12:e0177059.