

Neutralizing Peripheral Refraction Eliminates Refractive Scotomata in Tilted Disc Syndrome

Jack Phu, MPH, BOptom, FAAO,^{1,2*} Henrietta Wang, BOptom, BSc,^{1,2} Sephora Miao, BOptom, BSc,² Lydia Zhou, BOptom, BSc,² Sieu K. Khuu, PhD, BSc,² and Michael Kalloniatis, PhD, MScOptom, FAAO^{1,2}

SIGNIFICANCE: We demonstrate that the visual field defects in patients with tilted disc syndrome can be reduced or eliminated by neutralizing the peripheral scotoma in the area of posterior retinal bowing, which may allow differentiation between a congenital anomaly and acquired pathology.

PURPOSE: Tilted disc syndrome is a congenital and unchanging condition that may present with visual field defects mimicking loss seen in neurological diseases, such as transsynaptic retrograde degeneration. Our purpose was to systematically investigate the ability of a neutralized peripheral refraction to eliminate refractive visual field defects seen in tilted disc syndrome. This was compared with the same technique performed on patients with neurological deficits.

METHODS: The Humphrey Field Analyzer was used to measure sensitivities across the 30-2 test grid in 14 patients with tilted disc syndrome using four refractive corrections: habitual near correction and with an additional -1.00 , -2.00 or -3.00 D negative lens added as correction lenses. Peripheral refractive errors along the horizontal meridian were determined using peripheral retinoscopy and thus allowed calculation of residual peripheral refraction with different levels of refractive correction. Visual field defects were assessed qualitatively and quantitatively using sensitivities and probability scores in both patient groups.

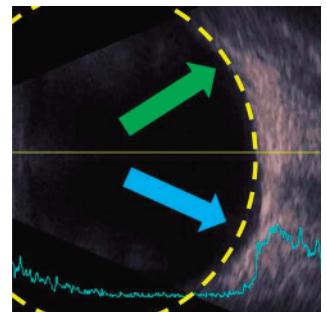
RESULTS: A smaller residual refractive error after the application of negative addition lenses correlated with improvement in visual field defects in terms of sensitivity and probability scores in patients with tilted disc syndrome. Patients with established neurological deficits (retrograde degeneration) showed improvement in sensitivities but not in probability scores.

CONCLUSIONS: Neutralizing the refractive error at the region of posterior retinal bowing due to tilted disc syndrome reduces the apparent visual field defect. This may be a useful and rapid test to help differentiate between tilted disc syndrome and other pathological causes of visual field defects such as neurological deficits.

Optom Vis Sci 2018;00:00–00. doi:10.1097/OPX.0000000000001286

Copyright © 2018 The Author(s). Published by Wolters Kluwer Health, Inc. on behalf of the American Academy of Optometry. This is an open-access article distributed under the terms of the Creative Commons Attribution-Non Commercial-No Derivatives License 4.0 (CCBY-NC-ND), where it is permissible to download and share the work provided it is properly cited. The work cannot be changed in any way or used commercially without permission from the journal.

OPEN



Author Affiliations:

¹Centre for Eye Health, University of New South Wales, Kensington, New South Wales, Australia

²School of Optometry and Vision Science, University of New South Wales, Kensington, New South Wales, Australia
*jphu@cfeh.com.au

Congenital tilted disc syndrome is a benign physiological anomaly commonly seen in clinical practice.¹ Although the exact definition of tilted discs is not consistent across current literature,^{2–4} tilted disc syndrome represents a constellation of clinical features that characterize this anomaly, including tilt (or oblique insertion) of the optic nerve and situs inversus of the blood vessels exiting the disc, with or without visual field defects corresponding to the region of fundus ectasia.¹

Tilted disc syndrome is thought to arise from a defect at the closure of the embryonic fissure, a theory that is supported by the most common location of ectasia, the inferonasal location.^{5,6} The relative myopic defocus in the region of fundus ectasia then leads to a visual field defect.⁷ Because of the position of the posterior bowing, the corresponding visual field defect is therefore most commonly located in the superotemporal field,^{3,8,9} although other defects such as arcuate scotomas and enlarged blind spots may be present. Because tilted disc syndrome is a commonly bilateral condition, this leads to the problem of potentially symmetrical visual field defects that can mimic functional losses occurring in pathologies such as retinal, optic nerve, and neurological disease.^{10–12} It is clinically important to be able to

distinguish between visual field defects that are due to a benign congenital anomaly and those that are attributable to disease.

Previous studies have reported that improvements in visual field sensitivity can be achieved in perimetry when using a negative addition lens. The theoretical framework is shown in Fig. 1, in which the negative addition lens diverges rays of light to focus more appropriately on the posteriorly bowed, but otherwise healthy retina. One study found improvement in the extent of the visual field measured using kinetic perimetry when using negative addition lenses in patients with tilted disc syndrome.¹³ More recently, we reported an empirical case of improvement in visual field sensitivity when measured using standard automated perimetry in a patient with tilted disc syndrome when using a fixed -3 D negative addition lens.¹² However, studies have not determined the quantitative relationship between the extent of fundus ectasia and visual field defect, nor do there exist any guidelines as to the optimal negative addition lens for reducing or eliminating the visual field defect.

In the present study, we systematically examined the role of negative addition lenses in eliminating the scotomata seen in patients with tilted disc syndrome in the region of fundus ectasia.

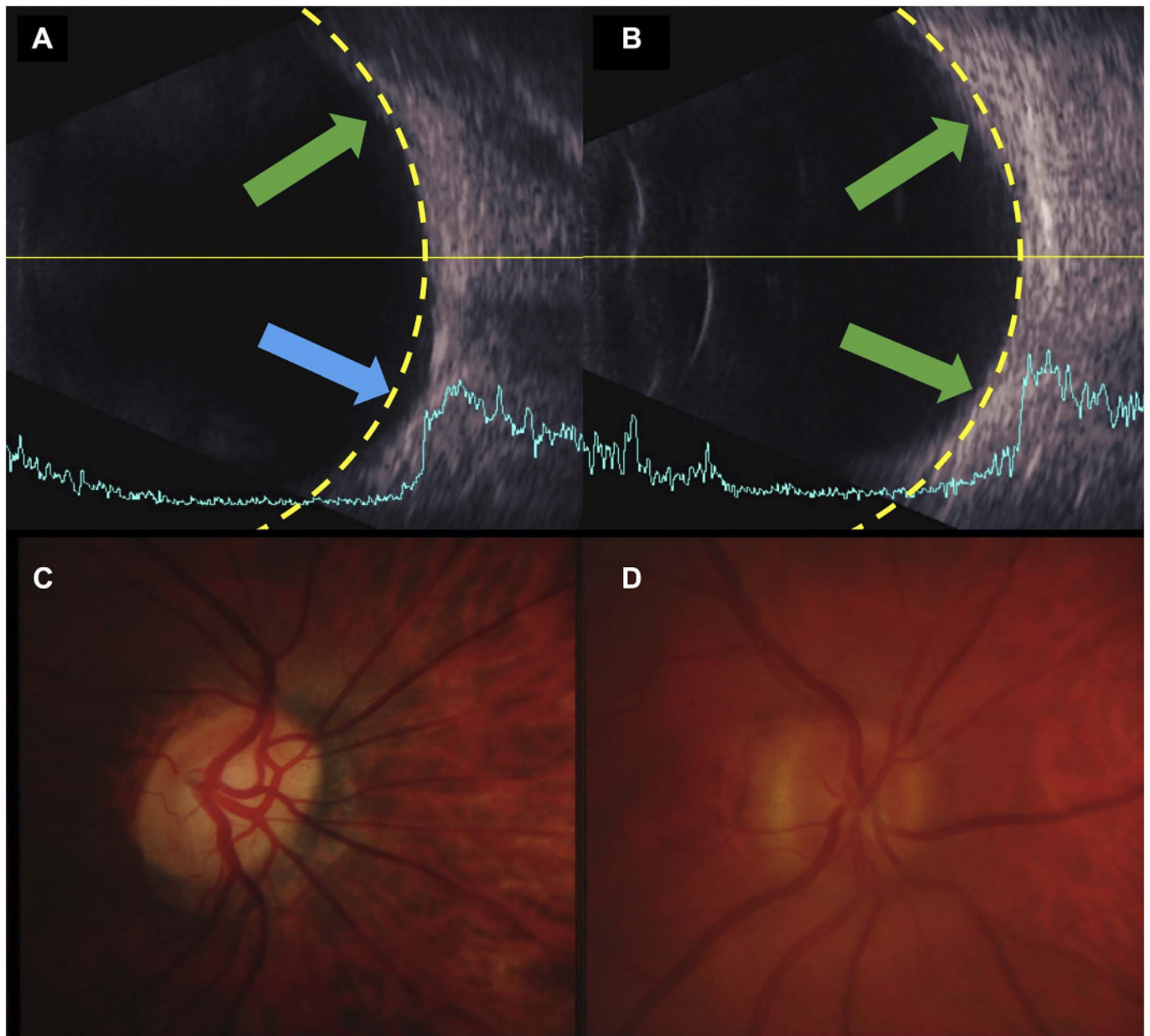


FIGURE 1. Theoretical framework behind the use of a negative addition lens in tilted disc syndrome. The yellow dashed lines indicate a circular arc. In (A), a patient with tilted disc syndrome has posterior bowing of the retina (blue arrow). A negative addition lens can focus rays of light more appropriately at the region of posterior retinal bowing by diverging rays of light. A patient with generally regular retinal curvature is shown in (B). The green arrows indicate regions with near normal curvature and/or slight anterior shift (relative hyperopic defocus). The fundus photographs of the corresponding representative patients are shown directly below. In (C), the optic nerve head displays tilt and torsion, with situs inversus of the adjacent retinal blood vessels typical of tilted disc syndrome. In (D), the optic nerve head is fairly oval in appearance, without tilt or torsion.

We hypothesized that the scotomata is refractive in origin, owing to the relative myopic defocus, and therefore, there exists an optimal level of refractive correction that can eliminate it. In this exploratory proof-of-concept study, we determined the relative peripheral refraction in patients diagnosed with benign tilted disc syndrome and then correlated this with visual field sensitivities measured using standard automated perimetry in conjunction with different levels of negative addition lenses. Quantification of the changes in visual field status would be desirable to correlate with the qualitative alterations seen in practice and the structural changes in the

ocular examination. We also tested a small number of patients with true pathologic visual field loss arising from neurological insults (at the chiasm or in higher cortical areas) leading to the epiphenomenon of transsynaptic retrograde degeneration.¹⁴ The prediction was that patients with true visual field defects due to pathology would show no improvement with negative addition lenses. The overall hypothesis of the study was that neutralizing the relative peripheral refraction in patients with tilted disc syndrome, but not in patients with retrograde degeneration due to a neurological insult, would eliminate the refractive scotoma.

METHODS

Participants

Fourteen patients with tilted disc syndrome and four patients with neurological deficits along the visual pathway resulting in subsequent retrograde degeneration were prospectively recruited for the study (Table 1). Suitable patients were identified from the medical records of patients seen at the Centre for Eye Health (University of New South Wales). All patients had undergone prior extensive ophthalmic testing at Centre for Eye Health, which included visual acuity, standard automated perimetry (using the Humphrey Field Analyzer; Carl Zeiss Meditec, Dublin, CA), applanation tonometry, gonioscopy, dilated fundus examination, color fundus photography (Kowa nonmyd 7; Kowa Medical, Sendai, Japan), and advanced imaging of the optic nerve head and macula (optical coherence tomography with Cirrus HD-OCT; Carl Zeiss Meditec). Aside from the relevant criteria used for the diagnoses of interest (tilted disc syndrome and neurological deficits; see subsections hereafter), other general inclusion criteria included age older than 18 years, visual acuity of 20/30 or better in the tested eye, no diabetes, no significant cataracts (Lens Opacity Classification System $>1^{15}$) or other media opacities affecting the visual field, and the ability to undertake reliable visual field testing. Other exclusion criteria included previous ocular surgery (aside from routine uneventful cataract surgery) or injury and other ocular or neurological diseases that affect the visual field (e.g., glaucoma, except for the patients with neurological deficits resulting in retrograde degeneration in that group). A previous study by Anderson et al¹⁶ has extensively documented the effects of dioptric blur on the visual field sensitivities in normal participants. Ethics approval was given by the Human Research Ethics Committee at the University of New South Wales, and the experiment followed the tenets of the Declaration of Helsinki. All patients gave their written informed consent before participation in the study.

Patients with Tilted Disc Syndrome

Criteria for a diagnosis of tilted disc syndrome for inclusion in the present study included tilt of the optic nerve head (defined as a difference between the maximum and minimum surface elevation of the disc; clinically, the ovality index was used, and in this study, it was required to be ≤ 0.75 for tilted disc syndrome²), situs inversus of the major retinal vessels exiting the disc, posterior bowing of the retina in a region surrounding the optic nerve head (confirmed using ultrasound biomicroscopy and optical coherence tomography), and visual field defects correlating to the disc and fundus appearance. The diagnosis of tilted disc syndrome was agreed upon by three independent Centre for Eye Health clinicians who were all experienced with ocular imaging. These participants

either had unilateral or bilateral tilted disc syndrome. For participants with bilateral tilted disc syndrome, one eye was randomly selected for testing. For participants with unilateral tilted disc syndrome, data were collected for the eye with tilted disc syndrome. In total, 14 suitable patients were identified and were prospectively tested.

Patients with Neurological Deficits

Patients within the neurological deficits group had structural and functional loss solely attributable to the anomaly along the visual pathway (confirmed with neuroimaging: computed axial tomography or magnetic resonance imaging) and not owing to other ocular pathologies or anomalies (e.g., tilted disc syndrome or glaucoma). Patients within this group included one patient with a compression lesion at the chiasm and three patients with insults beyond the chiasm. These patients all had characteristic structural losses visible on optical coherence tomography and corresponding functional losses apparent on standard automated perimetry. Four suitable patients with retrograde degeneration were identified and prospectively examined. Note that, for two participants, their fundus photographs and optical coherence tomography results have been reported, in part, by Zangerl et al.¹⁴ The characteristics of patients from both groups are shown in Table 1, including baseline Humphrey Field Analyzer mean deviation and pattern standard deviation scores.

Visual Field Testing

The Humphrey Field Analyzer was used to measure sensitivities at 75 locations (including the fovea and excluding the two points adjacent to the physiological blind spot) across the 30-2 test grid using standard parameters (an achromatic Goldmann size III target presented for 200 milliseconds). The SITA-Standard thresholding algorithm was used in this study to reflect the typical procedures used in clinical practice.¹⁷ Furthermore, the 30-2 test grid was used to obtain measurements of visual field sensitivity that were symmetrical about the vertical midline.¹⁸

Four different refractive corrections were used for each patient. The first refractive correction was the patient's normal near correction, inclusive of an age-normal near addition (beginning with a +1.00 D addition lens for subjects 30 to 39 years old), as recommended by the Humphrey Field Analyzer. The other three conditions were the normal near correction plus negative addition lenses of -1.00 , -2.00 , and -3.00 D on top. Testing was performed at least twice with each refractive correction. Testing was performed with the fellow eye patched and with natural pupils. The order of testing with each refractive correction was randomized to minimize order effects and lens adaptation effects on the results (especially given that each condition was performed at least twice).

TABLE 1. Patient demographics

| | Tilted disc syndrome | Neurological deficits with retrograde degeneration |
|---|--------------------------------|--|
| | (n = 14) | (n = 4) |
| Age, mean (range) (y) | 54.3 (36–73) | 57.0 (41–74) |
| Sex (male/female) | 6:8 | 4:0 |
| Spherical equivalent refractive error, median (range) (D) | -3.31 (-6.75 to 0.00) | -0.25 (-0.75 to $+0.75$) |
| Humphrey Field Analyzer mean deviation, median (range) (dB) | -1.99 (-2.73 to -1.30) | -9.75 (-18.78 to -3.83) |
| Humphrey Field Analyzer pattern standard deviation, median (range) (dB) | 2.35 (2.12 – 3.11) | 14.50 (5.93 – 17.06) |

For each session, participants were given sufficient breaks between each test to prevent fatigue. All patients had had extensive prior experience with standard automated perimetry testing. Fixation loss rates and false-positive rates were used as reliability indices for determine whether the result was included for analysis (<20% required for both criteria). False-negatives were not part of the reliability criteria, as regions of the visual field with poor sensitivity may manifest as high false-negatives, not necessarily owing to poor reliability but because of greater uncertainty.

Analysis of Visual Field Results

Resultant sensitivity data (in dB) were extracted directly from the Humphrey Field Analyzer printout. Sensitivity data were averaged at each spatial location for analysis. These results were then correlated with peripheral refraction at different retinal eccentricities. As the individual's residual refractive errors were correlated with their own visual field sensitivity results, age correction was not performed.¹⁹

Because the refractive scotomata induced by tilted disc syndrome may have only small alterations in sensitivity results, we also examined the *P* scores at each spatial location. The *P* score is an empirically determined score assignment based on the level of statistical significance of the defect flagged by the pattern deviation map, especially in cases of only mildly reduced sensitivity and subtle patterns of loss or in patients in whom generalized depressions may threaten to mask focal patterns of pathological loss.²⁰ Such maps are commonly used in clinical practice as a means to determine patterns of statistically significant visual field anomalies.^{21,22} The Glaucoma Hemifield Test on the Humphrey Field Analyzer,²³ for example, uses these scores to determine the presence of hemifield asymmetries in terms of statistically significant visual field defects. The *P* scores used by the Glaucoma Hemifield Test also scale with the depth of defect (at $P < .01$ or $P < .005$, the pattern deviation result is multiplied by 10), but differences on the printout are indistinguishable; that is, they use the same key at that *P* level irrespective of the depth of defect. Therefore, unlike the work of Asman and Heijl,²³ we did not scale the *P* score. Instead, we used an ordinal scale in the present study to reflect the levels of defect severity as visually presented by the Humphrey Field Analyzer: $P < .05$ was given a *P* score of 1; $P < .02$, a score of 2; $P < .01$, a score of 3; and $P < .005$, a score of 4 (as a scaled score would likely result in the same problem with using sensitivity values). Therefore, a change of score of +1 between refractive conditions indicated an increase in probability of abnormality by one step on the Humphrey Field Analyzer probability scale. A change of -1 indicates a decrease in probability of abnormality. Again, modifications to the probability of abnormality are similar to conventional statistical analyses.²¹ Like sensitivity values, the *P* score was averaged at each spatial location. The overall goal of this approach was not only to avoid the effects of variability but also to determine the changes in statistical significance visible in typical clinical interpretation.

Censoring Visual Field Defects

Recently, there have been suggestions of censoring sensitivity data below 15 to 19 dB, as measurements at or below this level may be unreliable and therefore confound accurate analysis.^{24,25} Specifically, this may affect the fidelity of the change in sensitivity analysis described above. Thus, in the present study, we also performed the previous analyses (change in sensitivity and change in

P score) after censoring data points at which the baseline sensitivity level was 19 dB or less. We hypothesized that, owing to the typically mild nature of sensitivity reduction occurring in tilted disc syndrome, censoring data would have minimal impact upon the results when examining changes in sensitivity and *P* score in the tilted disc syndrome cohort. Instead, it may affect the results of the neurological deficit cohort by revealing trends in sensitivity or *P* score change masked by unreliable sensitivity data.

Selection of Visual Field Defect Locations for Analysis

Because the visual field defects in tilted disc syndrome and neurological deficits were expected to predominantly affect only one quadrant or one vertical hemifield, we analyzed points along the two rows immediately above and two rows below (3 and 9° vertical eccentricity) of the horizontal midline. Each datum point within these four lines was considered individually but was matched to retinoscopy results based on their position along the horizontal axis (i.e., 3, 9, 15, or 21° nasal and temporal). Note that, although the 30-2 test was used, the 27° eccentricity was not used for quantitative analysis with relative peripheral refraction owing to the physical limitations of the room and the poor reliability of the retinoscopy results (hereafter).

Peripheral Retinoscopy and Relative Peripheral Refraction

Peripheral refraction can be performed using a variety of techniques.²⁶ In the present study, we used peripheral retinoscopy (Welch Allyn Streak Retinoscope, Skaneateles Falls, NY) performed in free space in conjunction with a trial frame and wide aperture loose lenses by two trained clinicians independently for each patient to obtain the refractive errors at different horizontal eccentricities. The participant fixated on one of nine targets corresponding to test eccentricities along the horizontal meridian of the 30-2 Humphrey Field Analyzer test grid: 0 (primary gaze), 3, 9, 15, and 21° nasally and temporally (except for 15° temporally for each participant, which corresponds to the approximate location of the physiological blind spot). Retinoscopy was performed with the examiner set up perpendicularly to the participant, and the participant was instructed to keep their head in primary position. The setup for fixation targets was calculated trigonometrically using a distance of 2.8 m (~9.8 ft, similar to previous reports^{27,28}) between the patient and the display. The angular subtense at the patient's eye in primary gaze was used to calculate the distance between each fixation target (black circle ~20/200 in size). Agreement between the two clinicians performing retinoscopy was within 0.25 D. Retinoscopy was performed at a working distance of approximately 60 cm (~2 ft) with a fogging lens of 1.50 D. Attention was focused on the distant targets with regular movements between targets to maintain constant attention.

Relative peripheral refraction was determined by taking the difference between the absolute refraction at the peripheral test location and the absolute refraction in primary gaze (0°). For example, a 3° nasal absolute refraction of -3.00 D is 2.00 D relatively more myopic compared with a foveal absolute refraction of -1.00 D; therefore, the relative peripheral refraction would be -2.00 D.

Finally, we calculated the residual relative peripheral refraction at each location. As the trial lens effectively aims to neutralize the refraction at 0°, there may be residual relatively peripheral refractions that differ at various retinal eccentricities. Using the previous

example where the relative peripheral refraction is -2.00 D, a negative addition lens of -1.00 D on top of the typical refractive correction (which has already neutralized the refraction at 0°) would result in a residual refraction of -1.00 D (-2.00 to -1.00 D = -1.00 D). A negative addition lens of -3.00 D would result in a residual refraction of $+1.00$ D, that is, residual relative peripheral hyperopia.

Statistical Analysis

Statistical analysis was carried using GraphPad Prism version 7 (GraphPad Prism, La Jolla, CA). Each datum point along the horizontal axis (i.e., the four points, 3 and 9° superior and inferior to the horizontal midline) was considered a separate sample, but each eccentricity was matched with the corresponding retinoscopy result along the horizontal axis (i.e., 3, 9, 15, or 21° nasal and temporal). Changes in sensitivity and change in P score were plotted as a function of residual peripheral refraction, and from the linear regression analysis, we extracted slope and y intercept data. Although P score is ordinal data in which the actual probability value differences are unequal, the changes occur discretely in a clinical setting based on the instrument printout (progressively darker from no shading to black). Thus, we used this analysis to determine the point at which a meaningful change in P score could be obtained in an effort to correlate quantitative data with the qualitative presentation of results. The y intercept indicated the amount of change in sensitivity of P score when the residual refractive error was 0. A slope with a $P < .05$ was considered significantly different to 0, signifying an effect of residual peripheral refraction.

RESULTS

Qualitative Analysis

One common method of analyzing visual field results is the determination of patterns of defects.²⁹ Typically, defects are given descriptors to help localize the site of structural loss. The grayscale, total deviation, and pattern deviation maps are typically used in combination. Thus, the first step of the analysis was a comparison of pattern deviation maps.

The visual field results of a representative patient with tilted disc syndrome and a representative patient with a neurological deficit and resultant retrograde degeneration are shown in Fig. 2 for each of the refractive conditions used. The baseline visual field results of both patients have significant defects respecting the vertical midline, both suggestive of a lesion along the visual pathway beyond the retina. With increasing negative addition lens power, the scotoma in the patient with tilted disc syndrome is reduced. In the patient with a neurological deficit, no significant change in the pattern or depth of defect is seen.

As an adjunct to this analysis, we also counted the number of statistically significant *defects* (a sensitivity result below the 95% normative distribution [$P < .05$] as seen on the Humphrey Field Analyzer pattern deviation map) for each observer and compared this number across the different refractive conditions. There was a tendency toward fewer defects with negative addition lenses in the tilted disc syndrome group compared with baseline (median [interquartile range] defects, 13 [9.25 to 20]) when comparing -1 D (10 [8.3 to 15.5], $P = .009$) but not with -2 D (10.5 [6.5 to 17.5], $P = .28$) or with -3 D (9.5 [8 to 19.3], $P = .33$). Correspondingly, there appeared to be no clear

systematic effect of changing lens power (Friedman test, $H(4) = 2.364$; $P = .5003$). In comparison, there were effects of the negative addition lenses on number of events for all cases of patients with a neurological deficit ($P > .9999$ for all combinations).

Quantitative Analysis — Eccentricity-dependent Effect

We then examined the amount of visual field sensitivity change as a function of retinal eccentricity for each of the different levels of negative addition lens. The hypothesis here is that there is an eccentricity-dependent effect, whereby the effect of each negative addition lens upon visual field sensitivity varies at different retinal locations. Fig. 3 shows the result of visual field sensitivity change from baseline as a function of retinal eccentricity for each negative addition lens correction. For the representative patient with tilted disc syndrome, there were locations that had clear and significant improvement in visual field sensitivity and areas with obvious visual field worsening. The areas of improvement were predicted from the qualitative analysis: the relative posterior retinal bowing at the nasal aspect correlates to the temporal defect in the visual field in the patient with tilted disc syndrome (Fig. 3A). The worsening of visual field sensitivity was also expected from the increased refractive error in areas without posterior bowing. There were also changes in sensitivity in patients with a neurological deficit, but this was more variable and had no consistent pattern (Fig. 3B). One likely reason for the variability is the relatively low sensitivity measurements in patients with deep defects: sensitivities below 15 to 19 dB on static perimetry are unreliable and highly variable.²⁴

Quantitative Analysis — Sensitivity versus Residual Refractive Error

Although the eccentricity-dependent effect is clear and is reflective of changes in retinal curvature, it provides no guidance about the optimal refractive correction for each specific location to minimize the visual field defect. Thus, the change in sensitivity was plotted as a function of residual refractive error (Fig. 4). A positive residual refractive error indicates relative hyperopia, and this was by far the most common outcome following the addition of the negative addition lens. For the analysis, we also divided the points into those with defects and nondefects. In patients with tilted disc syndrome, linear regression analysis showed an effect of relative hyperopia on sensitivity for both defects ($y = -0.3038x + 0.4527$, $P = .001$, $R^2 = 0.07$) and nondefects ($y = -0.2323x - 0.5881$, $P = .009$, $R^2 = 0.03$) (Fig. 4A). However, there was no effect of relative myopia, and this was possibly owing to the small sample size in this area (events, $y = -0.0478x + 0.5867$, $P = .83$, $R^2 = 0.002$; nonevents, $y = -0.226x - 1.419$, $P = .26$, $R^2 = 0.01$). There was a statistically significant effect of relative hyperopia on defects ($y = -1.005x + 2.964$, $P = .001$, $R^2 = 0.1802$) and non-defects ($y = -1.174x + 1.743$, $P = .001$, $R^2 = 0.1735$) in patients with a neurological deficit (Fig. 4B). These results were minimally changed when censoring data below 19 dB for patients with tilted disc syndrome (Fig. 4C) and patients with a neurological deficit (Fig. 4D) (equations not shown for clarity).

Correcting relative peripheral refractive error in patients with tilted disc syndrome seemed to result in improved sensitivities, with worsening sensitivity with increasing refractive error. However, the y -intercept of these linear regression analyses suggested an

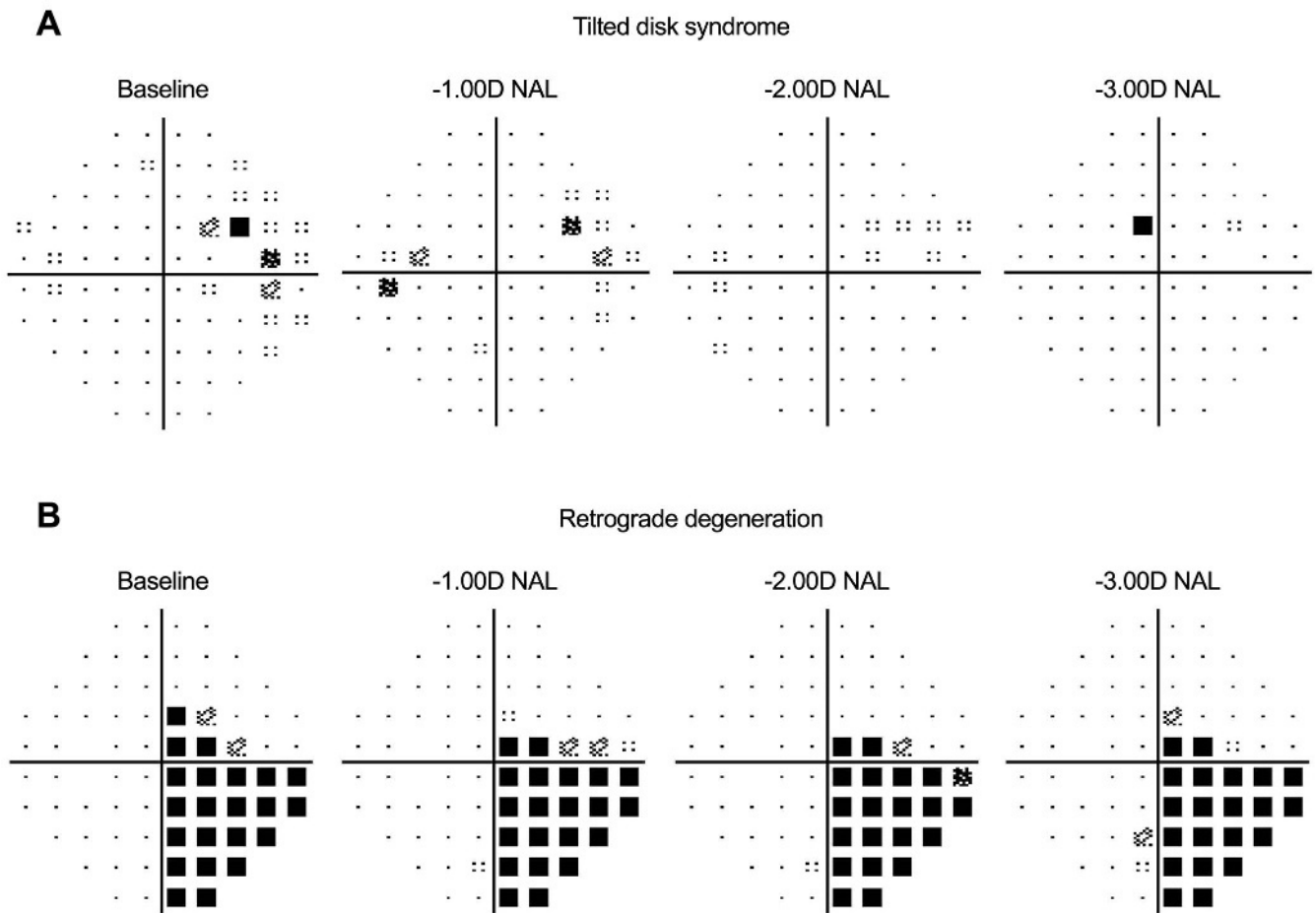


FIGURE 2. (A) Visual field results for a patient with tilted disc syndrome. Baseline visual field results show a cluster of visual field depressions primarily located temporally around the blind spot. Sequential negative addition lenses (–1.00, –2.00, and –3.00 D NAL) reduce the significance of the defects. (B) Visual field results for a patient with retrograde degeneration due to a neurological deficit. Baseline visual field shows a primarily inferotemporal quadrantanopia. Note the presence of defects that were flagged by the Humphrey Field Analyzer as highly significant ($P < .005$). Use of negative addition lenses did not appear to change the appearance of the visual field defect.

improvement of only 0.45 dB; that is, when residual refractive error is 0, there is only a small improvement in sensitivity. This therefore does not explain the improvement seen on qualitative analysis, such as in Fig. 2. Similarly, the apparent improvement in sensitivity with lower residual refractive error in patients with a neurological deficit also appears discordant with the results seen in Fig. 2.

Quantitative Analysis — P Score versus Residual Refractive Error

The problem with analyzing sensitivity as a function of refractive error is the magnitude of possible change: previous studies have shown that, particularly within the central visual field testing region, declines in sensitivity are small when the amount of introduced refractive error is small.^{16,20} Therefore, we analyzed the results according to the P score, which is reflective of the clinical interpretation of common maps within the printout. Unlike the work of Asman and Heijl,²³ we used an ordinal stepwise system of P score change, as described in Methods. This prevents complications from deep defects, which are affected by small changes in

the underlying sensitivity result (each dB of change at levels of $P < .001$ changes the P score of Asman and Heijl²³ by 10).²⁰

Fig. 5 shows the change in P score as a function of residual refractive error. A positive P score change indicates a reduced probability of abnormality; that is, the statistical significance of the defect has been reduced, and thus, the location has become more normal. Once again, there was a significant effect of relative hyperopia on P score for events ($y = -0.2089x + 1.131$, $P < .0001$, $R^2 = 0.14$). This time, there was also an effect of relative myopia for defects ($y = 0.3098x + 1.032$, $P = .01$, $R^2 = 0.22$) in patients with tilted disc syndrome (Fig. 5A). Both of these y intercepts were approximately equal to 1, indicating a one-step change in P score on the pattern deviation map. This is clinically significant, as a change here can visually eliminate the presence of a significant scotoma, for example, changing from a dark tone to a lighter or no tone. Unlike in the sensitivity-based analysis, there was no effect of relative hyperopia ($y = -0.03137x - 0.1109$, $P = .09$) or relative myopia ($y = 0.010x - 0.018$, $P = .58$) on P score at nondefect locations in patients with tilted disc syndrome, which would be consistent with no change in pattern, or, more

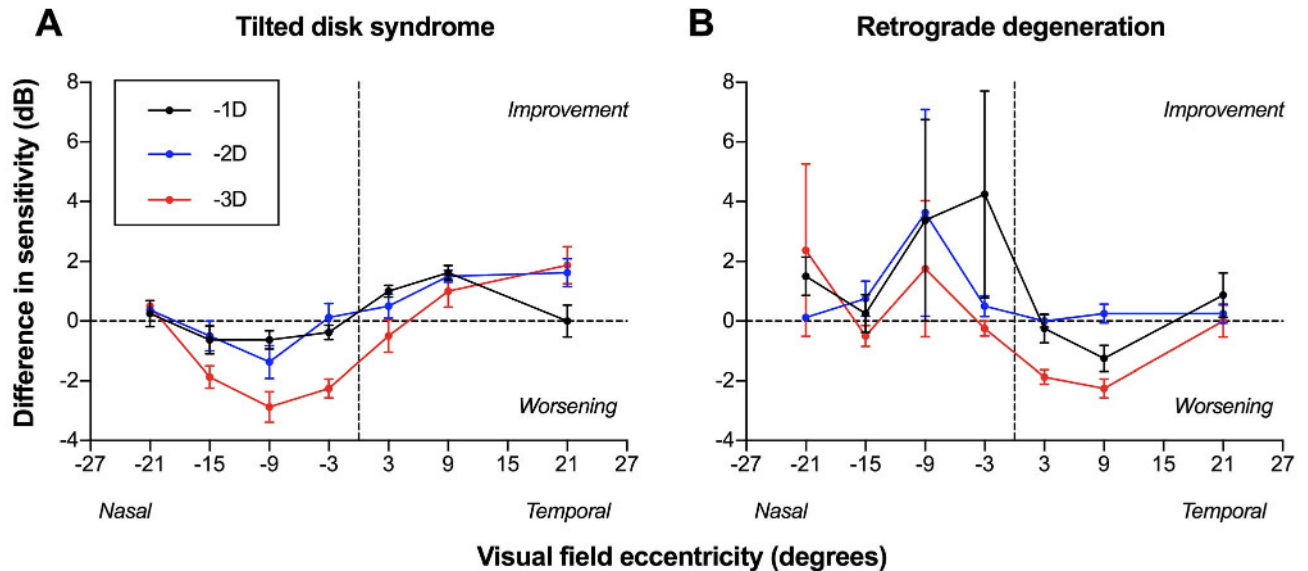


FIGURE 3. Difference in sensitivity (dB) as a function of visual field eccentricity ($^{\circ}$) for a patient with tilted disc syndrome (A) and a patient with a neurological deficit and retrograde degeneration (B). A positive difference in sensitivity indicated improvement, and a negative difference indicated worsening. A positive visual field eccentricity was considered temporal, and negative eccentricity was considered nasal. Each color denotes a different negative addition lens. Datum points indicate mean, and the error bars indicate 1 standard error of the mean.

importantly, improvement, in areas without a refractive scotoma at baseline. Similarly, there was no effect of residual refractive error on the P score of patients with a neurological deficit (Fig. 5B). The majority of points with a P score change of 0 are consistent with no change in pattern or depth of defect in a situation with true pathological loss. Again, there was no effect of censoring locations at which the baseline sensitivity value was 19 dB or less for both patients with tilted disc syndrome (Fig. 5C) and patients with a neurological deficit (Fig. 5D).

DISCUSSION

In the present study, we tested the hypothesis that neutralizing the relative peripheral refraction in patients with tilted disc syndrome can reduce or eliminate the refractive scotoma in the region of fundus ectasia. In addition to showing qualitative improvement in visual field results in tilted disc syndrome, our results also demonstrated a systematic quantifiable effect of relative peripheral refraction, whereby a residual refraction of 0 provided the greatest amount of sensitivity and P score improvement. As expected, we also found no significant improvement when testing patients with retrograde degeneration due to an underlying neurological deficit.

Small Sensitivity Improvements Are More Clearly Identified Using P Scores

The difference between using sensitivity and P scores in identifying the optimum level of residual refractive error for visual field improvement could be explained by the overall depth of visual field defect in patients with tilted disc syndrome. The negligible effect seen when using sensitivity as an index for improvement was most likely due to the shallow visual field defects in patients with tilted disc syndrome at baseline. This also accounts for the fact that

minimal difference was seen when censoring points with deep defects. Although statistically significant, the refractive scotomata may be relatively shallow, as per the work of Anderson et al.¹⁶ and as seen in the relatively low mean deviation scores.

Instead, using the P score index offers numerous advantages for data analysis in this situation. First, it provides a clinically meaningful and immediate visual cue to visual field improvement. The pattern deviation map on the Humphrey Field Analyzer (and analogous maps on other perimeters) is used in a range of grading and diagnostic matrices for determining disease.³⁰ The advantage of using pattern deviation map, as opposed to sensitivities, is that it accounts for the shape of the hill of vision, and thus, localized patterns of loss can be identified.³¹ Second, as a corollary to the use of the pattern deviation map, point-wise analysis of statistical significance is able to determine if changes in sensitivity at discrete locations are meaningful, especially given the potentially widespread visual field involvement common in tilted disc syndrome.^{8,9} Conversely, identifying statistically significant changes does not falsely highlight apparently large improvements or worsening in patients with true pathology, as the depth of defect is more likely to maintain the same level of statistical significance. As sensitivity loss increases, factors such as uncertainty and biases have been recently alluded to as contributors toward an increase in variability in sensitivity measurements³² (also see Turpin A, et al. IOVS 2018;59:E-Abstract 5129). Clinically, this has been shown to manifest as an increase in false-negative results.³³ Recent studies have even suggested that standard automated perimetry sensitivity measurements below 15 to 19 dB may be unreliable and have raised the possibility of even masking these results to improve the validity of visual field measurements.³⁴ Thus, it is expected that deep visual field defects in regions of pathological loss, such as in retrograde degeneration due to a neurological insult, would have poor repeatability and show significant fluctuations in sensitivity

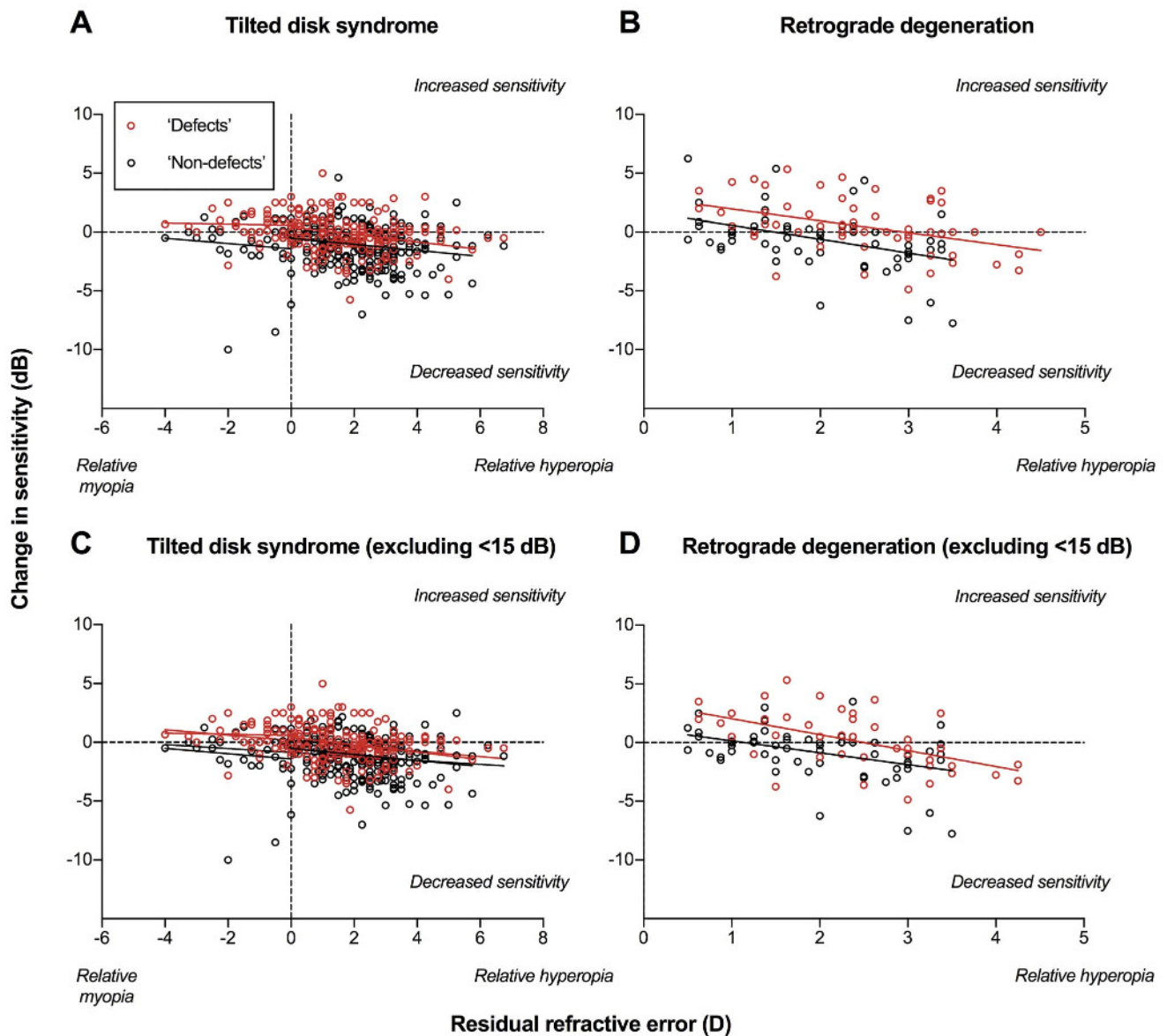


FIGURE 4. Change in sensitivity (dB) as a function of residual refractive error (D) for patients with tilted disc syndrome (A) and retrograde degeneration due to a neurological deficit (B). A positive change in sensitivity indicates improvement in sensitivity, and a negative change indicates worsening. A positive residual refractive error indicates relative hyperopia, and a negative refractive error indicates myopia. Defects (locations with a baseline pattern deviation $P < .05$) are shown in red, and nondetails (all other points with a pattern deviation result of $P > .05$) are shown in black. Note that all patients with retrograde degeneration only exhibited relative hyperopia, so the x axis begins at 0. Each datum point represents an individual test location along the horizontal meridian (i.e., one point from the four lines about the midline). The solid lines indicate the linear regression results, analyzed separately for relative hyperopia and relative myopia. (C) and (D) represent the results of patients with tilted disc syndrome and retrograde degeneration as per (A) and (B), respectively, but with results with a baseline sensitivity of less than 19 dB excluded from analysis. Note the similarity between (A) and (C) owing to the small number of censored points.

measurements. Using P scores mitigates this, as it is unlikely that sensitivity fluctuations would result in a change in P score significant enough to resemble an improvement in the refractive scotoma in tilted disc syndrome. Indeed, the apparent sensitivity improvements seen in patients with tilted disc syndrome were quickly nullified when using the P score system, as this accounts for fluctuations in dB values in areas of severe deficit, as a range of 0 to 19 dB in some areas of the visual field may show no change in P score at all. Third, it can

effectively identify differences occurring in defects in contrast to “non-defects.” Again, small changes in tilted disc syndrome and large fluctuations occur in cases of defects due to neurological deficits that are clinically meaningful (statistically significant changes relative to the normative range) would be masked or inappropriately identified, respectively, if relying on sensitivity measurements. The use of P scores would assist in identifying clinically meaningful change. Therefore, this unique approach facilitates a quantitative method of

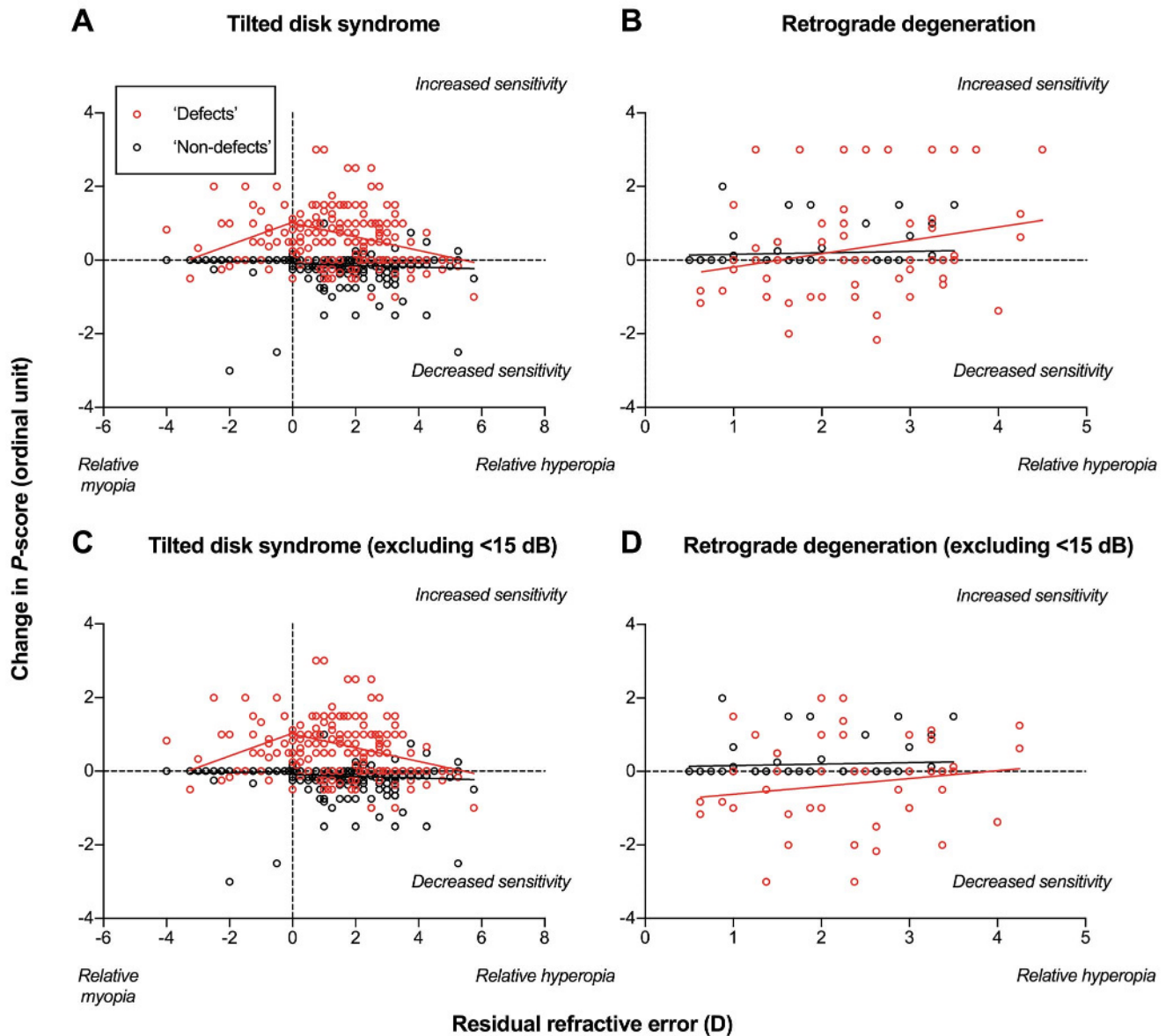


FIGURE 5. Individual differences in P score as a function of residual relative refraction (D), with color codes and x axis as per Fig. 4 (results for patients with tilted disc syndrome in (A) and patients with retrograde degeneration due to neurological deficits in (B)). A positive difference in P score indicates a decreased probability of abnormality on the Humphrey Field Analyzer deviation map (i.e., more normal), and a negative difference indicates an increased probability of abnormality (i.e., more abnormal). (C) and (D) represent the results of patients with tilted disc syndrome and retrograde degeneration as per (A) and (B), respectively, but with results with a baseline sensitivity of less than 19 dB excluded from analysis. Note the similarity between (A) and (C) owing to the small number of censored points.

examining visual field improvement that correlates better with the changes seen using traditional qualitative methods in comparison with comparisons in sensitivity alone.

Using Neurological Deficits as a Model to Compare Tilted Disc Syndrome

One reason why neurological deficits were used as a model for comparing the visual field change in tilted disc syndrome is because the visual field defects in tilted disc syndrome often resemble those occurring owing to anomalies of the higher visual pathway (at the chiasm or beyond). Our results appear to support the hypothesis that

improvement is possible in tilted disc syndrome but not in established retrograde degeneration. Here, another potential future study is in different stages of retrograde degeneration resulting from neurological insults. Structural and functional loss occurring due to neurological deficits may not occur concurrently, nor do they immediately manifest upon initial insult³⁵; time is an important factor in the damage process. A wider spectrum of disease would be informative to assess the ability of negative addition lenses to distinguish early clinical signs of retrograde degeneration due to neurological deficits from tilted disc syndrome.

Because the visual field defects in neurological deficits and tilted disc syndrome typically present in only one hemifield or

quadrant, this leaves additional nondefect points with which to examine the effect of relative peripheral refraction.^{1,14} Specifically, the nondefect points serve as a pseudo control to the defects: it is expected that locations at which there is no anatomical anomaly or pathology would exhibit similar behaviors to that of participants with no significant fundus ectasia. One potential confounding factor is the amount of central refractive error for each patient.

Is the Posterior Staphyloma Truly Just Refractive?

One of the fundamental assumptions of this work is that the visual field defect due to tilted disc syndrome is refractive in etiology, that is, a refractive scotoma that can be ameliorated using negative addition lenses. In comparison with other potential causes of posterior retinal bowing that may have loss of overlying neural and/or detector elements (e.g., retinal coloboma, posterior staphyloma due to pathological myopia), the retinal layers in tilted disc syndrome may still be intact enough to have visual field defects alterable by neutralizing the local refractive error. Fig. 6 contrasts the depth of visual field defect seen in the representative tilted disc syndrome and neurological deficit patients (from Fig. 1) and also an example patient with pathological myopia (−11.00 D). Although retrograde degeneration due to neurological insults and pathological myopia both show structural losses associated with pathology (e.g., thinning of the nerve fiber layer and ganglion cell layer, arrows), the area of posterior retinal bowing in tilted disc syndrome shows no such loss of neural tissue, only displacement. This provides further support for the use of negative addition lenses in differentially diagnosing tilted disc syndrome from other pathological conditions of the retina.

Previous studies have also suggested that the peripheral refraction may be driven, in part, by ocular parameters such as central refractive error and axial length, and thus, the central refractive error may be a confounding factor.^{36,37} Ethnicity may also play a small but significant role in relative peripheral refraction.³⁸ For this reason, we reported on the changes in visual field sensitivity and *P* scores as a function of residual relative peripheral refraction, rather than retinal eccentricity. Again, future studies with a range of refractive errors or fundus shapes would be informative.

Limitations

There were a number of limitations to this study. First, we used a simple technique (peripheral retinoscopy) to establish peripheral refractive error. The advantages of retinoscopy are numerous: it is generally repeatable in the skilled observer, it is accessible to clinicians, and it does not require highly specialized equipment.³⁹ We did not cycloplege the participants; repeatability of cycloplegic retinoscopy is poorer compared with noncycloplegic and worsens with measurements in the periphery owing to increased aberrations.⁴⁰ However, other techniques have been used in the literature for assessing peripheral refraction, including peripheral autorefraction,⁴¹ infrared scanning photoretinoscopy,⁴² and aberrometry measurements.⁴³ The typical step size used in refraction, 0.25 D, may account for some of the variability seen in the present results. However, this step size is the most practical, as smaller sizes may not be measureable or modifiable in clinical practice. Another way to potentially improve the relationship would be to incorporate cylindrical correction, rather than just best vision sphere. Four of 14 of the patients with tilted disc syndrome had oblique astigmatism (axis >15° from horizontal or vertical), and the remaining 10 patients with with-the-rule or against-

the-rule astigmatism had minimal changes in cylindrical refraction with retinal eccentricity (<0.50 D). Because astigmatism can also vary with retinal eccentricity with different levels of refractive error,⁴⁴ especially in cases of tilted disc syndrome, future study using more precise refractive corrections is warranted, as uncorrected cylinder could have masked further benefits to altering the peripheral refractive correction. Notably, the tilted disc syndrome cohort had higher refractive error compared with the neurological deficit group. This may have been a product of the unequal sizes but may also be owing to the greater preponderance of refractive errors in patients with tilted disc syndrome.¹ Again, this highlights the contribution of refraction on generate scotomata within the visual field. Furthermore, the role of peripheral aberrations was beyond the scope of the present study but may also be informative.

Second, we used the Humphrey Field Analyzer 30-2 test grid, which is typically recommended for assessment of suspected neurological deficits owing to its extent and symmetry. The point spacing of this grid is 6°, which is relatively coarse, unlike the 10-2 test grid.⁴⁵ Because the area of posterior retinal bowing may be small, the resolution of the test grid may not be sufficient to detect subtle changes in visual field sensitivity.

Third, because this was an exploratory study to establish the presence of an effect, the sample size of participants was overall small, and the range of test lenses was also restricted to three empirical levels. The reason for limiting it to −1.00, −2.00, and −3.00 D negative addition lenses was because of the potential distorting optical effects of higher refractive lenses for the majority of patients with small relative peripheral refractions.⁷ However, as seen in Figs. 3 and 4, there were patients in whom the residual refractive error was much higher at some test locations. We also included a small range of refractive errors. A recent study has suggested possible differences between highly myopic and non-highly myopic eyes with tilted discs.⁴⁶ Furthermore, we also combined presbyopes and nonpresbyopes (the youngest patient was 36 years old); in the latter group, the ability to accommodate may confound the visual field results using negative addition lenses, and hence, cycloplegia could be another consideration. A subgroup analysis was performed after dividing patients with tilted disc syndrome into two age groups: younger than 60 years (*n* = 8) and 60 years or older (*n* = 6). The effect of residual refractive error was unchanged in both groups when examining the change in sensitivity. Importantly, the effect of residual refractive error upon *P* scores was also unchanged: it was still significant at locations with defects for both the group 60 years or older and the group younger than 60 years and showed no effect at nondefect locations. The sample size for patients with neurological insults was too small for this subgroup analysis. Again, future studies could use this to specifically target regions of interest to further test our overarching hypothesis.

CONCLUSIONS

Our results demonstrate that negative addition lenses have the potential to improve visual field sensitivity in regions of posterior bowing in tilted disc syndrome, thereby offering a method for differentially diagnosing this condition from other pathological anomalies of the retina. This study provides a foundation for further research into optimizing optical correction for visual field testing.

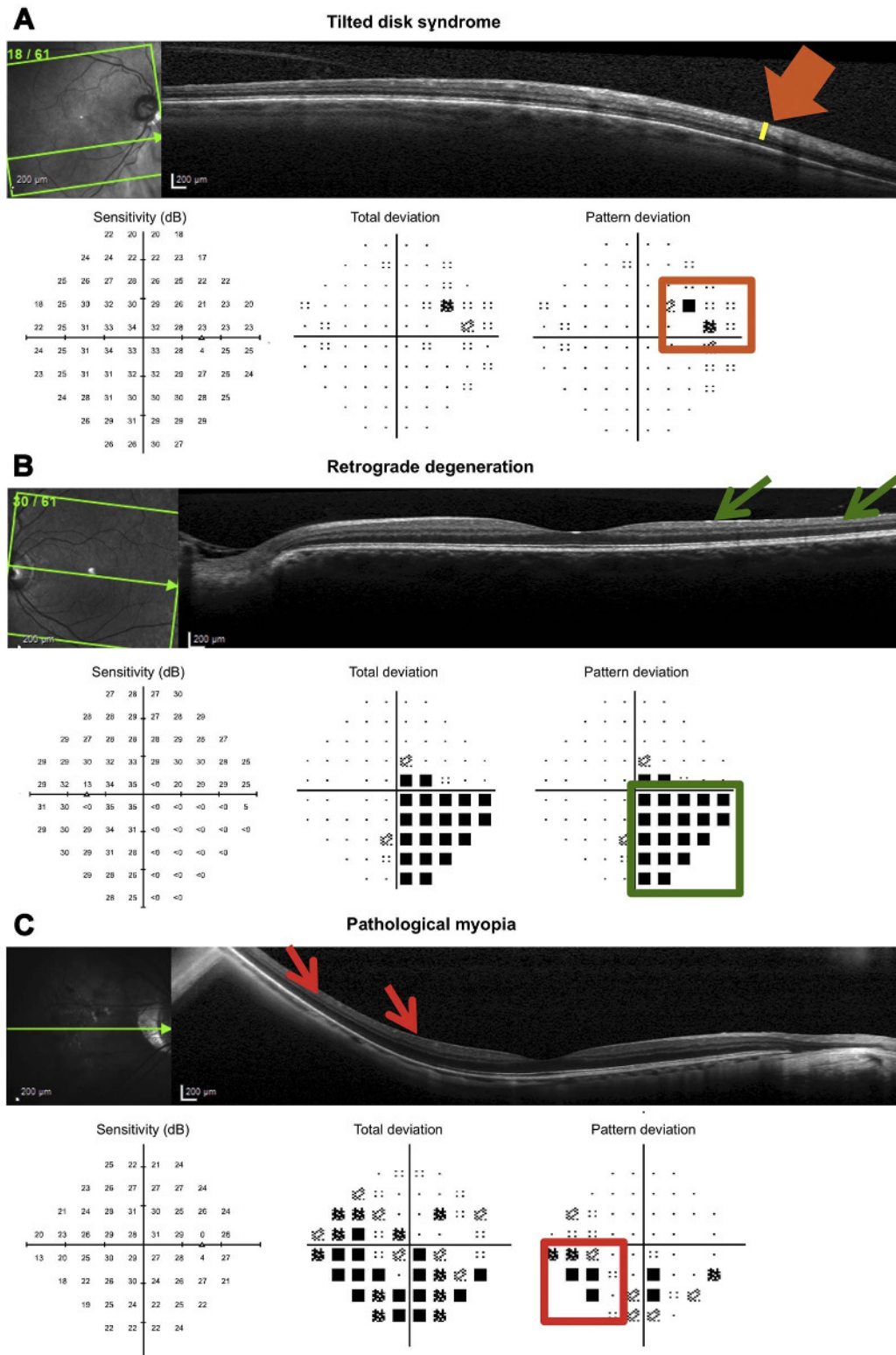


FIGURE 6. Spectralis optical coherence tomography results showing the structural correlate of visual field defects in three representative patients. In (A), the patient with tilted disc syndrome has clear posterior bowing with intact inner and outer retinal layers nasally (orange arrow), corresponding to the refractive scotoma in the temporal visual field (orange box). These defects tend to be shallow. In (B), the patient with a neurological deficit and manifest retrograde degeneration shows clear thinning of the inner retinal layers (retinal nerve fiber layer and ganglion cell layer, green arrows) temporal to the fovea corresponding the clear, deep inferonasal visual field defect (green box). In (C), a patient with pathological myopia (−11.00 D) has a posterior staphyloma within the central retina, with thinning of the inner retinal layers, similar to (B), temporal to the fovea (red arrows). This corresponds to the inferonasal visual field defect (red box), which appears deeper than the defect caused by posterior retinal bowing in tilted disc syndrome (A).

ARTICLE INFORMATION

Submitted: April 7, 2018

Accepted: June 19, 2018

Funding/Support: National Health and Medical Research Council (1033224; to MK).

Conflict of Interest Disclosure: None of the authors have reported a financial conflict of interest.

Author Contributions: Conceptualization: JP, HW, MK; Data Curation: JP, HW, SM, LZ, MK; Formal Analysis: JP; Funding Acquisition: MK; Investigation: JP, HW, SM, LZ; Methodology: JP, HW, SM; Project Administration: JP, SKK, MK; Resources: MK; Supervision: JP, SKK; Writing – Original Draft: JP; Writing – Review & Editing: HW, SKK, MK.

REFERENCES

- Witmer MT, Margo CE, Drucker M. Tilted Optic Disks. *Surv Ophthalmol* 2010;55:403–28.
- How AC, Tan GS, Chan YH, et al. Population Prevalence of Tilted and Torted Optic Discs among an Adult Chinese Population in Singapore: The Tanjong Pagar Study. *Arch Ophthalmol* 2009;127:894–9.
- Vongphanit J, Mitchell P, Wang JJ. Population Prevalence of Tilted Optic Disks and the Relationship of This Sign to Refractive Error. *Am J Ophthalmol* 2002;133:679–85.
- You QS, Xu L, Jonas JB. Tilted Optic Discs: The Beijing Eye Study. *Eye (Lond)* 2008;22:728–9.
- Apple DJ, Rabb MF, Walsh PM. Congenital Anomalies of the Optic Disc. *Surv Ophthalmol* 1982;27:3–41.
- Riise D. The Nasal Fundus Ectasia. *Acta Ophthalmol Suppl* 1975;3:108.
- Aung T, Foster PJ, Seah SK, et al. Automated Static Perimetry: The Influence of Myopia and Its Method of Correction. *Ophthalmology* 2001;108:290–5.
- Brazitikos PD, Safran AB, Simona F, et al. Threshold Perimetry in Tilted Disc Syndrome. *Arch Ophthalmol* 1990;108:1698–700.
- Gurlu VP, Alimgil ML, Benian O. Topographical Analysis of the Visual Field in Tilted Disc Syndrome. *Retina* 2002;22:366–8.
- Sowka J, Aoun P. Tilted Disc Syndrome. *Optom Vis Sci* 1999;76:618–23.
- Sowka JW, Luong VV. Bitemporal Visual Field Defects Mimicking Chiasmal Compression in Eyes with Tilted Disc Syndrome. *Optometry* 2009;80:232–42.
- Phu J, Khuu SK, Yapp M, et al. The Value of Visual Field Testing in the Era of Advanced Imaging: Clinical and Psychophysical Perspectives. *Clin Exp Optom* 2017;100:313–32.
- Vuori ML, Mantyjärvi M. Tilted Disc Syndrome May Mimic False Visual Field Deterioration. *Acta Ophthalmol* 2008;86:622–5.
- Zangerl B, Whatham A, Kim J, et al. Reconciling Visual Field Defects and Retinal Nerve Fibre Layer Asymmetric Patterns in Retrograde Degeneration: An Extended Case Series. *Clin Exp Optom* 2017;100:214–26.
- Chylack LT, Jr., Wolfe JK, Singer DM, et al. The Lens Opacities Classification System Iii. The Longitudinal Study of Cataract Study Group. *Arch Ophthalmol* 1993;111:831–6.
- Anderson RS, McDowell DR, Ennis FA. Effect of Localized Defocus on Detection Thresholds for Different Sized Targets in the Fovea and Periphery. *Acta Ophthalmol Scand* 2001;79:60–3.
- Bengtsson B, Heijl A, Olsson J. Evaluation of a New Threshold Visual Field Strategy, Sita, in Normal Subjects. Swedish Interactive Thresholding Algorithm. *Acta Ophthalmol Scand* 1998;76:165–9.
- Khoury JM, Donahue SP, Lavin PJ, et al. Comparison of 24-2 and 30-2 Perimetry in Glaucomatous and Nonglaucomatous Optic Neuropathies. *J Neuroophthalmol* 1999;19:100–8.
- Phu J, Khuu SK, Nivison-Smith L, et al. Pattern Recognition Analysis Reveals Unique Contrast Sensitivity Isocontours Using Static Perimetry Thresholds across the Visual Field. *Invest Ophthalmol Vis Sci* 2017;58:4863–76.
- Heijl A, Lindgren G, Olsson J, et al. Visual Field Interpretation with Empiric Probability Maps. *Arch Ophthalmol* 1989;107:204–8.
- Katz J. A Comparison of the Pattern- and Total Deviation-based Glaucoma Change Probability Programs. *Invest Ophthalmol Vis Sci* 2000;41:1012–6.
- Katz J, Congdon N, Friedman DS. Methodological Variations in Estimating Apparent Progressive Visual Field Loss in Clinical Trials of Glaucoma Treatment. *Arch Ophthalmol* 1999;117:1137–42.
- Asman P, Heijl A. Glaucoma Hemifield Test. Automated Visual Field Evaluation. *Arch Ophthalmol* 1992;110:812–9.
- Gardiner SK, Demirel S, Goren D, et al. The Effect of Stimulus Size on the Reliable Stimulus Range of Perimetry. *Transl Vis Sci Technol* 2015;4:10.
- Phu J, Khuu SK, Bui BV, et al. A Method Using Goldmann Stimulus Sizes I–V Measured Sensitivities to Predict Lead-time Gained to Visual Field Defect Detection in Early Glaucoma. *Trans Vis Sci Technol* 2018;7(4):17.
- Fedtke C, Ehrmann K, Holden BA. A Review of Peripheral Refraction Techniques. *Optom Vis Sci* 2009;86:429–46.
- Anderson RS, Thibos LN. Relationship between Acuity for Gratings and for Tumbling-E Letters in Peripheral Vision. *J Opt Soc Am (A)* 1999;16:2321–33.
- Lundstrom L, Gustafsson J, Svensson I, et al. Assessment of Objective and Subjective Eccentric Refraction. *Optom Vis Sci* 2005;82:298–306.
- Keltner JL, Johnson CA, Cello KE, et al. Visual Field Profile of Optic Neuritis: A Final Follow-up Report from the Optic Neuritis Treatment Trial from Baseline through 15 Years. *Arch Ophthalmol* 2010;128:330–7.
- Mills RP, Budenz DL, Lee PP, et al. Categorizing the Stage of Glaucoma from Pre-diagnosis to End-stage Disease. *Am J Ophthalmol* 2006;141:24–30.
- Bengtsson B, Bizios D, Heijl A. Effects of Input Data on the Performance of a Neural Network in Distinguishing Normal and Glaucomatous Visual Fields. *Invest Ophthalmol Vis Sci* 2005;46:3730–6.
- Phu J, Kalloniatis M, Khuu SK. Reducing Spatial Uncertainty through Attentional Cueing Improves Contrast Sensitivity in Regions of the Visual Field with Glaucomatous Defects. *Transl Vis Sci Technol* 2018;7(4):8.
- Bengtsson B, Heijl A. False-negative Responses in Glaucoma Perimetry: Indicators of Patient Performance or Test Reliability? *Invest Ophthalmol Vis Sci* 2000;41:2201–4.
- Wall M, Zamba GKD, Artes PH. The Effective Dynamic Ranges for Glaucomatous Visual Field Progression with Standard Automated Perimetry and Stimulus Sizes III and V. *Invest Ophthalmol Vis Sci* 2018;59:439–45.
- Jindahra P, Petrie A, Plant GT. The Time Course of Retrograde Trans-synaptic Degeneration Following Occipital Lobe Damage in Humans. *Brain* 2012;135:534–41.
- Verkicherla PK, Suheimat M, Schmid KL, et al. Peripheral Refraction, Peripheral Eye Length, and Retinal Shape in Myopia. *Optom Vis Sci* 2016;93:1072–8.
- Moore KE, Berntsen DA. Central and Peripheral Autorefractive Repeatability in Normal Eyes. *Optom Vis Sci* 2014;91:1106–12.
- Kang P, Gifford P, McNamara P, et al. Peripheral Refraction in Different Ethnicities. *Invest Ophthalmol Vis Sci* 2010;51:6059–65.
- Bharadwaj SR, Malavita M, Jayaraj J. A Psychophysical Technique for Estimating the Accuracy and Precision of Retinoscopy. *Clin Exp Optom* 2014;97:164–70.
- Zadnik K, Mutti DO, Adams AJ. The Repeatability of Measurement of the Ocular Components. *Invest Ophthalmol Vis Sci* 1992;33:2325–33.
- Atchison DA. Comparison of Peripheral Refractions Determined by Different Instruments. *Optom Vis Sci* 2003;80:655–60.
- Seidemann A, Schaeffel F, Guirao A, et al. Peripheral Refractive Errors in Myopic, Emmetropic, and Hyperopic Young Subjects. *J Opt Soc Am (A)* 2002;19:2363–73.
- Atchison DA, Scott DH. Monochromatic Aberrations of Human Eyes in the Horizontal Visual Field. *J Opt Soc Am (A)* 2002;19:2180–4.
- Ehsaei A, Mallen EA, Chisholm CM, et al. Cross-sectional Sample of Peripheral Refraction in Four Meridians in Myopes and Emmetropes. *Invest Ophthalmol Vis Sci* 2011;52:7574–85.
- Traynis I, De Moraes CG, Raza AS, et al. Prevalence and Nature of Early Glaucomatous Defects in the Central 10° of the Visual Field. *JAMA Ophthalmol* 2014;132:291–7.
- Shoeibi N, Moghadas Sharif N, Daneshvar R, et al. Visual Field Assessment in High Myopia with and without Tilted Optic Disc. *Clin Exp Optom* 2017;100:690–4.