



Endoscopic treatment of Killian-Jamieson diverticulum using submucosal tunneling diverticulotomy technique

Ali Zakaria, MD,¹ Mohammed Barawi, MD²

Killian-Jamieson diverticulum (KJD) is a rare type of esophageal diverticulum, with recent comprehensive literature review reporting few cases. It is less commonly encountered in clinical practice compared with Zenker's diverticulum. KJD is an anterolateral diverticulum that originates in an area of anatomic weakness known as the Killian-Jamieson triangle. It is located inferior to the cricopharyngeus muscle, superior to circular muscle, and lateral to the longitudinal muscle of the cervical esophagus (Fig. 1). The recurrent laryngeal nerve enters this location as it travels to the larynx. Zenker's diverticulum, in contrast, is located posteriorly superior to the cricopharyngeus muscle.

CASE REPORT

An 82-year-old female patient presented with progressively worsening dysphagia to solid food, regurgitation,

globus sensation, and halitosis. Barium esophagram was performed and revealed a 40-mm anterolateral protrusion at the level of the proximal cervical esophagus, consistent with KJD (Fig. 2). Because of her age and significant comorbidities (hypertension, peripheral vascular disease, and cardiac arrhythmia requiring permanent pacemaker), she preferred to proceed with the least-invasive intervention. Informed consent was obtained for endoscopic treatment using the submucosal tunneling diverticulotomy technique.

After endotracheal intubation and with the patient under general anesthesia, the gastroscope with distal attachment cap was introduced through the mouth with mild resistance noted distal to the cricopharyngeus muscle at the level of the diverticular septum. Upon endoscope withdrawal, the diverticulum was clearly identified at the anterolateral border of the esophagus (Fig. 3). Submucosal injection of normal saline solution mixed with methylene

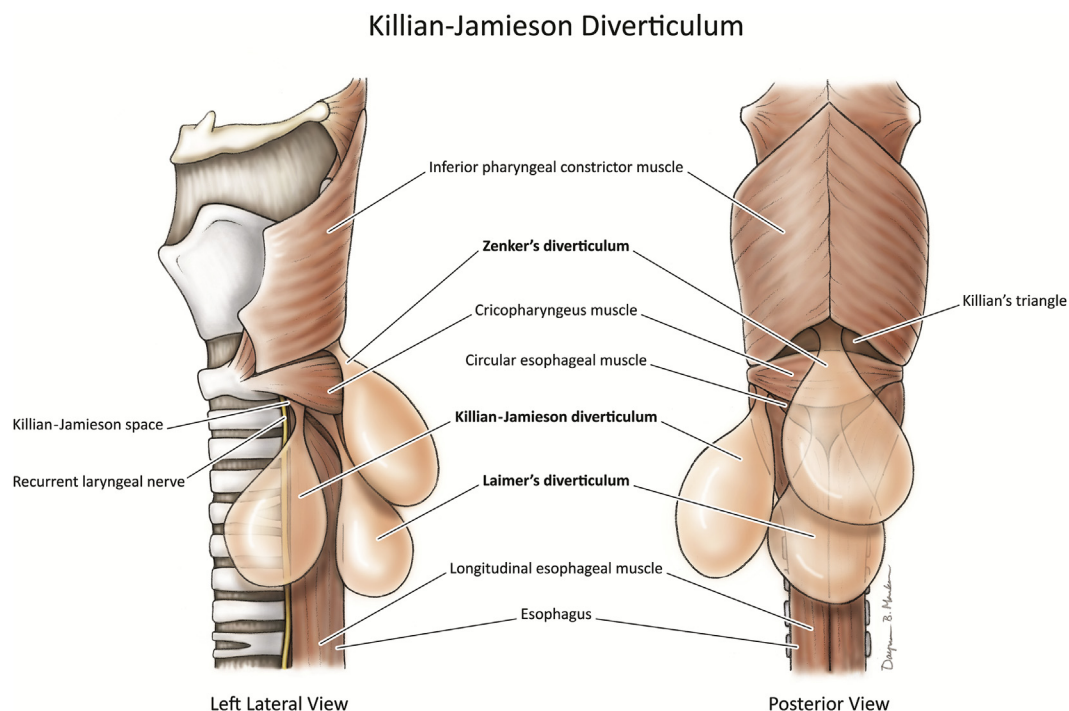


Figure 1. Anatomy of the hypopharynx. Killian-Jamieson space and its relation to the recurrent laryngeal nerve (*lateral view*). Three types of esophageal diverticula (Killian-Jamieson, Zenker's diverticulum, and Laimer's diverticulum), with their locations relative to cervical esophageal muscles. Printed with permission from Designer BioMed LLC.

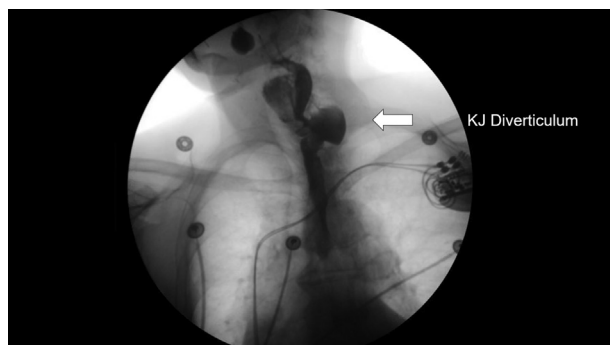


Figure 2. Barium esophagram reveals a 40-mm anterolateral protrusion at the level of the proximal cervical esophagus consistent with Killian-Jamieson diverticulum.

blue was performed using a 25-gauge needle. A 12-mm mucosotomy was performed 1.5 cm proximal to the diverticular septum using T-type Hybrid Knife (ERBE; USA, Marietta, Ga, USA). The tip of the endoscope with distal attachment cap was advanced to the tunnel. Submucosal dissection on both sides of the septum was performed, and the circular muscle fibers were clearly visualized. The same T-type Hybrid Knife, with the standard electrocautery endo-cut setting, was used to perform a completed myotomy. The base of the diverticulum was evaluated carefully to ensure complete dissection of all muscle fibers. The endoscope was withdrawn from the tunnel, and the mucosotomy site was closed using 3 through-the-scope endoclips. After the intervention, the endoscope was advanced to the esophagus with no resistance, and mucosal integrity was confirmed (Video 1, available online at www.VideoGIE.org).

The patient was given a dose of antibiotic prophylaxis. She tolerated the procedure well with no immediate or delayed procedural adverse events. She was admitted overnight for observation. Gastrografin esophagram was performed and revealed no evidence of extraluminal

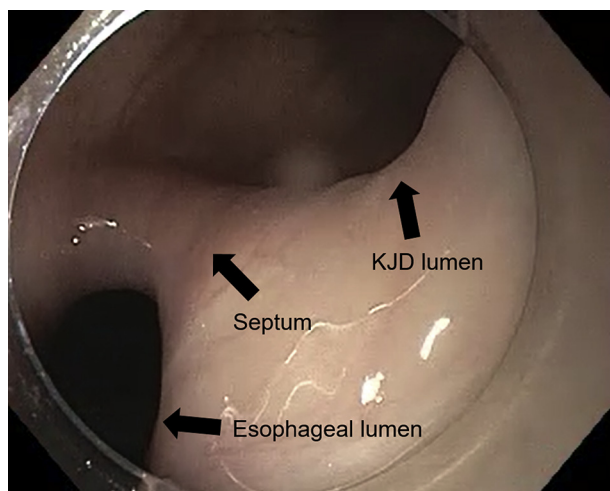


Figure 3. Endoscopic view of the diverticulum at the anterolateral border of the esophagus.

leak. She tolerated a clear liquid diet and was discharged home. During her postprocedural clinical follow-up, she had no residual symptoms.

DISCUSSION

KJD is a rare type of esophageal diverticulum, with a recent comprehensive literature review by Haddad et al¹ identifying 68 reported cases. It is less commonly encountered in clinical practice compared with Zenker's diverticulum. It is usually asymptomatic and is often diagnosed incidentally on radiologic imaging for other purposes. In symptomatic patients, dysphagia is most commonly reported.

KJD is more difficult to treat than Zenker's diverticulum because of the close proximity of the diverticulum neck to the recurrent laryngeal nerve. Transcervical surgical myotomy is the mainstay approach for treatment; however, endoscopic therapies have been reported as safe and effective.^{2,3}

Endoscopic techniques with either direct septotomy or tunneling diverticulotomy have been recently described. Tunneling diverticulotomy is preferred over direct diverticulotomy for its safety, with secure closure and lower risk of leak, and its effectiveness because it allows for longer myotomy and a lower recurrence rate.^{2,4} Herein, we demonstrated use of the submucosal tunneling diverticulotomy technique to successfully treat KJD.

DISCLOSURE

All authors disclosed no financial relationships.

Abbreviation: KJD, Killian-Jamieson diverticulum.

REFERENCES

1. Haddad N, Agarwal P, Levi JR, et al. Presentation and management of Killian Jamieson diverticulum: a comprehensive literature review. *Ann Otol Rhinol Laryngol* 2020;129:394-400.
2. Stavropoulos SN, Ali MF, Zhang X, et al. Endoscopic direct and tunneling diverticulotomy techniques for Killian Jamieson diverticulum: report of twelve cases [abstract]. *Gastrointest Endosc* 2019;89:AB180.
3. Yang D, Draganov PV. Endoscopic Killian-Jamieson diverticulotomy using a scissor-type electrosurgical knife. *Endoscopy* 2018;50:E175-6.
4. Tang SJ, Tang L, Chen E, et al. Flexible endoscopic Killian-Jamieson diverticulotomy and literature review. *Gastrointest Endosc* 2008;68:790-3.

Division of Gastroenterology, Ascension Providence Hospital, Southfield, Michigan (1), Division of Gastroenterology, Ascension St. John Hospital, Detroit, Michigan (2).

Copyright © 2020 American Society for Gastrointestinal Endoscopy. Published by Elsevier Inc. This is an open access article under the CC BY-NC-ND license (<http://creativecommons.org/licenses/by-nc-nd/4.0/>).

<https://doi.org/10.1016/j.vgie.2020.05.031>