

# A Rare Presentation of Ileocecal Mucormycosis in a Heart Transplant Recipient

Sook Hoang, MD<sup>1</sup>, and Michael Sestito, MD<sup>2</sup>

<sup>1</sup>Department of Surgery, University of Virginia Health System, Charlottesville, VA

<sup>2</sup>Department of Surgery, West Virginia University School of Medicine, Morgantown, WV

## ABSTRACT

*Mucorales* is an order of angioinvasive fungi that classically infects immunocompromised patients. As an aerogenous pathogen, it most frequently causes disease of the lungs and paranasal sinuses. Gastrointestinal mucormycosis represents a particularly rare site of infection. This case report describes the complicated presentation of ileocecal mucormycosis in an immunocompromised orthotopic heart transplant recipient. The diagnosis was made status-post ileocolonic resection, and the patient was promptly started on liposomal amphotericin B and micafungin. Unfortunately, the patient ultimately succumbed to disseminated infection. In this study, we review the epidemiology, the presenting features of gastrointestinal mucormycosis, and emphasize the prompt initiation of therapy on suspected disease.

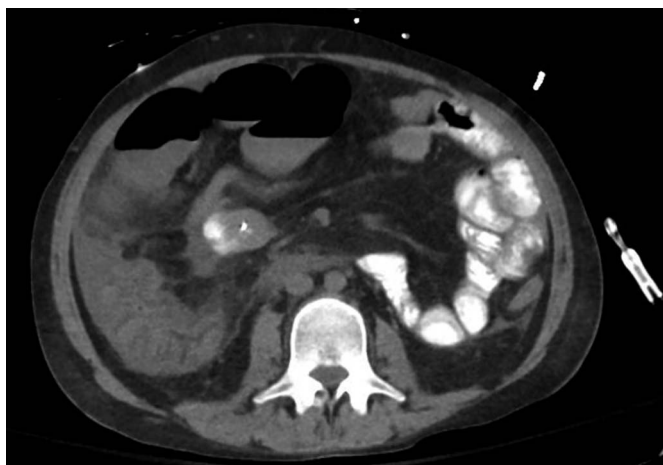
## INTRODUCTION

*Mucorales* is an order of filamentous fungi that are ubiquitous in the environment.<sup>1</sup> It acts as an opportunistic pathogen implicated in a host of human diseases collectively known as mucormycosis. As an aerogenous pathogen, it is believed to be introduced to the host through inhalation of sporangiospores primarily. Not surprisingly then, its primary sites of infectivity tend to be the lungs and paranasal sinuses (and by extension, orbit, and cerebrum).<sup>2</sup> In this study, we describe a rare case of ileocolic mucormycosis in a young but severely immunocompromised patient.

## CASE REPORT

Our patient is a 25-year-old man who was admitted after an episode of ventricular fibrillation. His medical history was significant for dilated cardiomyopathy requiring a heart transplant at 3 years of age and a second orthotopic heart transplant at 24 years old. His post-transplant course was complicated by cardiac arrest requiring extracorporeal membrane oxygenation with eventual permanent pacemaker placement, percutaneous endoscopic gastrostomy tube, and end-stage renal failure. In addition, in the setting of immunosuppression with neutropenia, he has had a complex infectious disease history including chronic sternal dehiscence containing *Pseudomonas aeruginosa*, Coryneform Gram-negative rods, and *Candida* spp. Given the proximity of the infection to his sternum and concern for osteomyelitis, before admission, he was being treated with a 6-week course of intravenous cefepime and vancomycin administered as an outpatient. He had also started on an extended 6- to 12-month course of oral voriconazole to treat the *Candida* spp. cultured from debrided mediastinal tissue. Because of concern for drug-associated arrhythmia, voriconazole was stopped at admission. This was replaced by micafungin for continued treatment of *Candida* spp. Of note, his immunosuppression regimen included tacrolimus and low-dose prednisone. He had previously been prescribed mycophenolate, but this was discontinued before admission in the setting of fungal infections. His immunosuppressant dosages were titrated to be within therapeutic range.

Early in his hospital course, he was intermittently febrile with a leukocytosis of 23 k/uL which was initially attributed to *P. aeruginosa* ventilator-associated pneumonia. Given his immunocompromised state, a noncontrast computed tomography (CT) scan was obtained on hospital day (HD) 7, demonstrating inflammatory changes of the cecum and ascending colon (Figure 1). These findings were initially believed to be multifactorial, including ischemia after recent ventricular fibrillation arrest and bowel edema from



**Figure 1.** Pelvic and abdominal computed tomography with findings suggestive of inflammatory changes to the cecum and moderate abdominal ascites.

cardiogenic shock. Supportive management was used. On HD 12, the patient developed increasing abdominal distension with decreased stool output, and a repeat abdominal CT demonstrated persistent inflammatory changes and a new onset of dilated small bowel loops with a transition point at the ileocecal valve. This was consistent with a partial small bowel obstruction. Because the patient was critically ill with multiple ongoing medical issues, the surgical team recommended conservative management. This included percutaneous endoscopic gastrostomy tube decompression, serial abdominal examinations, abdominal x-rays every 2–3 days, and transitioning enteral nutrition to total parenteral nutrition. Likewise, endoscopic evaluation was initially deferred because of his tenuous clinical status.

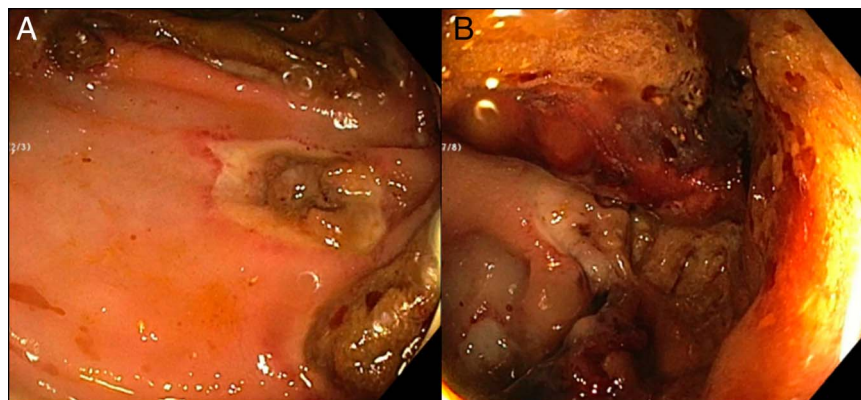
Despite these measures, the obstruction did not resolve, and the patient remained persistently febrile. A colonoscopy was ultimately performed on HD 22 which showed large ulcerations of the cecum and ascending colon and a severe angulated stricture of the ileocecal valve which was not traversable endoscopically (Figure 2). Biopsies of the cecum and ileocecal valve were performed, but pathologic results were not available at that time.

Immediately after the colonoscopy, the patient developed worsening abdominal distension. An abdominal CT showed a large-volume pneumoperitoneum, and he was taken to the operating room for an urgent exploratory laparotomy. Intraoperatively, 2 large perforations associated with necrotic bowel were identified at the terminal ileum. An ileocolic resection with extended right colectomy, long Hartmann pouch, and end ileostomy was performed. Gross inspection of the remaining bowel appeared viable. Final surgical pathology yielded transmural ischemic infarction with large fungal hyphae of variable morphology consistent with gastrointestinal mucormycosis (Figure 3). He was started on liposomal amphotericin B. Of note, micafungin was continued primarily to treat *Candida* mediastinitis and not mucormycosis because echinocandins have not been found to be an effective treatment for *Mucorales* species.

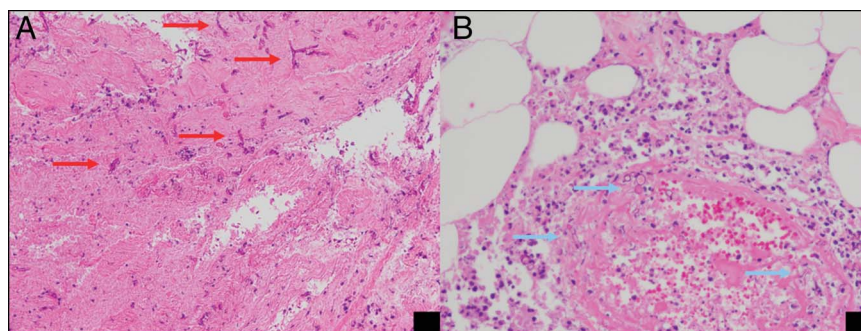
On the postoperative day 16/HD 38, he experienced a sudden drop in hemoglobin from 7.5 to 6.1 g/dL and frank blood through his ileostomy. CT angiography demonstrated active extravasation from the midjejunum along with several segments of worsening bowel wall thickening. Mesenteric angiography, however, did not demonstrate active bleeding, and therapeutic embolization could not be performed. Over the next 3 days, the patient's clinical status gradually worsened with increasing lactic acidosis, hypothermia, and requirements for blood pressure support. An ileoscopy was performed on postoperative day 18/HD 40 which showed necrotic, ulcerated ileum spanning 40%–50% of luminal circumference consistent with disseminated fungal infection (Figure 4). At that time, further surgical debridement was deemed unlikely to benefit the patient. Palliative measures were implemented, and our patient ultimately died the following day.

## DISCUSSION

Mucormycosis is classically diagnosed in immunocompromised patients with common risk factors, including diabetes mellitus, hematopoietic stem cell and solid organ transplantation, glucocorticoid therapy, and intravenous drug



**Figure 2.** Photographic images of the colonoscopy. (A) Large deep ulcerations surrounded by friable mucosa are visible in the cecum, and (B) scattered and discontinuous shallow ulcerations are seen extending to the hepatic flexure.



**Figure 3.** Histologic images taken from the ileocolic resection. (A) Intermediate-power image demonstrating abundant hyphal forms (red arrows) in necrotic debris on the serosal surface of the cecum and (B) high-power image of hyphae within a vessel (blue arrows) surrounded by acute inflammation.

use.<sup>1,3,4</sup> In a comprehensive retrospective review of 929 published cases, Roden et al reported infection patterns based on-site, including rhino-orbital-cerebral 39%, pulmonary 24%, cutaneous 19%, isolated cerebral 9%, gastrointestinal 7%, and generalized disseminated 3%.<sup>4</sup> These patterns were similar when comparing sites of infection, specifically in the solid organ transplantation and hematopoietic stem cell population.<sup>5,6</sup> In a 2020 case report by Poyuran et al, the authors identified only 8 adult cases of mucormycosis localized to the cecum or ileocecal junction reported in the literature.<sup>7</sup>

Clinical manifestations of gastrointestinal mucormycosis are nonspecific and include abdominal pain, distension, vomiting, fever, diarrhea, and melena.<sup>3</sup> The presenting feature of ileocecal infection is often peritonitis after gastrointestinal perforation, as seen in our case after endoscopy.<sup>7,8</sup> The gastrointestinal variant of mucormycosis tends to be fulminant with a mortality estimated to be 85%.<sup>4</sup> In fact, antemortem diagnosis is only made in about 25% of cases.<sup>9</sup>

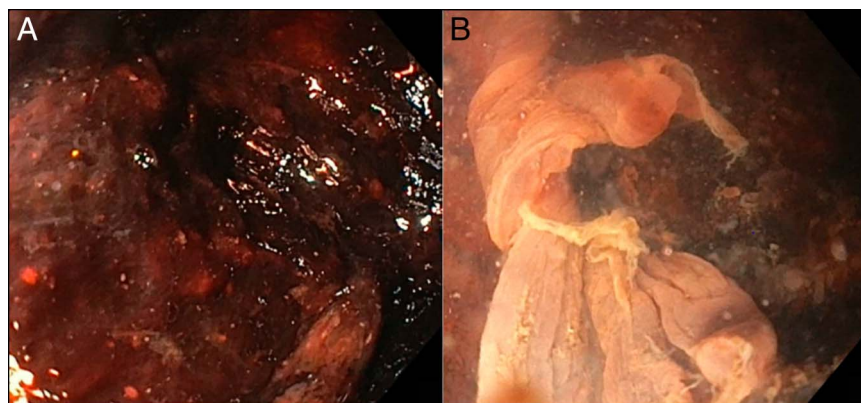
Thus, given a vague clinical picture but a life-threatening course, the clinician must maintain a high index of suspicion to make a timely diagnosis. This is essential because early initiation of treatment, a combination of surgery and antifungal therapy, offers the best chance of survival. *Mucorales* spp. are highly vasculotropic, leading to thrombosis and necrosis of the

infected organ.<sup>6,10</sup> Surgical debridement not only removes devitalized tissue but is also believed to improve penetration of subsequent antifungal therapy.<sup>1,3</sup> The need for early initiation of antifungal therapy is perhaps best exemplified in a study by Chamilos et al who demonstrated a 2-fold increase in mortality when the administration of amphotericin B was delayed beyond 6 days after the diagnosis of zygomycosis was made.<sup>11</sup> In our case, therapy was initiated as soon as the diagnosis became apparent; however, given the patient's protracted hospital course, it is likely that this infection had been present for much longer.

In summary, we present a 25-year-old heart transplant recipient who developed an extremely rare but highly fatal ileocecal mucormycosis. Despite our best efforts, the patient succumbed of this angioinvasive infection. We would like to emphasize keeping mucormycosis, of any site, high on the differential for immunocompromised populations to achieve the most optimal chance of survival.

## DISCLOSURES

Author contributions: S. Hoang reviewed the literature and revised the manuscript for intellectual content. M. Sestito wrote the manuscript and reviewed the literature. S. Hoang is the article guarantor.



**Figure 4.** Photographic images of the ileoscopy. (A) Diffusely necrotic and ulcerated ileum near end ileostomy and (B) necrotic and deeply ulcerated segment of more proximal ileum involving approximately 40%–50% of the bowel.

**Acknowledgments:** The authors thank the Department of Pathology of the University of Virginia for providing histologic images essential to the diagnosis of this patient.

**Financial disclosure:** None to report.

**Informed consent** was obtained for this case report.

Received October 13, 2020; Accepted June 21, 2021

## REFERENCES

1. Eucker J, Sezer O, Graf B, Possinger K. Mucormycoses. *Mycoses*. 2001;44: 253–60.
2. Thomson SR, Bade PG, Taams M, Chrystal V. Gastrointestinal mucormycosis. *Br J Surg*. 1991;78:952–4.
3. Spellberg B. Gastrointestinal mucormycosis: An evolving disease. *Gastroenterol Hepatol (NY)*. 2012;8:140–2.
4. Roden MM, Zaoutis TE, Buchanan WL, et al. Epidemiology and outcome of zygomycosis: A review of 929 reported cases. *Clin Infect Dis*. 2005;41: 634–53.
5. Singh N, Aguado JM, Bonatti H, et al. Zygomycosis in solid organ transplant recipients: A prospective, matched case-control study to assess risks for disease and outcome. *J Infect Dis*. 2009;200:1002–11.
6. Park BJ, Pappas PG, Wannemuehler KA, et al. Invasive non-aspergillus mold infections in transplant recipients, United States, 2001–2006. *Emerg Infect Dis*. 2011;17:1855–64.
7. Poyuran R, Dharan BS, Sandhyamani S, Narasimhaiah D. Mucormycosis-induced ileocecal perforation: A case report and review of literature. *J Postgrad Med*. 2020;66:48–50.
8. Law W, Lo OS. Ileocolonic mucormycosis in adult immunocompromised patients: A surgeon's perspective. *World J Gastroenterol*. 2010;16:1165–70.
9. Petrikos G, Skiada A, Lortholary O, Roilides E, Walsh TJ, Kontoyiannis DP. Epidemiology and clinical manifestations of mucormycosis. *Clin Infect Dis*. 2012;54(Suppl 1):S23–34.
10. Karanth M, Taniere P, Barraclough J, Murray JA. A rare presentation of zygomycosis (mucormycosis) and review of the literature. *J Clin Pathol*. 2005;58:879–81.
11. Chamilos G, Lewis RE, Kontoyiannis DP. Delaying amphotericin B-based frontline therapy significantly increases mortality among patients with hematologic malignancy who have zygomycosis. *Clin Infect Dis*. 2008;47: 503–9.

---

**Copyright:** © 2021 The Author(s). Published by Wolters Kluwer Health, Inc. on behalf of The American College of Gastroenterology. This is an open access article distributed under the terms of the Creative Commons Attribution-Non Commercial-No Derivatives License 4.0 (CCBY-NC-ND), where it is permissible to download and share the work provided it is properly cited. The work cannot be changed in any way or used commercially without permission from the journal.