

CASE REPORT

Hemangiopericytoma: an unusual cause of peritoneal carcinomatosis

Mahesh Prakash, Hina Arif Mumtaz, Kushaljeet S. Sodhi, R. Kapoor and Niranjan Khandelwal

Department of Radiodiagnosis, Post Graduate Institute of Medical Education and Research, 160012 Chandigarh, India

Corresponding address: Dr Hina Arif Mumtaz, MD, DNB, Department of Radiodiagnosis, Post Graduate Institute of Medical Education and Research, 160012 Chandigarh, India.

Email: drhinaarif@yahoo.co.in

Date accepted for publication 21 April 2009

Abstract

Hemangiopericytoma, a rare mesenchymal tumour, is believed to originate from the pericyte of Zimmermann. It may affect every organ in the body. Recurrences after treatment and metastasis are well known. However, presentation of hemangiopericytoma with peritoneal carcinomatosis is not documented in literature. To the best of our knowledge, we report the imaging findings of the first histologically proven case of hemangiopericytoma with peritoneal carcinomatosis.

Keywords: Hemangiopericytoma; peritoneal carcinomatosis; computed tomography.

Introduction

Peritoneal carcinomatosis is the most common terminal feature of abdominopelvic malignancies. Although the disease is limited to the peritoneal surface, this condition is still worrisome for the surgeon and the oncologist as complete surgical removal is impossible and systemic chemotherapy is ineffective.^[1] Peritoneal implants are most commonly encountered in ovarian carcinoma (35%), followed by colonic (30%) and gastric carcinoma (10%). Less than 5% of cases include pancreatic, uterine, fallopian tube, hepatocellular, cholangiocarcinoma, cervical, and bladder carcinomas, mesothelioma, Hodgkin disease, and carcinoma (primary site unknown).^[2]

To the best of our knowledge, hemangiopericytoma as a cause of abdominal carcinomatosis at the time of its presentation, has been not reported before. Although there are reports of recurrent peritoneal carcinomatosis in cases of hemangiopericytoma,^[3] we present a rare case of pelvic hemangiopericytoma presenting as peritoneal carcinomatosis.

Case history

A 45-year-old female presented with lower abdominal pain and dysuria of 2 months duration, along with loss

of appetite and loss of weight. No history of alteration of bowel habits, bleeding per vaginum or per rectum was given. She was a known hypertensive controlled on drugs. Pan hysterectomy was done 5 years previously for abnormal uterine bleeding. Histopathological examination of the operated specimen showed extensive adenomyosis in the myometrium. On general physical examination the patient appeared emaciated, her abdomen was distended with a huge abdominopelvic mass, approaching the navel. The hysterectomy scar was visible in the lower abdomen. Pulse and respiratory rate were normal.

On local examination, a huge firm mass 12 × 12 cm in size was palpated in the right iliac fossa, crossing the midline. Per vaginum examination revealed a mass along the right fornix. Haematological and biochemical investigations as well as chest radiograph were normal.

Ultrasound abdomen showed a large abdominopelvic solid heterogeneous mass with a few anechoic areas of necrosis within it. Increased colour flow was present on colour Doppler examination, suggesting the vascular nature of the mass. The right lobe of the liver had hypoechoic lesions with target appearance. There was moderate right hydronephrosis.

Multidetector contrast enhanced computed tomography was subsequently performed which revealed a

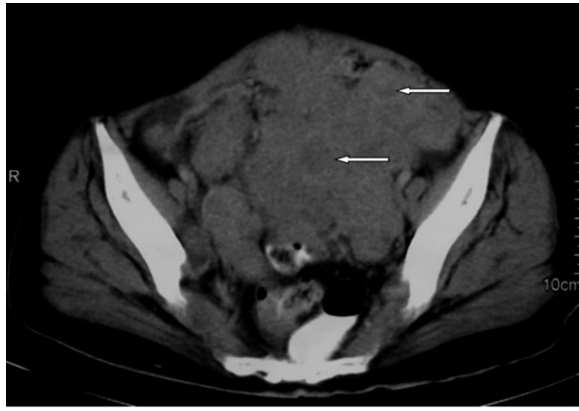


Figure 1 CECT sections through the pelvis. Large heterogeneously enhancing abdominopelvic mass with a few areas of necrosis, proven on cytology to be hemangiopericytoma.

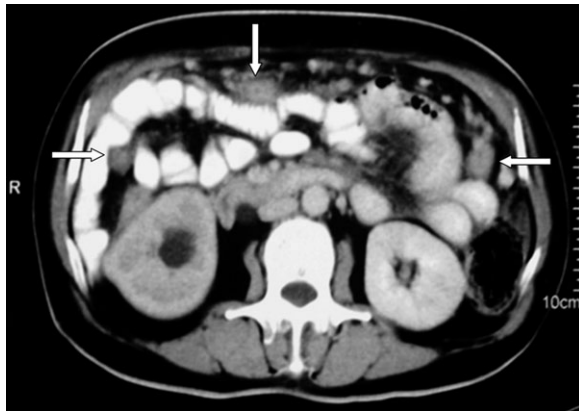

Figure 2 Peritoneal implants in the omentum and small bowel mesentery (arrowheads). Note the right hydronephrosis.

heterogeneously enhancing, lobulated abdominopelvic mass, $21 \times 16 \times 13$ cm in size, in relation to the greater omentum which showed subtle, small hypodense areas of necrosis. Ill-defined margins with invasion of the small bowel loops and mesentery, sigmoid mesocolon and vaginal vault were seen with indentation over the anterior wall of the rectum and the posterior wall of the urinary bladder (Fig. 1). Multiple well-defined heterogeneous masses suggestive of peritoneal implants were present in the small bowel mesentery, greater omentum and peritoneum, indenting the posterior surface of the liver adjacent to segment VI (Fig. 2). The distal right ureter was encased by the mass leading to subsequent right hydronephrosis. The liver showed multiple, heterogeneously enhancing masses suggestive of metastasis. Mild ascites was present. As the tumour was very large at the time of imaging, its site of origin could not be ascertained, hence a diagnosis of a sarcomatous tumour arising from the pelvis or solid primary omental tumour,

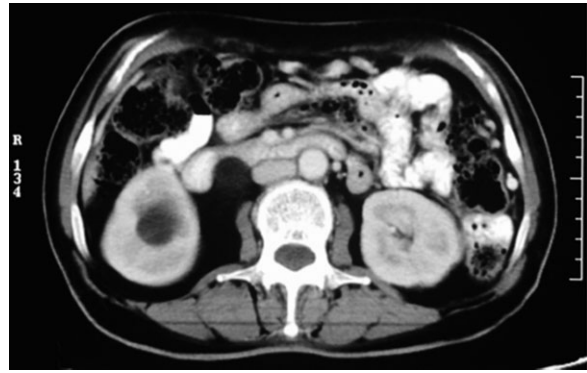

Figure 3 Post-chemotherapy repeat contrast-enhanced computed tomography shows significant resolution of the peritoneal implants.

with peritoneal carcinomatosis and hepatic metastasis was given.

Fine-needle aspiration cytology revealed tumour cells in sheaths and clusters. The tumour cells were round to oval with a high nuclear cytoplasmic ratio, clumped chromatin and scanty cytoplasm. Scattered spindle-shaped cells with bare nuclei in a necrotic and hemorrhagic background were seen. Cells were closely associated with vascular channels. Features were suggestive of hemangiopericytoma.

The patient received 6 cycles of a ifosfamide, epirubicin, cisplatin chemotherapy regime as there was dissemination of the disease at the time of presentation. Repeat contrast-enhanced computed tomography 6 months later showed significant reduction in the mass and omental deposits (Fig. 3), with resolution of ascites.

Discussion

Hemangiopericytoma constitutes <1% of all vascular neoplasm.^[4] This rare vascular tumour was first described by Schmidt in 1937 and named by Stout and Murray in 1942.^[5] It is most common in the lower extremities, head, neck, and retroperitoneum; less frequent sites are the abdomen and pelvis. Middle-aged adults are primarily affected. There is no sex predilection.

Hemangiopericytoma arises from the pericytes of Zimmerman which are rudimentary pericapillary cells, not connected to the arterial or venule epithelium. Pericytes have tendril-like projections that surround the capillary and regulate blood flow. Since all capillaries are surrounded by pericytes, hemangiopericytomas are ubiquitous in distribution.

According to Schwartz *et al.* hemangiopericytomas constitute 10% of all primary solid omental tumours.^[6] Development of this mesenchymal tumour in the greater omentum is extremely rare. Only 13 cases of omental hemangiopericytoma are reported in the English literature;^[7] 4 out of these 13 cases had recurrent peritoneal carcinomatosis; however no case of omental or pelvic

hemangiopericytoma documents peritoneal implants at the time of presentation.^[3]

Imaging plays a pivotal role in the appropriate treatment planning by demonstrating the vascular nature of the tumour, revealing the exact source of its blood supply, and, finally, demonstrating its size and relationship with the adjacent organs.

Ultrasonography of a hemangiopericytoma shows a solid mass with heterogeneous echo pattern, well-defined margins and marked vascularity with low impedance flow (mean resistive index 0.42) on colour flow imaging. Contrast-enhanced computed tomography demonstrates strong but brief peripheral enhancement and a central hypodense scar/necrosis in a well-defined solid mass can be seen. Homogenous enhancement, absence of calcification, necrosis and haemorrhage are commonly seen in benign hemangiopericytoma.^[8] Catheter angiography shows a feeder vascular pedicle with radial branching pattern wrapping a well-demarcated tumour stain.^[3] Magnetic resonance imaging (MRI) detects haemorrhage and necrosis within the tumour and delineates the relationship of the mass with the adjacent structures.^[9]

Less than 50% of patients are disease-free at 5 years. Recurrences, particularly developing at distant sites, after an extended disease-free interval are well known; they involve the liver, lung, bone, and peritoneum.^[3,10]

Systemic chemotherapy may be employed for hemangiopericytoma metastasis and recurrence. However, standard and effective chemotherapeutic regimens have yet to be established.^[10] Radical surgery still remains the mainstay of therapy.^[3] Peritoneal recurrences have even occurred in patients who have undergone surgery (omentectomy). Therefore, the early detection of locoregional disease, assessment of its extent and distant recurrence plays a key role in the prognosis of these patients.

A careful long-term follow-up is mandatory for such patients.

References

- [1] Sano T. Is peritoneal carcinomatosis an incurable disease or controllable locoregional condition? Challenge of surgeons with intraperitoneal hyperthermic chemotherapy. *Jpn J Clin Oncol* 2001; 31: 571–2. doi:10.1093/jjco/hye141. PMID:11902486.
- [2] Walkey MM, Friedman AC, Sohotra P, Radecki PD. CT manifestations of peritoneal carcinomatosis. *Am J Roentgenol* 1988; 150: 1035–41.
- [3] Kaneko K, Shirai Y, Wakai T, Hasegawa G, Kaneko I, Hatakeyama K. Hemangiopericytoma arising in the greater omentum: report of a case. *Surg Today* 2003; 33: 722–4. doi:10.1007/s00595-003-2559-6. PMID:12928856.
- [4] Slepiski M, Piotrowiak I, Wlodarczyk Z. Local recurrence and distance metastases 18 years after resection of the greater omentum haemangiopericytoma. *World J Surg Oncol* 2007; 63: 1477–8.
- [5] Stout AP, Murray MR. Hemangiopericytoma: vascular tumor featuring Zimmerman's pericytes. *Ann Surg* 1942; 116: 26–33.
- [6] Schwartz RW, Reames M, McGrath PC, Letton RW, Appleby G, Kenady DE. Primary solid neoplasms of the greater omentum. *Surgery* 1991; 109: 543–9.
- [7] Shiba H, Misawa T, Kobayashi S, Yokota T, Son K, Yanaga K. Hemangiopericytoma of the greater omentum. *J Gastrointest Surg* 2007; 11: 549–51. doi:10.1007/s11605-007-0099-x. PMID:17436143.
- [8] Bertolotto M, Cittadini Jr G, Crespi G, Perrone C, Pastorino R. Hemangiopericytoma of the greater omentum: US and CT appearance. *Eur Radiol* 1996; 6: 454–6.
- [9] Yilmaz E, Akkoclu A, Kargi A, et al. Radiography, Doppler sonography, and MR angiography of malignant pulmonary hemangiopericytoma. *Am J Roentgenol* 2003; 181: 1079–81.
- [10] Aliberti C, Benea G, Kopf B, De Giorgi U. Hepatic metastases of hemangiopericytoma: contrast-enhanced MRI, contrast-enhanced ultrasonography and angiography findings. *Cancer Imaging* 2006; 6: 56–9. doi:10.1102/1470-7330.2006.0011. PMID:16766270.