

## Two novel variants in the lecithin:cholesterol acyltransferase gene resulted in classic LCAT deficiency

Margareta Fistrek Prlic<sup>a,\*</sup>, Marijana Coric<sup>b</sup>, Laura Calabresi<sup>c</sup>, Chiara Pavanello<sup>c</sup>, Lorena Mosca<sup>d</sup>, Ugo Cavallari<sup>d</sup>, Ivana Vukovic Brinar<sup>a</sup>, Sandra Karanovic<sup>a</sup>, Mario Laganovic<sup>a,e</sup>, Bojan Jelakovic<sup>a</sup>

<sup>a</sup> Department of Nephrology, Arterial Hypertension, Dialysis and Transplantation, University Hospital Center Zagreb, University of Zagreb, School of Medicine, Kispaticeva 12, 10000, Zagreb, Croatia

<sup>b</sup> Department of Pathology, University Hospital Center Zagreb, University of Zagreb, School of Medicine, Kispaticeva 12, 10000, Zagreb, Croatia

<sup>c</sup> Center E. Grossi Paoletti, Department of Pharmacology, University of Milan, Via Balzaretti 9, 20133, Milan, Italy

<sup>d</sup> Medical Genetics Unit, Department of Services, ASST Grande Ospedale Metropolitano Niguarda, Piazza Ospedale Maggiore 3, 20162, Milan, Italy

<sup>e</sup> Department of Nephrology, University Hospital Merkur, University of Zagreb, School of Medicine, Zajceva 19, 10000, Zagreb, Croatia

### ARTICLE INFO

#### Article history:

Received 14 January 2022

Received in revised form

27 May 2022

Accepted 30 May 2022

Available online 2 June 2022

#### Keywords:

LCAT deficiency

Nephrotic syndrome

Gene variants

LCAT gene

### ABSTRACT

**Background and aims:** We report the first two cases of familial lecithin:cholesterol acyltransferase (LCAT) deficiency in Croatia with classical clinical and biochemical features.

**Patients and methods:** A 30-year-old man with nephrotic syndrome, corneal opacities, hepatosplenomegaly, anemia, low high-density lipoprotein (HDL)-cholesterol levels and arterial hypertension (blood pressure >200/100 mmHg) was admitted to our department. At admission, he had an elevated creatinine serum level (233 μmol/L), proteinuria of 12 g in 24-h urine (g/24 h), 3–7 erythrocytes in urine sediment and notable anemia (hemoglobin level 90 g/l). His HDL-cholesterol was significantly low (0.42 mmol/L). Besides chronic kidney disease (CKD), other secondary causes of hypertension were ruled out. The patient was previously diagnosed with membranous nephropathy and treated unsuccessfully with immunosuppressive agents (steroids, cyclosporine, cyclophosphamide). Re-evaluation of histopathological findings of kidney biopsy revealed massive deposition of lipid material in the glomerular basal membrane and in the mesangial region. His 4-year younger brother was also evaluated due to corneal opacities and new-onset arterial hypertension. Nephrotic range proteinuria with preserved global renal function was determined. He also had very low HDL-cholesterol levels.

**Results:** Kidney biopsies from both patients were consistent with LCAT deficiency. The disease was confirmed by measurement of LCAT enzyme activity, plasma cholesterol esterification rate, and genetic testing. Two novel missense variants in the LCAT gene (c.496G > A and c.1138T > C) were found.

**Conclusions:** To our knowledge, the presented cases are the first reported cases of genetic LCAT deficiency in Croatia. Given the clinical presentation, the complete lack of LCAT activity and cholesterol esterification rate, diagnosis of familial LCAT deficiency was made.

© 2022 The Authors. Published by Elsevier B.V. This is an open access article under the CC BY-NC-ND license (<http://creativecommons.org/licenses/by-nc-nd/4.0/>).

### Introduction

Familial lecithin:cholesterol acyltransferase (LCAT) deficiency is a rare autosomal recessive disorder, which was first described in a

Norwegian family by Gjone and Norum in 1968 [1,2]. It is characterized by the inability of LCAT enzyme to esterify cholesterol in plasma lipoproteins and it is a key player in the reverse cholesterol transport [2,3]. LCAT cleaves the fatty acid in sn-2 position of phosphatidylcholine and transfers it onto Ser181. That is followed by transesterification of the fatty acid to the 3-β-hydroxyl group on the A-Ring of cholesterol to form cholesteryl ester [4]. In normal individuals, the majority of plasma cholesteryl esters are produced by the LCAT reaction on HDL (alpha activity of LCAT), but LCAT may also act on apoB-containing lipoproteins (beta LCAT activity). Two

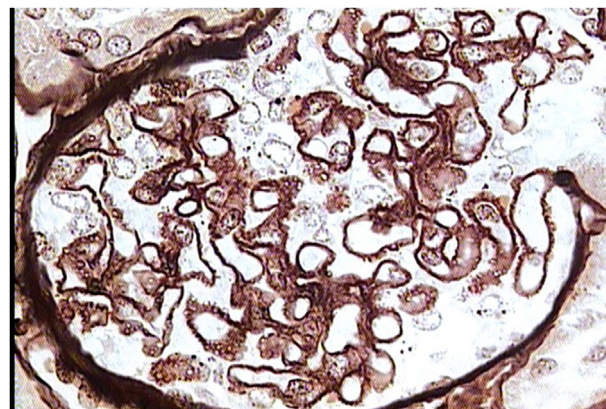
\* Corresponding author. Department of Nephrology, Arterial Hypertension, Dialysis and Transplantation, UHC Zagreb, Kispaticeva ulica 12, 10000, Zagreb, Croatia.

E-mail addresses: [margareta.fistrek@gmail.com](mailto:margareta.fistrek@gmail.com), [margareta.fistrek.prlc@kbc-zagreb.hr](mailto:margareta.fistrek.prlc@kbc-zagreb.hr) (M. Fistrek Prlic).

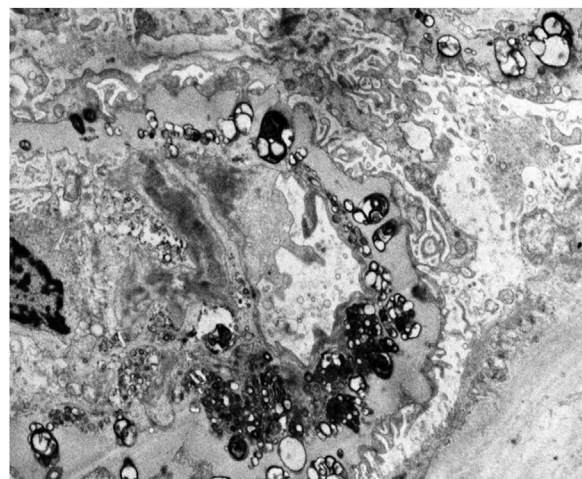
forms of LCAT deficiency have been described: a complete lack of LCAT activity, known as familial LCAT deficiency (FLD), where both alpha and beta activities are lost, and partial deficiency, called fish-eye disease (FED), where beta activity is retained [5,6]. Lack of LCAT results in increased serum unesterified cholesterol and its accumulation in the cornea, kidneys, spleen, liver, bone marrow and arteries. Extremely low HDL-cholesterol and corneal clouding are common features in both FLD and FED, but FLD cases in addition may also have proteinuria, renal failure, normochromic anemia and hepatosplenomegaly. The pathogenesis of renal disease in FLD is not entirely understood, but it is by all accounts related to the accumulation of abnormal lipoproteins, such as lipoprotein X (LpX) [7]. Cholesterol-laden foam cells are present in glomeruli and focal and segmental glomerulosclerosis may develop. Atherosclerosis and the risk for coronary heart disease in FLD patients are still controversial [8–11]. Renal disease is the main cause of mortality and morbidity in LCAT deficiency. Proteinuria develops early, but azotemia is usually detected only after the second decade of life, progressing to end-stage renal disease (ESRD) mostly by the fourth or fifth decade. Corneal opacities usually develop during childhood [12,13]. The disease may reoccur after kidney transplantation due to the persistence of metabolic disturbances [12]. Patients with familial LCAT deficiency display abnormal plasma lipid profiles and altered HDL subclasses distribution with the absence of mature HDL. HDL-cholesterol and apolipoprotein A-I levels are dramatically decreased, while total and low-density lipoprotein (LDL)-cholesterol and triglycerides are normal to elevated, and cholesterol esters/total cholesterol ratio is diminished [13]. Cholesterol esterification rate and LCAT activity are absent, while LCAT mass can be highly variable since some mutations primarily affect enzyme activity but not concentration [5]. Clinical diagnosis can be made by measuring LCAT activity and confirmed by molecular analysis for the presence of homozygous or compound heterozygous *LCAT* gene variants. Lipid depositions detected on kidney biopsy specimens are characteristic, but not specific for LCAT deficiency since similar lipid deposits occur in hepatic glomerulopathy in patients with chronic liver disease [14]. Curative therapy is still not available. The Human Gene Mutation Database (HGMD®) currently compiles 102 functionally relevant *LCAT* variants, including 81 missense/nonsense point mutations (<http://www.hgmd.cf.ac.uk>; last accessed on July 7, 2020). In this report, we describe the clinical course of the first Croatian family with classic LCAT deficiency carrying two novel pathogenetic variants in *LCAT* gene.

## Patients and methods

A 30-year-old man was admitted to our hospital due to nephrotic syndrome and hypertensive crisis. Previously, at the age of 19, he was diagnosed with membranous nephropathy and was unsuccessfully treated with immunosuppressive agents (steroids, cyclophosphamide, cyclosporine). Upon admission, physical examination revealed corneal opacities, increased blood pressure, hepatosplenomegaly, pleural effusions, and edema of the lower extremities. Normochromic anemia was also present (hemoglobin value 90 g/L). Abdominal ultrasound revealed enlarged liver and spleen while kidneys appeared normal. Apart from chronic kidney disease, other causes of secondary hypertension were ruled out. Cytologic bone marrow analysis showed normal hematopoietic tissue, with no signs of hemolysis in peripheral blood smear. Anemia has partially improved as a result of iron supplement therapy (follow-up hemoglobin value was 99 g/L). Clinical presentation and treatment-resistant membranous nephropathy made us request re-evaluation of histopathological findings of kidney biopsy, which revealed classic features of LCAT deficiency, with massive



**Fig. 1.** Kidney histopathology analysis (light microscopy, Jones silver stain - magnification 630x) showing thick glomerular basement membranes with bubbly and honeycomb appearance due to massive deposition of lipid material - classic features of LCAT deficiency.



**Fig. 2.** Electron microscopy of the patient's kidney showing lipid deposits in mesangial matrix and glomerular basement membrane (magnification 5600x).

deposition of lipid material in the glomerular basal membrane, and in the mesangial region (shown in [Figs. 1 and 2](#)).

The proband was treated with diuretics, antihypertensives, iron supplements, and erythropoietin. Patient has never taken lipid-lowering drugs. His renal function declined gradually and 4 years later (15 years after initial presentation) he started with regular hemodialysis sessions. Although initially combined kidney and split liver transplantation was considered, we opted for kidney transplantation only due to the insufficient evidence data supporting combined transplantation.

Laboratory analyses were performed on fasting blood samples and urine at admission and at a following visit. A complete lipid-lipoprotein profile (total cholesterol, HDL-cholesterol, triglycerides, apoA-I, apoA-II and apoB) was determined using a Roche Integra c311 analyzer. LDL-cholesterol was calculated by the Friedewald's formula. Plasma unesterified cholesterol and phospholipids were determined by standard enzymatic techniques [12]. Plasma LCAT activity and cholesterol esterification rate (CER) were measured as previously described [10]. Estimated glomerular filtration rate (eGFR) was calculated using the 2009 CKD-EPI creatinine equation. Standard processing of kidney biopsy samples included light microscopy, immunofluorescence and transmission electron microscopy. Genetic analysis was performed by

direct sequencing of coding exons and exon-intron junction regions of *LCAT* gene (NM\_000229).

## Results

The patient's laboratory parameters at admission and at a following visit are shown in Table 1 and Table 2.

Laboratory investigations in the proband showed reduced HDL-cholesterol levels, hypertriglyceridemia and increased unesterified to total cholesterol ratio. Absence of *LCAT* activity and CER suggested a complete *LCAT* deficiency. Genetic analysis showed that the proband was compound heterozygous for two novel *LCAT* variants: a nucleotide transition in exon 4 (c.496G > A) which results in a substitution of Alanine 166 with a Threonine and a nucleotide transition in exon 6 (c.1138T > C), resulting in an Arginine to Cysteine at the codon 380. Both variants have not been previously reported in disease/mutation databases (ClinVar, HGMD, LOVD) and have a very low allele frequency (AF) in population databases (gnomAD AF: 0.0000088); moreover, *in silico* computational prediction of variants' role is pathogenic.

**Table 1**  
Patient's laboratory findings at admission (Proband).

Laboratory parameter	Patient's value	Reference values
Hemoglobin (g/l)	90	138–175
Serum creatinine (μmol/l)	233	49–90
eGFR <sup>a</sup> (ml/min/1.73m <sup>2</sup> )	32	>60
Proteinuria (g/24 h) <sup>b</sup>	12	<0.25
Erythrocytes in urine sediment	3–7	0–2
Total cholesterol (mmol/l)	8.3	<5.0
HDL-cholesterol <sup>c</sup> (mmol/l)	0.42	>1
Triglycerides (mmol/l)	16.58	<1.7
Ferritin (μg/l)	26.6	30–400
C3 complement (g/l)	0.77	0.9–1.8
C4 complement (g/l)	0.21	0.1–0.4
ANA <sup>d</sup>	negative	<1:100
ANCA <sup>e</sup>	negative	<1:20
HIV <sup>f</sup> serology (s/c)	negative	<1
Hepatitis B serology – HbsAg <sup>g</sup> (s/c)	negative	<1
Hepatitis C serology (s/c)	negative	<1

<sup>a</sup> eGFR- Estimated Glomerular Filtration Rate.

<sup>b</sup> g/24 h – Grams in 24-h Urine.

<sup>c</sup> HDL-cholesterol – High Density Lipoprotein Cholesterol.

<sup>d</sup> ANA- Antinuclear Antibody.

<sup>e</sup> ANCA- Antineutrophil Cytoplasmic Antibody.

<sup>f</sup> HIV- Human Immunodeficiency Virus.

<sup>g</sup> HbsAg – Hepatitis B Surface Antigen.

**Table 2**  
Lipid and lipoprotein profiles of the family.

Laboratory parameter	Proband	Brother	Father	Mother	Reference values
Total cholesterol (mmol/L)	4.70	2.73	4.4	4.4	3.5–5.2
Unesterified cholesterol (mmol/L)	3.97	2.32	NA <sup>a</sup>	NA <sup>a</sup>	<1.55
Unesterified/total cholesterol (%)	84.5	85.0	NA <sup>a</sup>	NA <sup>a</sup>	0.25
HDL <sup>b</sup> cholesterol (mmol/L)	0.23	0.22	0.45	0.91	>1
Triglycerides (mmol/L)	7.36	1.85	2.7	1.2	<1.71
Apolipoprotein A-I (mg/dL)	45	52	NA <sup>a</sup>	NA <sup>a</sup>	115–180
Apolipoprotein A-II (mg/dL)	4	6	NA <sup>a</sup>	NA <sup>a</sup>	26–51
Apolipoprotein B (mg/dL)	89	27	NA <sup>a</sup>	NA <sup>a</sup>	70–150
<i>LCAT</i> <sup>c</sup> activity (nmol/mL/h)	0	0	NA <sup>a</sup>	NA <sup>a</sup>	25–55
CER <sup>d</sup> (nmol/mL/h)	0	0	NA <sup>a</sup>	NA <sup>a</sup>	30–60

<sup>a</sup> NA-not available.

<sup>b</sup> HDL -high-density lipoprotein.

<sup>c</sup> *LCAT*-lecithin:cholesterol acyltransferase.

<sup>d</sup> CER-cholesterol esterification rate.

Proband's father was a heterozygous carrier of the exon 4 (c.496G > A) variant, while proband's mother was heterozygous for the variant of exon 6 (c.1138T > C). Apart from a reduction in HDL-cholesterol levels, his father had no other signs of the disease (Table 2). His mother was healthy. The patient's younger brother (age 27) also had corneal opacities and newly diagnosed arterial hypertension. A routine checkup was performed at our hospital and revealed nephrotic range proteinuria (7.05 g/dU) without overt nephrotic syndrome, and with preserved kidney function (serum creatinine was 77 μmol/L with eGFR 118.4 ml/min/1.73 m<sup>2</sup>). His blood pressure is well controlled using five different antihypertensive agents and his red blood cell count is within the lower normal range. Mild hepatosplenomegaly, low HDL-cholesterol levels (0.24 mmol/L), and elevated triglycerides (4.28 mmol/l) were detected. *LCAT* enzyme activity was absent and CER was undetectable (Table 2). A kidney biopsy confirmed the diagnosis. Genetic analysis revealed that the brothers are carriers of the same genetic variants in the *LCAT* gene.

## Discussion

To our knowledge, the presented cases are the first reported cases of genetic *LCAT* deficiency in Croatia. Given the clinical presentation of the patients, the complete lack of *LCAT* activity, and CER we can conclude that they suffer from familial *LCAT* deficiency. The two *LCAT* gene variants detected in our patients have never been described before in public databases. Their clinical courses differed as the second brother still has preserved global renal function despite the same variants and undetectable *LCAT* enzyme activity and CER in both patients. However, such distinctions were already described in the literature [15]. An additional contribution to the more rapid course of kidney failure in the first case may be the use of immunosuppressants with potential nephrotoxic effect. As reported by Pavanello et al., CKD progression is faster for higher levels of unesterified cholesterol and this could also be the case in our patients [12]. Attempts to find an effective treatment for *LCAT* deficiency are underway. Enzyme replacement therapy (ERT) with recombinant *LCAT* is certainly an option, and it is currently under clinical development. It can restore *LCAT* activity and reduce circulating unesterified cholesterol, however, its effect on renal disease is not convincing [16]. Gene therapy could also be an option, but it has not been tested in humans yet [17]. Treatment with HDL mimetic CER-001 was recently found to be effective in stabilizing kidney function and improving vision disturbances [18,19]. Renal failure replacement methods such as hemodialysis, peritoneal dialysis, or kidney transplantation remain the therapy for renal failure. There is a risk of recurrence of the disease in the graft, but according to previous knowledge, the duration of the kidney transplant function is not significantly shortened [20,21]. Recent data have demonstrated that the median time of kidney graft failure in *LCAT* deficiency is 10 years [12]. Combined liver and kidney transplantation was performed once and no advantage was demonstrated over kidney transplantation alone [22].

## Author contributions

**Margareta Fistrek Prlic** – substantial contribution to the conception of the work, interpretation of findings, drafting the work, final approval of the report. **Marijana Coric** - acquisition and analysis of kidney biopsy material, interpretation of findings, critical revising of data for the work, final approval of the report. **Laura Calabresi** - substantial contribution to the conception of the work, interpretation of data, critical revising of the work, final approval of the report. **Chiara Pavanello** - substantial contributions to the conception of the work, acquisition and analysis of blood samples



for enzyme activity, lipid and lipoprotein profiles, interpretation of data, critical revising of the work, final approval of the report. **Lorena Mosca** - analysis of blood samples for genetic study, interpretation of data, critical revising of the work, final approval of the report. **Ugo Cavallari** - analysis of blood samples for genetic study, interpretation of data, critical revising of the work, final approval of the report. **Ivana Vukovic Brinar** - interpretation of findings, drafting the work, final approval of the report. **Sandra Karanovic** - interpretation of findings, drafting the work, final approval of the report. **Mario Laganovic** - acquisition of kidney biopsy material, interpretation of findings, drafting the work, final approval of the report. **Bojan Jelakovic** - interpretation of findings, drafting the work, final approval of the report.

### Declaration of competing interest

Margareta Fistrek Prlic – none, Marijana Coric – none, Laura Calabresi – none, Chiara Pavanello – none, Lorena Mosca – none, Ugo Cavallari – none, Ivana Vukovic Brinar – none, Sandra Karanovic – none, Mario Laganovic–none, Bojan Jelakovic–none.

### References

- [1] Utermann G, Menzel H, Dieker P, et al. Lecithin cholesterol acyltransferase deficiency: autosomal recessive transmission in large kindred. *Clin Genet* 1981;19:448–55.
- [2] Gjone E, Norum K. Familial serum cholesterol ester deficiency. *Acta Med Scand* 1968;183:107–12.
- [3] Assmann G, Von Eckardstein A, Funke H. Lecithin cholesterol acyltransferase deficiency and fish eye disease. *Curr Opin Lipidol* 1991;2:110–7.
- [4] Glomset J. The plasma cholesterol: acyltransferase reaction. *J Lipid Res* 1968;9:155–67.
- [5] Chen C, Albers J. Distribution of lecithin cholesterol acyltransferase (LCAT) in human plasma lipoprotein fractions. Evidence for the association of active LCAT with low density lipoproteins. *Biochem Biophys Res Commun* 1982;107:1091–6.
- [6] Carlson L, Holmquist L. Evidence for the presence in human plasma of lecithin cholesterol acyl transferase activity (beta LCAT) specifically esterifying free cholesterol of combined pre beta and beta lipoproteins. Studies of fish eye disease patients and control subject. *Acta Med Scand* 1985;218:197–205.
- [7] Ossoli A, Neufeld E, Thacker S, et al. Lipoprotein X causes renal disease in LCAT deficiency. *PLoS One* 2016;11(2):e0150083.
- [8] Gomasarshi M, Ossoli A, Castelnovo S, et al. Depletion in LpA-I: A-II particles enhances HDL-mediated endothelial protection in familial LCAT deficiency. *J Lipid Res* 2017;58(5):994–1001.
- [9] Oldoni F, Baldassarre D, Castelnovo S, et al. Complete and partial lecithin: cholesterol acyltransferase deficiency is differentially associated with atherosclerosis. *Circulation* 2018;138(10):1000–7.
- [10] Calabresi L, Pisciotta L, Costantin A, et al. The molecular basis of lecithin: cholesterol acyltransferase deficiency syndromes. *Arterioscler Thromb Vasc Biol* 2005;25(9):1972–8.
- [11] Hovingh GK, de Groot E, van der Steeg W, et al. Inherited disorders of HDL metabolism and atherosclerosis. *Curr Opin Lipidol* 2005;16(2):139–45.
- [12] Pavanello C, Ossoli A, Arca M, et al. Progression of chronic kidney disease in familial LCAT deficiency: a follow-up of the Italian cohort. *J Lipid Res* 2020;61(12):1784–8.
- [13] Pavanello C, Calabresi L. Genetic, biochemical, and clinical features of LCAT deficiency: update for 2020. *Curr Opin Lipidol* 2020;31(4):232–7.
- [14] Najafian B, Lusco MA, Finn LS, et al. AJKD Atlas of renal pathology: lecithin-cholesterol acyltransferase (LCAT) deficiency. *Am J Kidney Dis* 2017;70(1):5–6.
- [15] Castro-Ferreira I, Carmo R, Silva S, et al. Novel missense LCAT gene mutation associated with an atypical phenotype of familial LCAT deficiency in two Portuguese brothers. *J Inherit Metab Dis* 2018;40:55–62.
- [16] Shamburek R, Bakker-Arkema R, Auerbach B, et al. Familial lecithin:cholesterol acyltransferase deficiency: first-in-human treatment with enzyme replacement. *J Clin Lipidol* 2016;10(2):356–67.
- [17] Amar M, Shamburek R, Vaisman B, et al. Adenoviral expression of human lecithin-cholesterol acyltransferase in nonhuman primates leads to an anti-atherogenic lipoprotein phenotype by increasing high-density lipoprotein and lowering low-density lipoprotein. *Metabolism* 2009;58:568–75.
- [18] Pavanello C, Turri M, Strazzella A, et al. The HDL mimetic CER-001 remodels plasma lipoproteins and reduces kidney lipid deposits in inherited lecithin: cholesterol acyltransferase deficiency. *J Intern Med* 2021;1–7.
- [19] Faguer S, Colombat M, Chauveau D, et al. Administration of the high-density lipoprotein mimetic CER-001 for inherited lecithin–cholesterol acyltransferase deficiency. *Ann Intern Med* 2021;174(7):1022–5.
- [20] Horina H, Wirnsberger G, Horn S, et al. Long-term follow-up of a patient with lecithin cholesterol acyltransferase deficiency syndrome after kidney transplantation. *Transplantation* 1993;56:233–6.
- [21] Strøm EH, Sund S, Reier-Nilsen M, et al. Lecithin: cholesterol Acyltransferase (LCAT) Deficiency: renal lesions with early graft recurrence. *Ultrastruct Pathol* 2011;35(3):139–45.
- [22] Ahmad S, Miller M, Hanish S, et al. Sequential kidney-liver transplantation from the same living donor for lecithin cholesterol acyl transferase deficiency. *Clin Transplant* 2016;30(10):1370–4.