

Isolated unilateral oculomotor nerve neuropraxia following a trivial fall in a patient with calcified posterior petroclinoid ligament

Maneesha Anil Patwardhan

Department of Surgery, Jawaharlal Nehru Medical College, DMIMS, Wardha, Maharashtra, India

ABSTRACT

Isolated traumatic oculomotor nerve palsy caused by a trivial fall is extremely rare. We report a case of this condition. A 49-year-old woman had distal radius fracture and ptosis on the same side after having a trivial domestic fall. She did not show any clinical or radiological signs of head injury. Computerized tomography revealed a calcified posterior petroclinoid ligament which has direct anatomical and pathological relation with the oculomotor nerve.

Key words: Calcified petroclinoid ligament, neuropraxia, traumatic oculomotor nerve praxia

Introduction

Oculomotor nerve palsy has been known clinical entity following direct injury of the nerve or by indirect compression of the nerve by an expanding supratentorial hematoma. Direct traumatic isolated oculomotor nerve palsy is relatively rare and commonly associated with subarachnoid hemorrhage, skull fracture, aneurysm, carotid-cavernous fistula or midbrain lesion.^[1-3] Traumatic isolated oculomotor nerve palsy with negative imaging studies is extremely rare. There are very few cases reported in the literature in which Brain computerized tomography (CT) and magnetic resonance imaging were normal.^[4,5] We hereby report a case of isolated oculomotor nerve praxia associated without any clinical and radiological signs of head injury. The calcified petroclinoid ligament (PCL) was the only radiological finding. The patient was informed that data concerning the case would be published in the journal, and she consented.

Case Report

A 49-year-old woman was brought to the accident and emergency department with history of a fall and ended up with right side of the face hitting the floor, while doing household work. She did not lose consciousness, neither had any episode of memory loss, nausea nor bleeding from nose, mouth and ear. On examination, she was oriented, and Glasgow coma Scale was 15/15. Her vital signs were normal. Left sided ptosis with dilated pupil was noted. There were abrasions and lacerated wounds over her right cheek and chin [Figure 1]. Her cardiovascular system, respiratory system and nervous system were clinically normal. Radiographs of the skull, cervical spine, and chest were normal. Computed tomography of the head and Magnetic resonance imaging of the brain ruled out head injury. The CT scan was again reviewed by a neuroradiologist who revealed calcified posterior PCLs on both the sides [Figure 2a and b]. Her urinary fluoride level was 4.5 mg/l; however, she did not show radiological signs of skeletal fluorosis. Patient was treated conservatively for her ophthalmic complaints and did not receive any surgical intervention for the same. At the end of 8 months follow-up, the ptosis recovered completely with occasional complaints of headache and her pupillary reflex also returned to normal [Figure 3a and b].

Discussion

When isolated third nerve palsies occur, the closed head injury sufficient to cause such palsies almost always entails a loss of consciousness or fractured skull. Traumatic isolated oculomotor nerve palsy with unremarkable imaging studies is extremely rare.^[4-6] Literature shows variable incidence of isolated oculomotor nerve palsy ranging from 0.1% to 15%.^[7-9]

Access this article online	
Quick Response Code:	Website: www.asianjns.org
	DOI: 10.4103/1793-5482.151523

Address for correspondence:

Dr. Maneesha Anil Patwardhan, Department of Surgery, Jawaharlal Nehru Medical College and Acharya Vinoba Bhave Rural Hospital, DMIMS, Wardha - 442 004, Maharashtra, India. E-mail: maneeshap@gmail.com

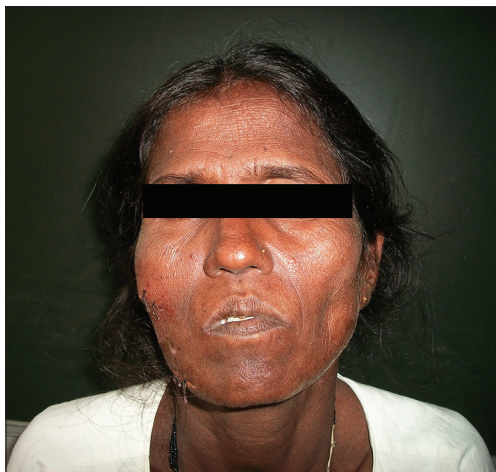

Figure 1: A 49-year-old woman had ptosis on the left side immediately after trivial fall. She also had minor wounds over her right cheek and chin

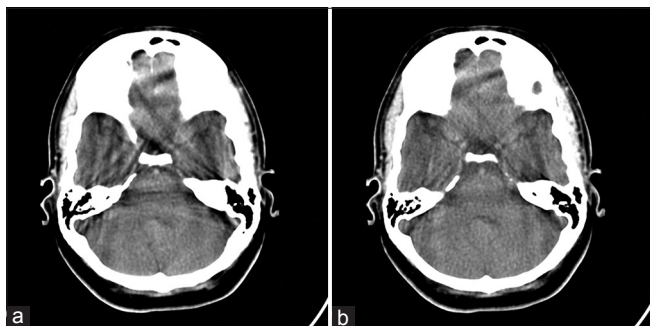


Figure 2: (a and b) Computerized tomography of the 49-year-old female revealed calcified posterior petroclinoid ligaments on both sides

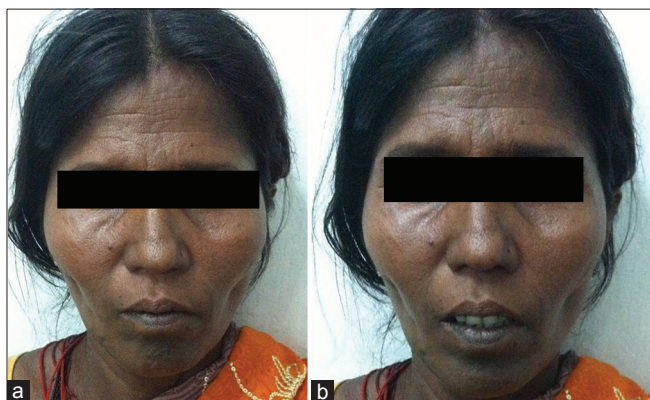

Figure 3: (a and b) Eight months follow-up of the lady who sustained traumatic isolated oculomotor nerve injury on the left side showed complete recovery of ptosis with minor residual squint

However, negative CT scan finding and degree of head injury was not mentioned in some of the studies.^[3] Minor head trauma may, however precipitate oculomotor nerve palsy in patients with occult intracranial mass lesion because of the mechanical stress.^[3]

Mechanism of traumatic oculomotor nerve palsy seems to be because of differential and then paradoxical movements

between the brainstem and supratentorial structures, which can cause rootlet avulsion. The distance the oculomotor nerve travels after its exit from the brainstem is relatively shorter than the neighboring cranial nerves exiting through the superior orbital fissure.^[4] During its course, it runs over a tough posterior PCL where it is more prone to get stretched against PCL when the brainstem shifts downwards at the moment of impact to the head.^[2,7,9] In the consequence, it may cause internal ophthalmoplegia because of an injury to the pupillomotor fibers on the ventromedial surface of the oculomotor nerve.^[2,6,7,9] In cases with calcified PCL tensile property of ligament is lost and the PCL acts as a fulcrum and the impact on the oculomotor nerve increases to cause neural trauma. The age of the patient can be closely correlated with the degree of calcification of PCL.^[10] In general, fluorosis is one of the attributable factors for calcification of ligaments.^[8] However, literature does not support calcification of ligaments of skull due to fluorosis. Our patient did not even show any skeletal signs of fluorosis on radiograph; even though the patient lived in the endemic zone of fluorosis and urinary fluoride level was on a higher side. In our patient however, the CT scan clearly demonstrated the calcified PCLs [Figure 2a and b] and this could be the possible explanation of nerve injury without any clinical and radiological evidence of head injury.

Due to distinct rarity of this clinical presentation and paucity of literature; treatment of traumatic isolated oculomotor nerve palsy has not been well defined. Furthermore, the poor prognosis of traumatic oculomotor nerve injury makes functional outcome guarded.^[11] Our patient however recovered completely. It can be believed that the injury to pupillomotor fibers of the oculomotor nerve must not have been severe enough to cause permanent or long-term disability.

It can be concluded from our case that mechanical traction on oculomotor nerve against calcified posterior PCL which acts as a fulcrum, may lead to neuropraxia of the oculomotor nerve without having any clinical and radiological signs of head trauma. Complete recovery can be expected in such type of injury of oculomotor nerve.

References

1. Balcer LJ, Galetta SL, Bagley LJ, Pakola SJ. Localization of traumatic oculomotor nerve palsy to the midbrain exit site by magnetic resonance imaging. *Am J Ophthalmol* 1996;122:437-9.
2. Nagaseki Y, Shimizu T, Kakizawa T, Fukamachi A, Nukui H. Primary internal ophthalmoplegia due to head injury. *Acta Neurochir (Wien)* 1989;97:117-22.
3. Walter KA, Newman NJ, Lessell S. Oculomotor palsy from minor head trauma: Initial sign of intracranial aneurysm. *Neurology* 1994;44:148-50.
4. Muthu P, Pritty P. Mild head injury with isolated third nerve palsy. *Emerg Med J* 2001;18:310-1.
5. Chen CC, Pai YM, Wang RF, Wang TL, Chong CF. Isolated oculomotor nerve palsy from minor head trauma. *Br J Sports Med* 2005;39:e34.
6. Takeuchi S, Takasato Y, Masaoka H, Hayakawa T, Otani N,

- Yoshino Y, *et al.* Isolated traumatic oculomotor nerve palsy caused by minor head trauma. *Brain Nerve* 2008;60:555-8.
7. Skrzat J, Walocha J, Jaworek JK, Mróz I. The clinical significance of the petroclinoid ligament. *Folia Morphol (Warsz)* 2007;66:39-43.
 8. Wang Y, Yin Y, Gilula LA, Wilson AJ. Endemic fluorosis of the skeleton: Radiographic features in 127 patients. *AJR Am J Roentgenol* 1994;162:93-8.
 9. Mariak Z, Mariak Z, Stankiewicz A. Cranial nerve II-VII injuries in fatal closed head trauma. *Eur J Ophthalmol* 1997;7:68-72.
 10. Cederberg RA, Benson BW, Nunn M, English JD. Calcification of the interclinoid and petroclinoid ligaments of sella turcica: A radiographic study of the prevalence. *Orthod Craniofac Res* 2003;6:227-32.
 11. Tokuno T, Nakazawa K, Yoshida S, Matsumoto S, Shingu T, Sato S, *et al.* Primary oculomotor nerve palsy due to head injury: Analysis of 10 cases. *No Shinkei Geka* 1995;23:497-501.

How to cite this article: Patwardhan MA. Isolated unilateral oculomotor nerve neuropraxia following a trivial fall in a patient with calcified posterior petroclinoid ligament. *Asian J Neurosurg* 2015;10:56.

Source of Support: Nil, **Conflict of Interest:** None declared.

