



## Research Article

# Risk factors for tissue expander infection in scar reconstruction: a retrospective cohort study of 2374 consecutive cases

Chen Dong<sup>1</sup>, Minhui Zhu<sup>2</sup>, Luguang Huang<sup>3</sup>, Wei Liu<sup>1</sup>, Hengxin Liu<sup>1</sup>, Kun Jiang<sup>3</sup>, Zhou Yu<sup>1,\*</sup> and Xianjie Ma<sup>1,\*</sup>

<sup>1</sup>Department of Plastic Surgery, Xijing Hospital, Fourth Military Medical University, Xi'an, 710032, Shaanxi, People's Republic of China, <sup>2</sup>Department of Burn and Plastic Surgery, the Sixth Medical Center of Chinese PLA General Hospital, Beijing, 100048, People's Republic of China and <sup>3</sup>Information Center, Xijing Hospital, Fourth Military Medical University, Xi'an, 710032, Shaanxi, People's Republic of China

\*Correspondence. Zhou Yu, Email: yz20080512@163.com; Xianjie Ma, Email: majing@fmmu.edu.cn

Received 23 May 2020; Revised 7 July 2020; Editorial decision 24 August 2020

## Abstract

**Background:** Tissue expansion is used for scar reconstruction owing to its excellent clinical outcomes; however, the complications that emerge from tissue expansion hinder repair. Infection is considered a major complication of tissue expansion. This study aimed to analyze the perioperative risk factors for expander infection.

**Methods:** A large, retrospective, single-institution observational study was carried out over a 10-year period. The study enrolled consecutive patients who had undergone tissue expansion for scar reconstruction. Demographics, etiological data, expander-related characteristics and post-operative infection were assessed. Univariate and multivariate logistic regression analysis were performed to identify risk factors for expander infection. In addition, we conducted a sensitivity analysis for treatment failure caused by infection as an outcome.

**Results:** A total of 2374 expanders and 148 cases of expander infection were assessed. Treatment failure caused by infection occurred in 14 expanders. Multivariate logistic regression analysis identified that disease duration of  $\leq 1$  year (odds ratio (OR), 2.07;  $p < 0.001$ ), larger volume of expander (200–400 ml vs  $< 200$  ml; OR, 1.74;  $p = 0.032$ ;  $> 400$  ml vs  $< 200$  ml; OR, 1.76;  $p = 0.049$ ), limb location (OR, 2.22;  $p = 0.023$ ) and hematoma evacuation (OR, 2.17;  $p = 0.049$ ) were associated with a high likelihood of expander infection. Disease duration of  $\leq 1$  year (OR, 3.88;  $p = 0.015$ ) and hematoma evacuation (OR, 10.35;  $p = 0.001$ ) were so related to high risk of treatment failure.

**Conclusions:** The rate of expander infection in patients undergoing scar reconstruction was 6.2%. Disease duration of  $< 1$  year, expander volume of  $> 200$  ml, limb location and postoperative hematoma evacuation were independent risk factors for expander infection.

**Key words:** Tissue expansion, Tissue expander, Scar reconstruction, Risk factors, Infection

## Highlights

- A large retrospective observational study carried out over a 10-year period including 2374 expanders.
- Disease duration, expander volume, expander site, and haematoma evacuation were related to expander infection.
- Recommendation regarding prevention and management of expander infection according to authors' experience.

## Background

Tissue expansion was first introduced by Neumann in 1957; its widespread clinical application began after Radovan's representation in 1976 [1, 2]. Scars, which are often reconstructed by tissue expansion, are the sequelae of burn, trauma or surgery [3, 4]. Scars can decrease quality of life for patients and delay reintegration into society due to their perceived appearance causing psychosocial distress [5]. Each year, 100 million patients acquire scars in the developed world, and \$12 billion was spent on an anti-scarring drug in the USA alone in 2008 [6, 7]. Although many non-surgical treatments can improve quality of life and the symptoms of scars, none can eliminate scars completely [8]. Given the excellent color and texture match that can be achieved, and the minimal donor-site morbidity of expanded flaps, tissue expansion is often preferred for scar reconstruction [9]. Despite these benefits, a significant hindrance of tissue expansion approaches is the length of time they take and the fact that they require surgery to insert and remove the expander [10]. Moreover, the incidence of complications emerging from tissue expansion varies between 4.0% and 63.0% (mean = 17.4%), according to a systematic review [11]. Once unsalvageable complications occur, the treatment purpose may not be achieved, and new injuries and scars may appear.

Infection is a major threat to the success of tissue expansion; the incidence of infection ranges from 1.4% to 35.4% in previous studies of patients undergoing scar reconstruction [12–18]. The published literature has analyzed possible risk factors for expander infection, including age, gender, body mass index (BMI), prolonged drain use, smoking and radiation therapy, but these studies have presented discrepant conclusions [11, 19–21]. For example, in children, an age of less than 10 years has been shown to be a risk factor, while other studies have found no difference in complication rates between adult and pediatric populations [18, 22]. These discrepancies may be due to small sample sizes, varying definitions of important indicators and differences in surgical methods. Moreover, previous large-sample studies mainly focused on complication risks of expander-based breast reconstruction rather than scar reconstruction [20, 23, 24].

Based on the Clavien–Dindo classification of surgical complications, an infection of Grade II or higher was chosen as the primary outcome in the present study [25]. The cases were considered as expander infection if the following conditions were satisfied: additional antibiotic treatment; unscheduled debridement surgery; or premature removal of tissue expanders because of surgical site infection, but excluding slightly local redness, swelling and bedside drainage. Identifying risk factors for infection can inform potential treatment strategies to reduce the incidence of infection. Thus, we reviewed 2374 consecutive cases of tissue expansion for scar reconstruction over a 10-year period to identify perioperative risk factors for infection from 12 variables.

## Methods

### Study design

We identified a retrospective cohort of consecutive patients who underwent expander implantation between 1 January 2009 and 31 December 2018 at a single center (Department of Plastic Surgery, Xijing Hospital). Patients were excluded if they: (1) suffered from unrelated diseases to the extent that normal expansion was disturbed; (2) requested suspension of the expansion for non-medical reasons; or (3) censored key data (e.g. expander volume) for any reason. The study was approved by the ethics committee at Xijing hospital (KY20192155-C-1) and was preregistered in the Chinese Clinical Trial Registry (ChiCTR1900027702).

All variables were collected using the hospital information system (HIS) and extracted using dedicated software (designed by HL and KJ) for tissue expansion. The data were inspected by two independent researchers. Predictors included age, gender, causes, disease duration, preoperative red blood cell (RBC) count, preoperative white blood cell (WBC) count, surgical duration, expander number, expander size, expander location, initial fill volume ratio (initial fill/actual volume) and postoperative hematoma evacuation. The primary outcome was the occurrence of expander infection (beyond Grade II) at least once at any point until the expanded flaps were elevated. The secondary outcome was treatment failure caused by uncontrollable infection. In this situation, the expander had to be removed and tissue expansion was ended. Risk factors and the complication rates were estimated based on each expander.

### Surgical technique

The preoperative design was based on the areas and locations of the lesions. Incisions were made at 1–2 cm from the side of the scar or at the junction between the scar and the normal skin. The length of the incision was 3–7 cm, and the incision was positioned parallel to the long axis of the expander in most cases. The depth of tissue dissection was uniform and depended on the donor and recipient sites. Expanders were inserted between the galea aponeurotica and the periosteal surface in the scalp; beneath the frontal muscle in the forehead; in the superficial layer of the superficial musculo-aponeurotic system in the cheek; beneath the retroauricular fascia in the posterior auricular; in the superficial or deep side of the platysma in the neck; or beneath the deep fascia in the trunk or limbs. The pocket was 0.5–1.0 cm larger than the periphery of the expanders, enabling it to be fully flattened after insertion. All injection ports were external. Negative-pressure drainage was applied routinely. To prevent expanders from displacement under the incision, subcutaneous tissue was sutured approximately 1 cm from the incision and the skin was sutured in layers. Routine bandaging, with appropriate levels of pressure, was applied postoperatively in each case. Intravenous antibiotics were

given for 3–5 days, and the drainage tube was removed on either the second or third day after surgery. The suture was removed on day 8–12 after surgery. The first fluid injection into the expander was administered on the third to fifth day after surgery, then once or twice a week thereafter in the outpatient clinic for several months.

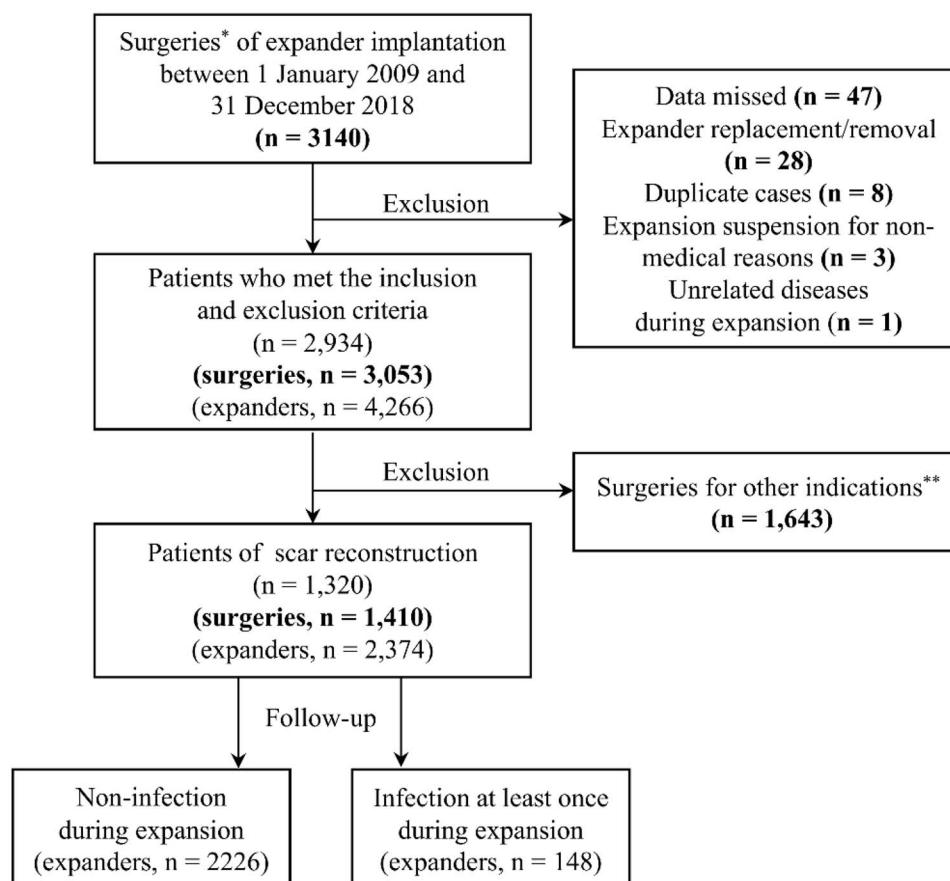
### Statistical analysis

Descriptive data is presented as mean  $\pm$  standard deviation, median (minimum, maximum) or frequencies and proportions, as appropriate, by surgeries. Differences between the groups with or without infection, in terms of their demographic and clinical characteristics, were estimated based on the expander used. The complication rate was also calculated based on the expander. Univariate analysis was conducted using logistic regression modeling. Univariate significance at the level of  $p < 0.1$  was considered for entry into a multivariate logistic regression model. The criterion to remain in the model was  $p < 0.05$ . Furthermore, for validating the robustness of the model mentioned above, we conducted a sensitivity analysis using logistic regression modeling for

treatment failure caused by infection. All statistical analyses were conducted using SPSS (version 25.0, IBM, NY, USA).

### Results

A total of 1320 patients and 1410 surgeries were included in the study (Figure 1). The average age of patients was  $21.5 \pm 9.4$  years. A total of 629 (44.6%) patients were female. The main cause of scarring was thermal burns ( $n = 1017$ , 72.1%). The length of time from wound healing to the time of surgery was recorded as the disease duration (median = 13.0; range = <1–52 years). Approximately 90% of preoperative laboratory results were within the reference range (RBC,  $n = 1287$ , 91.3%; WBC,  $n = 1279$ , 90.7%). The median surgical duration of expander insertion was 70 (15, 585) minutes. In 51.5% of cases one expander was inserted ( $n = 726$ ); 33.9% had two inserted and 14.6% had three or more inserted ( $n = 478$  and 206, respectively). In terms of anatomical locations where expanders were placed, these were: scalp, 31.1% ( $n = 438$ ); trunk, 28.8% ( $n = 406$ ); face, 19.5% ( $n = 275$ ); multiple locations, 12.1% ( $n = 171$ ); limbs, 4.5% ( $n = 64$ ); and neck, 4.0% ( $n = 56$ ). The median total



**Figure 1.** Flow diagram of the 1410 cases (2374 expanders) who underwent tissue expansion for scar reconstruction over a 10-year period. \*In one surgery, expander number may be one or more according to practical need. \*\*Other indications include microtia reconstruction, breast reconstruction, penile reconstruction, trauma, etc.

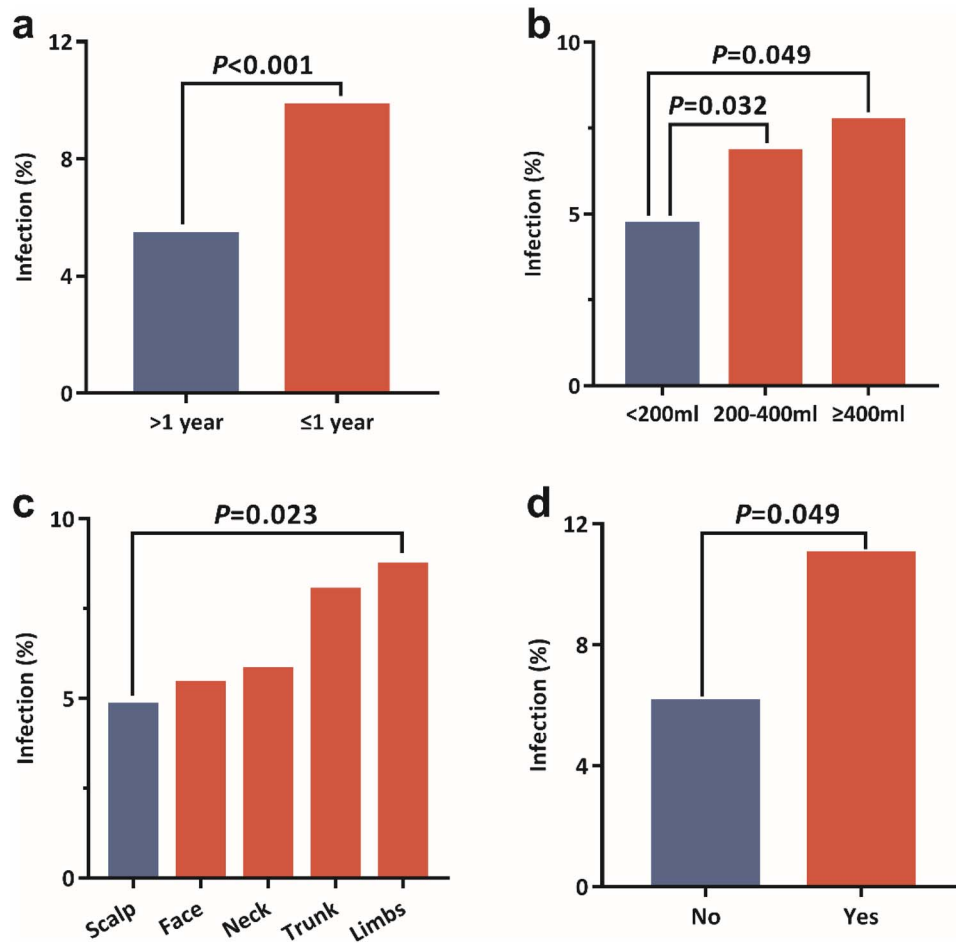
**Table 1.** Differences between the groups without or with infection in terms of their demographic and clinical characteristics by expanders

Variable	Tissue expander infection, n(%)		Total, n(%) n = 2374	P
	No (n = 2226)	Yes (n = 148)		
Age, years				
<18	718 (32.3)	55 (37.2)	773 (32.6)	1 (reference)
18–40	1414 (63.5)	84 (56.8)	1498 (63.1)	0.156
≥40	94 (4.2)	9 (6.1)	103 (4.3)	0.553
Gender				
Male	1212 (54.4)	88 (59.5)	1300 (54.8)	1 (reference)
Female	1014 (45.6)	60 (40.5)	1074 (45.2)	0.236
Causes				
Thermal burn	1729 (77.7)	117 (79.1)	1846 (77.8)	1 (reference)
Other <sup>a</sup>	497 (22.3)	31 (20.9)	528 (22.2)	0.696
Disease duration, year				
> 1	1811 (81.4)	103 (69.6)	1914 (80.6)	1 (reference)
≤ 1	415 (18.6)	45 (30.4)	460 (19.4)	0.001
RBC count, × 10 <sup>12</sup> /L <sup>b</sup>				
4.5–5.5	2044 (91.8)	133 (89.9)	2177 (91.7)	1 (reference)
<4.5	66 (3.0)	3 (2.0)	69 (2.9)	0.548
>5.5	116 (5.2)	12 (8.1)	128 (5.4)	0.142
WBC count, × 10 <sup>9</sup> /L <sup>b</sup>				
4.0–10.0	2038 (91.6)	132 (89.2)	2170 (91.4)	1 (reference)
<4.0	116 (5.2)	11 (7.4)	127 (5.3)	0.245
>10.0	72 (3.2)	5 (3.4)	77 (3.2)	0.882
Surgical duration, min				
<60	528 (23.7)	32 (21.6)	560 (23.6)	1 (reference)
60–130	1141 (51.3)	79 (53.4)	1220 (51.4)	0.538
≥130	557 (25.0)	37 (25.0)	594 (25.0)	0.713
Expander number				
1–2	1566 (70.4)	117 (79.1)	1683 (70.9)	1 (reference)
≥3	660 (29.6)	31 (20.9)	691 (29.1)	0.025
Total expander size, ml				
<200	936 (42.0)	46 (31.1)	982 (41.4)	1 (reference)
200–400	544 (24.4)	40 (27.0)	584 (24.6)	0.071
≥400	746 (33.5)	62 (41.9)	808 (34.0)	0.009
Expander location				
Scalp	774 (34.8)	39 (26.4)	813 (34.2)	1 (reference)
Face	470 (21.1)	27 (18.2)	497 (20.9)	0.610
Neck	179 (8.0)	11 (7.4)	190 (8.0)	0.572
Trunk	677 (30.4)	59 (39.9)	736 (31.0)	0.010
Limbs	126 (5.7)	12 (8.1)	138 (5.9)	0.064
Initial fill volume ratio, %				
10–20	1155 (51.9)	72 (48.6)	1227 (51.7)	1 (reference)
<10	438 (19.7)	36 (24.3)	474 (20.0)	0.192
≥20	633 (28.4)	40 (27.0)	673 (28.3)	0.947
Hematoma evacuation				
No	2161 (97.1)	140 (94.6)	2301 (96.9)	1 (reference)
Yes	65 (2.9)	8 (5.4)	73 (3.1)	0.095

RBC red blood cell, WBC white blood cell

<sup>a</sup>Other causes: chemical cauterization, mechanical lesion, iatrogenic injury, etc.

<sup>b</sup>Preoperative laboratory test; only current male adult reference is listed here, all subjects are grouped according to the corresponding reference range of different populations and different times



**Figure 2.** Rate of expander infection in patients undergoing scar reconstruction using expanders according to: (a) disease duration; (b) expander volume; (c) expander site; and (d) hematoma evacuation

expander size in one surgery was 400 (30, 3350) ml. Additionally, 54 patients (3.8%) required repeat surgery to evacuate a hematoma after expander insertion. The median time of hematoma evacuation was 3 (0, 24) days after the insertion of expanders; there was no expander infection which occurred earlier than the procedures of evacuation.

A total of 2374 expanders were included. One or more infections occurred with 148 expanders (Figure 1). By dividing all data into groups without or with infection and undertaking univariate logistic regression analysis, the differences between the two groups in terms of their demographic and clinical characteristics were calculated and are presented in Table 1.

For univariate logistic regression analysis, five patient features and expanders were selected. The group with disease duration ≤1 year had a significantly higher rate of infection when compared with the group with a disease duration of >1 year (odds ratio (OR), 2.07; 95% CI, 1.42–3.02;  $p < 0.001$ ; 9.8% vs 5.4%, Figure 2a). Expander size was associated with a higher rate of infection—the larger the expander size, the higher the risk of infection (200–400 ml vs <200 ml: OR, 1.74; 95% CI, 1.05–2.90;  $p = 0.032$ ;

≥400 ml, vs <200 ml: OR, 1.76; 95% CI, 1.00–3.07;  $p = 0.049$ ; 7.7% (≥400 ml) vs 6.8% (200–400 ml) vs 4.7% (<200 ml); Figure 2b). Compared with the scalp, expanders placed in the limbs had a higher risk of infection (OR, 2.22; 95% CI, 1.12–4.40;  $p = 0.023$ ; 8.7% vs 4.8%; Figure 2c). The group who underwent hematoma evacuation had a higher rate of infection compared to the normal group (OR, 2.17; 95% CI, 1.00–4.68;  $p = 0.049$ ; 6.1% vs 11.0%; Figure 2d). As for expander number, the difference between 1–2 and ≥3 did not reach statistical significance ( $p = 0.064$ ). Table 2 lists the parameters of the indicative variables in the multivariate logistic regression model and Figure 2 shows the complication rates of the groups mentioned in the model.

The majority of the infections were controlled timely and had little effect on reconstructive outcome. Unfortunately, 9.5% of expanders (14/148) were permanently removed because of unresolved infection. In the sensitivity analysis for treatment failure caused by infection as outcome, the disease duration of ≤1 year (OR, 3.88; 95% CI, 1.31–11.52;  $p = 0.015$ ) and hematoma evacuation (OR, 10.35; 95% CI, 2.66–40.30;  $p = 0.001$ ) were also related to high risk (Table 3).

**Table 2.** Multivariate logistic regression analysis of risk factors for infection

Variables	$\beta$	OR (95% CI)	<i>P</i>
Disease duration, $\leq 1$ vs $> 1$ (year)	0.73	2.07 (1.42–3.02)	<b>&lt;0.001</b>
Expander number, 1–2 vs $\geq 3$	–0.40	0.67 (0.44–1.02)	0.064
Expander volume, 200–400 vs $< 200$ (ml)	0.56	1.74 (1.05–2.90)	<b>0.032</b>
Expander volume, $\geq 400$ vs $< 200$ (ml)	0.56	1.76 (1.00–3.07)	<b>0.049</b>
Expander site, head vs scalp	0.38	1.47 (0.82–2.62)	0.199
Expander site, neck vs scalp	0.43	1.54 (0.76–3.14)	0.234
Expander site, trunk vs scalp	0.43	1.53 (0.96–2.45)	0.075
Expander site, limbs vs scalp	0.80	2.22 (1.12–4.40)	<b>0.023</b>
Hematoma evacuation, yes vs no	0.77	2.17 (1.00–4.68)	<b>0.049</b>

OR odd ratio, CI confidence interval

**Table 3.** Sensitivity analysis for treatment failure caused by infection as outcome

Variables	Univariate		Multivariate	
	OR (95% CI)	<i>P</i>	OR (95% CI)	<i>P</i>
Disease duration, $\leq 1$ vs $> 1$ (year)	3.15 (1.09–9.12)	0.035	3.88 (1.31–11.52)	0.015
Expander volume, 200–400 vs $< 200$ (ml)	0.84 (0.15–4.60)	0.841	1.39 (0.19–10.29)	0.750
Expander volume, $\geq 400$ vs $< 200$ (ml)	2.45 (0.73–8.15)	0.146	3.68 (0.53–24.96)	0.182
Expander site, head vs scalp	2.46 (0.41–14.79)	0.324	3.31 (0.38–28.65)	0.277
Expander site, neck vs scalp	2.15 (0.19–23.79)	0.534	2.59 (0.21–32.02)	0.457
Expander site, trunk vs scalp	3.89 (0.81–18.80)	0.091	2.52 (0.47–13.62)	0.284
Expander site, limbs vs scalp	2.96 (0.27–32.87)	0.377	4.66 (0.40–54.18)	0.219
Hematoma evacuation, yes vs no	8.92 (2.44–32.69)	0.001	10.35 (2.66–40.30)	0.001

OR odds ratio, CI confidence interval

## Discussion

Tissue expansion is one of the most important surgical techniques for scar reconstruction, but its relatively high complication rate hinders universal application. Infection, which is one of the major complications of expansion, may result in premature removal and even failure [26]. Therefore, we reviewed 2374 consecutive cases in our clinic to identify risk factors for infection based on hospital admission records.

The rate of infection was 6.2% of the retrospective cohort during a 10-year period, which was similar to previous studies [11, 27]. The tissue expansion data was characterized by the possibility that one patient may undergo multiple surgeries, and one surgery may include multiple expander insertions, and expanders can be placed at one or multiple anatomical locations. Thus, we described the baseline data by surgeries and calculated the component ratio of the infection groups by expanders. Finally, a disease duration of  $< 1$  year, an expander volume of  $> 200$  ml, limb location and hematoma evacuation were selected by multivariate regression logistic analysis as independent risk factors for expander infection. To the best of our knowledge, this study included the largest single-center

sample of tissue expansion for scar reconstruction to identify risk factors for infection.

The timing of surgical intervention is an important concern for plastic surgeons. Previous practical guidelines for scar management recommend that surgical scar revision may be considered if the patient has developed a permanent scar (existing for at least 1 year) [6, 28, 29]. Our results reveal that a disease duration of  $< 1$  year is associated with a higher rate of expander infection. This may be attributed to evidence of inflammation around immature scars, which may affect the anti-infective ability of the expanded local flap [24]. Except in special situations, we recommend 1 year as a reference for the timing of surgical intervention for various types of scar. In addition, it is essential to carefully evaluate the donor area in preoperative preparation.

Expander-related indices, including the number of expanders used per session, the size of the expanders and the location of the expanders were reported as risks for complication of tissue expansion in many articles [10, 11, 21, 22, 30]. Our results confirmed that expanders located in the limbs had the highest infection rate among all body



**Table 4.** Algorithm for prevention and management of expander infection

Stage	Measurement
Risk assessment	<ol style="list-style-type: none"> <li>1. General risks: severe general illness, hemostatic abnormalities, etc.</li> <li>2. Primary risks: disease duration of &lt;1 year, hematoma evacuation</li> <li>3. Secondary risks: large expander (&gt;400 ml), limb location</li> </ol>
Preoperative preparation	<ol style="list-style-type: none"> <li>1. Proper expander volume and site of expander implantation according to the lesions</li> <li>2. Any wound or folliculitis in the donor sites should be noted</li> <li>3. Skin cleaning one night before expander implantation</li> </ol>
Surgical procedures	<ol style="list-style-type: none"> <li>1. Strict aseptic technique during surgeries</li> <li>2. Thorough hemostasis, endoscope-assisted placement of expander is available [14]</li> <li>3. Strenuous and repeated traction of tissue must be avoided</li> </ol>
Postoperative care	<ol style="list-style-type: none"> <li>1. Prophylactic antibiotics (3–5 days)</li> <li>2. Any mild infection (e.g. folliculitis) and blood circulation disorders of expanded flap should be treated</li> <li>3. Fluid injection by plastic surgery specialized nurses</li> </ol>
Infection	<ol style="list-style-type: none"> <li>1. Oral or intravenous antibiotic regimen (adjusted by culture results)</li> </ol>
Mild	<ol style="list-style-type: none"> <li>1. Remove partial fluid from expander to relax tension of expanded flap</li> <li>2. Dressing change</li> </ol>
Moderate	<ol style="list-style-type: none"> <li>1. Expander pocket lavage via drainage tube</li> <li>2. Continuous infusion-drainage [40, 41]</li> </ol>
Severe	<ol style="list-style-type: none"> <li>1. Making an incision along the previous one, performing surgical debridement</li> <li>2. Expander exchange or removal</li> </ol>

sites and had a significant likelihood of developing infection compared with the scalp. Compared with other anatomical regions, the limbs may have poorer vascular distribution and a larger range of motion. Moreover, the size of the expander, which determined the foreign body size and tissue dissection range, was identified as a significant independent risk factor for expander infection. The OR of infection using the middle-size (200–400 ml) and large ( $\geq 400$  ml) expanders was 1.74 and 1.77, respectively, when compared with the small (<200 ml) expander. Our findings are in agreement with Karimi *et al.* and Lei *et al.*, who recommended that expanders of any size should be expanded to a greater extent instead of choosing a larger expander volume to obtain enough area of expanded flaps [27, 31]. However, our analysis did not show a statistically significant difference in infection rate of based on the expander number per session. In fact, after the skin incision was closed, whether in one or multiple areas, the pocket of each expander was not directly connected. Therefore, in addition to the close proximity, inserting multiple expanders did not significantly increase the possibility of infection with each expander.

Hematoma is an early complication of tissue expansion, usually occurring 0–48 hours after expander insertion. Once uncontrollable postoperative hematoma occurs, reoperations are often required for their removal, which also means hematoma evacuation. In this study, we have shown that hematoma evacuation was associated with a higher likelihood of expander infection. On one hand, tissue hematomas provide a hotbed for bacteria, increase the tension of the expanded flap and prolong the drainage time. Previous studies have shown that hematoma may increase the likelihood of infection of implanted devices or prosthesis [32, 33]. On the other hand, reoperation could increase rate of infection, which has been verified in various kinds of surgeries, such as kidney transplantation, penile prosthesis replacement and shoulder arthroplasty [33–35]. Similarly, surgical re-exploration and evacuation for hematoma were

also likely to allow bacteria to enter the pocket of expanders. Therefore, we suggest that the tendency of bleeding should be corrected preoperatively, meticulous care should be taken to achieve intraoperative hemostasis and the duration of prophylactic antibiotics should be extended appropriately for patients who have hematoma evacuation.

In addition, our results suggest that age was not a risk factor for infection, which were consistent with the findings of Adler *et al.*, but were not in agreement with other studies [18, 22]. With sufficient preoperative evaluation and meticulous postoperative care, pediatric tissue expansion is safe and effective [26]. Moreover, it has been reported that BMI  $\geq 25$ , radiation therapy and smoking history can increase the probability of expander complications, but these were not identified in the present study because there were too few patients with a history of radiotherapy or smoking in our study [2, 11, 20, 21, 23]. A partial lack of height data led to invalid analysis of BMI. We also regret having no data to compare infection rate between internal port and external port in this study; this is because, in the past 10 years, all the injection ports of expanders were externally placed in our institution. According to our previous research between 2003 to 2012, the external placement of the injection port did not increase the probability of infection (internal vs external, 5.4% (38/703) vs 5.2% (139/2679)) [36]. Moreover, sterile saline injection via an external port is convenient and painless, especially for the pediatric population [37], and hospitalization is not required during the expansion period (between the insertion and removal of expanders). Given it is a non-invasive operation, saline injection by external port was performed by experienced nurses in the clinic as routine. Therefore, we believe that the external placement of injection port may not be a risk factor for expander infection.

Sensitivity analysis was used to assess the robustness of the research [38]. It is accepted that treatment failure caused by infection is an adverse event for both surgeons and patients. Thus, treatment failure was chosen as another

outcome to validate this model. The data in Table 3 indicate that a disease duration of <1 year and hematoma evacuation are also related to a high risk of treatment failure. As for expander volume and site, the difference was not statistically significant, probably owing to the small number (14/2374) of positive patients included.

According to the above analyses, and our clinical experience, we recommend an algorithm for the prevention and management of tissue expander infection, as detailed in Table 4.

The present study adopted a retrospective design. Inherently, the major biases for this study include selection bias and measurement bias [39]. To avoid selection bias, consecutive patients were selected over a 10-year period and the inclusion and exclusion criteria were relatively broad. To avoid measurement bias, the majority of the clinical data were obtained from the HIS by database engineers using special software. These were then checked manually to ensure optimal data accuracy. A small number of patients had missing or inaccurate data; thus, our investigators conducted telephone follow-up interviews with patients to further supplement and revise the corresponding data.

Despite our efforts to reduce bias, one limitation of this retrospective study was that there was still missing data in the hospital admissions records. Additionally, our research was limited to a single center and should be further verified in a multicenter study. Besides, we intend to gather more cases and reasonably subclassify parts of the body according to whether there are joints or important neurovascular structures nearby for inclusion in future research.

## Conclusions

In conclusion, expander infection in patients undergoing scar reconstruction occurred in 6.2% of cases in our department. A disease duration of <1 year (from wound healing to surgery), an expander volume of >200 ml, expander insertion in the limbs and hematoma evacuation were independent risk factors for expander infection. Disease duration of <1 year and hematoma evacuation were also related to a higher risk of treatment failure caused by infection. We recommend that surgical intervention is performed 1 year after wound healing. When inserting large-volume expanders in the limb region, surgeons should pay extra attention to aseptic technique and postoperative care. Moreover, it is necessary to correct bleeding tendency and properly manage hematoma for infection prevention.

## Acknowledgements

We thank Qian He from Qujiang New Area Administrative Committee, Xi'an, China for data entry and Peng He from the Department of Nephrology, Xijing Hospital, Fourth Military Medical University, China for statistical analysis.

## Abbreviations

BMI: body mass index; HIS: hospital information system; RBC: red blood cell; WBC: white blood cell; OR: odds ratio

## Funding

The authors have no related financial interests or commercial associations. Funding from the National Natural Science Foundation of China (81671925, 81971851), the Shaanxi Province Key R&D Program Project (2018ZDXM-SF-081) and the Discipline Promotion Project of Xijing Hospital (XJZT19D03) were received for this study.

## Conflicts of interest

None stated.

## Availability of data and materials

The data used and/or analysed in the current study are available upon request.

## Authors' contributions

CD designed and carried out the study, collected and analysed the data and wrote the draft. MZ contributed to the conception of the study. LH and KJ assisted in the data collection by designing software. WL and HL helped with data collection by manual checking. ZY and XM contributed to the design of the study, provided administrative support and edited the manuscript. ZY and XM contributed equally to this work. All authors read and approved the final manuscript.

## Ethics approval and consent to participate

This study was approved by the ethics committee at Xijing Hospital (KY20192155-C-1) and was preregistered in the Chinese Clinical Trial Registry (ChiCTR1900027702) on 24 December 2019.

## References

1. Neumann CG. The expansion of an area of skin by progressive distention of a subcutaneous balloon; use of the method for securing skin for subtotal reconstruction of the ear. *Plast Reconstr Surg* (1946). 1957; 19: 124–30.
2. Radovan C. Breast reconstruction after mastectomy using the temporary expander. *Plast Reconstr Surg*. 1982; 69: 195–208.
3. Ogawa R. Surgery for scar revision and reduction: from primary closure to flap surgery. *Burns Trauma*. 2019; 7:7. <https://doi.org/10.1186/s41038-019-0144-5>.
4. Min P, Li J, Brunetti B, Pu Z, Su W, Xi W, et al. Pre-expanded bipedicle visor flap: an ideal option for the reconstruction of upper and lower lip defects postburn in Asian males. *Burns Trauma*. 2020. <https://doi.org/10.1093/burnst/tkaa005>.
5. Finnerty CC, Jeschke MG, Branski LK, Barret JP, Dziewulski P, Herndon DN. Hypertrophic scarring: the greatest unmet challenge after burn injury. *Lancet*. 2016; 388: 1427–36.
6. Bayat A, McGrouther DA, Ferguson MW. Skin scarring. *BMJ*. 2003; 326: 88–92.
7. Sen CK, Gordillo GM, Roy S, Kirsner R, Lambert L, Hunt TK, et al. Human skin wounds: a major and snowballing threat to public health and the economy. *Wound Repair Regen*. 2009; 17: 763–71.
8. Khansa I, Harrison B, Janis JE. Evidence-based scar management: how to improve results with technique and technology. *Plast Reconstr Surg*. 2016; 138: 165S–78S.
9. Ma X, Li Y, Li W, Liu C, Peng P, Song B, et al. Reconstruction of large Postburn facial-scalp scars by expanded Pedicle Deltopectoral flap and random scalp flap: technique improvements



- to enlarge the reconstructive territory. *J Craniofac Surg*. 2017; 28: 1526–30.
10. Azzi JL, Thabet C, Azzi AJ, Gilardino MS. Complications of tissue expansion in the head and neck. *Head Neck*. 2020; 42: 747–62.
  11. Huang X, Qu X, Li Q. Risk factors for complications of tissue expansion: a 20-year systematic review and meta-analysis. *Plast Reconstr Surg*. 2011; 128: 787–97.
  12. Patel PA, Elhadi HM, Kitzmiller WJ, Billmire DA, Yakuboff KP. Tissue expander complications in the pediatric burn patient: a 10-year follow-up. *Ann Plast Surg*. 2014; 72: 150–4.
  13. Motamed S, Niazi F, Atarian S, Motamed A. Post-burn head and neck reconstruction using tissue expanders. *Burns*. 2008; 34: 878–84.
  14. As'adi K, Emami SA, Salehi SH, Shoar S. A randomized controlled trial comparing endoscopic-assisted versus open neck tissue expander placement in reconstruction of post-burn facial scar deformities. *Aesthetic Plast Surg*. 2016; 40: 526–34.
  15. Tang S, Wu X, Sun Z, Cheng H, Shen H, Tang L, et al. Staged reconstructive treatment for extensive irregular cicatricial alopecia after burn. *Medicine (Baltimore)*. 2018. <https://doi.org/10.1097/MD.00000000000013522>.
  16. Abellan Lopez M, Serror K, Chauat M, Mimoun M, Boccara D. Tissue expansion of the lower limb: retrospective study of 141 procedures in burn sequelae. *Burns*. 2018; 44: 1851–7.
  17. Tayyaba FU, Amin MM, Attaur-Rasool S, Naseer U, Ambar A. Reconstruction of post burn scalp alopecia by using expanded hair-bearing scalp flaps. *Pak J Med Sci*. 2015; 31: 1405–10.
  18. Adler N, Elia J, Billig A, Margulis A. Complications of nonbreast tissue expansion: 9 years experience with 44 adult patients and 119 pediatric patients. *J Pediatr Surg*. 2015; 50: 1513–6.
  19. Margulis A, Billig A, Elia J, Shachar Y, Adler N. Complications of post-burn tissue expansion reconstruction: 9 years experience with 42 Pediatric and 26 adult patients. *Isr Med Assoc J*. 2017; 19: 100–4.
  20. Hanna KR, Tilt A, Holland M, Colen D, Bowen B, Stovall M, et al. Reducing infectious complications in implant based breast reconstruction: impact of early expansion and prolonged drain use. *Ann Plast Surg*. 2016; 76: S312–5.
  21. Smolle C, Tuca A, Wurzer P, Spindel SM, Forbes AA, Spindel S, et al. Complications in tissue expansion: a logistic regression analysis for risk factors. *Burns*. 2017; 43: 1195–202.
  22. Fochtman A, Keck M, Mittlböck M, Rath T. Tissue expansion for correction of scars due to burn and other causes: a retrospective comparative study of various complications. *Burns*. 2013; 39: 984–9.
  23. Nguyen KT, Hanwright PJ, Smetona JT, Hirsch EM, Seth AK, Kim JY. Body mass index as a continuous predictor of outcomes after expander-implant breast reconstruction. *Ann Plast Surg*. 2014; 73: 19–24.
  24. Ota D, Fukuuchi A, Iwahira Y, Kato T, Takeuchi M, Okamoto J, et al. Identification of complications in mastectomy with immediate reconstruction using tissue expanders and permanent implants for breast cancer patients. *Breast Cancer*. 2016; 23: 400–6.
  25. Clavien PA, Barkun J, de Oliveira ML, Vauthey JN, Dindo D, Schulick RD, et al. The Clavien-Dindo classification of surgical complications: five-year experience. *Ann Surg*. 2009; 250: 187–96.
  26. Bjornson LA, Bucevska M, Verchere C. Tissue expansion in pediatric patients: a 10-year review. *J Pediatr Surg*. 2019; 54: 1471–6.
  27. Karimi H, Latifi NA, Momeni M, Sedigh-Maroufi S, Karimi AM, Akhoondinasab MR. Tissue expanders; review of indications, results and outcome during 15 years' experience. *Burns*. 2019; 45: 990–1004.
  28. Gold MH, McGuire M, Mustoe TA, Pusic A, Sachdev M, Waibel J, et al. Updated international clinical recommendations on scar management: part 2—algorithms for scar prevention and treatment. *Dermatol Surg*. 2014; 40: 825–31.
  29. Monstrey S, Middelkoop E, Vranckx JJ, Bassetto F, Ziegler UE, Meaume S, et al. Updated scar management practical guidelines: non-invasive and invasive measures. *J Plast Reconstr Aesthet Surg*. 2014; 67: 1017–25.
  30. Sue GR, Sun BJ, Lee GK. Complications after two-stage expander implant breast reconstruction requiring reoperation: a critical analysis of outcomes. *Ann Plast Surg*. 2018; 80: S292–4.
  31. Lei J, Hou C, Duan P, Hao Z, Zhai Y, Meng Y. Clinical application of modified skin soft tissue expansion in early repair of devastating wound on the head due to electrical burn. *Zhonghua Shao Shang Za Zhi*. 2015; 31: 406–9.
  32. Essebag V, Verma A, Healey JS, Krahn AD, Kalfon E, Coutu B, et al. Clinically significant pocket hematoma increases long-term risk of device infection: BRUISE CONTROL INFECTION study. *J Am Coll Cardiol*. 2016; 67: 1300–8.
  33. Cheung EV, Sperling JW, Cofield RH. Infection associated with hematoma formation after shoulder arthroplasty. *Clin Orthop Relat Res*. 2008; 466: 1363–7.
  34. Ostaszewska A, Wszola M, Olszewska N, Karpeta E, Serwanska-Swietek M, Kuthan R, et al. Reoperation in early kidney post-transplant period as a strong risk factor of surgical site infection occurrence. *Transplant Proc*. 2019; 51: 2724–30.
  35. Hinds PR, Wilson SK, Sadeghi-Nejad H. Dilemmas of inflatable penile prosthesis revision surgery: what practices achieve the best outcomes and the lowest infection rates? (CME). *J Sex Med*. 2012; 9: 2483–91.
  36. Zhu M, Zhang D, Ye X, Ma X, Guo X. Risk factors of infection after skin soft tissue expansion. *Zhonghua Zheng Xing Wai Ke Za Zhi*. 2019; 35: 986–90.
  37. Azadgoli B, Fahradyan A, Wolfswinkel EM, Tsuha M, Magee W, 3rd, Hammoudeh JA, et al. External port tissue expansion in the Pediatric population: confirming its safety and efficacy. *Plast Reconstr Surg*. 2018; 141: 883e–90e.
  38. Thabane L, Mbuagbaw L, Zhang S, Samaan Z, Marcucci M, Ye C, et al. A tutorial on sensitivity analyses in clinical trials: the what, why, when and how. *BMC Med Res Methodol*. 2013. <https://doi.org/10.1186/1471-2288-13-92>.
  39. Sessler DI, Imrey PB. Clinical research methodology 2: observational clinical research. *Anesth Analg*. 2015; 121: 1043–51.
  40. Chang H, Zhou B, Cui X, Su Y, Ma X. Analysis of the bacteria spectrum and clinical treatment of topical skin infection during soft tissue expander implantation. *Zhonghua Zheng Xing Wai Ke Za Zhi*. 2016; 32: 191–5.
  41. Wei M, Liu YJ, Li ZL, Wang ZG, Zhu JL. Clinical effect of arthroscopic debridement and infusion-drainage on septic arthritis after arthroscopic anterior cruciate ligament reconstruction. *Zhongguo Gu Shang*. 2015; 28: 279–81.