



Contents lists available at ScienceDirect

## International Journal of Surgery Case Reports

journal homepage: [www.casereports.com](http://www.casereports.com)

# Destructive Osteonecrosis of the Femoral Head After a Single Intra-Articular Corticosteroid Injection: A Report of Two Cases

Abdulaziz F. Ahmed, Mohammed Hammad, Motasem Salameh, Ghalib O. Ahmed\*

Section of Orthopedics, Department of Surgery, Hamad General Hospital, Doha, Qatar

## ARTICLE INFO

### Article history:

Received 26 October 2020  
 Received in revised form  
 18 November 2020  
 Accepted 18 November 2020  
 Available online 22 November 2020

### Keywords:

Avascular  
 Necrosis  
 Osteonecrosis  
 Femoral  
 Head

## ABSTRACT

**INTRODUCTION:** Accelerated femoral head avascular necrosis after a single dose intra-articular steroid injection is a rare pathology. Few cases were reported in the literature. Most cases were managed with total hip arthroplasty.

**CASE PRESENTATION:** In this study, we report two rare cases of destructive osteonecrosis of the femoral head. Both patients presented with hip osteoarthritis that failed nonoperative measures. A single intra-articular corticosteroid injection was administered for each patient. Both patients had femoral head destruction and significant resorption at 14 and 11 weeks, respectively. Septic arthritis was ruled out by blood tests and joint aspiration. Total hip arthroplasty (THA) was undertaken and histology reports confirmed the osteonecrosis. The postoperative follow-up was uneventful with satisfactory hip function.

**DISCUSSION AND CONCLUSION:** Destructive osteonecrosis of the femoral head is a rare catastrophic potential complication of intra-articular corticosteroid injection. Hence, physicians must consider this complication when counseling patients before an intra-articular corticosteroid hip injection.

© 2020 Published by Elsevier Ltd on behalf of IJS Publishing Group Ltd. This is an open access article under the CC BY-NC-ND license (<http://creativecommons.org/licenses/by-nc-nd/4.0/>).

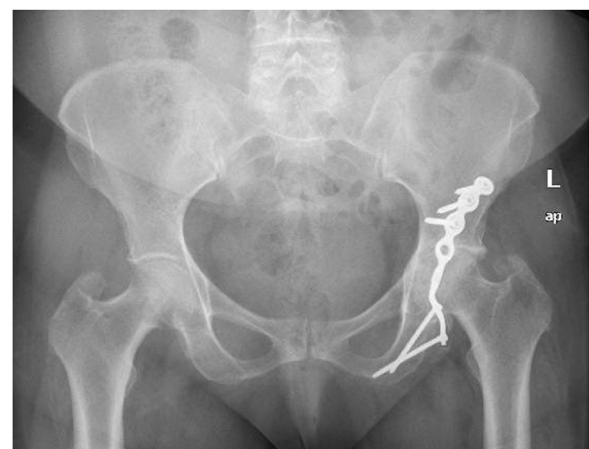## 1. Introduction

The incidence of femoral head osteonecrosis has been estimated to reach up to 30,000 cases annually, and it accounts for 10% of the indications for total hip arthroplasty (THA) [1,2].

Femoral head osteonecrosis can develop following direct factors such as femoral neck fracture, hip dislocations, radiation. Whereas, indirect factors consist of corticosteroids, alcohol intake, smoking, hypercoagulable states, marrow-replacing disease (e.g., Gaucher disease), systemic lupus erythematosus (SLE), Caisson disease and viral infections (e.g., hepatitis, human immunodeficiency) [3,4].

It is noteworthy that up to 40% of hip osteonecrosis are attributed to the use of corticosteroids [5]. The risk of osteonecrosis is most significant with prolonged and high dose corticosteroid treatment [5,6]. In addition, short-term exposure has been described in several reports as well. However, only a few cases of osteonecrosis of the femoral head have been reported following a single intra-articular injection [7]. In this report, we describe two rare cases of destructive osteonecrosis of the femoral head after a single corticosteroid injection.

The patients were informed that data concerning their cases would be submitted for publication, and they provided consent.



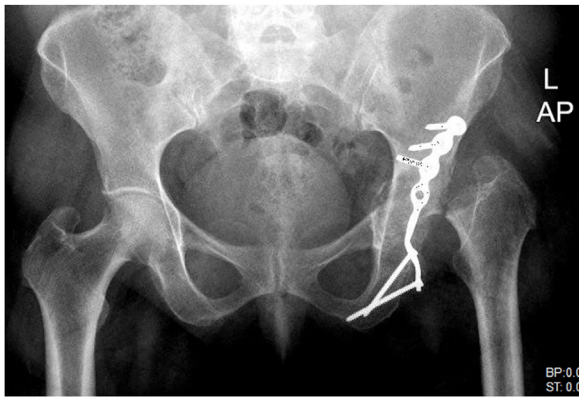**Fig. 1.** Case 1; Anteroposterior and lateral pelvis radiographs demonstrating left hip post-traumatic arthritis.

## 2. Case presentation

The Surgical Case Report (SCARE) statement guidelines were utilized in the reporting of the two cases [8].

Case 1. A 58-years-old female presented with left hip post-traumatic osteoarthritis two years after open reduction and internal fixation for left acetabulum posterior wall fracture-dislocation (Fig. 1). The pain was exacerbated with activity and

\* Corresponding author at: Orthopaedic Surgery Department, Hamad Medical Corporation, Al-Rayyan Road, Doha, Qatar.  
 E-mail address: [gahmed@hamad.qa](mailto:gahmed@hamad.qa) (G.O. Ahmed).

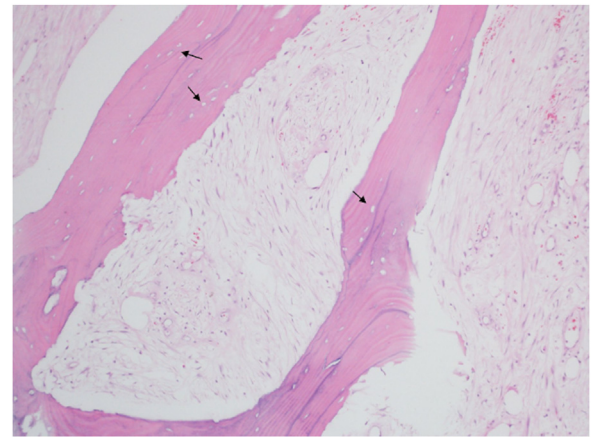


**Fig. 2.** Case 1; Anteroposterior and lateral pelvis radiograph displaying left femoral head resorption following an intra-articular corticosteroid injection.

relieved by rest. She had a past medical history of hypertension and hypothyroidism, however no history of cancer, blood coagulation disorders, or inflammatory arteriopathies. No previous intake of corticosteroids. No history of smoking or alcohol consumption.

Initially she was treated with nonoperative measures such as self-directed exercises, weight loss, and analgesia. The left hip pain was refractory to the aforementioned conservative modalities, which impaired her daily living activities. Subsequently, a fluoroscopy-guided intra-articular corticosteroid injection of methylprednisolone acetate 80 mg and 3 mL of bupivacaine 0.5% was administered and the pain was improved for six weeks. At 14 weeks following the injection, she presented with further deterioration in left hip pain with the inability to perform any sort of weight-bearing. Physical examination demonstrated inability of weight-bearing ambulation, left lower limb shortening of approximately 2 cm, and a painful global range of motion.

Infection laboratory workup, including the hip joint aspiration and triphasic bone scan, were negative. Left hip plain radiographs and CT scan demonstrated destruction and resorption of the left femoral head (Fig. 2).

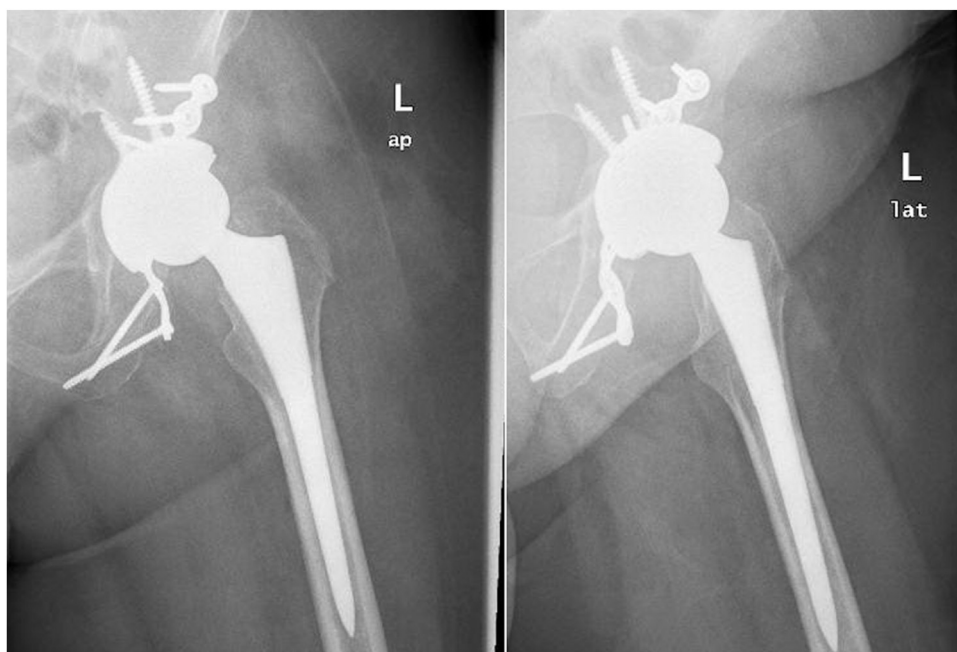

**Fig. 3.** Case 1; Histological photomicrographs of the intraoperative femoral head fragments demonstrating A) Necrotic bony trabeculae with empty lacunae (arrows) adjacent to fibrotic bone marrow (hematoxylin and eosin  $\times 100$ ). B) Significant bone marrow fibrosis (hematoxylin and eosin  $\times 200$ ).

Subsequently, a cementless left THA with ceramic on ceramic bearings was performed through the posterior hip approach, and the implants from the previous acetabulum ORIF were retained. A bone biopsy was taken from the remnant of the femoral head which confirmed the diagnosis of osteonecrosis and ruled out the presence of infection (Fig. 3).

Postoperatively, the patient had a smooth recovery and was discharged with a postoperative physical therapy plan. At the latest follow-up of five years, she was satisfied with the left hip function, and no postoperative complications were noted (Fig. 4).

Case 2. A 47-year-old female who is a known case of psoriasis complained of right hip worsening pain and difficulty in performing daily life activities. She is known to have right hip osteoarthritis (Fig. 5), which failed conservative measures such as non-steroidal anti-inflammatories, and physical therapy. No past surgical history, however, she has a past medical history of coronary artery disease, morbid obesity and modulating immunotherapy for psoriasis. No relevant family history, and no alcohol intake or smoking.



**Fig. 4.** Case 1; post-operative anteroposterior and lateral hip radiographs following total hip arthroplasty.

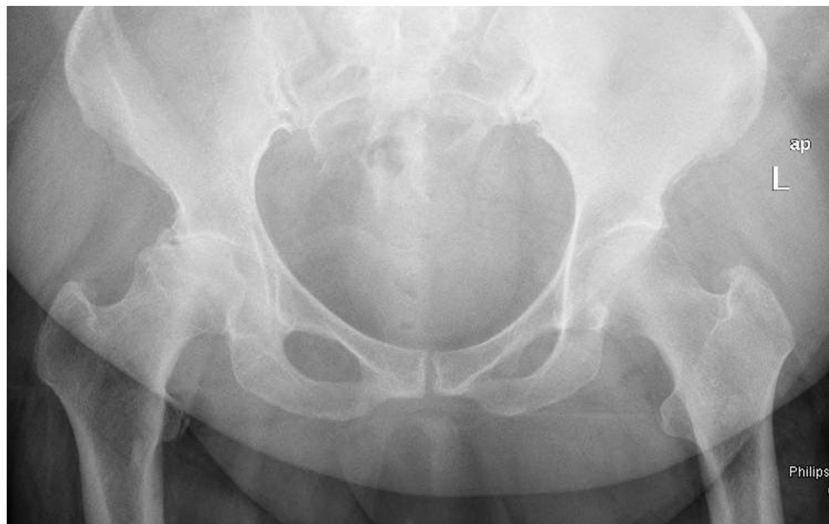


Fig. 5. Case 2; Anteroposterior pelvis radiograph demonstrating right hip osteoarthritis.

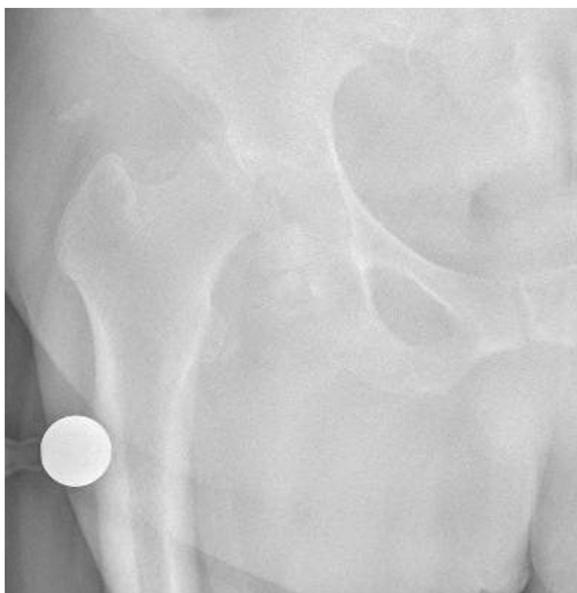

Fig. 6. Case 2; Anteroposterior and lateral hip radiographs displaying right femoral head resorption following an intra-articular corticosteroid injection.

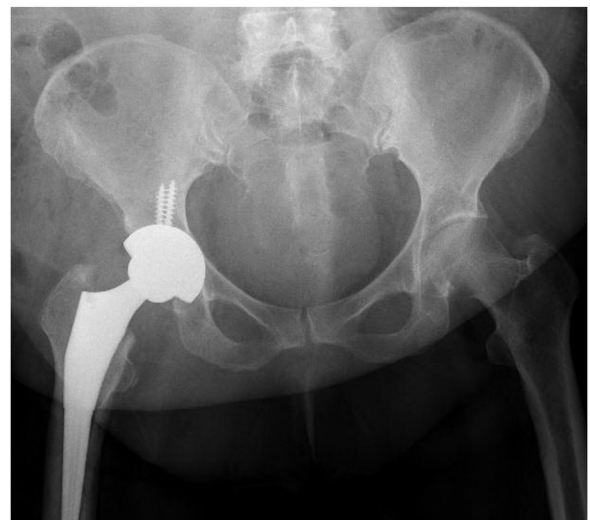

Fig. 7. Case 2; post-operative anteroposterior and lateral hip radiographs following a total hip arthroplasty.

A right hip ultra-sound guided intra-articular injection with 3 mL levobupivacaine 0.5% and triamcinolone acetonide 40 mg was performed by a pain specialist, with immediate pain relief. Eleven weeks later she presented with worsening right hip pain with the inability to perform any sort of weight-bearing. Physical examination showed inability of weight-bearing ambulation, right lower limb shortening of 3 cm, and painful global range of motion.

The infection workup revealed a white cell count of  $5.5 \times 10^3/\mu\text{L}$  and a C-reactive protein of 1.3 mg/L with negative joint aspiration. Right hip plain radiographs displayed right femoral head destruction and resorption (Fig. 6).

Thereafter, a cementless right THA with ceramic on ceramic bearings was performed through the posterior hip approach (Fig. 7). Bone biopsy was taken from the remnant of the femoral head which ruled out infection and confirmed the diagnosis of osteonecrosis (Fig. 8).

Postoperatively, the patient had an uneventful course and was discharged within eight days after achieving physical therapy discharge milestones. At the latest follow-up point 1 year post-

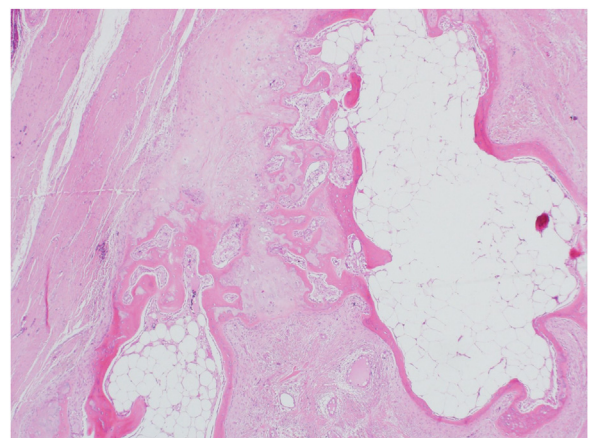


Fig. 8. Case 2; A) Macroscopic photo showing femoral head fragmentation B) Histological photomicrograph (hematoxylin and eosin stain  $\times 40$ ) of the intraoperative femoral head fragments demonstrating bony erosion with subchondral cysts surrounded by fibrosis.

**Table 1**

Summary of reported cases of rapidly-progressive osteonecrosis of the femoral head following a single intra-articular corticosteroid injection.

Author, year	Age	Sex	Diagnosis	Corticosteroid Injection	Time	Treatment
Yamamoto, 2006	50	Female	Osteoarthritis	Methylprednisolone acetate 80 mg	12 weeks	THA
Kassam, 2010	79	Male	Osteoarthritis	Triamcinolone acetonide 2 mL	5 weeks	THA
Thompson and Ensrud, 2019	72	Female	Osteoarthritis	Triamcinolone acetonide 80mg	4 weeks	THA
Al-Omari, 2019	78	Male	Osteoarthritis	Unspecified	7.25 weeks	THA

operatively, she was ambulating independently with a profound improvement in pain and hip function with no postoperative complications.

### 3. Discussion

This study reported two cases with destructive osteonecrosis of the femoral head after single intra-articular corticosteroid injection. The osteonecrosis in both cases was destructive, occurring within 14 and 11 weeks of intraarticular steroid injection in each case, respectively.

In the first case, the patient had a posttraumatic osteoarthritis and in the second case, the patient is known to be obese, psoriatic with osteoarthritis.

In the literature, few cases have been previously reported with femoral head osteonecrosis following single intra-articular corticosteroid injections (Table 1) [7,9–11]. It was first reported in 2006 on a 50-year-old female with left hip osteoarthritis following a single intra-articular injection with 80 mg of methylprednisolone [9]. In previous case reports, patients presented initially with mild hip osteoarthritis, which deteriorated rapidly into severe hip pain and disability. The period from an intra-articular corticosteroid injection to deterioration ranged from 4 to 12 weeks. The radiographs in all cases were notable for femoral head collapse and flattening. The underlying etiology of osteonecrosis was confirmed with histology, and infectious processes were ruled out. Hip replacement in the form of THA was performed in all reports, except in the case report by Vanushkina et al., who implemented a hip hemiarthroplasty instead.

In the evaluation of the destruction of the femoral head, several differential diagnoses should be considered. Septic hip infection following intra-articular injections is a potentially devastating complication. The incidence of iatrogenic joint infection is rare with an incidence 2–10 cases per 100,000 injections [12]; however, its prevalence has increased given the frequent use of intra-articular corticosteroids and viscosupplements in the management of osteoarthritis. Risk factors for iatrogenic joint infections include immunocompromised states (e.g., diabetes mellitus, HIV, immunosuppressants), excessive alcohol intake, previous joint or skin infections, presence of joint prosthesis and previous joint surgery [13]. It is paramount to rule out any infectious processes. A proper history and physical examination in combination with inflammatory markers and intraoperative tissue cultures are necessary for the process of evaluation.

Another differential diagnosis is rapidly-progressive osteoarthritis, which is defined as loss of > 50% of joint space within 12 months [14]. It can occur following trauma such as acetabular fracture, which is more prevalent in elderly males. However, non-traumatic cases have been reported in elderly female [15]. The clinical presentation resembles that of rapidly-progressive osteonecrosis; therefore, further investigations are useful in differentiating one condition from another. In early stages, the subchondral fractures in rapidly progressive osteoarthritis appear as a curvilinear band of low signal on all MRI sequences [16]. Whereas, the MRI findings in osteonecrosis display edema with serpentine-like pattern and the subchondral fracture is concave to the articular surface [17]. In late stages where the

femoral head is destroyed, MRI findings and histopathology offer little to no value in differentiating between both conditions. Histology in rapidly-progressive osteoarthritis shows synovitis that is consistent with reactive and hypervascularity changes [15]. However, osteonecrosis histology is evident in bone marrow edema and necrosis with appositional bone formation [18].

In summary, destructive osteonecrosis of the femoral head is a rare catastrophic potential complication of intra-articular corticosteroid injection. Hence, physicians must consider this complication when counseling patients before an intra-articular corticosteroid hip injection. In addition, such cases can be treated effectively with THA.

### Conflicts of interest

No conflict of interest to declare.

### Funding

No funding was obtained for this case report.

### Ethical approval

The case report was approved by the medical research centre at Hamad Medical Corporation, Doha, Qatar. Reference number: MRC-04-20-188.

### Consent

Written informed consent was obtained from the patient for publication of this case report and accompanying images. A copy of the written consent is available for review by the Editor-in-Chief of this journal on request.

### Author contribution

AA, MH and MS wrote the manuscript and consented the patients. GA was the senior author who provided supervision for writing this case report.

### Registration of research studies

The study is a case report and has no registries.

### Guarantor

Dr. Ghalib Ahmed is the senior author and the guarantor.

### Provenance and peer review

Not commissioned, externally peer-reviewed.

### References

- [1] J.F. Desforges, H.J. Mankin, Nontraumatic necrosis of bone (Osteonecrosis), *N. Engl. J. Med.* 326 (May (22)) (1992) 1473–1479.

- [2] J. Moya-Angeler, A.L. Gianakos, J.C. Villa, A. Ni, J.M. Lane, Current concepts on osteonecrosis of the femoral head, *World J. Orthop.* 6 (September (8)) (2015) 590–601.
- [3] G.S. Lausten, Non-traumatic necrosis of the femoral head, *Int. Orthop.* 23 (November (4)) (1999) 193–197.
- [4] J. Bergman, A. Nordström, P. Nordström, Epidemiology of osteonecrosis among older adults in Sweden, *Osteoporos. Int.* 30 (May (5)) (2019) 965–973.
- [5] R.S. Weinstein, Glucocorticoid-induced bone disease, *N. Engl. J. Med.* 365 (July (1)) (2011) 62–70.
- [6] M.A. Mont, R. Pivec, S. Banerjee, K. Issa, R.K. Elmallah, L.C. Jones, High-dose corticosteroid use and risk of hip osteonecrosis: meta-analysis and systematic literature review, *J. Arthroplasty* 30 (September (9)) (2015) 1506–1512, e5.
- [7] A.A. Al-Omari, A.J. Aleshawi, O.A. Marei, H.M. Bani Younes, K.Z. Alawneh, E. ALQuran, et al., Avascular necrosis of the femoral head after single steroid intra-articular injection, *Eur. J. Orthop. Surg. Traumatol.* 30 (2020) 193–197.
- [8] R.A. Agha, M.R. Borrelli, R. Farwana, K. Koshy, A. Fowler, D.P. Orgill, For the SCARE Group, The SCARE 2018 statement: updating consensus surgical CAse REport (SCARE) guidelines, *Int. J. Surg.* 60 (2018) 132–136.
- [9] T. Yamamoto, R. Schneider, Y. Iwamoto, P.G. Bullough, Rapid destruction of the femoral head after a single intraarticular injection of corticosteroid into the hip joint, *J. Rheumatol.* 33 (August (8)) (2006) 1701–1704.
- [10] A.M. Kassam, Accelerated avascular necrosis after single intra-articular injection of corticosteroid into the hip joint, *Case Rep.* 2010 (2010), bcr1020092405.
- [11] A.R. Thompson, E.R. Ensrud, Rapid onset of femoral head osteonecrosis after a single intra-articular hip joint injection of corticosteroid, *Am. J. Phys. Med. Rehabil.* 99 (April (4)) (2020) e54–e55.
- [12] C.J. Mathews, G. Coakley, Septic arthritis: current diagnostic and therapeutic algorithm, *Curr. Opin. Rheumatol.* 20 (July (4)) (2008) 457–462.
- [13] C.J.E. Kaandorp, D. Van Schaardenburg, P. Krijnen, J.D. Habbema, M.A. van de Laar, Risk factors for septic arthritis in patients with joint disease, *Arthritis Rheum.* 38 (December (12)) (1995) 1819–1825.
- [14] M. Lequesne, Rapidly progressing destructive diseases of the hip, *Ann. Radiol. (Paris)* 36 (1993) 62–64.
- [15] D.J. Flemming, C.N. Gustas-French, Rapidly progressive osteoarthritis: a review of the clinical and radiologic presentation, *Curr. Rheumatol. Rep.* 19 (July (7)) (2017) 42.
- [16] N. Boutry, C. Paul, X. Leroy, D. Fredoux, H. Migaud, A. Cotton, Rapidly destructive osteoarthritis of the hip: MR imaging findings, *AJR Am. J. Roentgenol.* 179 (September (3)) (2002) 657–663.
- [17] S. Ikemura, T. Yamamoto, G. Motomura, Y. Nakashima, T. Mawatari, Y. Iwamoto, MRI evaluation of collapsed femoral heads in patients 60 years old or older: differentiation of subchondral insufficiency fracture from osteonecrosis of the femoral head, *AJR Am. J. Roentgenol.* 195 (1) (2010) W63–8.
- [18] S.G. Chernetsky, M.A. Mont, D.M. LaPorte, L.C. Jones, D.S. Hungerford, E.D. McCarthy, Pathologic features in steroid and nonsteroid associated osteonecrosis, *Clin. Orthop. Relat. Res.* (1999) 149–161.

## Open Access

This article is published Open Access at [sciencedirect.com](https://www.sciencedirect.com). It is distributed under the [IJSCR Supplemental terms and conditions](#), which permits unrestricted non commercial use, distribution, and reproduction in any medium, provided the original authors and source are credited.