



# Aldosterone and progesterone-secreting adrenocortical adenocarcinoma in a cat with a concurrent meningioma

*Journal of Feline Medicine and Surgery*  
*Open Reports*  
 1–7

© The Author(s) 2016  
 Reprints and permissions:  
[sagepub.co.uk/journalsPermissions.nav](http://sagepub.co.uk/journalsPermissions.nav)  
 DOI: 10.1177/2055116915624448  
[jfmsopenreports.com](http://jfmsopenreports.com)



Jana Leshinsky<sup>1</sup>, Julia A Beatty<sup>1</sup>, Anne Fawcett<sup>2</sup>, Katja Voss<sup>1</sup>,  
 Mariano Makara<sup>1</sup>, Mark B Krockenberger<sup>3</sup> and Vanessa R Barrs<sup>1</sup>

## Abstract

**Case summary** A 12-year-old, male neutered domestic shorthair cat was referred for investigation of suspected hyperaldosteronism due to persistent hypokalaemia, hindlimb ataxia, weakness of 1 month's duration and a left adrenal mass that was detected on abdominal ultrasound. Neurological examination findings at referral were suggestive of a concurrent left forebrain lesion. Hyperaldosteronism and concurrent hyperprogesteronism were confirmed on endocrine testing. On computed tomography (CT) of the abdomen and thorax there was no evidence of local vascular invasion by the adrenal mass or of metastatic disease. CT and magnetic resonance imaging featured a large, focal rim-enhancing extra-axial left forebrain lesion consistent with a meningioma. Surgical excision of the forebrain mass was followed by adrenalectomy 2 weeks later. The tumours were classified on histopathology as a psammomatous meningioma and an adrenocortical adenocarcinoma, respectively. Immunohistochemical staining of the meningioma confirmed the presence of progesterone receptors. The cat remains well 2 years later.

**Relevance and novel information** In humans, elevated serum progesterone levels have been associated with rapid growth of meningiomas due to the presence of progesterone receptors on the tumour. This is the first report of a cat with a progesterone and aldosterone-secreting adrenocortical adenocarcinoma and a concurrent meningioma. Clinicians should be aware of the potential effect of elevated progesterone on meningiomas in cats.

**Accepted:** 1 December 2015

## Introduction

In humans, elevated serum progesterone levels have been associated with rapid growth of meningiomas due to the expression of progesterone receptors (PRs) on tumour cells.<sup>1–3</sup> Here we report a case of a meningioma in a cat with an adrenocortical carcinoma that was co-secreting aldosterone and progesterone.

## Case description

A 12 year-old, male neutered, domestic shorthair cat was referred to the Valentine Charlton Cat Centre for investigation of persistent hypokalaemia (2.5–3.3 mmol/l; reference interval [RI] 3.5–5.8 mmol/l), hypertension, hindlimb ataxia and weakness of approximately 1 month's duration. A palpable, left-sided, cranial abdominal mass localised to the left adrenal gland was identified on abdominal ultrasound.

On presentation at referral, the cat was agitated, vocalising and pacing compulsively in wide circles to the left. The cat weighed 6.45 kg (body condition score [BCS] 3/5) and had lost 500 g in body weight over the previous 2 months. On physical examination vital parameters were normal. A grade III/VI left parasternal

<sup>1</sup>Valentine Charlton Cat Centre, Faculty of Veterinary Science, University of Sydney, NSW, Australia

<sup>2</sup>Sydney Animal Hospitals – Inner West, Stanmore, NSW, Australia

<sup>3</sup>Veterinary Pathology Diagnostic Services, Faculty of Veterinary Science, University of Sydney, NSW, Australia

### Corresponding author:

Vanessa Barrs BVSc, PhD, MVetClinStud, FANZCVS, Faculty of Veterinary Science, University of Sydney, Evelyn Williams Building B10, NSW 2006, Australia  
 Email: [vanessa.barrs@sydney.edu.au](mailto:vanessa.barrs@sydney.edu.au)



systolic heart murmur was auscultated and systolic arterial blood pressure was 220 mmHg (Doppler method). A neurological examination revealed an absent right menace response and a proprioceptive deficit on the right forelimb. Cranial nerves and spinal reflexes were assessed to be normal. On fundoscopy, there was evidence of hypertensive chorioretinopathy, including a focal, hyper-reflective bullous lesion in the left tapetal fundus and tortuous retinal vessels.

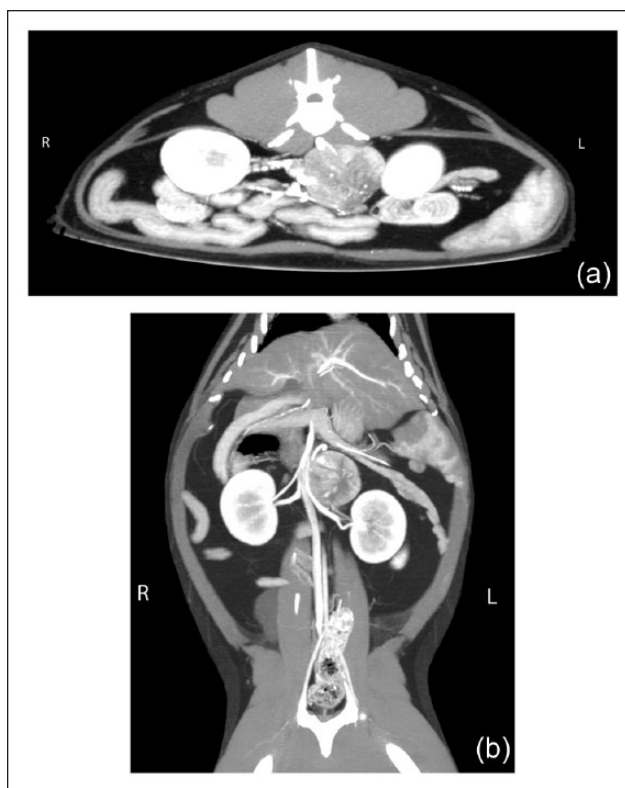
An aldosterone-secreting adrenal neoplasm was suspected, based on clinical history, hypokalaemia, systemic hypertension with evidence of end-organ damage and sonographic findings. Abnormalities on repeat haematology and serum biochemistry were confined to hypokalaemia (2.5 mmol/l; RI 3.5–5.8 mmol/l), metabolic alkalosis (bicarbonate 25 mmol/l; RI 17–21 mmol/l) and mildly elevated creatinine kinase (460 U/l; RI 64–400 U/l). Serum total thyroxine was within normal limits (37 nmol/l; RI 10–60 nmol/l). Plasma aldosterone concentration was markedly elevated (>3465 pmol/l; RI 110–540 pmol/l), while plasma renin activity was low (<40 fmol/l/s; RI 60–630 fmol/l/s). An adrenocorticotropic hormone (ACTH) stimulation test was performed using 125 µg cosyntropin (Synacthen; Novartis) administered intravenously. Progesterone was increased at time zero (16.1 nmol/l; RI 0.19–2.22 nmol/l) and 1 h post-ACTH administration (23.2 nmol/l; RI 2.86–14.62 nmol/l). Based on these results, an aldosterone and progesterone-secreting adrenal neoplasm was diagnosed.

A repeat abdominal ultrasound confirmed the presence of a 3.1 cm diameter, circumscribed, hypoechoic mass involving the left adrenal gland, with no evidence of metastases or vascular or renal parenchymal invasion. The right adrenal gland was of normal dimensions and appearance (3.9 mm diameter).

The neurological abnormalities were suggestive of a concurrent left forebrain lesion. It was difficult to determine the clinical course of the neurological signs because profound weakness from hypokalaemia was also present. However, major differential diagnoses included metastasis from an adrenal carcinoma, a primary meningioma or a vascular accident secondary to hypertension.

The cat underwent computed tomography (CT) of the abdomen, thorax and skull under general anaesthesia (Figure 1). There was no evidence of vascular invasion of adjacent blood vessels by the adrenal mass. There was no evidence of metastatic disease within the thorax. On CT of the skull, an extra-axial, rim-enhancing, left forebrain lesion was evident after the administration of iohexol (2 ml/kg, Omnipaque 350; GE Healthcare). Meningioma was suspected and magnetic resonance imaging (MRI) was performed to further characterise the lesion and to confirm that the tumour was solitary, prior to surgical excision (Figure 2).

On MRI the forebrain mass (2 cm × 1.5 cm) was well demarcated and had a broad base towards the periphery

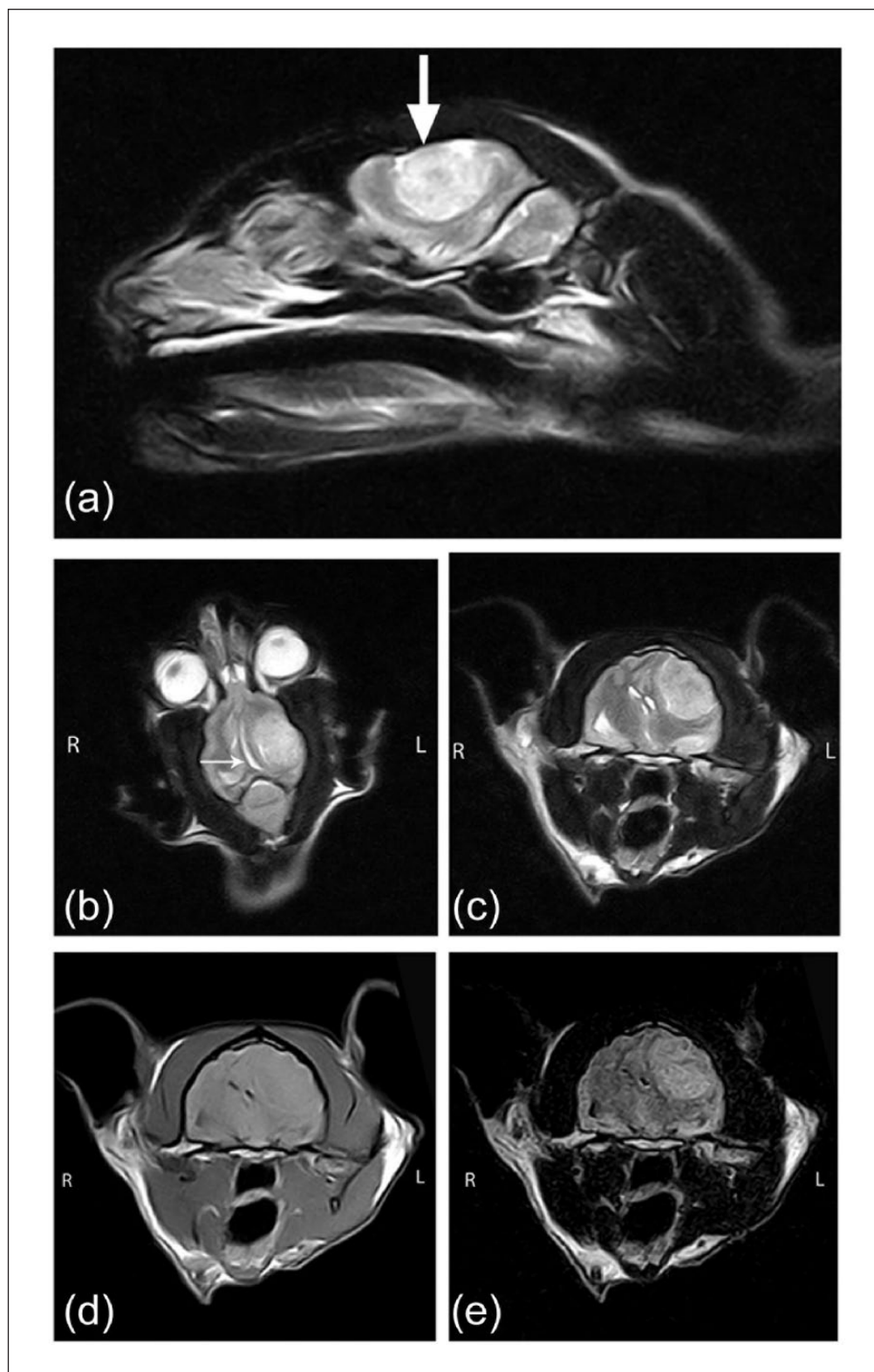


**Figure 1** Postcontrast (a) axial and (b) dorsal images acquired utilising 0.8 mm slice collimation computed tomography at the level of the cranial pole of the left kidney. These images have been reconstructed using a maximum-intensity projection technique with OsiriX software (v.6.1.1.64-bit; Pixmeo Sarl). There is a 2.4 cm (width) × 3 cm (height) × 3.2 cm contrast-enhancing left adrenal mass. The mass is located immediately caudal to the renal artery and adjacent to the vena cava. There is no evidence of invasion into the adjacent vessels. The right adrenal gland cannot be visualised in these images

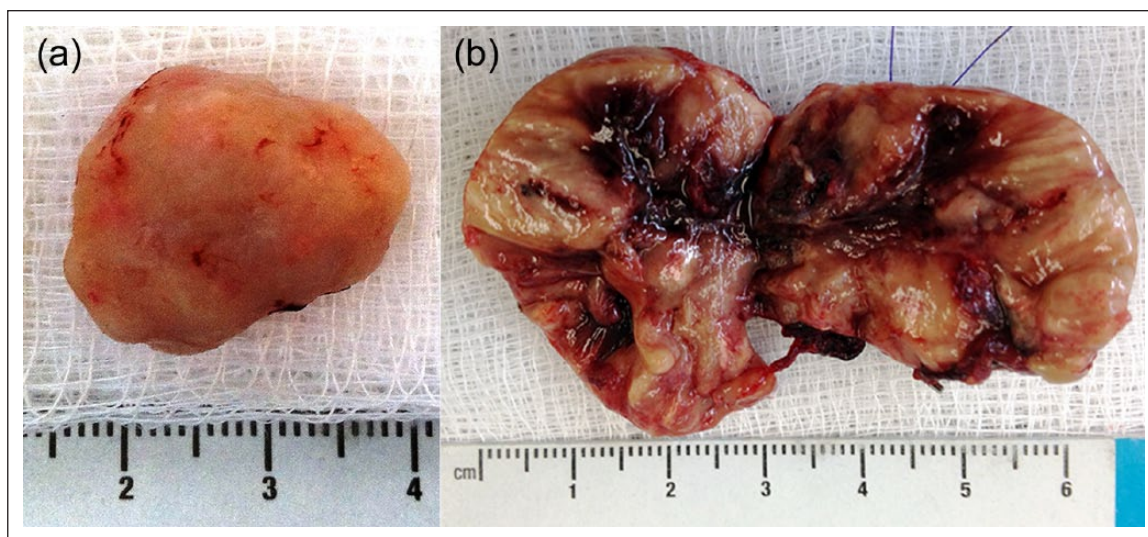
associated with the left parietal lobe causing a midline shift and impingement of the left lateral ventricle. The mass was isointense to grey matter in the T1-weighted sequence and hyperintense in T2-weighted and FLAIR sequences. There was transtentorial herniation of part of the mesencephalon into the caudal fossa and obliteration of the subarachnoid space between the cerebellum and medulla. There was evidence of mild peritumoural oedema. These findings were consistent with a single meningioma.

Anaesthetic recovery was unremarkable and the cat was discharged on amlodipine besylate (1.25 mg q24h PO, Norvasc; Pfizer), spironolactone (6.25 mg q24h PO, Aldactone; Pfizer) and potassium gluconate (156 mg q12h PO, Hypokal; Mavlab). Prednisolone (7.5 mg q12h PO, Pred-X 5; Apex Laboratories) was given to treat suspected cerebral oedema.

Twenty-four hours after discharge the cat re-presented with recurrent vocalisation, a left body turn, stilted hindlimb gait and hindlimb weakness. Serum



**Figure 2** T2-weighted (a) parasagittal, (b) dorsal and (c) axial, and T1-weighted precontrast (d) axial and (e) fluid attenuation inversion recovery (FLAIR) axial 4 mm thickness magnetic resonance images. There is a 2 cm × 1.5 cm well-demarcated mass lesion with a broad base towards the periphery within the left parietal brain lobe (thick arrow). There is evidence of midline shift and impingement of the left lateral ventricle (thin arrow). The mass is isointense to grey matter in the T1-weighted sequences and hyperintense in T2-weighted and FLAIR sequences. The mass is consistent with a meningioma with evidence of increased intracranial pressure.



**Figure 3** (a) Meningioma resected via a rostral craniotomy. (b) Cut surface of the resected adrenocortical adenocarcinoma

acid–base and electrolytes showed persistent hypokalaemia (2.9 mmol/l) and metabolic alkalosis (pH 7.482 [RI: 7.31–7.46]; bicarbonate 31.3 mmol/l [RI 17–21 mmol/l]). A potassium chloride infusion (0.5 mmol/kg/h IV) was given, as well as mannitol (0.25 g/kg IV over 1 h) for suspected increased intracranial pressure. Phenobarbitone (15 mg q12h PO, Phenomav; Mavlab) was also commenced. After stabilisation, the intracranial mass was removed 3 days later via a rostral craniotomy with no complications (Figure 3). On histopathology the mass was composed of spindle cells with ovoid plump nuclei, vesiculate chromatin and small multiple nucleoli. There were distinct cell boundaries with moderate eosinophilic cytoplasm. Psammoma bodies were evident between cell aggregates. A diagnosis of psammomatous meningioma was made. Immunohistochemical staining of the meningioma using a mouse monoclonal antibody to human PR previously validated for use in the cat (Bio-Genex InSite PR antibody [Clone PR88]; Bio-Genex) was performed.<sup>4</sup> There was strong positive labelling of PRs in the meningioma tissue (Figure 4). Mammary adenocarcinoma tissue was utilised as a positive tissue control, and an affinity-purified normal mouse IgG reagent control (preimmune serum) supplied by the manufacturer was used as the negative control.

Postoperative recovery from the craniotomy was uneventful and neurological status markedly improved over the next 2 weeks, except for persistent weakness. Hypokalaemia (2.3–2.9 mmol/l), and metabolic alkalosis (bicarbonate 29.0 mmol/l) and hypertension persisted, while hypertension was controlled (systolic blood pressure 150 mmHg). Left adrenalectomy was performed 2 weeks after the craniotomy. A typed blood transfusion was required postoperatively to treat intra-abdominal

haemorrhage. Hypokalaemia and hypertension resolved and oral potassium, spironolactone and amlodipine were weaned. The patient was discharged from hospital 5 days after surgery. Histopathology of the adrenal tumour was consistent with a low-grade, encapsulated, adrenocortical carcinoma.

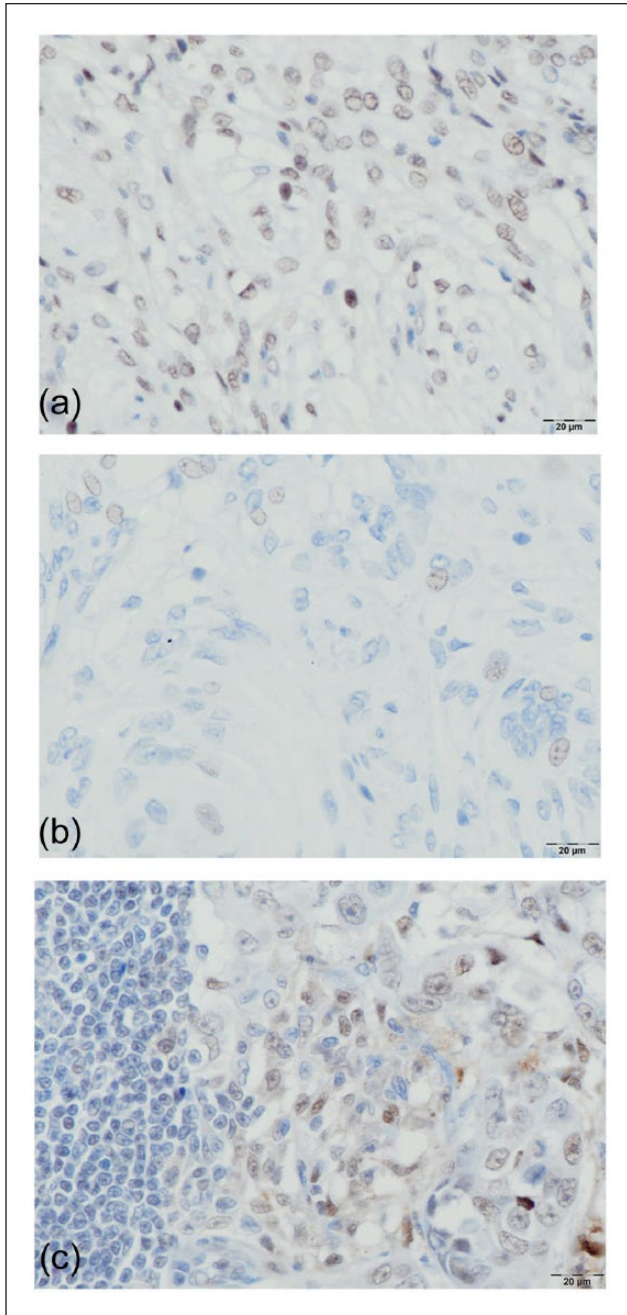
At a recheck, 2 weeks after adrenalectomy, serum biochemistry was suggestive of mineralocorticoid deficiency (mild hyperkalaemia [5.9 mmol/l; RI 3.7–5.4 mmol/l], normal sodium [146 mmol/l; RI 144–158 mmol/l] and low Na:K [24.7; RI >29.0]). Fludrocortisone (0.15 mg daily divided dosage PO, Florinef; Aspen Pharma) was administered. This medication was tapered and then ceased over a 3 week period. A week after stopping the fludrocortisone, serum potassium was normal and the cat continued to gain weight. All neurological deficits had resolved.

Two years post-initial presentation the cat was clinically normal, normotensive and 1 kg heavier (7.5 kg, BCS 4/5). Electrolytes, urea and creatinine were within RIs. No neurological deficits were detected on examination.

## Discussion

To our knowledge, this is the first report in a cat of an adrenal mass secreting aldosterone and progesterone with a concurrent meningioma. The documentation of PRs in a meningioma with concurrent elevation of serum progesterone is also novel.

There are two previous reports of adrenocortical carcinomas secreting aldosterone and progesterone in cats.<sup>5,6</sup> Hyperprogesteronism in cats with aldosterone-secreting adrenal tumours may be under-reported. Clinical signs associated with hyperprogesteronism may be subtle, or as in this case, absent. Alternatively, hyperprogesteronism can resemble hypercortisolaemia with



**Figure 4** Photomicrograph of meningeoma tissue (a) after immunohistochemical staining for progesterone receptors (PRs). Note the positive labelling of most nuclei compared with the relative absence of labelling with the negative antibody control (b). (c) PRs are present within the positive antibody control (mammary adenocarcinoma tissue). Immunohistochemistry was performed using a mouse monoclonal antibody to PRs (Bio-Genex Insite PR antibody [Clone PR88]; Bio-Genex) and the peroxidase method with 3,3'-diaminobenzidine chromagen and a light haematoxylin counterstain

signs including polyuria, polydipsia, poor coat condition, seborrhoea, thin fragile skin and a pot-bellied appearance.<sup>7-10</sup> Other co-hormone secretions reported in

cats with adrenocortical tumours include androstenedione and testosterone in one case,<sup>11</sup> and testosterone and oestradiol in another.<sup>12</sup> Concurrent cortisol and sex steroid-secreting adrenal tumours have not been reported in cats. We measured progesterone in this case because of our previous observation of hyperprogesteronism in a cat with concurrent hyperaldosteronism.<sup>5</sup> We cannot rule out the possibility of cortisol or other adrenal steroid hormone secretion, as other adrenal hormones were not measured. In other cases of feline adrenal progesterone/sex-steroid secreting tumours, low post-ACTH cortisol concentrations were reported.<sup>8,10,11</sup> Potential mechanisms for this response include a lack of enzymes within the adrenal tumour to convert progesterone to cortisol, or hypothalamic-pituitary-adrenal axis suppression from excessive circulating levels of cortisol as a result of displacement from cortisol binding protein by progesterone. In humans, adrenal tumours have been shown to co-secrete aldosterone with cortisol, testosterone, progesterone and androstenedione.<sup>13-15</sup> Enhancement of the biosynthetic pathway of aldosterone in an aldosterone-secreting tumour, resulting in increased serum concentrations of the intermediates of aldosterone production, including progesterone, is proposed to account for some cases.<sup>6</sup> Alternatively, neoplastic cells within the zona glomerulosa and fasciculata/reticularis may directly increase secretion of aldosterone and progesterone, respectively.<sup>13</sup>

Meningiomas are the most common primary intracranial tumour in cats, dogs and humans.<sup>16-20</sup> In cats, they comprise 33-59% of neoplasms of the central nervous system.<sup>16,17,20,21</sup> Meningiomas are derived from the arachnoid cap cells associated with the venous sinus of the dura.<sup>16</sup> In cats, meningiomas are usually histologically benign, but their behaviour may be malignant.<sup>4,16,17,20</sup>

Rapid progression of neurological symptoms due to meningioma in human pregnancy was first reported by Cushing and Eisenhardt in 1938, and the association between excessive progesterone secretion and the development, or accelerated growth, of meningiomas is now well established in human medicine, where hormone replacement therapy, contraceptive implants and breast carcinoma are also implicated.<sup>3,18,22-24</sup> The development of multiple meningiomas during prolonged progesterone agonist therapy that regressed with cessation of treatment is also compelling evidence of this association.<sup>18,22</sup> Further, the incidence of meningiomas in women is twice as high as in men, especially during their reproductive life period.<sup>3,18,22</sup> There is also a known association between the development of meningioma and carcinoma of the breast.<sup>3,18,22,24</sup>

Sex hormone receptor expression in meningiomas from humans, cats and dogs has been reported.<sup>2,3,4,25-27</sup> In humans, PRs are detected in >64% of meningiomas, and oestrogen receptors (ER) are expressed to a lesser

extent.<sup>1-3</sup> In vitro and in vivo studies have also shown that these receptors are functional.<sup>1</sup> Adamo et al reported that feline meningiomas,<sup>4</sup> like human ones, have a high proportion of PRs and an absence of ERs. To our knowledge serum progesterone levels have not been investigated in cases of feline and canine meningioma. PR expression is less likely in more aggressive and atypical meningioma cases in people and dogs.<sup>3,25,26,28</sup> This association has not been definitively established in cats but appears likely.<sup>4,25</sup>

Assay of progesterone and other aldosterone intermediates in cats with aldosterone-producing tumours is recommended as co-hormone secretion may be underreported. In a survey of laboratory submissions of feline sera for aldosterone assay, marked elevations in corticosterone and progesterone were detected in some cats with marked elevation of aldosterone (>3000 pmol/l).<sup>28</sup> Elevated serum progesterone levels may contribute to muscle weakness and hypertension seen in these patients.<sup>29</sup>

## Conclusions

Clinicians should maintain an index of suspicion for hyperprogesteronism in cats, particularly where progressive intracranial signs are detected. The role of hyperprogesteronism and PRs on meningioma growth in cats requires further investigation.

**Acknowledgements** Lachlan Hughes, Angela Phillips, Esther Tarszisz and Graeme Allan assisted with initial work-up of the cat.

**Conflict of interest** The authors declared no potential conflicts of interest with respect to the research, authorship, and/or publication of this article.

**Funding** The authors received no financial support for the research, authorship, and/or publication of this article.

**Addendum** An additional case of a cat with an adrenal tumour co-secreting aldosterone, progesterone and oestradiol, was recently reported.<sup>30</sup>

## References

- Black P, Carroll R and Zhang J. **The molecular biology of hormone and growth factor receptors in meningiomas.** In: Fahlbusch R, Bock WJ, Brock M, et al. (eds). *Modern neurosurgery of meningiomas and pituitary adenomas.* Vienna, Austria: Springer, 1996, pp 50–53.
- Carroll RS, Zhang J, Dashner K, et al. **Progesterone and glucocorticoid receptor activation in meningiomas.** *Neurosurgery* 1995; 37: 92–97.
- Hsu DW, Efirid JT and Hedley-Whyte ET. **Progesterone and estrogen receptors in meningiomas: prognostic considerations.** *J Neurosurg* 1997; 86: 113–120.
- Adamo PF, Cantile C and Steinberg H. **Evaluation of progesterone and estrogen receptor expression in 15 meningiomas of dogs and cats.** *Am J Vet Res* 2003; 64: 1310–1318.
- Briscoe K, Barrs VR, Foster DF, et al. **Hyperaldosteronism and hyperprogesteronism in a cat.** *J Feline Med Surg* 2009; 11: 758–762.
- DeClue AE, Breshears LA, Pardo ID, et al. **Hyperaldosteronism and hyperprogesteronism in a cat with an adrenal cortical carcinoma.** *J Vet Intern Med* 2005; 19: 355–358.
- Flood SM, Randolph JF, Gelzer A, et al. **Primary hyperaldosteronism in two cats.** *J Am Anim Hosp Assoc* 1999; 35: 411–416.
- Boord M and Griffin C. **Progesterone secreting adrenal mass in a cat with clinical signs of hyperadrenocorticism.** *J Am Vet Med Assoc* 1999; 214: 666–669.
- Refsal KR and Harvey AM. **Feline primary hyperaldosteronism** In: Bonagura JD and Twedt DC (eds). *Kirks's current veterinary therapy.* St Louis, MO: Elsevier Saunders, 2014, pp 238–242.
- Rossmeisl J, Scott-Moncrieff J, Siems J, et al. **Hyperadrenocorticism and hyperprogesteronemia in a cat with an adrenocortical adenocarcinoma.** *J Am Anim Hosp Assoc* 2000; 36: 512–517.
- Millard RP, Pickens EH and Wells KL. **Excessive production of sex hormones in a cat with an adrenocortical tumor.** *J Am Vet Med Assoc* 2009; 234: 505–508.
- Boag AK, Neiger R and Church DB. **Trilostane treatment of bilateral adrenal enlargement and excessive sex steroid hormone production in a cat.** *J Small Anim Pract* 2003; 45: 263–266.
- Gláz E, Rác K, Varga I, et al. **Mineralocorticoid production of adrenal cortical adenomas.** *J Steroid Biochem Mol Biol* 1993; 45: 57–64.
- Spaeth M, Korovkin S, Antke C, et al. **Aldosterone- and cortisol-co-secreting adrenal tumors: the lost subtype of primary aldosteronism.** *Eur J Endocrinol* 2011; 164: 447–455.
- Peppia M, Pikounis V, Papaxoinis G, et al. **Adrenocortical carcinoma secreting cortisol, androgens and aldosterone: a case report.** *Cases J* 2009; 2: 8951–8951.
- Adamo PF, Forrest DL and Dubielzig R. **Canine and feline meningiomas: diagnosis, treatment, and prognosis.** *Compend Contin Educ Vet* 2004; 27: 951–966.
- Motta L, Mandara MT and Skerritt GC. **Canine and feline intracranial meningiomas: an updated review.** *Vet J* 2012; 192: 153–165.
- Claus EB, Bondy ML, Schildkraut JM, et al. **Epidemiology of intracranial meningioma.** *Neurosurgery* 2005; 57: 1088–1095.
- Sessums K and Marianai C. **Intracranial meningioma in dogs and cats: a comparative review.** *Compend Contin Educ Vet* 2009; 31: 330–339.
- Tomek A, Cizinauskas S, Doherr M, et al. **Intracranial neoplasia in 61 cats: localisation, tumour types and seizure patterns.** *J Feline Med Surg* 2006; 8: 243–253.
- Bradshaw J, Pearson G and Gruffydd-Jones T. **A retrospective study of 286 cases of neurological disorders of the cat.** *J Comp Pathol* 2004; 131: 112–120.
- Rivkin M, Toms A, Bronov O, et al. **Cerebellopontine angle chondroid meningioma apoplexy complicating a third trimester pregnancy: case report and review of the literature.** *J Clin Gynecol Obstet* 2013; 2: 84–89.
- Cowppli-Bony A, Bouvier G, Rué M, et al. **Brain tumors and hormonal factors: review of the epidemiological literature.** *Cancer Causes Control* 2011; 22: 697–714.

- 24 Custer BS, Koepsell TD and Mueller BA. **The association between breast carcinoma and meningioma in women.** *Cancer* 2002; 94: 1626–1635.
- 25 Mandara M, Ricci G, Rinaldi L, et al. **Immunohistochemical identification and image analysis quantification of oestrogen and progesterone receptors in canine and feline meningioma.** *J Comp Pathol* 2002; 127: 214–218.
- 26 Pravdenkova S, Al-Mefty O, Sawyer J, et al. **Progesterone and estrogen receptors: opposing prognostic indicators in meningiomas.** *J Neurosurg* 2006; 105: 163–173.
- 27 Shayanfar N, Mashayekh M and Mohammadpour M. **Expression of progesterone receptor and proliferative marker Ki67, in various grades of meningioma.** *Acta Med Iran* 2010; 48: 142–147.
- 28 Refsal KR and Mazaki-Tovi M. **Baseline concentration of progesterone, cortisol, and corticosterone in a laboratory survey of feline sera submitted for assay of aldosterone [abstract].** *Proceedings of the 19th Annual ECVIM Companion Animals Congress*; 2009 September 8–10; Porto, Portugal.
- 29 Harvey AM and Refsal KR. **Primary hyperaldosteronism** In: Rand J, Behrend EN, Gunn-Moore D, et al (eds). *Clinical endocrinology of companion animals*. 1st ed. Hoboken, NJ: John Wiley, 2013, pp 115–127.
- 30 Daniel G, Mahony OM, Markovich JE, et al. **Clinical findings, diagnostics and outcome in 33 cats with adrenal neoplasia (2002–2013).** *J Feline Med Surg*. Epub ahead of print 24 February 2015. DOI: 10.1177/1098612X15572035.